

## CASE REPORT / ПРИКАЗ БОЛЕСНИКА

# Tumors of the orbit as the first manifestation of a lung and breast malignancy

Mihailo Stjepanović<sup>1,2</sup>, Nikola Marić<sup>1</sup>, Marko Baralić<sup>3</sup>, Jasmina Marić-Živković<sup>1</sup>, Violeta Mihailović-Vučinić<sup>1,2</sup>

<sup>1</sup>Clinical Center of Serbia, Clinic of Pulmonology, Belgrade, Serbia;

<sup>2</sup>University of Belgrade, Faculty of Medicine, Belgrade, Serbia;

<sup>3</sup>Clinical Center of Serbia, Clinic of Nephrology, Belgrade, Serbia



## SUMMARY

**Introduction** Orbit is one of the rarer locations for the metastasis of malignant tumors. The symptoms of orbital tumors are nonspecific, but require detail diagnostics. Methods of visualization, such as ultrasound, radiography, computed tomography scan and/or magnetic resonance imaging of the endocranium are a mandatory step in the diagnostics in order to determine not only the spread of the malignancy but also the affliction of the surrounding structures. The orbital manifestations can be the first sign of the malignant disease.

**Outline of cases** The first case report presents a female patient with ocular symptomatology as a result of a metastasis of previously undiscovered breast cancer, and the second report presents a male patient with undiscovered lung cancer also presenting with ocular symptomatology.

**Conclusion** An orbital tumor should instigate further diagnostic procedures, as it can be the first sign of a disseminated malignant disease.

**Keywords:** orbit; cancer; metastasis; lungs; breast

## INTRODUCTION

Tumor of the orbit is a term that encompasses a wide array of both benign and malignant processes located in the orbit or in its structures (mainly bone structures). Some of these processes are vascular malformations, inflammations, proliferation of the adipose tissue (in Graves–Basedow disease), benign and malignant tumors. The clinical manifestation of the orbital tumors is, most commonly, nonspecific, and is manifested with exophthalmos, ptosis, ocular pain, or visual disorders. Computed tomography (CT), magnetic resonance imaging (MRI) and ultrasound are important visualization methods in the diagnostic of these tumors, as well as providing important data in choosing the best treatment options [1]. Depending of the etiology and clinical presentation, the treatment options of the orbital tumors are pharmacological, surgical, or radiational [2, 3]. We present two clinical cases where the primary manifestation of a malignant disease, whose primary localization is extraorbital, is orbital symptomatology.

## REPORTS OF CASES

### Case 1

Female patient, aged 54 years, was initially treated at the Clinic of Ocular Diseases, Clinical Center of Serbia, due to double vision, ocular

pain, and suddenly developed divergent strabismus. Retrobulbar mass was discovered and a biopsy was performed. The pathohistological finding was that of a metastatic adenocarcinoma. As a part of a preoperative diagnostic, a chest X-ray was performed and showed a bilateral pleural effusion. A pulmonologist was consulted, who indicated the hospitalization at the Clinic of Pulmonology. After hospitalization, a diagnostic pleural thoracentesis was performed and its pathohistological finding was that of a chronic fibrosing pleuritis. In the effusion itself, malignant cells were discovered; however, further differentiation could not have been performed. During the physical examination, enlarged lymph nodes in both axilla were found, so mammography was performed. The mammography showed a malignant lesion in the left breast, classified as T2N1Mx. In order to determine the spread of the malignant disease, radiography of the head, spine, and pelvis was performed, which showed multiple osteolytic metastases (Figure 1). After performing all of the previously stated diagnostic procedures, as well as the revision of the orbital tumor biopsy, it was concluded that the patient had primary breast cancer with the metastasis in the orbit, pleura, and the skeletal system. The patient was presented to the Council for Primary Breast Cancer at the Institute for Oncology and Radiology of Serbia. The Council suggested treatment with systemic chemotherapy – fluorouracil, Adriamycin, and Cytoxan (FAC) regimen.

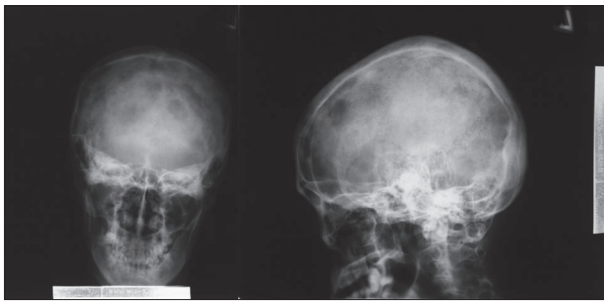
**Received • Примљено:**  
December 2, 2019

**Accepted • Прихваћено:**  
June 15, 2020

**Online first:** June 29, 2020

### Correspondence to:

Mihailo STJEPANOVIĆ  
Clinic of Pulmonology  
Clinical Center of Serbia  
Koste Todorovica 26/20  
11000 Belgrade, Serbia  
[mihailostjepanovic@gmail.com](mailto:mihailostjepanovic@gmail.com)



**Figure 1.** Radiography of the skull and spine with osteolytic metastases

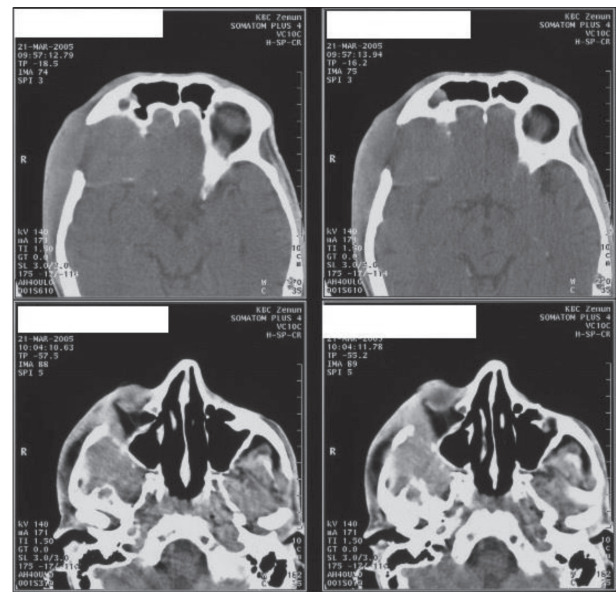
## Case 2

Male patient, 47 years old, was admitted to the Clinic of Ocular Diseases, presenting with a ptosis of the right eyelid. He did not have any respiratory symptoms at the time of admission. As a part of the diagnostic procedure, a CT scan of the endocranium was performed (Figure 2), which showed that the ptosis was caused by a tumor of the orbit. Additional diagnostic procedures were performed and chest X-ray showed enlarged right hilum with elements of infiltration present. This finding was further expanded with a CT scan of the thorax and the abdomen (Figure 3), which showed a primary tumor mass in the right lung with multiple osteolytic metastases in the thoracic vertebrae, left iliac bone, and in the skull. Multiple osteolytic metastases had been confirmed with scintigraphy (Figure 4), and new metastases in the sternum and ribs were detected. The patient was transferred to the Clinic of Pulmonology. Taking into consideration the state of the patient (severe cachexia, cyanosis) and a severe decrease in pulmonary function, predominantly obstructive type (FVC 44.2%, FEV1 21.4%, FEV1/FVC 38.85), further diagnostic procedures were not performed at that time, and symptomatic treatment was applied. Despite all of the therapeutic measurements, the patient suffered a lethal outcome.

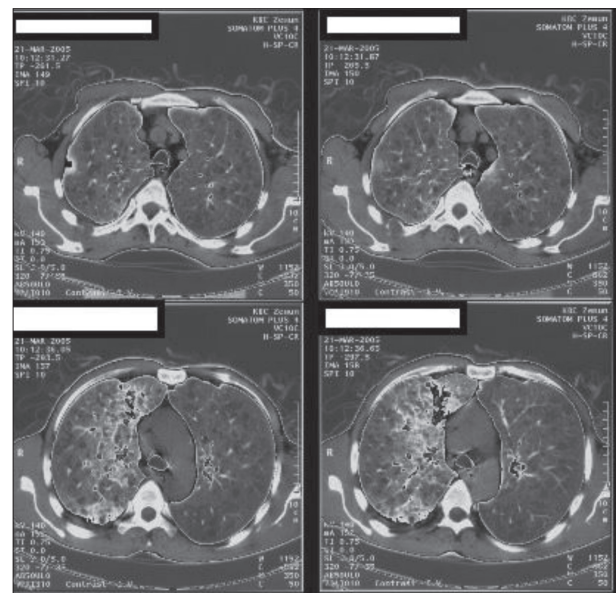
Consent was obtained from the patients for publication of this report and any accompanying images.

## DISCUSSION

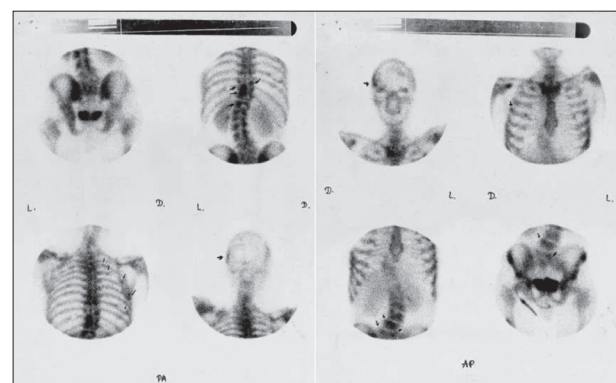
Although rare, the signs and symptoms of the metastasis in the ocular region can be the first sign of a malignant disease [4]. As for the metastasis of the non-small cell lung cancer, the eye represents an uncommon localization [5]. Clinical symptoms evolve rather quickly, in a matter of weeks or months, and consist of exophthalmos and difficulty in moving the eye itself. Pain, double vision, and other visual problems are also frequent. It should be noted that, depending on the destruction of other nearby structures, the patient could present with an enophthalmos. Certain studies have shown a relative correlation between the localization of the metastasis in the orbit and its primary localization. Breast cancer has an affinity for the adipose and muscular tissue, prostate cancer afflicts the bone, and melanoma most commonly afflicts the muscular tissue [6].



**Figure 2.** Computed tomography scan of the endocranium, showing a tumor infiltrating the base of the skull, zygomatic bone, and the walls of the orbit, with penetration in the endocranium



**Figure 3.** Computed tomography scan of the thorax, showing emphysema, tumor, and multiple metastatic changes



**Figure 4.** Scintigraphy with multiple osteoblastic changes in the vertebrae, sternum, scapula, skull, and ribs

Ocular manifestations can be the first symptoms of a malignant disease primary located elsewhere. The incidence of an ocular metastasis in lung cancer is 4–6.7% [7]. A case report at the University Hospital in Bohn has shown a patient, aged 65 years, who presented with an afferent pupillary defect in his vision. The initial diagnosis was that of an acute optic ischemia. However, after further diagnostics, it was discovered that the metastasis of the lung cancer caused the compression of the optic nerve, which in turn caused the visual deficit [8]. A patient similar to our second case report, was described by doctors in Japan. The patient, 55 years of age, had a sudden onset of double vision with no respiratory symptomatology. The initial MRI of the endocranium showed a tumor in the right orbit, with destruction of the surrounding bone structures. The finding was supplemented with a CT scan of the thorax, and the full body scintigraphy. The CT scan showed a tumor in the right lung, 4 cm in diameter. Pathohistological finding showed that the tumor is an adenocarcinoma, and scintigraphy showed multiple osteolytic metastases. Taking into consideration all of the diagnostic results, it was concluded that the patient had adenocarcinoma of the lungs with multiple metastases. The patient was treated with chemo- and radiotherapy; however, three months after the diagnosis was set, despite the therapy, the patient died [9]. A case report from Indonesia had showcased a 39-year-old woman who presented with blindness and nonproductive cough. The physicians performed a panel of diagnostic procedures similar to our own, and were able to perform

a biopsy of a supraclavicular lymph node, which showed that the patient had adenocarcinoma of the lung. After a multidisciplinary approach, it was concluded that the patient had stage IV lung cancer, and was treated with chemotherapy. Unfortunately, after the first cycle, the patient passed away [10].

The orbit is not a common localization of the metastasis for malignant tumors [11]. More often than not, the ocular symptomatology is the first sign of the malignancy. Methods of visualization, such as CT scan, MRI, and full-body scintigraphy, are important to diagnose the underlying disease, as well as its spread. However, it is important to know that the lethality in these patients is significantly higher, due to the fact that these patients usually have multiple metastases. Certain tumor markers have shown promise in predicting the development of ocular metastases, although further research is needed [12]. The purpose of our case reports is to present these relatively rare forms of metastases, and to help in everyday clinical practice in diagnosing the primary malignant disease.

#### ACKNOWLEDGEMENT

This study was supported by the Ministry of Education and Science of the Republic of Serbia (grants no. 175046 and 175081).

**Conflict of interest:** None declared.

#### REFERENCES

- Gündüz K, Yanik Ö. Myths in the Diagnosis and Management of Orbital Tumors. *Middle East Afr J Ophthalmol*. 2015;22(4):415–20.
- Yao WC, Bleier BS. Endoscopic management of orbital tumors. *Curr Opin Otolaryngol Head Neck Surg*. 2016;24(1):57–62.
- Rokohl AC, Koch KR, Kabbasch C, Kreppel M, Lüers JC, Grau S, et al. Importance of interdisciplinary collaboration for optimal treatment of orbital tumors. *HNO*. 2019;67(7):528–33.
- Lazaros K, Bertil D. Intraocular Metastases A Review. *Asia-Pacific J of Ophthalmol*. 2017;6(2):208–14.
- Niu F, Zhou Q, Yang J, Zhong WZ, Chen ZH, Deng W, et al. Distribution and prognosis of uncommon metastases from non-small cell lung cancer. *BMC Cancer*. 2016;16:149.
- Goldberg RA, Rootman J, Cline RA. Tumors metastatic to the orbit: a changing picture. *Surv Ophthalmol*. 1990;35(1):1–24.
- Nelson CC, Hertzberg BS, Klintworth GK. A histopathologic study of 716 unselected eyes in patients with cancer at the time of death. *Am J Ophthalmol*. 1983;95(6):788–93.
- Becker EJ, Herwig MC, Holz FG, Kuchelmeister K, Thomas D, Charbel-Issa P, et al. Orbital metastasis of a previously unknown lung carcinoma mimicking posterior ischemic optic neuropathy. *Ophthalmologe*. 2015;112(6):525–8.
- Mori H, Maekawa N, Satoda N, Otsuka N, Sakai N, Fukuse T. A case of primary lung cancer with initial symptoms due to orbital metastases. *Nihon Kogyoku Gakkai Zasshi*. 2003;41(1):19–24.
- Soeroso NN, Tarigana SP, Saragiha W, Sari ND, Lubis N, Lubis H. Lung adenocarcinoma presenting with an orbital metastasis. *Respir Med Case Rep*. 2018;25:116–18.
- Ducasse A, Merol JC, Bonnet F, Litré F, Arndt C, Larré I. Adult orbital tumors. *J Fr Ophtalmol*. 2016;39(4):387–99.
- Ge QM, Zou YT, Shi WQ, Zhang YQ, Li B, Min YL, et al. Ocular Metastasis in Elderly Lung Cancer Patients: Potential Risk Factors of CA-125, CA-153 and TPSA. *Cancer Manag Res*. 2020;12:1801–08.

## Тумори орбите као прво испољавање малигне болести плућа и дојке

Михаило Стјепановић<sup>1,2</sup>, Никола Марић<sup>1</sup>, Марко Баралић<sup>3</sup>, Јасмина Марић-Живковић<sup>1</sup>, Виолета Михаиловић-Вучинић<sup>1,2</sup>

<sup>1</sup>Клинички центар Србије, Клиника за пулмологију, Београд, Србија;

<sup>2</sup>Универзитет у Београду, Медицински факултет, Београд, Србија;

<sup>3</sup>Клинички центар Србије, Клиника за нефрологију, Београд, Србија

### САЖЕТАК

**Увод** Орбита представља једну од ретких локација метастаза малигнух тумора. Симптоми тумора орбите су неспецифични, али захтевају детаљну дијагностику. Методе визуелизације као што су ултразвук, радиографија лобање и компјутеризована томографија / магнетна резонантна томографија ендокранијума представљају обавезан корак у дијагностици како би се тачно одредили степен раширености метастазе и захваћеност околних структура. Треба напоменути да симптоматологија везана за метастатски тумор орбите може бити први знак малигне болести.

**Приказ болесника** Први приказ случаја се тиче жене са орбиталном симптоматологијом која је последица метастазе претходно неоткривеног карцинома дојке, док се у другом случају ради о мушкарцу са орбиталним испољавањима метастатског карцинома плућа, такође претходно недијагностикованог.

**Закључак** Малигни тумори орбите треба да подстакну даљу дијагностику код оболелог, с обзиром на то да могу бити последица дисеминоване малигне болести.

**Кључне речи:** орбита; карцином; метастаза; плућа; дојка