



CASE REPORT / ПРИКАЗ БОЛЕСНИКА

Upper limb robotic neurorehabilitation after pediatric stroke

Hristina Čolović^{1,2,3}, Lidija Dimitrijević^{1,2}, Vanja Đurić³, Sonja Janković⁴

¹University of Niš, Faculty of Medicine, Niš, Serbia;

²Clinical Center of Niš, Physical Medicine and Rehabilitation Clinic, Niš, Serbia;

³Polyclinic Neuromedic, Niš, Serbia;

⁴Clinical Center of Niš, Department of Radiology, Niš, Serbia

SUMMARY

Introduction Pediatric brain stroke is a rare condition, with the incidence of 1.2–13/100,000. The most common consequence is hemiparesis with unilateral hand impairment. There is level 4 evidence that robotics may improve the function of upper limbs. In this paper, we present the effect of combined robotic rehabilitation and kinesitherapy on the distal portion of the arm in the chronic phase of hemiparesis in childhood.

Case outline In a 7.5-year-old girl the treatment with robotic neurorehabilitation was administered in the chronic phase of post-stroke rehabilitation, 18 months after the stroke, involving individualized kinesitherapy for 30 minutes, and virtual reality-based rehabilitation using the robotic Smart Glove for 30 minutes. The rehabilitation protocol was administered for 12 weeks (five times a week). The results of therapeutic evaluation showed that the level 2 of Manual Ability Classification System remained unchanged until the end of treatment, while the grade assigned for the spasticity of flexors in the forearm and fingers was 2 at the treatment onset, 1+ after four weeks of therapy, and 1 after eight and 12 weeks of therapy. Qualitative improvement of arm function through the increase of the overall value of the Quality of Upper Extremity Skills Test was evidenced at each evaluation testing, being the greatest after the first four weeks of rehabilitation (4.83%).

Conclusion The result of our study suggests that combined robotic rehabilitation and kinesitherapy can improve the functional motor performance of the arm involved in the chronic recovery phase after a pediatric stroke.

Keywords: pediatric stroke; upper limb; robotics; rehabilitation

INTRODUCTION

A brain stroke is a devastating disease predominantly occurring in the elderly; however, it may occur in children as well. In general, pediatric stroke can be divided into arterial ischemic stroke (AIS) and hemorrhagic stroke. The division is the same as in the adult population, but the difference lies in its etiology [1].

The incidence of pediatric stroke ranges 1.2–13/100,000 inhabitants and it is considered a rare condition in the pediatric population [2]. The incidence rate of childhood AIS has been 1.6/100,000 per year [3]. However, it is a worrisome fact that the prevalence of pediatric stroke has risen by around 35% between 1990 and 2013 [4].

The risk factors for AIS in the pediatric population are arteriopathy, cardiac disease, cardiac surgery/interventions, sickle cell disease, infections, thrombophilia, etc. [5].

The signs and symptoms of acute stroke in children are similar to those in adults. The most common symptoms include hemiparesis and hemifacial weakness in 67–90%, and speech or language disturbances in 20–50% [6]. Clinical presentation of childhood stroke varies depending on the age of the child, with younger

children usually having motor deficits, while older children commonly have a combination of language disorders and motor deficits [7]. It has been proposed in some studies that the recovery patterns and pathways differ between children and adults affected by stroke [8].

In spite of these differences in the aspects of etiology and recovery, therapeutic approaches for pediatric stroke are still largely based on the treatment of stroke in adults [2]. It should be stressed that stroke in childhood presents a serious rehabilitation challenge since in a high percentage of the affected it leads to physical, cognitive, and psychosocial disability. These deficits have a deep impact on independent functioning, everyday activities, and the quality of life of the affected children. Since there is a lack of randomized controlled studies that would address the issue, the optimal treatment is still debated upon, and most of the rehabilitation recommendations are based on expert consensus or weak evidence [5, 9, 10]. Recovery of the arm function is one of the main goals of rehabilitation attempts after childhood stroke; the upper limb function is essential in the performance of everyday activities and has a significant impact on independent functioning and the overall quality of life of the affected

Received • Примљено:

January 4, 2020

Accepted • Прихваћено:

February 27, 2020

Online first: March 3, 2020

Correspondence to:

Hristina ČOLOVIĆ

Branka Krsmanovića 17/34

18000 Niš, Serbia

hristina.colovic@medfak.ni.ac.rs

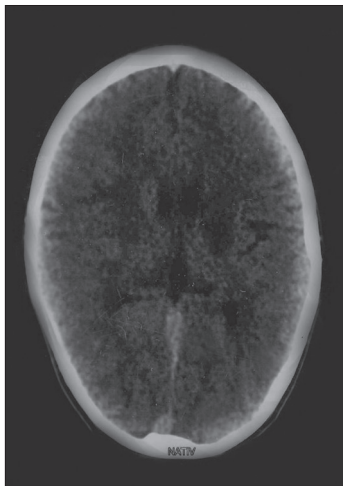


Figure 1. Multidetector Computed Tomography angiography in the axial plane showing a hypodense zone in the basal ganglia and internal capsule of the left side

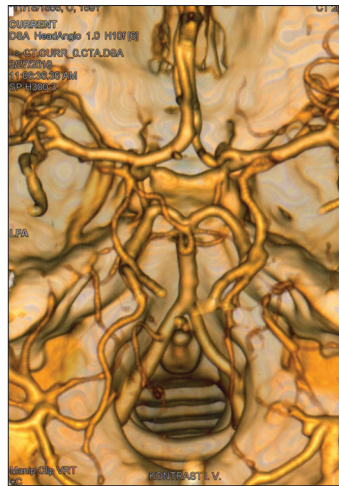


Figure 2. Multidetector computed tomography angiography, presented in 3D volume rendering technique, showing patency of intracranial arteries




Figure 3. RAPAEL Smart Glove™

children. The described abilities are largely determined by the distal function of the upper limb.

The first published systematic review of the papers dealing with the effectiveness of non-pharmacological rehabilitation interventions in motor and cognitive impairments after pediatric stroke has indicated that the available evidence supports the use of robotics in the rehabilitation of an upper limb [11].

CASE REPORT

In a 7.5-year-old girl, the treatment with robotic neurorehabilitation was administered in the chronic phase of post-stroke rehabilitation. At the age of five years and 10 months, after an hour-long strong headache, right-sided dissociated-type hemiparesis had developed (plegic arm and severely paretic leg). Multidetector Computed Tomography (MDCT) angiography in the axial plane showed a hypodense zone in the basal ganglia and internal capsule of the left side (Figure 1). MDCT angiography scanning, performed 2.5 months after the stroke, showed patency of intracranial arteries (Figure 2). An early rehabilitation treatment was introduced on the fourth post-stroke day, followed by an intensive rehabilitation treatment at the Physical Medicine and Rehabilitation Clinic, continuing rehabilitation with periodical out-patient treatment. Prior to robotic rehabilitation treatment, it was established that there were no cognitive impairments nor speech impairments.

The rehabilitation protocol was administered on the distal part of the paretic arm, consisting of individualized kinesitherapy (exercises to increase the motion range, to stretch shortened muscles, to strengthen agonist muscles) for 30 minutes, and virtual reality (VR)-based rehabilitation using the robotic Smart Glove (SG) for 30 minutes, under constant supervision of trained, licensed therapists.

The rehabilitation protocol was administered for 12 weeks (five times a week).

The RAPAEL Smart Glove™ (Neofect, Yong-in, Korea) is a high technology device designed for rehabilitation of the distal portion of an upper limb after brain stroke (Figure 3). The glove represents a sensory device, supported by a computer system, able to follow/detect and measure the range of movements of the distal portion of the arm: forearm (pronation/supination), wrist (flexion/extension, radial/ulnar deviation), and fingers (flexion/extension of each of the fingers). The training games are divided in accordance with the aforementioned movements of all joint segments.

In each game, the patient is asked to perform a task associated with a particular movement. The games simulate the activities of daily living, and owing to the algorithm the SG adjusts individually the optimal game difficulty level (for games such as catching a butterfly, chopping food, playing drums, squeezing oranges, fishing, table sweeping), with visual feedback information.

The observed parameters of therapeutic evaluation are spasticity and functional motor status of the arm.

Spasticity was assessed according to the Modified Ashworth Scale [12].

The manual ability was classified according to the Manual Ability Classification System (MACS) [13]. Quality of Upper Extremity Skills Test (QUEST) was used for the assessment of the achieved functional motor level of the arm [14].

The measurements of the above parameters were performed before the treatment, and four, eight, and 12 weeks after the treatment started. There were no adverse events during the intervention and during the measurement of outcomes.

The results of the therapeutic evaluation showed that the level 2 of MACS remained unchanged until the end of treatment, while the grade assigned for the spasticity of

flexors in the forearm and fingers was 2 at the treatment onset, 1+ after four weeks of therapy, and 1 after eight and 12 weeks of therapy. The total value of QUEST at the first testing was 79.71%; 84.54% after four weeks; 88.73% after eight weeks; and 90.18% at the completion of therapy. The greatest increase of QUEST subscore was evident in the domain of grasping, for as high as 14.12% in relation to the initial value.

This case report was approved by the institutional ethics committee, and written consent was obtained from the patient for the publication of this case report and any accompanying images.

DISCUSSION

There have not been many papers dealing with the issue of long-term arm recovery after pediatric stroke, in contrast to the adult populations, for which it has been established long ago that the distal portion of the upper limb is the last part of the body to recover [15]. In recent years, the interest in this problem has slightly increased. A study of the problem of pediatric AIS has been published, dealing with the motor functional outcomes and recognition of early poor outcome predictors aiming at adequate early interventions and long-term rehabilitation. The results suggest that fine motor functioning, adaptive behavior, the performance of the activities of daily living, and the overall quality of life are all lower compared to population norms. It has been found that pre-school children have poorer motor outcomes [16].

In the design of the rehabilitation protocol we abided by the recommendations of the Royal College of Paediatrics and Child Health (2017): Stroke in childhood and Royal College of Physicians Intercollegiate Stroke Working Party (2016), stating that the time from stroke should not prevent us from considering intensive training and that it is necessary to engage in training for at least 45 minutes every day for as long as patients are willing to participate, showing some measurable benefits from the treatment [5, 17]. The rehabilitation protocol in our study lasted 60 minutes, five times a week for 12 weeks. Due to common cold and family reasons, the patient did not attend treatment four times.

Considering the use of robotics, we should stress that it is a technologically innovative approach so that standard protocols and measurement indicants in the assessment of robotic neurorehabilitation have not yet been reported in the literature. It is, however, interesting for the children, it motivates them quickly to actively participate in the performance of movements that simulate everyday activities, with very important feedback incorporating vision, hearing, proprioception. Our opinion is that the lack of randomized studies is the reason for level 4 evidence that robotics may improve the function of upper limbs in children with hemiplegia and spasticity [11]. In particular,

this level has been determined based on a paper in which a significant beneficial effect was achieved in hemiplegic children in terms of movement coordination and spasticity, which were maintained for as much as a month after robotic therapy [18]. The decision that our rehabilitation protocol should involve both kinesitherapy and robotic therapy was based on the fact that the therapy with SG system was possible with voluntary movements only and did not involve assisted movements, which were indicated and administered in the therapy even before the use of robotics in our patient. In fact, we decided to try the approach with robotics when there had not been any functional motor improvement of the arm during five months' monitoring period and with occasional kinesitherapy.

Our selection of measurement indices involved spasticity, the functional motor status of the arm, and participation in the activities of daily living. Spasticity reduction supported various functional outcomes so that after four weeks of treatment spasticity score was reduced by a half, and the QUEST score increased by as much as 4.83%. Each evaluation testing showed a qualitative improvement of the arm as a whole, with the greatest QUEST subscore increase in the domain of grasping, as we expected to a degree.

The termination of the therapy was based on the recommendations by the Royal College of Pediatrics and Child Health (2017): Stroke in Childhood, when the girl lost interest for games involving SG and when the functional improvement of the arm status in the last period was only 1.45% [5]. The level of manual ability of the arm in daily living activities improved, as her parents stated, but remained at level 2 by the MACS classification.

It can be interesting to consider the paper by Frascarelli et al. [19], who reported in 2009 on clinical improvement of control and coordination after the use of robotics in children with movement disorders, but were unable to establish which of the training variables had the greatest impact on recovery. Ten years have passed from the publication of this paper, but we still do not have an answer to the dilemmas reported in the paper. Many important questions remain open, among which the key problems are the treatment protocol definition, the optimal duration of intensive training, and whether the use of robotics can shorten this period and improve the outcome. It has been established so far that the use of robotics cannot replace the usual individual exercise techniques in children, but it has been proven that it could contribute to functional recovery [11]. The role of VR-based rehabilitation remains to be confirmed in the future in further studies, which would hopefully provide higher levels of evidence. The result of our study suggests that combined robotic rehabilitation and kinesitherapy are able to improve the functional motor performance of the arm involved in the chronic recovery phase after a pediatric stroke.

Conflict of interest: None declared.

REFERENCES

1. Calgary Pediatric Stroke Program [Internet]. Calgary: Pediatric stroke – Definitions and terminology; c2019 [cited 2020 Nov 19]. Available from: https://ucalgary.ca/perinatalstroke/definitions_terminology
2. Tsz DS, Valente JH. Pediatric stroke: a review. *Emerg Med Int*. 2011;2011:734506.
3. Mallick AA, Ganesan V, Kirkham FJ, Fallon P, Hedderly T, McShane T, et al. Childhood arterial ischaemic stroke incidence, presenting features, and risk factors: a prospective population-based study. *Lancet Neurol*. 2014;13(1):35–43.
4. Krishnamurthi RV, deVeber G, Feigin VL, Barker-Collo S, Fullerton H, Mackay MT, et al. Stroke prevalence, mortality and disability-adjusted life years in children and youth aged 0–19 years: Data from the global and regional burden of stroke 2013. *Neuroepidemiology*. 2015;45(3):177–89.
5. Royal College of Paediatrics and Child Health [Internet]. London: Stroke in childhood - clinical guideline for diagnosis, management and rehabilitation; c2019 [cited 2019 Dec 11]. Available from: <https://www.rcpch.ac.uk/resources/stroke-childhood-clinical-guideline-diagnosis-management-rehabilitation>
6. Ferriero DM, Fullerton HJ, Bernard TJ, Billingham L, Daniels SR, DeBaun MR, et al. Management of Stroke in Neonates and Children: A Scientific Statement From the American Heart Association/ American Stroke Association. *Stroke*. 2019;50(3):e51–96.
7. Jeong JW, Lee J, Kamson DO, Chugani HT, Juhasz C. Detection of hand and leg motor tract injury using novel diffusion tensor MRI tractography in children with central motor dysfunction. *Magn Reson Imaging*. 2015;33(7):895–902.
8. Kim CT, Han J, Kim H. Pediatric stroke recovery: a descriptive analysis. *Arch Phys Med Rehabil*. 2009;90(4):657–62.
9. Hebert D, Lindsay MP, McIntyre A, Kirton A, Rumney PG, Bagg S, et al. Canadian stroke best practice recommendations: stroke rehabilitation practice guidelines, update 2015. *Int J Stroke*. 2016;11(4):459–84.
10. Mallick AA, O'Callaghan FJ. Risk factors and treatment outcomes of childhood stroke. *Expert Rev Neurother*. 2010;10(8):1331–46.
11. Mirkowski M, McIntyre A, Faltynek P, Sequeira N, Cassidy C, Teasell R. Nonpharmacological rehabilitation interventions for motor and cognitive outcomes following pediatric stroke: a systematic review. *Eur J Pediatr*. 2019;178(4):433–54.
12. Alhusaini AA, Dean CM, Crosbie J, Shepherd RB, Lewis J. Evaluation of spasticity in children with cerebral palsy using Ashworth and Tardieu scales compared with laboratory measures. *J Child Neurol*. 2010;25(10):1242–7.
13. Eliasson AC, Krumlind-Sundholm L, Rosbald B, Beckung E, Arner M, Ohrvall AM, et al. The Manual ability classification system (MACS) for children with cerebral palsy: scale development and evidence of validity and reliability. *Dev Med Child Neurol*. 2006;48(7):549–54.
14. DeMatteo C, Law M, Russell D, Pollock N, Rosenbaum P, Walter S. QUEST: Quality of Upper Extremity Skills Test [Internet]. Hamilton: McMaster University, Can Child Centre for Childhood Disability Research; 1992 [cited 2019 Dec 19]. Available from: https://slpemad.files.wordpress.com/2015/06/1992_quest_manual.pdf
15. Fredericks CM, Saladin LK, Fredericks C. Pathophysiology of the motor systems: principles and clinical presentations. 1st ed. Philadelphia: FA Davis; 1996.
16. Cooper AN, Anderson V, Greenham M, Hearn S, Hunt RW, Mackay MT, et al. Motor function daily living skills 5 years after paediatric arterial ischaemic stroke: a prospective longitudinal study. *Dev Med Child Neurol*. 2019;61(2):161–7.
17. Royal College of Physicians Intercollegiate Stroke Working Party [Internet]. London: National clinical guideline for stroke; c2020 [cited 2020 Jan 2]. Available from: <https://www.rcplondon.ac.uk/projects/stroke-programme>
18. Fasoli SE, Fragala-Pinkham M, Hughes R, Hogan N, Krebs HI, Stein J. Upper limb robotic therapy for children with hemiplegia. *Am J Phys Med Rehabil*. 2008;87(11):929–36.
19. Frascarelli F, Masia L, Di Rosa G, Cappa P, Petrarca M, Castelli E, et al. The impact of robotic rehabilitation in children with acquired or congenital movement disorders. *Eur J Phys Rehabil Med*. 2009;45(1):135–41.

Неурорехабилитација руке роботиком после можданог удара код деце

Христина Чоловић^{1,2,3}, Лидија Димитријевић^{1,2}, Вања Ђурић³, Соња Јанковић⁴

¹Универзитет у Нишу, Медицински факултет, Ниш, Србија;

²Клинички центар Ниш, Клиника за физикалну медицину и рехабилитацију, Ниш, Србија;

³Поликлиника *Neuromedic*, Ниш, Србија;

⁴Клинички центар Ниш, Центар за радиологију, Ниш, Србија

САЖЕТАК

Увод Педијатријски мождани удар спада у ретка стања са инциденцијом од 1,2–13/100.000. Најчешћа последица је хемипареза са оштећењем функције руке. Постоје докази нивоа 4 да роботика може побољшати функцију горњих екстремитета.

Циљ приказа је ефекат комбиноване примене роботичке рехабилитације и кинезитерапије на дистални део руке у хроничној фази хемипарезе у дечјем узрасту.

Приказ болесника Код девојчице старе 7,5 година, 18 месеци после педијатријског можданог удара примењен је рехабилитациони протокол дисталног дела руке: кинезитерапијски програм у трајању од 30 минута и роботска рехабилитација применом *Smart Glove* у трајању од 30 минута. Протокол је примењиван у трајању од 12 недеља, пет пута недељно. Резултати терапијске евалуације су показали да

је функционални моторички ниво руке остао непромењен, да је спастичитет према модификованој Ашвортовој скали флексора подлактице и прстију од почетне вредности 2 после четири недеље терапије износио 1+, а после осам и 12 недеља 1. Квалитативно побољшање функције руке кроз пораст укупне вредности Теста за процену спретности горњих екстремитета евидентирано је на сваком евалуацијском тестирању; највеће је било после прве четири недеље рехабилитације (4,83%).

Закључак Резултати нашег истраживања показали су да комбинована примена роботске неурорехабилитације уз кинезитерапију побољшава функционално моторички опоравак руке у хроничној фази после педијатријског можданог удара.

Кључне речи: мождани удар; деца; горњи екстремитет; роботика; рехабилитација