



CASE REPORT / ПРИКАЗ БОЛЕСНИКА

Larrey diaphragmatic hernia in an adult

Goran Stanojević¹, Milica Nestorović¹, Branko Branković¹, Aleksandar Bogdanović², Milan Radojković¹, Nebojša Ignjatović¹

¹University of Niš, Faculty of Medicine, Niš Clinical Center, Clinic for Digestive Surgery, Department of Surgery, Niš, Serbia;

²Niš Clinical Center, Clinic for Thoracic Surgery, Niš, Serbia

SUMMARY

Introduction Larrey hernia is a very rare type of the left sided parasternal congenital hernia with the incidence of 1–3% of all anterior diaphragmatic hernias.

Case report The paper describes Larrey congenital diaphragmatic hernia in an adult female patient, aged 70 years. Seventeen years earlier, the patient had had problems with intermittent left side chest pain, hypertension, dyspnea, shortness of breath, fatigue, and abdominal discomfort. She had no past surgical history, and no traumatic rupture of the diaphragm. An open surgical repair was conducted, reducing the herniated organs back into the abdominal cavity, and closing the diaphragmatic defect, repaired with a non-absorbable suture. During the immediate postoperative period, as well as six months later, the patient had a remarkable postoperative recovery.

Conclusion Larrey hernia represents an extremely rare kind of the anterior diaphragm hernias, which can be symptomatically manifested in older persons over 65 years of age. The treatment in the cases of asymptomatic and symptomatic Larrey hernias is a surgical intervention.

Keywords: Larrey hernia; Morgagni hernia; adult diaphragmatic hernia; open repair

INTRODUCTION

Larrey hernia represents an exceptionally rare type of left sided congenital diaphragmatic hernia, with an incidence of 2% of all anterior diaphragmatic hernias with intra-abdominal organ prolapse into the chest cavity, through the so-called “Hiatus Larrey” or the left sternocostal triangle. It usually symptomatically manifests later in life. In addition to the left-sided one, there is also a hernia called Morgagni right-sided anterior congenital hernia, which occurs more frequently, in 90% of the cases, and a hernia called Morgagni–Larrey hernia, which is bilateral, and the incidence of which is around 8% (Figure 1) [1, 2, 3].

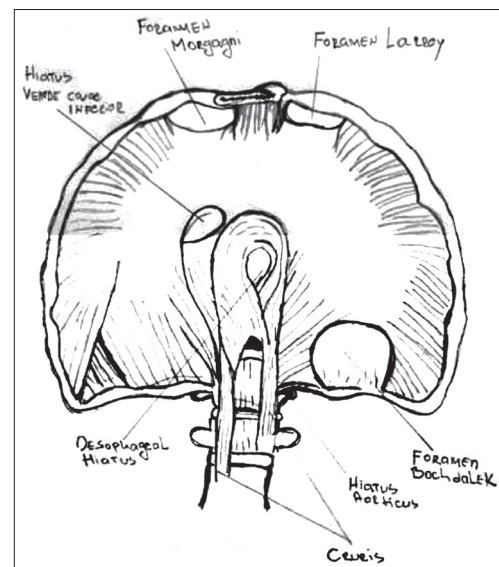


Figure 1. Anatomical locations of the common types of diaphragmatic hernia

CASE REPORT

We report a case of a 70-year-old woman, suffering from intermittent left-side chest pain, hypertension, dyspnea, shortness of breath, fatigue, and abdominal discomfort. She had had no past surgical history and no traumatic rupture of the diaphragm. The difficulties occurred 17 years earlier, in the form of intermittent heart palpitations and arrhythmia symptoms. During the previous six months, she had complained about vague thoracic and abdominal discomfort with mild dyspnea in exertion.

On admission, the woman was hemodynamically stable, and the laboratory analyses were within normal limits. She was examined at The Clinic for Digestive Surgery. Preoperative

computed tomography (CT) revealed a large segment of transversal colon herniating into the left hemithorax, causing a partial compression of the lung (Figure 2). The patient was operated on under general anesthesia, upper and midline laparotomy was done with a herniated omentum, and the transverse colon was reduced into the abdomen (Figures 3 and 4).

A 6 × 3 cm defect was identified just behind the xiphisternum, through which a part of the omentum and transverse colon herniated into the left hemithorax.

After confirming viability by inspection and palpation, the contents were reduced back into

Received • Примљено:
November 29, 2018

Revised • Ревизија:
September 20, 2019

Accepted • Прихваћено:
January 28, 2020

Online first: January 30, 2020

Correspondence to:

Goran STANOJEVIĆ
Niš Clinical Centre
Clinic for Digestive Surgery
Department of Surgery
Bul. Zorana Đinđića 48
18000 Niš
stgoran@medfak.ni.ac.rs;
stgoran1964@gmail.com

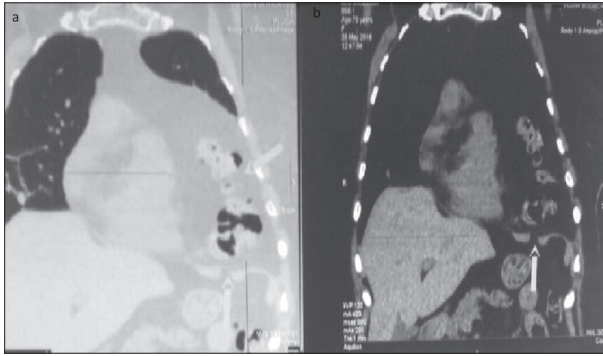


Figure 2. a) Preoperative sagittal computed tomography scan of the chest and abdomen with Larrey left side parasternal congenital diaphragmatic herniation of the abdominal contents into the thoracic cavity; b) preoperative sagittal computed tomography scan with the arrow showing anterior Larrey defect and anterior hernia

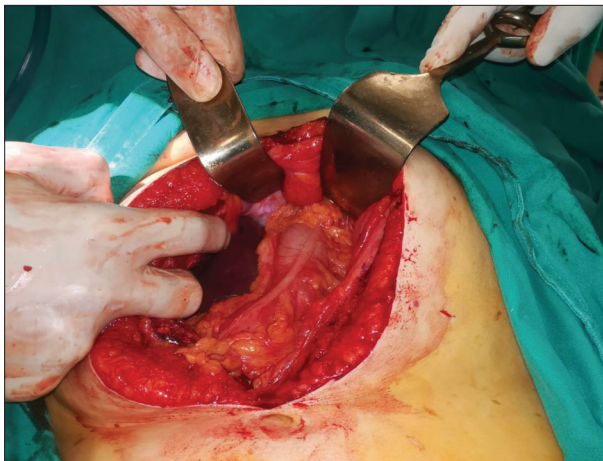


Figure 3. Intraoperative photograph showing diaphragmatic herniation of transverse colon and omentum through the hernial defect into the thorax

the abdomen. The diaphragmatic defect was repaired and the plication of the diaphragm was performed with an interrupted suture (Figure 5).

The postoperative course was uneventful, and the patient was discharged from hospital on the eighth postoperative day. Six months after the operation, during a control examination, the patient was feeling well and a remarkable reduction of symptoms was noticed. The control CT scan was normal (Figure 6).

This case report was approved by the institutional ethics committee, and written consent was obtained from the patient for the publication of this case report and any accompanying images.

DISCUSSION

Diaphragmatic hernia is a weakness of the diaphragmatic wall that allows the passage of the abdominal organs into the chest cavity. According to the cause of occurrence, it is mainly congenital, but in 7% of the cases it can also be acquired as a consequence of trauma with a rupture of the diaphragm. According to the place of origin, congenital hernias can be classified as Bochdalek hernia, located posterolaterally, and Morgagni–Larrey or Morgagni–Larrey

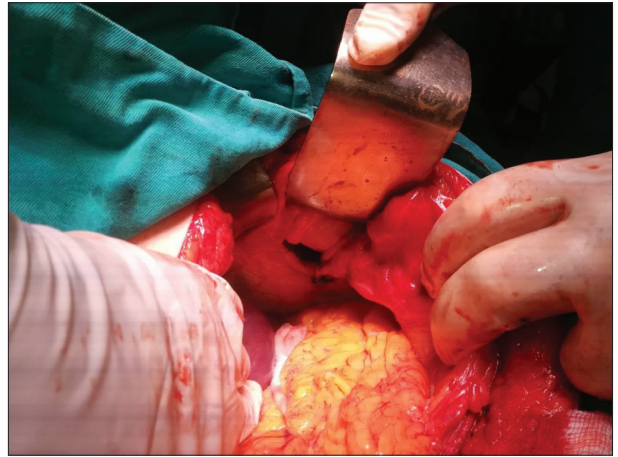


Figure 4. Intraoperative photograph showing the hernial defect on the left side of the retrosternal part of the diaphragm

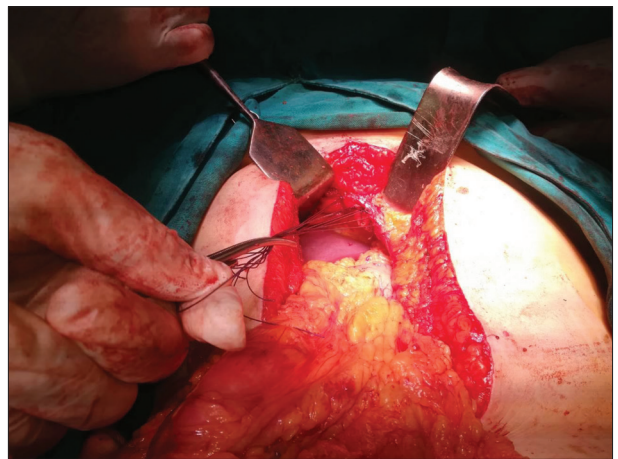


Figure 5. Primary closure of the retrosternal diaphragmatic defect using multiple interrupted sutures

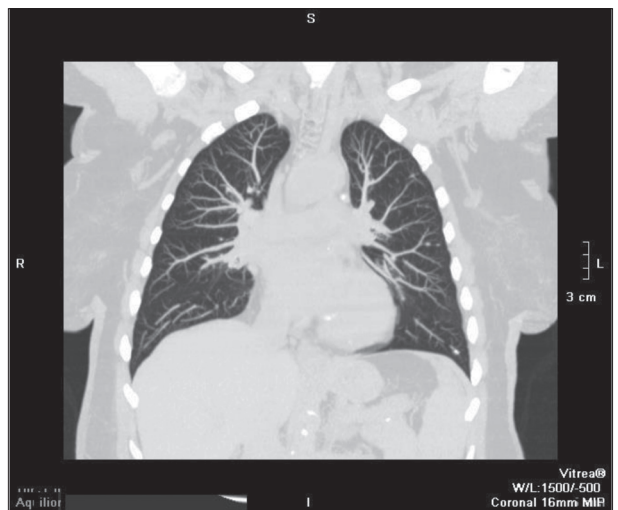


Figure 6. Six months after the operation control computed tomography scan was normal

anterolateral hernia, located parasternally, retro-chondrosterally, or in the retrocostoxyphoid region [4].

Larrey hernia represents an exceptionally rare type of congenital diaphragmatic hernia. It occurs as a consequence of a failure of fusion in the anterior portion of the

pleuroperitoneal membrane, resulting in the appearance of the left-sided defect in the retrosternal part of the diaphragm, called “Hiatus Larrey,” or the left-sided sternocostal triangle [1]. It was named after the surgeon of Napoleon Bonaparte, Dominique Jean Larrey (1766–1842), who first described it in 1829, while analyzing the alternative ways in the treatment of pericardial tamponade [4]. Alongside Larrey’s hernia, a more frequent congenital diaphragmatic hernia is the Morgagni’s one, localized on the right side, and named after the famous Italian anatomist and pathologist from Bologna, Giovanni Battista Morgagni. He described it in his study *De sedibus et causis morborum per anatomen indagatis* (*On the seats and causes of disease investigated by anatomy*) in 1761 [5]. In the case where hernia is present bilaterally, it is called Morgagni–Larrey [6].

The incidence of congenital hernias is 0.3–0.5/1,000 in newborns, while Bochdalek hernia occurs in 1/2,200 childbirths. In cases of the front, or anterolateral ones, it is 1/1,000,000 childbirths [7]. Depending on the existence of the hernia sac, it is possible to classify them into so-called “true” and “false” hernias. The “true hernias,” where hernia sacs are present, occur as a consequence of the disorder in the development of the diaphragm during the fetal period, when the closure of the pleuroperitoneal hiatus occurs, but the migration of the muscle is missing. In this case, the increased intra-abdominal pressure moves organs from the abdominal into the chest cavity, together with peritoneal evagination, which represents a hernia sac. The “false hernias” occur in the embryonic phase of development, when the closure of the pleuroperitoneal hiatus is missing, so the movement of intra-abdomen organs into the chest cavity is not followed by the peritoneum, with a subsequent lack of the hernia sac [4].

In general, the symptoms of anterolateral hernias occur during childhood, with respiratory symptomatology, while in only around 2–3% of the cases they manifest in adults, mainly around the age of 58 in the female population, and around the age of 50 in the male population [8].

In the review and analysis of 298 cases, Horton et al. [9] indicate that 28% of patients had no symptoms, while in 75% of the examinees there were some disturbances, such as pain and dyspnea. In the study by Abraham et al. [10], where the highest number of Larrey hernia cases were analyzed, 50% of the examinees were asymptomatic at presentation. The most common contents of hernia were stomach, transverse colon, omentum, and spleen. The conditions for the appearance of clinical disturbances are the increased intraabdominal pressure, pregnancy, obesity, chronic constipation, chronic obstructive lung disease, bronchial asthma, etc. [2, 10]. The clinical manifestation of Larrey hernia can also be developed as an acute condition in 25% of the cases. It occurs due to incarceration, i.e. volvulus of the abdominal cavity organs into the chest (stomach, transversal colon, omentum, small intestine, etc.), with gangrene formed and with perforation [6, 10]. The most common content of the anterolateral hernias is the omentum and the transversal colon, which was the case with our patient [11].

The diagnosis is set by a plain chest X-ray. However, the golden standard for diagnosing Larrey hernia is contrast CT. In cases where it is necessary to differentiate the

unclear pictures of mediastinal or parasternal masses, it is also possible to apply the magnetic resonance imaging of the chest and abdomen [12]. The treatment of Larrey hernias, asymptomatic and symptomatic, is essentially surgical, performed in a timely fashion to prevent complications, such as incarceration, obstruction, strangulation, or volvulus with gangrene of the bowel. There are two possible approaches: transabdominal and transthoracic. In the series of 298 patients, from the aforementioned study by Horton et al. [9], 49% of the patients were treated through thoracotomy, 30% through laparotomy, 17% laparoscopically, and 0.7% thoracoscopically. The transthoracic approach has an advantage in the expressed adhesions of the hernia and the hernia sac, with pericardial pleural and other mediastinal structures. It also refers to the patients who had a previous abdominal operation. The transabdominal approach presents an advantage in the cases where it is necessary to explore the opposite side of the diaphragm, due to the suspicion of the existence of Morgagni, or Morgagni–Larrey hernia, and to explore the remaining part of the abdominal cavity, owing to the suspicion of other associated diseases, particularly in cases of acute conditions with strangulation of the abdominal cavity organs [12, 13]. A combined approach should also be mentioned, which implies that the operation began with one approach (transabdominal or transthoracic), and then continued with another, in the conditions of non-reducible hernia, gangrene with perforation of the hollow viscus, etc. In addition to the so-called “open approach,” it is possible to make a minimally invasive, i.e. laparoscopic or thoracoscopic approach. The well-known advantages of the minimally invasive treatment, including the faster postoperative recovery, as well as the shorter hospitalization period and minimal scarring, urged an increased number of surgeons to treat the patients in this manner in the last several years [1, 14]. The robotic surgery, whether transabdominal or transthoracic, represents another technological progress with well-recognized advantages: ergonomics, preciseness of instruments, as well as easy operation in narrow spaces [15, 16]. With regard to the treatment with a small-diameter hernia opening (less than 16 cm²), it is possible to perform a primary suture, while in larger defects (larger than 20–30 cm²), the plastics of the diaphragm opening is induced with the help of various kinds of meshes, to avoid tension [14]. The data from the literature indicate that polypropylene meshes are mainly applied, but the possibility of using other types of meshes has not been excluded [17].

Larrey hernia represents an extremely rare kind of the anterior diaphragm hernias, which can symptomatically manifest in persons over the age of 65 years. This kind of hernia should be taken into account in older patients suffering from long-term respiratory problems, palpitations, fatigue, difficulties in discharging, swollen abdomen, and occasional pain. The plain chest X-ray and CT represent choices of diagnostic procedures that could discover the existence of the anterior left diaphragm hernia with high precision. The treatment of asymptomatic and symptomatic Larrey hernias is a surgical intervention.

Conflict of interest: None declared.

REFERENCES

- Rajkumar JS, Tadimari H, Akbar S, Rajkumar A, Kothari A, Vishnupriya VS, et al. Laparoscopic Repair of Larrey (Left-sided Morgagni) Hernia: Technical Consideration. *Indian Journal of Surgery*. 2018;80:395–8.
- Dapri G, Himpens J, Hainaux B, Roman A, Stevens E, Capelluto E, et al. Surgical technique and complications during laparoscopic repair of diaphragmatic hernias. *Hernia*. 2007;11(2):179–83.
- Ciancarella P, Fazzari F, Montano V, Guglielmo GP. A huge Morgagni hernia with compression of the right ventricle. *J Saudi Heart Assoc*. 2018;30(2):143–6.
- Aybar LAA, Gomez CCG, Garcia AJT. Morgagni-Larrey parasternal diaphragmatic hernia in the adult. *Rev Esp Enferm Dig*. 2009;101(5):357–66.
- McBride CA, Beasley SW. Morgagni's hernia: Believing is seeing. *ANZ J Surg*. 2008;78(9):739–44.
- Lanteri R, Santangelo M, Rapisarda C, Cataldo A, Licata A. Bilateral Morgagni-Larrey – A rare cause of intestinal obstruction Hernia. *Arch Surg*. 2004;139(12):1299–300.
- Taskin M, Zengin K, Unal E, Eren D, Korman U. Laparoscopic repair of congenital diaphragmatic hernias. *Surg Endosc*. 2002;16(5):869.
- Mittal A, Pardasani M, Baral S, Thakur S. A Rare case report of Morgagni Hernia with Organo-Axial Gastric Volvulus and concomitant Para-esophageal hernia, repaired laparoscopically in a Septuagenarian. *Int J Surg Case Rep*. 2018;45:45–50.
- Horton JD, Hofmann LJ, Hetz SP. Presentation and management of Morgagni hernias in adults: a review of 298 cases. *Surg Endosc*. 2008;22(6):1413–20.
- Abraham V, Myla Y, Verghase S, Chandran BS. Morgagni-Larrey Hernia – a Review of 20 cases. *Indian J Surg*. 2012;74(5):391–5.
- Arikan S, Dogan MB, Kocakusak A, Ersoz F, Sari S, Duzkoynu Y, et al. Morgagni's Hernia: Analysis of 21 Patients with Our Clinical Experience in Diagnosis and Treatment. *Indian J Surg*. 2018;80(3):239–44.
- Lee SY, Kwon JN, Kim YS, Kim KY. Strangulated Morgagni hernia in an adult: Synchronous prolapse of the liver and transverse colon. *Ulus Travma Acil Cerrahi Derg*. 2018;24(4):376–8.
- Patil T, Negi S, Thakur V. Hernia of Morgagni in the Elderly: A Case Report. *Cureus*. 2017;9(8):1–6.
- Yamamoto Y, Tanabe K, Hotta R, Fujikuni N, Adachi T, Misumi T, et al. Laparoscopic extra-abdominal suturing technique for the repair of Larrey's diaphragmatic hernia using the port closure needle (EndoClose®): A case report. *Int J Surg Case Rep*. 2016;28:34–7.
- Amore D, Bergaminelli C, Di Natale D, Casazza D, Scaramuzzi R, Curcio C. Morgagni hernia repair in adult obese patient by hybrid robotic thoracic surgery. *J Thorac Dis*. 2018;10(7):E555–9.
- Fu SS, Carton MM, Ghaderi I, Galvani CA. Robotic-Assisted Simultaneous Repair of Paraesophageal Hernia and Morgagni Hernia: Technical Report. *J Laparoendosc Adv Surg Tech A*. 2018;28(6):745–50.
- Shakya VC. Simultaneous laparoscopic management of Morgagni hernia and cholelithiasis: two case reports. *BMC Res Notes*. 2015;8:283.

Лареова дијафрагмална кила код одрасле особе

Горан Станојевић¹, Милица Несторовић¹, Бранко Бранковић¹, Александар Богдановић², Милан Радојковић¹, Небојша Игњатовић¹

¹Универзитет у Нишу, Медицински факултет, Клинички центар Ниш, Клиника за дигестивну хирургију, Катедра хирургије, Ниш, Србија;
²Клинички центар Ниш, Клиника за торакалну хирургију, Ниш, Србија

САЖЕТАК

Увод Лареова хернија је врло редак облик предње левостране парастерналне конгениталне киле са инциденцом 1–3% свих предњих дијафрагмалних кила.

Приказ болесника Приказан је случај појаве Лареове киле код женске особе старе 70 година. Седамнаест година имала је проблеме са повременим боловима у левој страни грудног коша, хипертензију, диспнеју, замор и нелагодност у трбуху. Болесница није пре тога оперисана нити је имала повреду дијафрагме. Оперисана је отвореним приступом, са враћањем органа из грудног коша у трбушну дупљу, са

затварањем дијафрагмалног отвора нересорптивним концем. Током непосредног постоперативног периода и шест месеци после њега болесница је имала уредан клинички ток. **Закључак** Лареова кила је изузетно ретка врста предње дијафрагмалне киле, која се симптоматски може манифестовати и код особа старијих од 65 година. Третман код асимптоматских и симптоматских Лареових кила је хируршка интервенција.

Кључне речи: Лареова кила; Моргањијева кила; дијафрагмална кила код одраслих; отворени приступ