



ORIGINAL ARTICLE / ОРИГИНАЛНИ РАД

Clinical characteristics and surgical treatment of dacryocystitis – a ten-year retrospective study

Miloš Trajković¹, Nikola Živković^{2,3}, Dragan Krasić^{1,2}, Andrija Ćosić¹, Vojkan Lazić¹, Miloš Stojanović¹, Ana Cvetanović^{2,4}, Staša Krasić⁵

¹Clinic of Dentistry, Niš, Serbia;

²University of Niš, Faculty of Medicine, Niš, Serbia;

³Niš Clinical Centre, Pathology and Pathological Anatomy Center, Niš, Serbia;

⁴Niš Clinical Centre, Oncology Clinic, Niš, Serbia;

⁵University of Belgrade, Faculty of Medicine, Belgrade, Serbia

SUMMARY

Introduction/Objective Nasolacrimal duct obstruction with consequent epiphora and the development of dacryocystitis (DC) represents a common pathological entity in the clinical practice of ophthalmologists and maxillofacial surgeons. The etiology of DC is multifactorial and still has not been clarified in detail. It is considered that ascending infections from the nasal cavity and paranasal sinuses, injuries and surgical interventions in the middle third of the face, dacryoliths, tumors of the lacrimal sac and surrounding structures may be some of the etiological factors of nasolacrimal duct obstruction.

The aim of this study is to present clinical characteristics and surgical treatment of DC.

Methods A retrospective study was carried out. It covered a period of 10 years during which 49 patients with clinically verified DC were treated after surgical examination and complete diagnostics. Out of the total number, 37 patients underwent surgery.

Results The occurrence of predisposing factors was present in 80% of the patients – rhinitis and the inflammation of paranasal sinuses in 27 patients (72%), injuries and surgical interventions in the middle third of the face in nine patients (24%), whereas lacrimal sac and nasolacrimal duct tumors were noted in three patients (8%). Surgical failure, which was manifested in terms of recurrent DC and epiphora, was noted in six cases (16%).

Conclusion Regarding the possible complications of inadequately administered antibiotic therapy and a broad spectrum of pathological entities which comprise the differential diagnosis, dacryocystorhinostomy with an adequate histopathological analysis and appropriate antibiotic therapy in the acute stage represents a right way for the treatment of DC.

Keywords: dacryocystitis; predisposing factors; differential diagnosis; surgical treatment

INTRODUCTION

Nasolacrimal duct obstruction (NLDO) with consequent epiphora and the development of dacryocystitis (DC) represents a common pathological entity in the clinical practice of ophthalmologists and maxillofacial surgeons [1].

The etiology of DC is multifactorial and still has not been clarified in detail. It is considered that ascending infections from the nasal cavity and paranasal sinuses, injuries and surgical interventions in the middle third of the face, dacryoliths, tumors of the lacrimal sac and surrounding structures may be some of the etiological factors of NLDO [2].

The acute dacryocystitis (ADC) is characterized by the appearance of hyperemia and a painful swelling in the medial canthus region, as opposed to the chronic form (CDC) which is characterized by a persistent painless swelling in the mentioned region with signs of mucopurulent exudation from the lacrimal punctum, epiphora, chronic conjunctivitis, and episodes of exacerbation of the chronic process.

The congenital form of DC is statistically the rarest form found in 5% of infants [3]. It is a very serious disease characterized by a high mortality rate if not treated adequately.

The initial treatment of ADC implies a systemic and local administration of antibiotics, incision, and drainage of the lacrimal sac content, which leads to decompression, evacuation of content and possible microbiological analyses. The absence of treatment of the acute stage may lead to complications such as preseptal and orbital cellulitis, meningitis, and cavernous sinus thrombosis.

The final treatment involves dacryocystorhinostomy (DCR), which can be external or endonasal. Both procedures, external dacryocystorhinostomy (ext-DCR), described by Addeo Toti in 1904, and endonasal dacryocystorhinostomy (endo-DCR), described by Caldwell in 1983, have undergone numerous modifications over time [4].

The aim of this study is to present clinical characteristics and surgical treatment of DC.

Received • Примљено:
October 12, 2018

Revised • Ревизија:
September 26, 2019

Accepted • Прихваћено:
October 16, 2019

Online first: October 17, 2019

Correspondence to:

Nikola ŽIVKOVIĆ
Pathology and Pathological
Anatomy Center
Niš Clinical Centre
48 Dr Zoran Đinđić Boulevard
18000 Niš, Serbia
nikola.zivkovic@medfak.ni.ac.rs

METHODS

A retrospective study was carried out. It covered a period from 2006 to 2015 during which 49 patients with clinically verified DC were treated after a surgical examination and complete diagnostics. Out of the total number, 37 patients underwent surgery.

All patients were surgically treated under general anesthesia at the Maxillofacial Surgery Clinic, Faculty of Medicine, University of Niš.

The analysis included the sex and age of patients, existence of chronic diseases, and occurrence of predisposing factors, i.e. existence of rhinitis, sinusitis, as well as injuries or surgical interventions in the middle third of the face. It also studied clinical characteristics of DC in terms of acute or chronic presentation of the process, localization, histopathology, microbiological analyses, recurrence, and postoperative complications of all patients, which involved epiphora, or recurrent DC. All patients underwent ext-DCR under general endotracheal anesthesia along with keeping a silicone tube for two months (Figures 1 and 2).

Classic ext-DCR with mono or bicanalicular silicone intubation, depending on the clinical manifestation of DC, was performed in all patients. The purpose of the

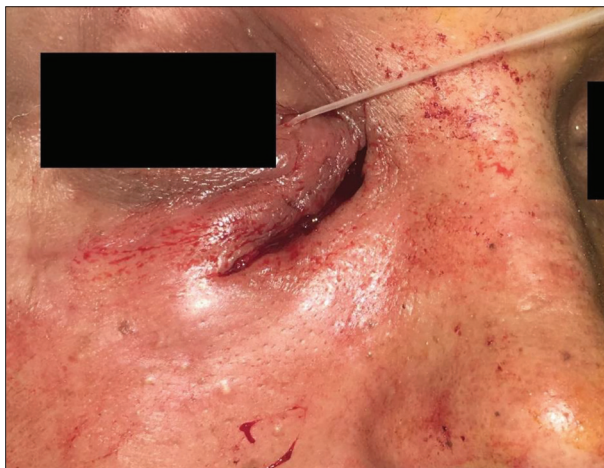

Figure 1. Condition after silicone single-channel tube placement; the photograph is used with the permission of the subject

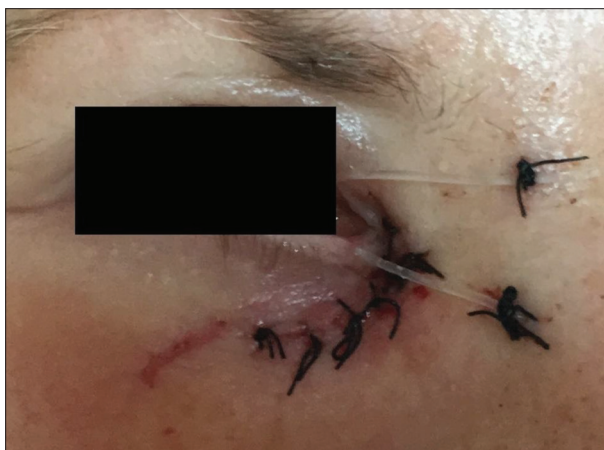

Figure 2. Condition after silicone double-channel tube placement; the photograph is used with the permission of the subject

above surgical procedures is based on the removal of the cystic sacs and the *de novo* formation of the nasolacrimal duct, which allows the normalization of the function of the lacrimal apparatus. The minimal period of postoperative monitoring was 18 months.

A multi slice computerized tomography was performed preoperatively in four patients with suspected lacrimal sac tumor in order to determine the extent of process and to plan further treatment.

This paper was approved by the institutional ethics committee, and written consent was obtained from the patients for the publication of this study and any accompanying images.

RESULTS

The mean age of the mentioned group of patients was 56, with the age interval ranging from 27 to 72. Considering sex, 28 patients (75%) were female, whereas nine patients included in the study (25%) were male.

The presence of chronic systemic diseases was determined in 30 patients (81%). Chronic arterial hypertension was present in 20 patients, diabetes mellitus in 10, chronic obstructive pulmonary disease in eight, glaucoma in five, and hyperthyroidism and rheumatoid arthritis in four patients.

The occurrence of predisposing factors was present in 80% of the patients (Table 1); 18 patients consulted a doctor in the acute stage of the disease. They were treated with broad-spectrum antibiotics (2nd or 3rd generation cephalosporins and clindamycin) until clinical and laboratory results indicated the regression of the signs of infection. Incisions in the sac region were made in 10 cases. The ADC was more frequent in younger patients.

Table 1. The occurrence of predisposing factors

Predisposing factors	Patients (n, %)
Rhinitis and the inflammation of paranasal sinuses	27 (72%)
Injuries and surgical interventions in the middle third of the face	9 (24%)
Lacrimal sac and nasolacrimal duct tumors	3 (8%)

Initially, a chronic process was present in 31 patients. The congenital form of DC was not included in the study.

DC was more common on the left than on the right side (Figure 3).

Microbiological analyses indicated dominant presence of gram-positive flora. *Staphylococcus aureus*, staphylococcal pneumonia, and *Staphylococcus epidermidis* were isolated in 85% of cases; equally present both in the acute and chronic process. Methicillin-resistant *Staphylococcus aureus* (MRSA) was isolated in two cases. Gram-negative bacteria, *Haemophilus influenzae*, *Pseudomonas aeruginosa*, *Neisseria* and *Klebsiella* were isolated in 10 patients, exclusively in ADC. Three microbiological findings of CDC were negative.

Surgical failure, which was manifested in terms of recurrent DC and epiphora, was noted in six cases (16%).

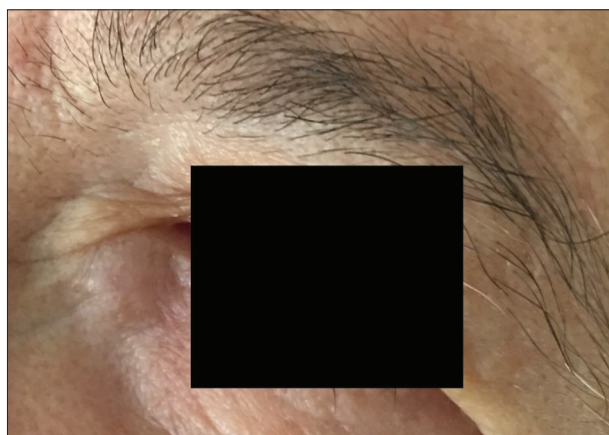

Figure 3. Chronic form of dacryocystitis; the photograph is used with the permission of the subject

In three patients after DCR, a recurrence of the disease appeared on average four weeks after the surgery. Initially, the patients in question were diagnosed with ADC, which was treated with broad-spectrum antibiotics and incisions. Given that microbiological findings indicated the presence of gram-negative bacteria, no recurrences were noted after the administration of therapy based on the antibiogram.

In two cases, the anamnesis showed the existence of long-standing episodes of CDC treated out-patiently at another medical institution. After DCR had been performed, a recurrence of the underlying disease appeared two weeks after the stitches removal. Considering that microbiological analyses indicated the existence of MRSA, the patients were treated with intensive antibiotic therapy with vancomycin, after which the signs of infection diminished. Reinterventions were carried out after the regression of infection, after which no recurrences were noted.

In one case, recurrences appeared two weeks after the accidental loss of a silicone tube. No recurrences were noted after the reintervention and placing a new silicone tube.

Histopathological (HP) analyses after DCR indicated that chronic nongranulomatous inflammation was reported in 34 cases (91%) (Figure 4), the presence of papilloma in two cases, whereas lacrimal sac adenocarcinoma was reported in one case.

DISCUSSION

DC is the inflammation of the lacrimal sac clinically presented in the ADC and CDC. The process is more frequent in females above the age of 40, contrary to the congenital form, which is equally present in both sexes and represents 1% of the total number of all types of DC [5]. A more frequent occurrence of DC in females than in males is explained by a smaller diameter of the nasolacrimal duct and therefore bigger chances for the appearance of a pathway and consequent infection. The ADC is more common in the young. Similar results were presented in the study by Eshaghiet et al [6].

Greater incidence of DC on the left compared to the right side is a consequence of a sharper angle between the

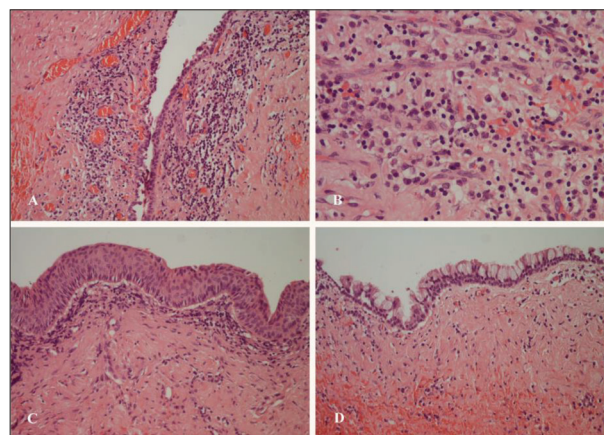


Figure 4. Pathohistological image of chronic dacryocystitis; the epithelium is usually cubical, with two layers (A) (H&E, $\times 10$); the submucosa contains a large number of blood vessels (neovascularization), as well as a thick, chronic inflammation infiltrate (lymphocytes, plasmocytes, histocytes) (B) (H&E, $\times 40$); the epithelium can show squamous metaplasia (C) and goblet cell hyperplasia foci (D) (H&E, $\times 20$)

lacrimal sac and the nasolacrimal duct, therefore creating a greater possibility for the disruption of drainage, pathway, and a consequent infection, which is in correlation with the results of the study [7].

Ext-DCR, which uses transcutaneous access to enable exquisite visibility of the operative field, more control over intraoperative complications, and a shorter surgical course, is a surgical method of choice in treating DC. The success of the mentioned technique ranges from 80% to 96%, which is also in correlation with the results of our study [8].

In all cases, a silicone tube was placed despite the research conducted by Feng et al. [9] who concluded that success of the initial ext-DCR both with and without placing a silicone tube was identical.

The process of endo-DCR, which statistically shows identical success as the aforementioned procedure, has never been carried out in our institution due to the lack of technical possibilities [10].

Microbiological analyses indicated the presence of combined bacterial flora, i.e. the presence of both gram-positive and gram-negative bacteria.

A study, which included microbiological findings from 84 ADC and CDC, reported that *Staphylococcus aureus* was the most common gram-positive bacteria present in 28.8% of cases, equally present both in acute and chronic processes [11]. The existence of MRSA, which has been statistically increasing since 1998, is related to frequent episodes of exacerbation of the chronic form of the disease and the appearance of recurrences after DCR [12]. Gram-negative bacteria are in most cases associated with the ADC, foudroyant clinical course, and frequent recurrences, with *Haemophilus influenzae*, *Pseudomonas aeruginosa*, *Neisseria*, *Klebsiella*, and *Escherichia coli* being the most common ones [13].

In a study which retrospectively encompassed 377 HP findings after performed DCR, Anderson et al. [14] reported a dominant presence of chronic nongranulomatous

inflammation (321, 85.1%), granulomatous inflammation including sarcoidosis (eight, 2.1%), lymphoma (seven, 1.9%) and a total of five malignant tumors. The authors of the study stressed that the clinical course of the mentioned malignancies completely corresponded to the clinical image of CDC and suggested an obligatory HP analysis after each DCR. The dominant presence of chronic inflammation (85.1%) marked rhinitis and inflammation of paranasal cavities as possible etiological factors of DC. The results of the aforementioned study are in correlation with our results.

A study by Lefebvre et al. [15], which included 49 patients with performed DCR, reported surgical failure in seven cases (13%). Surgical failure occurred in patients with MRSA, gram-negative bacteria, rhinosinusitis, lymphoma, early loss of a silicone tube and Crohn's disease. In our study, the reasons of DCR failure were associated with MRSA infection in two cases, gram-negative bacteria infection in two cases, and an accidental loss of a silicone tube in one case. The occurrence of surgical failure associated with MRSA and gram-negative bacteria is also emphasized in studies by other authors [16].

The available literature suggests that the recommended silicone tube retaining time is at least two months after

DCR [17]. Accidental loss or early removal is associated with the appearance of NLDO. In our study, all patients had the tube removed after two months, except for one patient, i.e. a case of accidental loss. In a study, which included 25 patients with evidently high risk of postoperative failure after DCR, Sodhi PK et al. [18] suggested the removal of a silicone tube to be six months after surgery.

CONCLUSION

DC is a common pathological entity in everyday clinical practice, more frequent in women above the age of 40.

Given the possible complications, inadequately administered antibiotic therapy and a broad spectrum of pathological entities, which comprise the differential diagnosis, DCR with an adequate HP analysis and appropriate antibiotic therapy in the acute stage represents a right way for the treatment of DC.

The success of the mentioned procedure, which statistically varies from 80% to 90%, confirms our choice of therapy in the treatment of DC.

Conflict of interest: None declared.

REFERENCES

- Harish V, Benger RS. Origins of lacrimal surgery, and evolution of dacryocystorhinostomy to the present. *Clin Exp Ophthalmol*. 2014;42(3):284–7.
- Wladis EJ, Shinder R, Le Febvre D, Sokol J, Boyce M. Clinical and microbiologic features of dacryocystitis-related orbital cellulitis. *Orbit*. 2016;35(5):258–61.
- Goel R, Nagpal S, Kumar S, Meher R, Kamal S, Garg S, et al. Transcanalicular laser-assisted dacryocystorhinostomy with endonasal augmentation in primary nasolacrimal duct obstruction: our experience. *Ophthalmic Plast Reconstr Surg*. 2017;33(6):408–12.
- Anijeet D, Dolan L, Macewen CJ. Endonasal versus external dacryocystorhinostomy for nasolacrimal duct obstruction. *Cochrane Database Syst Rev*. 2011;1:CD007097.
- Li EY, Wong ES, Wong AC, Yuen HK. Primary vs Secondary Endoscopic Dacryocystorhinostomy for Acute Dacryocystitis With Lacrimal Sac Abscess Formation: A Randomized Clinical Trial. *JAMA Ophthalmol*. 2017;135(12):1361–6.
- Eshraghi B, Abdi P, Akbari M, Fard MA. Microbiologic spectrum of acute and chronic dacryocystitis. *Int J Ophthalmol*. 2014;7(5):864–7.
- Feijó ED, Caixeta JA, de Souza Nery AC, Limongi RM, Matayoshi S. A comparative study of modified transcanalicular diode laser dacryocystorhinostomy versus conventional transcanalicular diode laser dacryocystorhinostomy. *Eur Arch Otorhinolaryngol*. 2017;274(8):3129–34.
- Pandya VB, Lee S, Benger R, Danks JJ, Kourt G, Martin PA, et al. External dacryocystorhinostomy: assessing factors that influence outcome. *Orbit*. 2010;29(5):291–7.
- Feng YF, Cai JQ, Zhang JY, Han XH. A meta-analysis of primary dacryocystorhinostomy with and without silicone intubation. *Can J Ophthalmol*. 2011;46(6):521–7.
- Ozsutcu M, Balci O, Tanriverdi C, Demirci G. Efficacy of adjunctive mitomycin C in transcanalicular diode laser dacryocystorhinostomy. *Eur Arch Otorhinolaryngol*. 2017;274(2):873–7.
- Prakash R, GirishBabu RJ, Nagaraj ER, Prashanth HV, Jayashree SS. A Bacteriological study of dacryocystitis. *JCDR*. 2012;6(4):652–5.
- Wong ES, Chow CW, Luk WK, Fung KS, Li KK. A 10-Year Review of Ocular Methicillin-Resistant Staphylococcus aureus Infections: Epidemiology, Clinical Features, and Treatment. *Cornea*. 2017;36(1):92–7.
- Pfeiffer M, Hacopian A, Merritt H, Phillips M, Richani K. Complete vision loss following orbital cellulitis secondary to acute dacryocystitis. *Case Rep Ophthalmol Med*. 2016:9630698.
- Anderson NG, Wojno TH, Grossniklaus HE. Clinicopathologic findings from lacrimal sac biopsy specimens obtained during dacryocystorhinostomy. *Ophthalm Plast Reconstr Surg*. 2003;19(3):173–6.
- Lefebvre DR, Dhar S, Lee I, Allard F, Freitag SK. External dacryocystorhinostomy outcomes in patients with a history of dacryocystitis. *Digit J Ophthalmol*. 2015;21(3):1–22.
- Pandit VK, Jehan M, Pathak N. To analyse the success rate of external dacryocystorhinostomy related with anatomical osteotomy size made during surgery. *Int J Appl Res*. 2018;4:354–8.
- Eshraghi B, Hashemian H, Fard MA, Safizadeh M. Lacrimal sac empyema incision and drainage followed by early external dacryocystorhinostomy. *Orbit*. 2013;32(5):278–80.
- Sodhi PK, Pandey RM, Malik KP. Experience with bicanalicular intubation of the lacrimal drainage apparatus combined with conventional external dacryocystorhinostomy. *J Craniomaxillofac Surg*. 2003;31(3):187–90.

Клиничке карактеристике и хируршки третман дакриоциститиса – десетогодишња ретроспективна студија

Милош Трајковић¹, Никола Живковић^{2,3}, Драган Красић^{1,2}, Андрија Ћосић¹, Војкан Лазић¹, Милош Стојановић¹, Ана Цветановић^{2,4}, Сташа Красић⁵

¹Клиника за стоматологију, Ниш, Србија;

²Универзитет у Нишу, Медицински факултет, Ниш, Србија;

³Клинички центар Ниш, Центар за патологију и патолошку анатомију, Ниш, Србија;

⁴Клинички центар Ниш, Клиника за онкологију, Ниш, Србија;

⁵Универзитет у Београду, Медицински факултет, Београд, Србија

САЖЕТАК

Увод/Циљ Опструкција дренаже назолакрималног канала са последичном епифором и развојем дакриоциститиса представља учестали патолошки ентитет у клиничкој пракси офталмолога и максилофацијалних хирурга. Етиологија дакриоциститиса је мултифакторијална и још увек није разјашњена до детаља. Сматра се да асцендентно ширење инфекције из носног кавитета и параназалних синуса, повреде и хируршке интервенције у пределу средње трећине лица, дакриолити, тумори лакрималног сакуса и околних структура могу бити неки од етиолошких фактора опструкције дренаже назолакрималног канала.

Циљ ове студије је приказивање клиничких карактеристика и хируршког лечења дакриоциститиса.

Методe Обављена студија је ретроспективна. Обухватила је период од 10 година, у којем је после хируршког прегледа и комплетне дијагностике лечено 49 болесника са клинички евидентним дакриоциститисом, од којих је оперисано њих 37.

Резултати Појава предиспонирајућих фактора се среће код 80% болесника – присуство ринитиса и запаљења параназалних синуса код 27 болесника (72%), повреде и хируршке интервенције у пределу средње трећине лица код девет болесника (24%), док је појава тумора лакрималног сакуса и назолакрималног дуктуса уочена код три болесника (8%). Оперативни неуспех који се манифестовао појавом рекурентног дакриоциститиса и епифоре уочен је код шест (16%) случајева.

Закључак С обзиром на могуће компликације неадекватно ординираних антибиотске терапије и широк спектар патолошких ентитета који чине диференцијалну дијагнозу, дакриоцисториностомија уз адекватну хистопатолошку анализу и одговарајућу антибиотску терапију у акутној фази представља сигуран начин за терапију дакриоциститиса.

Кључне речи: дакриоциститис; предиспонирајући фактори; диференцијална дијагноза; хируршко лечење