



REVIEW ARTICLE / ПРЕГЛЕД ЛИТЕРАТУРЕ

Myoma pseudocapsule – a biological and surgical structure to respect during myomectomy

Andrea Tinelli^{1,2,3}, Radmila Sparić^{4,5}

¹Veris delli Ponti Hospital, Department of Obstetrics and Gynecology, Scorrano, Italy;

²Vito Fazzi Hospital, Division of Experimental Endoscopic Surgery, Imaging, Technology and Minimally Invasive Therapy, Department of Obstetrics and Gynecology, Lecce, Italy;

³Moscow Institute of Physics and Technology (State University), Faculty of Biological and Medical Physics, Phystech BioMed School, Laboratory of Human Physiology, Dolgoprudny, Moscow Region, Russia;

⁴Clinical Centre of Serbia, Clinic for Gynecology and Obstetrics, Belgrade, Serbia;

⁵University of Belgrade, Faculty of Medicine, Belgrade, Serbia

SUMMARY

Uterine fibroids affect almost one in two patients, causing many pelvic problems and requiring pharmacologic and surgical treatment. For many years, the importance of the fibroid was emphasized as uterine pathology, without focusing on the complex myometrial biology peripheral to fibroid. Moreover, the traditional surgical technique in fibroid removal has not been investigated for years. In recent years, on the contrary, morphological, neuroendocrine and anatomical studies have demonstrated the importance of a biological and surgical structure surrounding myoma, rich in neurotransmitters and neurofibres, the myoma pseudocapsule. This structure is formed in the womb peripheral to fibroid onset, it separates the fibroid from the myometrium and acts as a tissue regenerator after the removal of the fibroid from the uterus. The translation of scientific research on pseudocapsules into surgical practice has allowed us to identify new techniques of myomectomy, removing the myoma inside the pseudocapsule and promoting the pseudocapsules sparing surgery. All this to favor the subsequent biological process of uterine scarring and healing, by activating the neurotransmitters and neurofibres present in the myometrial fovea. The correct healing after fibroid removal restores the uterine anatomy, with a positive impact on subsequent reproductive function, reducing problems related to the muscle scar.

Keywords: myoma pseudocapsule; myomectomy; neurovascular bundle; reproductive surgery; pregnancy; fertility

INTRODUCTION

Uterine myomas, leiomyomas, or fibroids are the most common pathology in female genital organs; most of them are asymptomatic, but they can also cause severe symptoms [1]. The prevalence of uterine fibroids ranges 5.4–77% [2]. Fibroids negatively affect female reproductive function, as they are recognized as an important cause of infertility. Moreover, women affected by fibroids are at a higher risk for complications during pregnancy, labor, and delivery [3]. Fibroids are preferentially treated by surgery, by vaginal, laparoscopic, laparotomic, or hysteroscopic approach [4, 5, 6].

Currently, minimally invasive techniques based on biologically reasoned myomectomy allow the preservation of the myoma pseudocapsule, in order to spare the muscular and fibro-neurovascular myometrial fibers, ensuring the complete and bloodless removal of the myoma [7, 8].

PHYSIOLOGY OF UTERINE MUSCLE REPAIR

Myometrial scar after myomectomy requires a correct and physiological healing. The healing

process, once the fibroid is enucleated, is one of the fundamental steps that restores the uterine reproductive function. Nevertheless, the muscle damage itself may promote the signaling activities to trigger regeneration of the myometrium. The synthesis and release of signaling molecules, initiated by neurotransmitters and neurofibres, after the cellular damage, can prompt itself the cell activation, inducing muscle regeneration and healing [9]. After the muscle damage, the biological “injury–repair–regeneration” sequence leads to complete functional recovery during the days or weeks after the initial injury [10].

The fundamental process in the regeneration of a damaged muscle is the revascularization of the injured muscular tissue. The neoangiogenic network in the myometrial fovea (where the fibroid was located) is the first sign of tissue repair, as a necessity for the later morphological and functional healing. New capillaries grow from the surviving stems of the blood vessels into the center of the myometrial fovea; the neoangiogenesis in the damaged myometrium provides a sufficient supply of oxygen, improving aerobic energy metabolism for the muscular tissue repair [11]. In such a regenerative process, the neuropeptides and neurotransmitters have a significant role in wound healing.

Received • Примљено:

July 20, 2019

Revised • Ревизија:

December 27 2019

Accepted • Прихваћено:

February 11, 2020

Online first: February 22, 2020

Correspondence to:

Andrea TINELLI

Division of Experimental Endoscopic Surgery, Imaging, Technology and Minimally Invasive Therapy

Department of Obstetrics and Gynecology

Vito Fazzi Hospital

Lecce 73100, Italy

andreatinelli@gmail.com

Moreover, there is evidence that the nervous system and its neurotransmitters, such as neuropeptide Y (NPY), substance P (SP), vasoactive intestinal peptide (VIP), oxytocin, vasopressin (VP), growth-hormone-releasing hormone (GHRH), protein gene product 9.5 (PGP 9.5) and calcitonin gene-related peptide (CGRP) play a crucial role in mediating inflammation and healing processes [9, 12, 13]. Among these neurotransmitters, a slight distribution of oxytocin neurofibres into the uterus has been demonstrated, with their high presence into the cervico-isthmic area [14].

Analyzing the biology of the myometrial scar after myomectomy, the spared neuropeptides enhance the correct myometrial healing at the hysterotomic site, and most of the abovementioned neuropeptides have been found in the fibroid pseudocapsule, as a neurovascular bundle surrounding the fibroid [14–17]. To date, it has not been clarified if the pseudocapsule vasculature network could be sustained by mechanical and inflammatory effects of the fibroid on myometrium, or produced by a sort of “neoplastic-type” neoangiogenesis, due to the myoma growth or even to a muscle and tissue healing process [18].

In the human uterus, obstacles in attaining serial specimens of hysterotomic scar after myomectomy are the main problems of biological and surgical investigations. Thus, the post-cesarean section and post-myomectomy remodeling processes in the womb are currently an unsolved puzzle. They can be monitored only by ultrasound or magnetic resonance imaging [19].

Healing of the wound is a vibrant process which involves neuromediators, neuropeptides, angiogenic factors, blood cells, extracellular matrix, and parenchymal cells. It follows three composite and coinciding phases: inflammation, tissue formation, and remodeling [20]. In these phases, the intra-pseudocapsule growth factors can be very useful in enhancing the muscle repair process after myomectomy [21].

Nonetheless, the biogenesis of a myoma pseudocapsule requires further investigations, either on the analysis of the hormonal and pharmacological effects of drugs on the pseudocapsule, based on reducing fibroid growth without compromising pseudocapsule characteristics, or on the pre-operative therapy and the post-operative follow up, in order to preserve womb functionality, as much as possible [22, 23].

THE “INTRACAPSULAR MYOMECTOMY”

The rationale for the fibroid removal starts with the preservation of its pseudocapsule (Figure 1), the neurovascular bundle which surrounds the myoma itself [15, 16, 17]. This modern technique of removing fibroids was adapted from urology, in which the removal of the prostate gland must occur with the conservation of the neurovascular bundle above it. Thus, concerning the significance of the prostatic capsule-sparing and the physiological role of nerve-sparing techniques for prostatectomy, it was possible to translate it on the pseudocapsule-sparing during myomectomy.

There are also some passages that can be borrowed from urology to gynecology during prostatectomy and

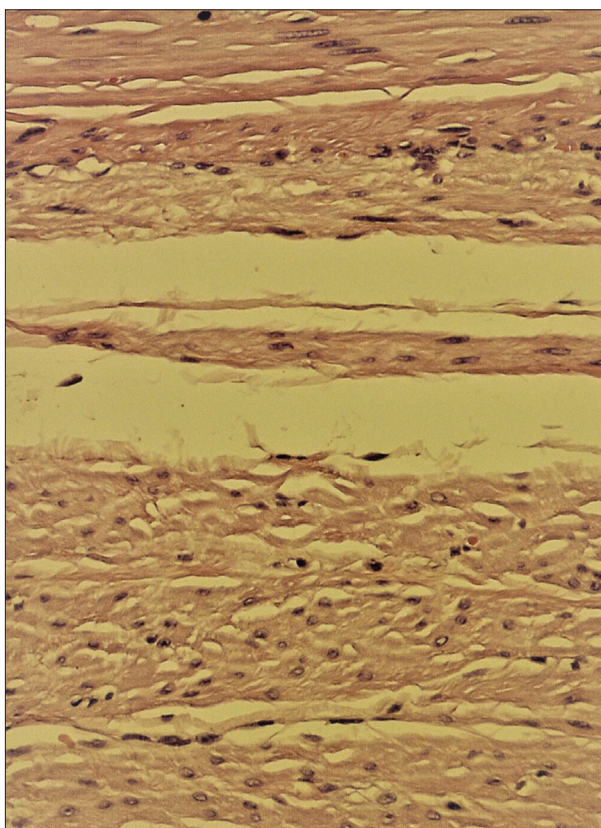


Figure 1. Histology of the myoma pseudocapsule

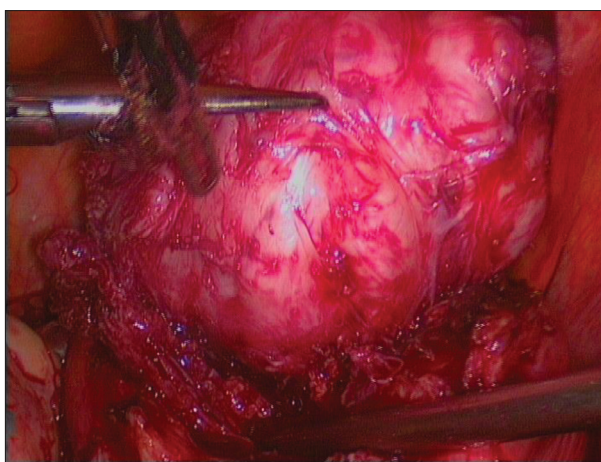


Figure 2. Laparoscopic intracapsular myomectomy

myomectomy. During laparoscopic/robotic prostatectomy, if bleeding occurs, meanwhile, insufflation pressure can be increased and local compression can also be performed by a hemostatic gauze, directly on the prostate neurovascular bundle (the source of bleeding). The same surgical passages can be repeated during laparoscopic myomectomy (Figure 2), in case of bleeding. Then, the hemostasis by high-wattage diathermocoagulation should always be avoided during dissection near the prostate neurovascular bundles, as it has been shown that it can be harmful to the cavernous nerve function in the canine model, with indirect damage to the pelvic nerves of sexual function after prostatectomy [18, 24].

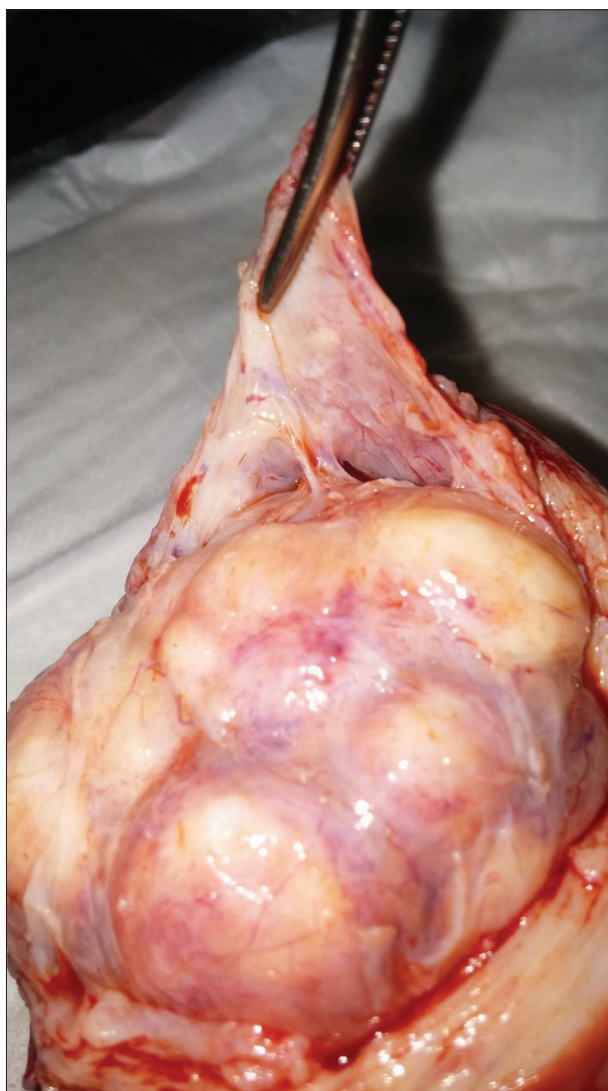

Figure 3. Macroscopic exposition of the pseudocapsule

Returning to the fibroid enucleation technique, the possibility to perform myomectomy by removing the myoma from its pseudocapsule was called “intracapsular myomectomy” [16, 18, 19]. In this technique, the fibroid is taken out, by surgeon, from its muscular fovea, by stretching and enucleating the myoma directly from the adjacent myometrium, avoiding the damage to the adjacent fibromuscular skeleton, breaking up the fibrous bridges (Figure 3) [4, 6, 25, 26]. As a general surgical recommendation, in robotic, laparoscopic, laparotomic, vaginal, or hysteroscopic setting, the surgical enucleation of each fibroid always needs to be gently performed in order to enhance and improve the successive myometrial healing, trying to correctly restore the uterine anatomy and biology [27, 28]. Thus, the myoma pseudocapsule neurovascular bundle needs to be preserved and spared during myomectomy, avoiding any damaging surgical maneuvers, such as extensive and high-wattage diathermocoagulation or unnecessary tissue manipulation or muscular injury. This physiological surgical technique to remove fibroids largely respects the fibroid neurovascular bundle, and its neuropeptides and neurofibers, since the iatrogenic pseudocapsule damage

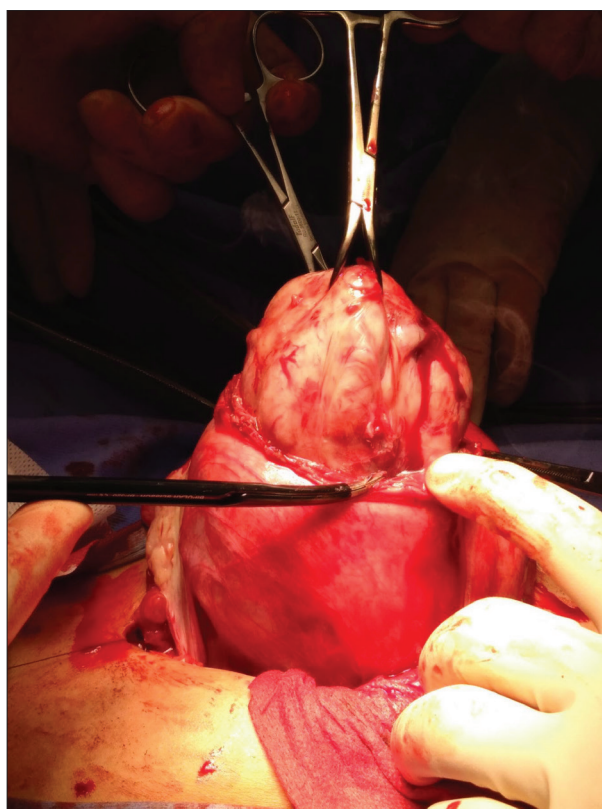


Figure 4. Laparotomic intracapsular myomectomy

may change the successive neurotransmitters' function in muscle repair, thus impairing uterine healing [8, 18].

The operative consequences of an inappropriate myomectomy technique performed with pseudocapsule injury may lead to the following: 1) a reduction in the number of neuropeptides and neurofibers at the hysterotomy site, with a negative impact on physiological myometrial healing; 2) an increase of the fibrotic process at the hysterotomy site; and 3) insufficiency of either myometrial neurotransmission or of muscular impulse and contractility. All of these features can lead to an altered post-surgical uterine physiology, as well as to a reduced uterine musculature functionality. This process could be the main one responsible for impaired healing with uncorrected myometrial functionality, with unfavorable effects on a subsequent pregnancy, including a possible dramatic uterine rupture [29, 30].

LAPAROTOMIC/LAPAROSCOPIC INTRACAPSULAR MYOMECTOMY

The laparotomic and laparoscopic intracapsular myomectomy techniques do not differ substantially, except for the major surgical benefit of laparoscopy in case of subserous and intramural fibroids. The principal benefits of the endoscopic approach are significant reduction of perioperative operative blood loss, lower dosage requirements for analgesic drugs, and shorter hospitalization. Additionally, laparoscopic intracapsular myomectomy results in slightly enhanced short-term outcomes in terms of postoperative fever, myometrium scar hematoma formation, ileus and

antibiotic treatment, in comparison to laparotomic surgery (Figure 4). Laparoscopic myomectomy has reduced blood loss for the hemostatic CO₂ pressure, a part of selective gentle coagulation of the pseudocapsule vessels. The CO₂ insufflation can reduce blood loss during laparoscopy, as increased intra-peritoneal pressure can lead to the occlusion of small blood vessels and capillaries during myomectomy [30]. This effect, combined with fewer traumatic endoscopic micro-manipulations, could result in overall positive surgical results [2, 7, 25].

Once the visceral peritoneum is incised at the midline longitudinal plane, by monopolar scissors, by the harmonic scalpel, monopolar scissors, or crochet needle electrode, the myoma pseudocapsule is easily recognized during dissection and then cut to expose the fibroid surface. The identification of the “cleavage plane” between the fibroid and the pseudocapsule is important for correct intracapsular myomectomy, in order not to preserve muscular fibers and to selectively coagulate blood vessels of the pseudocapsule. Atraumatic clamp or irrigator cannula should be used to gently dissect the myoma from its pseudocapsule. Hemostasis of the small vessels bleeding can be selectively achieved by low-wattage bipolar clamps, a harmonic scalpel, hook electrode, or monopolar scissors, always at low wattage (not more than 30 watts), to progressively expose the hidden part of the fibroid into the uterus (the myometrial fovea), incorrectly called “the base of the myoma”, and the pseudocapsule fibrovascular bridges (selectively coagulated). This technique allows for a complete minimally traumatic removal of the fibroid from its pseudocapsule, with minimal blood loss and pseudocapsule sparing.

HYSTEROSCOPIC INTRACAPSULAR MYOMECTOMY

The development of hysteroscopic myomectomy in 1976 represented a revolution in the treatment of submucous fibroids, replacing the laparotomic approach, significantly improving patients’ surgical outcomes [31]. Nowadays, the hysteroscopic myomectomy represents the gold standard in the treatment of submucous myomas [32]. Nevertheless, the submucous myomas’ treatment is probably a hysteroscopic procedure that carries greater risk than others, due to the potential for complications it has, such as cervix laceration, hemorrhage, uterine perforation, or clinical intravasation syndrome [33, 34]. It is not easy to estimate the right frequency of the abovementioned complications as it is of high variability according to pathology characteristics, surgeon skills, and employed technique [35].

Wamsteker et al. [36] and Lasmar et al. [37] investigated and assessed the characteristics of submucous fibroids able to influence surgical outcomes in hysteroscopic myomectomy. The treatment of intracavitary fibroids with an intramural extension of 50% or more has always been represented as a challenge for hysteroscopic surgeons, as it is burdened with an increased risk for intraoperative complications, sometimes requiring a multiple-step procedure [5, 36, 38]. Moreover, in cases of multiple myomas, the risk is even higher.

Currently, resectoscopic slicing is still the most commonly used technique for treating submucous myomas, and probably for this reason myomectomy represents the hysteroscopic procedure with a higher complication rate. Unfortunately, the classical slicing technique, even in expert hands, does not respect the pseudocapsule and the adjacent healthy myometrium. During the resection of the intramural component of a myoma, the “pseudocapsular tissue” should be visualized all over the resected area. Sometimes, due to fibroid dimensions and bleeding, it can be challenging to make a distinction between the myoma tissue, the pseudocapsule, and the healthy myometrium. The problem is the direct action of the electrical loop during the myoma slicing and the incorrect dissection of the anatomical planes. The traditional technique altered the intrauterine anatomy and it is almost impossible to avoid the injury of the myometrial fibers, causing a direct (by cutting) and indirect (by thermal spreading) damage to the pseudocapsule and the surrounding healthy myometrium. This fundamental issue is responsible for all the intraoperative complications during the hysteroscopic myomectomy. Moreover, the role of surgical trauma to the healthy myometrium during hysteroscopic surgery can lead to synechiae and adhesions’ formation [28, 39].

The ideal hysteroscopic myomectomy ideally should be performed in one surgical step, a safe and effective procedure, which is simple and well-tolerated [32]. In the last decades, several techniques have been proposed in order to overcome the limits represented by the classical slicing for the treatment of the myometrial portion of submucous myomas [5]. The main objective of these techniques was the detachment of the intra-myometrial part of the fibroid, in order to enable the sliding from the myometrium into the uterine cavity. Some authors proposed the use of uterine contractions, induced by manual massage, drugs, or changing intrauterine pressure [40–43]. A combination of multiple techniques and ultrasound monitoring during myomectomy was also described [44, 45]. Authors proposed the detachment of intramural component of fibroids by electrical incision of the fibroconnective bridges, anchoring the myoma to the pseudocapsule [46].

A technique that allowed us to overcome the limits represented by the classical slicing was described in 1995, as the cold-loop hysteroscopic myomectomy [46]. This method allowed to change the approach to the myoma, from the progressive reduction or electrical power using and its switching to a mechanical enucleation of the myoma from the pseudocapsule, by the physiological contraction of the myometrium. It represented a revolution in the hysteroscopic treatment of submucous fibroids, since it distinguished the anatomical planes, respected the anatomical and functional integrity of the myometrium and of the pseudocapsule, at the same time ensuring a safe and effective procedure. By the cold-loop myomectomy, the fibroconnective bridges that anchor the myoma to its pseudocapsule are mechanically disconnected, enucleating the intramural component of the fibroid, without any effect to the adjacent healthy myometrial tissue. Moreover, the cold loops are applied between the myoma and the pseudocapsule, allowing to avoid uterine

perforation by electrical loop and injury to abdominal organs or vessels. Noteworthy, in case of perforation by cold loops, the damage induced can be considered to be the same as that with a Hegar dilator [8].

Finally, the respect of the myometrium allows uterine contractions, facilitating the sliding of the intramural part of the fibroid into the uterine cavity and at the same time increases the free myometrial margin thickness [47]. The uterine contraction and the respect of the myometrial muscular fibers decreases the risk of bleeding and the absorption of the distension medium, enhancing the possibility to accomplish the treatment in a single operation [48].

The respect of the pseudocapsule promotes better healing of the myometrium, avoiding scarring and reducing the intrauterine adhesions and dramatic complications, such as subsequent uterine rupture [5, 28, 49, 50].

CONCLUSION

The morphological and molecular investigation performed on the fibroid pseudocapsule changed the current surgical

and biological scenario of myomectomy, due to interesting scientific results. The discovery of the fibroneurovascular structure surrounding the fibroid, rich in neuropeptides and neurotransmitters, translated the new concept of myomectomy in reproductive surgery and in fertility-sparing procedures, even for giant fibroids and during pregnancy.

Much evidence on the presence of angiogenetic properties in a few millimeters of the biological structure, the pseudocapsule, underline the necessity to preserve it as much as possible while performing myomectomy, especially to preserve myometrial integrity near the fibroid site, indirectly enhancing myometrial healing after myomectomy, and reducing surgical bleeding.

Intracapsular myomectomy should also enhance the post-operative adhesions' reduction. In our opinion, the intracapsular myomectomy, with pseudocapsule sparing by endoscopic "microsurgical" magnification, as a safe and feasible minimally invasive technique, should be performed in all myomectomies.

Conflict of interest: None declared.

REFERENCES

- Sparic R, Mirkovic L, Malvasi A, Tinelli A. Epidemiology of Uterine Myomas: A Review. *Int J Fertil Steril*. 2016;9(4):424–35.
- Coronado GD, Marshall LM, Schwartz SM. Complications in pregnancy, labor, and delivery with uterine leiomyomas: a population-based study. *Obstet Gynecol*. 2000;95(5):764–9.
- Evans P, Brunsell S. Uterine fibroid tumors: diagnosis and treatment. *Am Fam Physician*. 2007;75(10):1503–8.
- Rolli R, Favilli A, Acanfora MM, Scuderi G, Di Renzo GC, Gerli S. Vaginal myomectomy is a safe and feasible procedure: a retrospective study of 46 cases. *J Obstet Gynaecol Res*. 2012;38(9):1201–5.
- Tinelli A, Malvasi A, Hudelist G, Cavallotti C, Tsin DA, Schollmeyer T, et al. Laparoscopic intracapsular myomectomy: comparison of single versus multiple fibroids removal. An institutional experience. *J Laparoendosc Adv Surg Tech A*. 2010;20(8):705–11.
- Di Spiezio Sardo A, Mazzon I, Bramante S, Bettocchi S, Bifulco G, Guida M, et al. Hysteroscopic myomectomy: a comprehensive review of surgical techniques. *Hum Reprod Update*. 2008;14(2):101–19.
- Falcone T, Parker WH. Surgical management of leiomyomas for fertility or uterine preservation. *Obstet Gynecol*. 2013;121(4):856–68.
- Mazzon I, Favilli A, Grasso M, Horvath S, Di Renzo GC, Gerli S. Is Cold Loop Hysteroscopic Myomectomy a Safe and Effective Technique for the Treatment of Submucous Myomas With Intramural Development? A Series of 1434 Surgical Procedures. *J Minim Invasive Gynecol*. 2015;22(5):792–8.
- Hanna KR, Katz AJ. An update on wound healing and the nervous system. *Ann Plast Surg*. 2011;67(1):49–52.
- Tidball JG. Mechanisms of muscle injury, repair, and regeneration. *Compr Physiol*. 2011;1(4):2029–62.
- Järvinen TA, Järvinen TL, Kääriäinen M, Kalimo H, Järvinen M. Muscle injuries: biology and treatment. *Am J Sports Med*. 2005;33(5):745–64.
- Henderson J, Terenghi G, Ferguson MW. The reinnervation and revascularisation pattern of scarless murine fetal wounds. *J Anat*. 2011;218(6):660–7.
- Gouin JP, Carter CS, Pournajafi-Nazarloo H, Glaser R, Malarkey WB, Loving TJ, et al. Marital behavior, oxytocin, vasopressin, and wound healing. *Psychoneuroendocrinology*. 2010;35(7):1082–90.
- Malvasi A, Cavallotti C, Nicolardi G, Pellegrino M, Vergara D, Greco M, et al. The opioid neuropeptides in uterine fibroid pseudocapsules: a putative association with cervical integrity in human reproduction. *Gynecol Endocrinol*. 2013;29(11):982–8.
- Malvasi A, Tinelli A, Cavallotti C, Morroni M, Tsin DA, Nezhat C, et al. Distribution of substance P (SP) and vasoactive intestinal peptide (VIP) in pseudocapsules of uterine fibroids. *Peptides*. 2011;32(2):327–32.
- Mettler L, Tinelli A, Hurst BS, Teigland CM, Sammur W, Dell'edera D, et al. Neurovascular bundle in fibroid pseudocapsule and its neuroendocrinologic implications. *Expert Rev Endocrinol Metab*. 2011;6(5):715–22.
- Malvasi A, Cavallotti C, Nicolardi G, Pellegrino M, Dell'edera D, Vergara D, et al. NT, NPY and PGP 9.5 presence in myometrium and in fibroid pseudocapsule and their possible impact on muscular physiology. *Gynecol Endocrinol*. 2013;29(2):177–81.
- Tinelli A, Malvasi A, Hurst BS, Tsin DA, Davila F, Dominguez G, et al. Surgical management of neurovascular bundle in uterine fibroids pseudocapsule. *JLS*. 2012;16(1):119–29.
- Tinelli A, Hurst BS, Mettler L, Tsin DA, Pellegrino M, Nicolardi G, et al. Ultrasound evaluation of uterine healing after laparoscopic intracapsular myomectomy: an observational study. *Hum Reprod*. 2012;27(9):2664–70.
- Vikhareva Osser O, Valentin L. Risk factors for incomplete healing of the uterine incision after caesarean section. *BJOG*. 2010;117(9):1119–26.
- Di Tommaso S, Massari S, Malvasi A, Bozzetti MP, Tinelli A. Gene expression analysis reveals an angiogenic profile in uterine leiomyoma pseudocapsule. *Mol Hum Reprod*. 2013;19(6):380–7.
- De Falco M, Staibano S, Mascolo M, Mignongna C, Improda L, Ciociola F, et al. Leiomyoma pseudocapsule after pre-surgical treatment with gonadotropin-releasing hormone agonists: relationship between clinical features and immunohistochemical changes. *Eur J Obstet Gynecol Reprod Biol*. 2009;144(1):44–7.
- Mavrellos D, Ben-Nagi J, Davies A, Lee C, Salim R, Jurkovic D. The value of preoperative treatment with GnRH analogues in women with submucous fibroids: a double-blind, placebo-controlled randomized trial. *Hum Reprod*. 2010;25(9):2264–9.
- Ong AM, Su LM, Varkarakis I, Inagaki T, Link RE, Bhayani SB, et al. Nerve sparing radical prostatectomy: effects of hemostatic energy sources on the recovery of cavernous nerve function in a canine model. *J Urol*. 2004;172(4 Pt 1):1318–22.
- Zhao X, Zeng W, Chen L, Chen L, Du W, Yan X. Laparoscopic Myomectomy Using "Cold" Surgical Instruments for Uterine Corpus Leiomyoma: A Preliminary Report. *Cell Biochem Biophys*. 2015;72(1):141–6.

26. Pitter MC, Srouji SS, Gargiulo AR, Kardos L, Seshadri-Kreaden U, Hubert HB, et al. Fertility and Symptom Relief Following Robot-Assisted Laparoscopic Myomectomy. *Obstet Gynecol Int*. 2015;2015:967568.
27. Closon F, Tulandi T. Uterine myomata: Organ-preserving surgery. *Best Pract Res Clin Obstet Gynaecol*. 2016;35:30–6.
28. Mazzon I, Favilli A, Cocco P, Grasso M, Horvath S, Bini V, et al. Does cold loop hysteroscopic myomectomy reduce intrauterine adhesions? A retrospective study. *Fertil Steril*. 2014;101(1):294–8.e3.
29. Chao AS, Chang YL, Yang LY, Chao A, Chang WY, Su SY, et al. Laparoscopic uterine surgery as a risk factor for uterine rupture during pregnancy. *PLoS One*. 2018;13(5):e0197307.
30. Tinelli A, Mettler L, Malvasi A, Hurst B, Catherino W, Mynbaev OA, et al. Impact of surgical approach on blood loss during intracapsular myomectomy. *Minim Invasive Ther Allied Technol*. 2014;23(2):87–95.
31. Neuwirth RS. A new technique for and additional experience with hysteroscopic resection of submucous fibroids. *Am J Obstet Gynecol*. 1978;131(1):91–4.
32. Pakrashi T. New hysteroscopic techniques for submucosal uterine fibroids. *Curr Opin Obstet Gynecol*. 2014;26(4):308–13.
33. Howe RS. Third-trimester uterine rupture following hysteroscopic uterine perforation. *Obstet Gynecol*. 1993;81:827–9.
34. Jedeikin R, Olsfanger D, Kessler I. Disseminated intravascular coagulopathy and adult respiratory distress syndrome: life-threatening complications of hysteroscopy. *Am J Obstet Gynecol*. 1990;162(1):44–5.
35. Murakami T, Tamura M, Ozawa Y, Suzuki H, Terada Y, Okamura K. Safe techniques in surgery for hysteroscopic myomectomy. *J Obstet Gynaecol Res*. 2005;31(3):216–23.
36. Wamsteker K, Emanuel MH, de Kruijff JH. Transcervical hysteroscopic resection of submucous fibroids for abnormal uterine bleeding: results regarding the degree of intramural extension. *Obstet Gynecol*. 1993;82(5):736–40.
37. Lasmar RB, Barrozo PR, Dias R, Oliveira MA. Submucous myomas: a new presurgical classification to evaluate the viability of hysteroscopic surgical treatment—preliminary report. *J Minim Invasive Gynecol*. 2005;12(4):308–11.
38. Emanuel MH, Wamsteker K, Hart AA, Metz G, Lammes FB. Long-term results of hysteroscopic myomectomy for abnormal uterine bleeding. *Obstet Gynecol*. 1999;93(5 Pt 1):743–8.
39. Deans R, Abbott J. Review of intrauterine adhesions. *J Minim Invasive Gynecol*. 2010;17(5):555–69.
40. Hallez JP. Single-stage total hysteroscopic myomectomies: indications, techniques, and results. *Fertil Steril*. 1995;63(4):703–8.
41. Darwish A. Modified hysteroscopic myomectomy of large submucous fibroids. *Gynecol Obstet Invest*. 2003;56(4):192–6.
42. Murakami T, Hayasaka S, Terada Y, Yuki H, Tamura M, Yokomizo R, et al. Predicting outcome of one-step total hysteroscopic resection of sessile submucous myoma. *J Minim Invasive Gynecol*. 2008;15(1):74–7.
43. Bernard G, Darai E, Poncelet C, Benifla JL, Madelenat P. Fertility after hysteroscopic myomectomy: effect of intramural myomas associated. *Eur J Obstet Gynecol Reprod Biol*. 2000;88(1):85–90.
44. Korkmazer E, Tekin B, Solak N. Ultrasound guidance during hysteroscopic myomectomy in G1 and G2 Submucous Myomas: for a safer one step surgery. *Eur J Obstet Gynecol Reprod Biol*. 2016;203:108–11.
45. Ludwin A, Ludwin I, Pityński K, Basta P, Basta A, Banas T, et al. Transrectal ultrasound-guided hysteroscopic myomectomy of submucosal myomas with a varying degree of myometrial penetration. *J Minim Invasive Gynecol*. 2013;20(5):672–85.
46. Litta P, Vasile C, Merlin F, Basta P, Basta A, Banas T, et al. A new technique of hysteroscopic myomectomy with enucleation in toto. *J Am Assoc Gynecol Laparosc*. 2003;10(2):263–70.
47. Casadio P, Youssef AM, Spagnolo E, Rizzo MA, Basta A, Banas T, et al. Should the myometrial free margin still be considered a limiting factor for hysteroscopic resection of submucous fibroids? A possible answer to an old question. *Fertil Steril*. 2011;95(5):1764–8.e1.
48. Mazzon I, Favilli A, Grasso M, Horvath S, Bini V, Di Renzo GC, et al. Predicting success of single step hysteroscopic myomectomy: A single centre large cohort study of single myomas. *Int J Surg*. 2015;22:10–4.
49. Tinelli A, Mynbaev OA, Sparic R, Vergara D, Di Tommaso S, Salzet M, et al. Angiogenesis and Vascularization of Uterine Leiomyoma: Clinical Value of Pseudocapsule Containing Peptides and Neurotransmitters. *Curr Protein Pept Sci*. 2017;18(2):129–39.
50. Tinelli A, Malvasi A, Guido M, Tsin DA, Hudelist G, Hurst B, et al. Adhesion formation after intracapsular myomectomy with or without adhesion barrier. *Fertil Steril*. 2011;95(5):1780–5.

Псеудокапсула миома – биолошка и хируршка структура коју треба поштовати током миомектомије

Андреа Тинели^{1,2,3}, Радмила Спарич^{4,5}

¹Болница „Верис дели понти“, Одељење за акушерство и гинекологију, Скорано, Италија;

²Болница „Вито Фаци“, Одељење за гинекологију и акушерство, Одсек за експерименталну ендоскопску хирургију, имидинг технологију и минимално инвазивну терапију, Лече, Италија;

³Московски институт за физику и технологију (Државни универзитет), Одсек за примењену математику, интернационални пренос медицинских знања и истраживање биолошких модела, Москва, Русија;

⁴Клинички центар Србије, Клиника за гинекологију и акушерство, Београд, Србија;

⁵Универзитет у Београду, Медицински факултет, Београд, Србија

САЖЕТАК

Миоми материце се јављају код готово сваке друге болеснице, узрокују бројне интрапелвичне тегобе и захтевају фармаколошко или хируршко лечење. Дуги низ година значај миома је посматран као болест материце, без фокусирања на комплексну биологију миометријума који их окружује. Уз то, традиционална хируршка техника уклањања миома није истраживана годинама. Насупрот томе, у новије време, морфолошке, неуроендокрине и анатомске студије су показале значај биолошке и хируршке структуре која окружује миом, богате неуротрансмитерима и нервним влакнима, односно псеудокапсуле миома. Ова структура се формира у материци периферно од миома, одваја миом од миометријума и функционише као регенератор ткива после уклањања миома из материце. Примена научних ис-

траживања псеудокапсула у хируршкој пракси омогућила је настанак нових техника миомектомије, које подразумевају уклањање миома унутар псеудокапсуле и промовисање поштедних операција у односу на псеудокапсулу. Све ово погодује накнадним биолошким процесима оживљавања и зарастања материце, активацијом неуротрансмитера и нервних влакана присутних у миометријалној ложи миома. Правилно зарастање после уклањања миома успоставља анатомију материце, са позитивним утицајем на каснију репродуктивну функцију, смањујући компликације повезане са оживљом у миометријуму.

Кључне речи: псеудокапсула миома; миомектомија; неуроваскуларна петелка; репродуктивна хирургија; трудноћа; фертилитет