

CASE REPORT / ПРИКАЗ БОЛЕСНИКА

Mineral trioxide aggregate for the treatment of external root resorption in an avulsed immature tooth – ten years of follow-up

Tamara Perić¹, Dejan Marković¹, Bojan Petrović²¹University of Belgrade, School of Dental Medicine, Department of Paediatric and Preventive Dentistry, Belgrade, Serbia;²University of Novi Sad, Faculty of Medicine, Dentistry Clinic of Vojvodina, Department of Paediatric and Preventive Dentistry, Novi Sad, Serbia**SUMMARY**

Introduction Root resorption may occur as a consequence of avulsion injury and may lead to the progressive loss of tooth structure. The aim was to report the outcome of root resorption treated with mineral trioxide aggregate in a replanted immature permanent incisor after 10 years of follow-up.

Case outline This case presents external root resorption that was detected 18 months after the avulsion injury in a nine-year-old child. Apical portion of the canal was filled with mineral trioxide aggregate and the rest of the canal was filled with a canal sealer and gutta-percha. Control examinations were performed six months after the completion of the endodontic treatment and afterwards yearly. The tooth was asymptomatic clinically and radiographs did not show progression of root resorption up to four years of follow-up. Infraposition of the injured tooth was detected five years after the replantation, but without significant radiographic changes, until the eight-year follow-up, when root resorption was detected again. However, the tooth was still hard and symptomless at the 10-year follow-up.

Conclusion Mineral trioxide aggregate may have an important role in the preservation of replanted immature teeth for a prolonged period.

Keywords: immature teeth; avulsion injury; root resorption; mineral trioxide aggregate

INTRODUCTION

Traumatic injuries to permanent anterior teeth are common during childhood and 0.5–16% of the 7–10-year age group experience tooth avulsion [1]. Prolonged inadequate storage has been identified as a crucial factor for the survival of an avulsed tooth [2]. Ideally, tooth should be replanted within five minutes after the injury, but in clinical practice, teeth are frequently stored in unphysiological media and replantation is delayed [2]. Therefore, loss of pulpal vitality could be considered to be an expected clinical finding in avulsed teeth [3]. As a further complication, root resorption may occur and may lead to the progressive loss of tooth structure.

The treatment of avulsed immature permanent teeth presents a challenge in the contemporary clinical practice. Despite the fact that teeth with open apices have a potential to revascularize and continue root development, these teeth usually have poorer prognosis in comparison to mature teeth, particularly due to delayed replantation after unphysiological storage [3]. Unfortunately, in the majority of clinical cases, the objective of endodontic treatment is to eliminate the infection or arrest the root resorption.

Mineral trioxide aggregate (MTA) is endodontic cement that consists of tricalcium

oxide, tricalcium silicate, tricalcium aluminate, silicate oxide, bismuth oxide, and other hydrophilic particles, which set in the presence of moisture. This is a biocompatible material which provides good sealing [4, 5]. It has been reported to stimulate osteoblasts/odontoblasts, thus inducing hard tissue formation, and its use has been recommended in complex endodontic cases [6, 7, 8]. The use of MTA for endodontic treatment of immature teeth implies the formation of an apical plug that acts as an artificial barrier providing an immediate obturation of the open apex.

The purpose of this report was to describe the outcome of root resorption treated with MTA in a replanted immature permanent incisor after 10 years of follow-up.

CASE REPORT

A nine-year-old girl was referred from the public dental health service to the Clinic for Paediatric and Preventive Dentistry, School of Dental Medicine, University of Belgrade, Serbia, in August of 2004. The night before the referral, after an accident during play, she suffered an avulsion injury of a permanent left central maxillary incisor and primary left lateral maxillary incisor and uncomplicated crown fracture of a permanent right central maxillary incisor.

Received • Примљено:

January 11, 2019

Revised • Ревизија:

August 6, 2019

Accepted • Прихваћено:

September 4, 2019

Online first: September 23, 2019**Correspondence to:**

Tamara PERIĆ
School of Dental Medicine
Department of Paediatric
and Preventive Dentistry
Dr Subotica 11
11000 Belgrade
Serbia
tamara.peric@stomf.bg.ac.rs

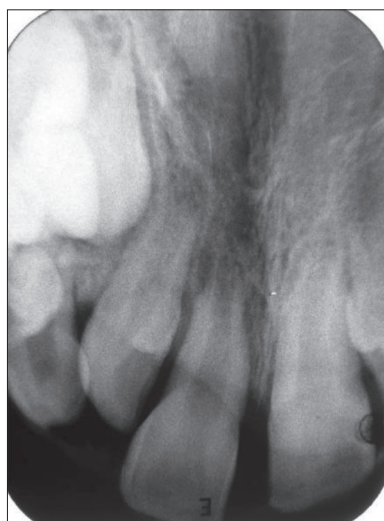

Figure 1. Initial radiograph

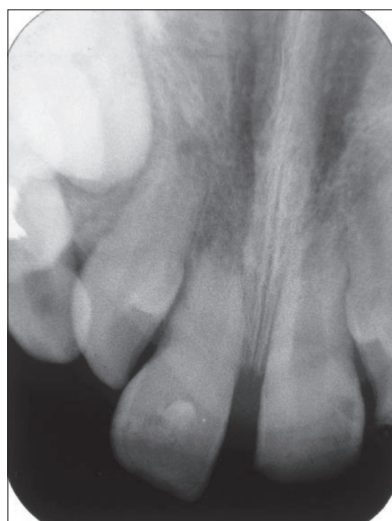

Figure 2. Calcium hydroxide dressing

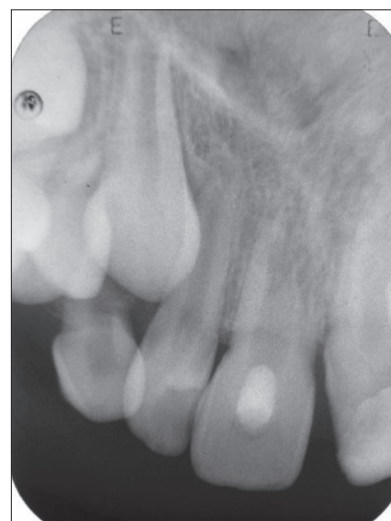

Figure 3. External root resorption after 18 months

Replantation of the avulsed permanent tooth was performed after three-hour dry storage at the public health service facilities (Figure 1) and the injured tooth was stabilized at our clinic with a passive, flexible acid-etched composite splint after a total of 14 hours. Although tetracycline was recommended, the girl was placed on 250 mg of penicillin to be taken every six hours for one week. Tetanus coverage was evaluated and suitable oral hygiene and dietetic regime were recommended. Informed parental consent for the future treatment was obtained in writing and consent was also obtained from the child.

Ten days after the injury, endodontic treatment of the replanted tooth was initiated. Following pulpectomy, a non-setting calcium hydroxide paste (Kalcipast®, ICN Galenika, Belgrade, Serbia) was placed in the root canal. The splint was removed 14 days after the injury.

According to guidelines at that time, endodontic treatment consisted of periodical changes of a calcium hydroxide dressing for apexification at the following regime: seven days, one month, and when radiographs revealed a loss of material from the root canal (Figure 2) [9]. Periapical radiographs were taken every three months during the first year, and every six months thereon. Eighteen months after the injury, external root resorption was detected radiographically (Figure 3). At this point, the patient and her parents were informed that initial treatment was not successful, and that progredient root resorption would eventually lead to tooth loss. They were not particularly motivated to continue with the treatment that is “temporary,” especially in the situation when the complication occurred. Taking into account all clinical considerations, a definitive endodontic treatment was suggested.

Calcium hydroxide was removed and the apical portion of the canal was filled with mineral trioxide aggregate (ProRoot MTA, Dentsply Tulsa Dental, Tulsa, OK, USA;

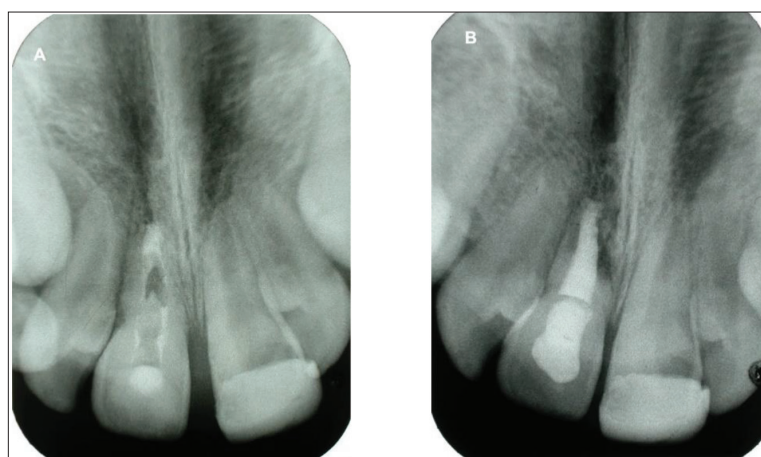


Figure 4. Definitive obturation with: (A) MTA; (B) root canal sealer and gutta-percha

Figure 4a). The material was allowed to set into the canal and after three days the rest of the canal was filled with a canal sealer (Acroseal, Septodont, Saint Maur des Fosses, France) and gutta-percha (Figure 4b). The crown of the tooth was then restored with glass-ionomer cement (Fuji IX, GC Int, Tokyo, Japan) and composite material (Gradia Direct, GC Int).

Control examinations were performed six months after the completion of the endodontic treatment and yearly thereon. The tooth was asymptomatic clinically and radiographs did not show progression of root resorption up to four years of follow-up (Figures 5a–5c). Infraposition of the injured tooth was detected five years after replantation, suggesting that replacement resorption was developing (Figure 5d). At this point, decoronation was not considered as a treatment option since alveolar contour was still preserved. To improve aesthetic appearance, the tooth was built-up with composite material. At the six-year (Figure 5e) and seven-year (Figure 5f) follow-up, no significant resorption progression was observed clinically or radiographically. Starting from the eighth year, root resorption developed again (Figures 5g–5i). However, the tooth was still hard and symptomless at the 10-year follow-up.

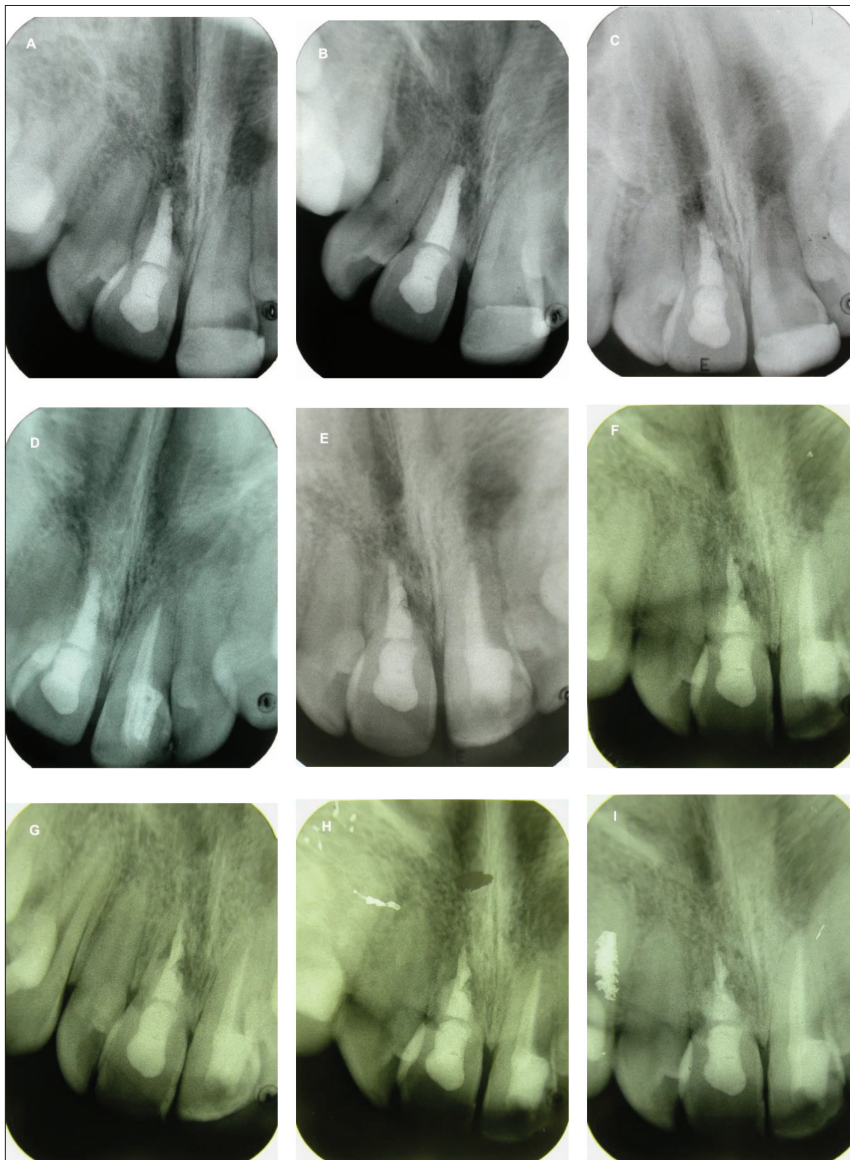


Figure 5. Radiographic follow-up after: (A) two years; (B) three years; (C) four years; (D) five years; (E) six years; (F) seven years; (G) eight years; (H) nine years; and (I) 10 years

Unfortunately, the patient was not followed longer as she had moved and the tooth was extracted by another dentist.

DISCUSSION

Most avulsion injuries occur at an age which is crucial to facial growth and the psychosocial development of a child. The treatment of an avulsion injury is rather demanding, considering the fact that several factors, such as the mechanism of the injury, apical maturity of the root, extra-alveolar storage, the patient's compliance, etc. may influence therapy and prognosis of these injuries [3]. Nevertheless, the maintenance of the injured tooth is of utmost importance in young patients until growth reaches its full potential.

Favorable healing after an avulsion injury requires quick emergency intervention, followed by an evaluation and possible treatment at decisive times during the healing

phase [10]. The maintenance of periodontal ligament cellular viability is essential for longevity of the replanted tooth [11]. However, if excessive drying occurs before replantation, the damaged periodontal ligament cells will elicit a severe inflammatory response over a diffuse area on the root surface. Treatment strategies should always be considered in the context of limiting the extent of the peri-radicular inflammation, thus tipping the balance toward favorable (cemental) rather than unfavorable (osseous replacement or inflammatory root resorption) healing [10].

Apical maturity of the root presents an important factor that determines the outcome of a replanted tooth. Although a tooth with uncompleted root development possesses a strong reparatory potential and a thicker periodontal ligament that desiccates more slowly, the postreplantation outcome is usually poorer compared to a mature tooth. Andreasen et al. [2] in a study of 400 replanted teeth reported higher failure rates in teeth with open apices. According to the current guidelines, the removal of the necrotic pulp tissue and the use of calcium hydroxide in the root canal are mandatory to stimulate apical closure in a developing tooth and to prevent root resorption [12]. However, it has been reported that prolonged

treatment with calcium hydroxide exhibits a high complication rate [2, 3]. This approach comprises repetitive changes of calcium hydroxide dressing which may last for several months leading to the difficulties in patient follow-up. In addition, the canal is susceptible to reinfection because it is covered by a temporary coronal seal [13]. For those reasons, the use of calcium hydroxide for apexification is no longer supported [14].

Currently, MTA is recommended for the treatment of immature teeth with necrotic pulp [5]. Erdem and Sepet [13] performed early treatment with MTA in traumatized immature incisors and showed resolution of the periapical lesions and apexification in four out of five teeth during the two-year follow-up period. Sarris et al. [15] investigated MTA as an apical barrier in 17 non-vital immature permanent incisors and reported a decrease in the size of the periapical lesion without radiographic signs of root resorption in 76.5% of cases. Moore et al. [16] evaluated 22 non-vital traumatized teeth treated with MTA and showed

95.5% clinical and 90.9% radiographical success during the minimum 18-month follow-up. Pace et al. [17] evaluated 17 immature teeth treated with MTA during 10 years and reported 94% healing rates. Četenović et al. [18] assessed two MTA products in both immature and mature traumatized necrotic teeth, and showed significant reduction or complete regression of chronic periapical lesions. Data on comparison between calcium hydroxide and MTA clinical efficacy in immature teeth apexification are still limited. It has been shown that both materials had similar clinical (asymptomatic tooth without pain, swelling, and luxation) and radiographical (apical barrier formation, normal periapical space, no root resorption/fracture) success rates, with apical barrier formation with MTA requiring significantly shorter time [19–23].

The evidence on use of MTA for the treatment of teeth with root resorption is low [5]. Correspondingly to the

present case, Aggarwal and Singla [24] reported that treatment with MTA successfully discontinued external root resorption after avulsion and replantation during a four-year follow-up. It has been shown that MTA has high pH and the ability to release calcium and phosphate ions for a longer period, which may deactivate the inflammatory process and retard the odontoclastic activity [24, 25].

To conclude, maintenance of an anterior tooth is of the utmost importance in pediatric patients until growth reaches its full potential. MTA may have an important role in the preservation of a replanted immature tooth for a long period.

Informed consent: Written informed consent was obtained from the patient for this case report publication, including the accompanying images, case history, and data.

Conflict of interest: None declared.

REFERENCES

- Andreasen JO. Etiology and pathogenesis of traumatic dental injuries. A clinical study of 1,298 cases. *Scand J Dent Res*. 1970;78(4):329–42.
- Andreasen JO, Borum MK, Jacobsen HL, Andreasen FM. Replantation of 400 avulsed permanent incisors. 4. Factors related to periodontal ligament healing. *Endod Dent Traumatol*. 1995;11(2):76–89.
- Petrovic B, Markovic D, Peric T, Blagojevic D. Factors related to treatment and outcomes of avulsed teeth. *Dent Traumatol*. 2010;26(1):52–9.
- Benetti F, Gomes-Filho JE, de Araujo Lopes JM, Barbosa JG, Jacinto RC, Cintra LTA. In vivo biocompatibility and biomineralization of calcium silicate cements. *Eur J Oral Sci*. 2018;126(4):326–33.
- Torabinejad M, Parirokh M, Dummer PMH. Mineral trioxide aggregate and other bioactive endodontic cements: an updated overview- part II: other clinical applications and complications. *Int Endod J*. 2018;51(3):284–317.
- Kontakiotis EG, Filippatos CG, Tzanetakos GN, Agrafioti A. Regenerative Endodontic Therapy: A Data Analysis of Clinical Protocols. *J Endod*. 2015;41(2):146–54.
- Youssef AR, Emar R, Taher MM, Al-Allaf FA, Almalki M, Almasri MA, Siddiqui SS. Effects of mineral trioxide aggregate, calcium hydroxide, biodentine and Emdogain on osteogenesis, Odontogenesis, angiogenesis and cell viability of dental pulp stem cells. *BMC Oral Health*. 2019;19(1):133.
- Četenović B, Colović B, Vasilijević S, Pasalić S, Jokanović V, Marković D. In vitro biocompatibility of nanostructured endodontic materials using SCAP cells. *Balk J Dent Med*. 2017;21(3):167–70.
- Flores MT, Andreasen JO, Bakland LK. Guidelines for the evaluation and management of traumatic dental injuries. *Dent Traumatol*. 2001;17(5):193–8.
- Trope M. Clinical management of the avulsed tooth: present strategies and future directions. *Dent Traumatol*. 2002;18(1):1–11.
- Osmanovic A, Halilovic S, Kurtovic-Kozaric A, Hadziabdic N. Evaluation of periodontal ligament cell viability in different storage media based on human PDL cell culture experiments – A systematic review. *Dent Traumatol*. 2018;34(6):384–93.
- Andersson L, Andreasen JO, Day P, Heithersay G, Trope M, DiAngelis AJ, et al. International Association of Dental Traumatology guidelines for the management of traumatic dental injuries. 2. Avulsion of permanent teeth. *Dent Traumatol*. 2012;28(2):88–96.
- Erdem AP, Sepet E. Mineral trioxide aggregate for obturation of maxillary central incisors with necrotic pulp and open apices. *Dent Traumatol*. 2008;24(5):e38–41.
- Duggal M, Tong HJ, Al-Ansary M, Twati W, Day PF, Nazzal H. Interventions for the endodontic management of non-vital traumatised immature permanent anterior teeth in children and adolescents: a systematic review of the evidence and guidelines of the European Academy of Paediatric Dentistry. *Eur Arch Paediatr Dent*. 2017;18(3):139–51.
- Sarris S, Tahmassebi JF, Duggal MS, Cross IA. A clinical evaluation of mineral trioxide aggregate for root-end closure of non-vital immature permanent incisors in children – a pilot study. *Dent Traumatol*. 2008;24(1):79–85.
- Moore A, Howley MF, O'Connell AC. Treatment of open apex tooth using two types of white mineral trioxide aggregate after initial dressing with calcium hydroxide in children. *Dent Traumatol*. 2011;27(3):166–73.
- Pace R, Giuliani V, Nieri M, Di Nasso L, Pagavino G. Mineral trioxide aggregate as apical plug in teeth with necrotic pulp and immature apices: a 10-year case series. *J Endod*. 2014;40(8):1250–4.
- Četenović B, Marković D, Gutmann J, Perić T, Jokanović V. Endodontic treatment of traumatized teeth with chronic periapical lesions using antibiotic paste and mineral trioxide aggregate obturation – a preliminary study. *Srp Arh Celok Lek*. 2019;147(5–6):270–5.
- Bonte E, Beslot A, Boukpepsi T, Lasfargues JJ. MTA versus Ca(OH)₂ in apexification of non-vital immature permanent teeth: a randomized clinical trial comparison. *Clin Oral Investig*. 2015;19(6):1381–8.
- Lin JC, Lu JX, Zeng Q, Zhao W, Li WQ, Ling JQ. Comparison of mineral trioxide aggregate and calcium hydroxide for apexification of immature permanent teeth: A systematic review and meta-analysis. *J Formos Med Assoc*. 2016;115(7):523–30.
- Kahler B, Rossi-Fedele G, Chugal N, Lin LM. An Evidence-based Review of the Efficacy of Treatment Approaches for Immature Permanent teeth with pulp necrosis. *J Endod*. 2017;43(7):1052–7.
- Nicoloso GF, Pötter IG, Rocha RO, Montagner F, Casagrande L. A comparative evaluation of endodontic treatments for immature necrotic permanent teeth based on clinical and radiographic outcomes: a systematic review and meta-analysis. *Int J Paediatr Dent*. 2017;27(3):217–27.
- Kim SG, Malek M, Sigurdsson A, Linn LM, Kahler B. Regenerative endodontics: a comprehensive review. *Int Endod J*. 2018;51(12):1367–88.
- Aggarwal V, Singla M. Management of inflammatory root resorption using MTA obturation- a four year follow up. *Br Dent J*. 2010;208(7):287–9.
- Vivan RR, Zapata RO, Zeferino MA, Bramante CM, Bernardineli N, Garcia RB, et al. Evaluation of the physical and chemical properties of two commercial and three experimental root-ending filling materials. *Oral Surg Oral Med Oral Pathol Pral Radiol Endod*. 2010;110(2):250–6.

Минерални триоксидни агрегат у терапији екстерне ресорпције корена избијеног зуба са незавршеним растом корена – исход после десет година

Тамара Перић¹, Дејан Марковић¹, Бојан Петровић²

¹Универзитет у Београду, Стоматолошки факултет, Клиника за дечју и превентивну стоматологију, Београд, Србија;

²Универзитет у Новом Саду, Медицински факултет, Клиника за стоматологију Војводине, Нови Сад, Србија

САЖЕТАК

Увод Ресорпција корена зуба се може јавити као последица повреде и може водити прогресивном губитку зубних структура.

Циљ рада је био да се прикаже клинички исход реплантације избијеног сталног зуба са незавршеним растом корена после десет година.

Приказ болесника Представљен је случај екстерне ресорпције корена зуба детектоване 18 месеци после авулзионе повреде код деветогодишњег детета. Апикални део канала корена зуба је напуњен минералним триоксидним агрегатом, док је остатак канала оптуриран пастом и гутаперка поенима. Контролни прегледи су обављани шест месеци

после завршетка ендодонтског лечења и, после тога, једном годишње. До четврте године праћења зуб је био без клиничких и радиографских знакова прогресије ресорпције корена. Инфрапозиција повређеног зуба уочена је пет година после реплантације, али без значајних радиографских промена све до осме године праћења, када је уочено напредовање ресорпције корена. Ипак, после десет година зуб је и даље био клинички без симптома.

Закључак Минерални триоксидни агрегат може имати значајну улогу у дуготрајном очувању реплантираних зуба са незавршеним растом корена.

Кључне речи: незавршен раст корена; авулзија; ресорпција корена; минерални триоксидни агрегат