

CASE REPORT / ПРИКАЗ БОЛЕСНИКА

Pickwickian syndrome – “the tip of the iceberg” in extremely obese patients

Jelena Kaščak, Slađana Anđelić

Municipal Institution for Emergency Medical Care, Belgrade, Serbia

**SUMMARY**

Introduction Pickwickian syndrome (PS), also known as hypoventilation syndrome in adults, consists of three factors: obesity [Body Mass Index (BMI) > 30 kg/m²], daytime hypercapnia and sleep-disordered breathing, after ruling out other disorders that may cause alveolar hypoventilation. Timely recognition of PS is of utmost importance because such patients have significant morbidity and mortality. However, recent data indicate that PS is under-recognized and under-treated. We report a case of early-identified PS prehospitally with a favorable outcome after hospital treatment.

Case outline A 67-year-old female patient was diagnosed prehospitally, and the diagnosis was later confirmed in hospital. Diagnostic criteria were as follows: BMI > 45,7 kg/m² (height 170 cm, weight 132 kg), hypercapnia, hypoxemia and respiratory acidosis (pCO₂ – 41 mmHg, pO₂ – 56 mmHg, pH 7.45) in the absence of other causes of hypoventilation. During hospitalization, the following diagnostic procedures were performed: standard laboratory analyses, chest radiography, electrocardiography, abdomen and heart echocardiography. An attempted sleep study (polysomnography) was interrupted due to a drop in oxygen saturation levels. Non-invasive mechanical ventilation and a diet were used as the first line of therapy. However, due to the development of a global respiratory insufficiency, the patient was intubated and placed on a mechanical ventilator. After 30 days of hospital treatment, the patient was released in a satisfactory general condition with recommendations for weight reduction and symptomatic therapy.

Conclusion As obesity is becoming an epidemic of modern society, early recognition and treatment of PS is of crucial importance.

Keywords: obesity; Pickwick syndrome; early recognition; treatment

INTRODUCTION

The increase in the prevalence of extreme obesity in the last decade is a health, economic and demographic problem of global proportions. Overweight and obesity cause 3.4 million deaths a year [1]. Classification of obese adults based on body mass index (BMI) (obese class I: BMI 30–34.9; obese class II: BMI 35–39.9; obese class III: BMI ≥ 40) and relative risk assessment of morbidity (elevated, moderately elevated and highly elevated) was made by World Health Organization in 1997. [2]. According to the results of the 2013 Health Survey in the Republic of Serbia, based on the measured BMI, more than half (56.3%) of the population was overweight (35.1% pre-obese and 21.2% obese) [1]. The average BMI value in the adult population of Serbia is 26 ± 4.74 kg/m².

Among the many complications of obesity, respiratory tract disorders are in the shadow of metabolic and cardiovascular complications, so they have been extremely rarely mentioned in our surroundings [3]. Types of respiratory disorders in obese people may be different:

1. respiratory function disorders without alveolar hypoventilation;
2. obesity hypoventilation syndrome (OHS);
3. obstructive sleep apnea syndrome (OSAS);
4. risk during and after surgical interventions [3].

OHS, also historically described as the Pickwickian syndrome (PS), is defined as daytime hypercapnia and hypoxemia (PaCO₂ > 45 mmHg and PaO₂ < 70 mmHg at sea level) in an obese patient (BMI > 30 kg/m²) with sleep-disordered breathing in the absence of any other cause of hypoventilation [4]. OHS is a diagnosis of exclusion. Other causes of hypoventilation, such as chronic obstructive pulmonary disease, severe interstitial lung disease, mechanical respiratory limitation (for example, chest wall disorders such as kyphoscoliosis), myopathies (such as myasthenia gravis), neurological diseases, central causes (such as cerebrovascular disease and untreated hypothyroidism), and congenital causes (such as Ondine's syndrome), should be ruled out. OHS often remains undiagnosed until late in the course of the disease. Its exact prevalence is unknown, but it has been estimated that 10–20% of obese patients with obstructive sleep apnea have hypercapnia [5]. Early recognition is important because these patients have significant morbidity and mortality. Effective treatment can lead to significant improvement in patient outcomes, underscoring the importance of early diagnosis and early treatment [6].

We report a case of prehospitally identified PS with a favorable outcome after hospital treatment.

Received • Примљено:
February 22, 2019

Revised • Ревизија:
November 24, 2019

Accepted • Прихваћено:
November 27, 2019

Online first: November 28, 2019

Correspondence to:

Slađana ANĐELIĆ
Franše d'Eperea 5
11000 Belgrade
Serbia
novizivot94@gmail.com

CASE REPORT

An emergency medical service team intervened because of severe choking of a 67-year-old female patient. She lived alone. The emergency medical service doctor found that the patient is extremely centrally obese (android type), BMI 45.7 kg/cm² (height 170 cm, weight 132 kg), moving with difficulty. In medical history, the patient previously stated difficulties breathing, worsening in the lying position, fatigue even during minor activities, as well as all-day drowsiness. The problems have been more pronounced over the previous seven days. Furthermore, she has urinary incontinence and "swollen stomach". The patient treats hypertension with fasinopril, which she takes irregularly. She had been smoking for the last 40 years (three packs a day). The patient denies any loss of consciousness, allergies, previous pulmonary, otorhinolaryngological, neurological, cardiological, metabolic (diabetes mellitus) and endocrinological diseases, as well as chronic use of sedatives. On examination, the patient is mildly somnolent (Glasgow Coma Score 13), oriented, afebrile, dyspnoic (respiratory rate 20/min.), facial plethora, cyanotic (central cyanosis), anicteric. Patient's aspect was severe. There was weakened respiratory noise above the lungs, crackles basal left, oxygen saturation (SaO₂) 44%. Heart rate was rhythmic, sounds somewhat quieter. Blood pressure was 160/90 mmHg. The palpation of internal abdominal organs was difficult due to pronounced obesity. No peripheral edema. Electrocardiography (ECG): sinus rhythm, heart rate 110/min., S wave in D1 and from V1 to V6, without acute changes in the ST segment. Hundred-percent O₂ is applied through an oxygen mask at a dose of 6 L/min. The patient was transported to hospital under the diagnosis of suspected PS.

On admission to hospital, the patient's status remained unchanged, with slightly corrected SaO₂ (58%). Gas analyses with no oxygen therapy when awake were: pO₂ 56 mmHg, pCO₂ 41 mmHg, pH 7.45. Due to the development of a global respiratory insufficiency (pO₂ 34 mmHg, pCO₂ 67 mmHg, pH 7.24) and the need for ventilatory support, the patient was moved to

the Respiratory Unit. She is initially connected to non-invasive mechanical ventilation. Because of inefficient gas exchange, the patient was intubated and placed on a mechanical ventilator. After being stabilized, the patient was extubated, connected to non-invasive mechanical ventilation and then put on oxygen therapy.

Table 1 shows diagnostic procedures performed during hospitalization. Laboratory test results are shown in Table 2.

The treatment included: therapeutic diet (very-low-calorie diet), crystalloid infusions, electrolytes, antibiotics (ceftazidime, moxifloxacin, vancomycin), anticoagulants (low-molecular-weight heparin, then oral), angiotensin converting enzyme inhibitors, Ca antagonists, gastrointestinal agents and other symptomatic and supportive therapies.

Due to paroxysms of atrial fibrillation (Figure 1), amiodarone was included. The patient was converted to sinus rhythm with occasional paroxysmal atrial fibrillation.

After 30 days of hospital treatment, the patient was released in a satisfactory general condition with recommendation of the following therapy: lifestyle interventions (dietary changes and physical exercise), amiodarone 200 mg 1 × 1 (five days), enalapril 10 mg 2 × 1, amlodipine 5 mg 1 × 1, furosemide 40 mg 1 × 1 with 1 gr KCl, acenocoumarol 1 × 1/2 until international normalized ratio medical check-up (goal international normalized ratio between 2 and 3), pantoprazole 20 mg 1 × 1. The patient had scheduled appointments with a pulmonologist and a cardiologist 15 days after hospital release, and glycemia and Hemoglobin A1c tests after a month.

DISCUSSION

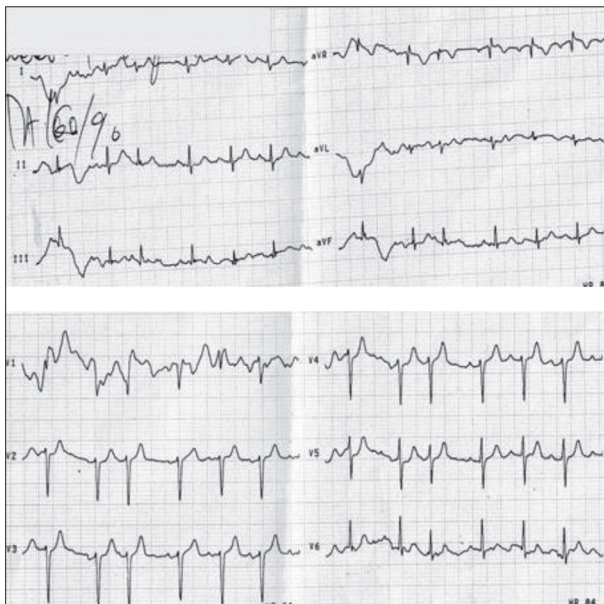
A high suspicion of PS is critical for setting the PS diagnosis [7]. Our patient fulfilled the clinical criteria (SpO₂ 44%, dyspnea on exertion, but also at rest, in unbecoming and uncomfortable positions of the body, facial plethora, elevated level of bicarbonates in the blood). According to

Table 1. Diagnostic test and results

Diagnostic test	Results
Chest x-ray	Left basal accentuated vascular markings with suspected initial signs of consolidation. Slightly voluminous chylous fluid. No signs of pleural effusion.
Echocardiographic examination of the heart complicated by the constitution.	Left pulmonary artery dilated 46 cm seems free. Mitral valve degenerately altered velum, mild mitral regurgitation and transmitral flow in the type of pseudonormalization are recorded. Left ventricle of normal dimensions, hypertrophic walls 14/12mm, preserved global systolic functions ejection fraction 45–50%. The assessment of regional kinetics is difficult but there seems to be no regional asynergy E/e' 13.6. Aortic bulb of normal diameter at the root and the ascendant part with atherosclerotically altered walls. Aortic valve of degenerately altered velum, partly sclerotic, preserved coaptation and disturbed separation. Increased flow rates over aortic valve Vmax 2.26 m/sec, mild aortic stenosis. Dilated right cavities, limit functions right ventricle tricuspid annular plane systolic excursion 22 mm, mild tricuspid regurgitation and systolic pressure in the right ventricle of about 35 mmHg registered. The pericardium is not split. Fat pad in front of the right ventricle.
Abdominal echocardiographic examination	In the accessible part the liver is homogenous, steatosis, without focal lesions. The gallbladder, bile ducts, pancreas, aorta, and retroperitoneal space (not fully visualized) without visible changes. Spleen and both kidneys no appreciable disease. Bladder almost empty, a catheter placed. No free fluid in the abdomen.
Polysomnography	As there was suspicion of sleep apnea syndrome, a sleep study (polysomnography) was attempted, which was interrupted due to a drop in SaO ₂ levels and the necessity to resume oxygen therapy.

Table 2. Laboratory test details

Laboratory test	Result		Laboratory test	Result	
Reference ranges	max.	min.	Reference ranges	max.	min.
WBC 3.9–10 × 10 ⁹ /l	10.8	6.1	Urea 2.8–7.2 mmol/l	10.1	3.7
Neu 40–70%	84.7	70	Cre 53–124 μmol/l	158	86
Eo 0–6%	10		CK 26–192 U/L	2511	33
RBC 3.86–5.08 × 10 ⁹ /l (women)	4.51		CKMB 24 U/L	66	44
Hgb 110–180 g/l	154		ALT 8–41 U/L	63	57
PLT 140–450 × 10 ⁹ /l	189		AST 7–36 U/L	86	33
CRP < 5 mg/l	57.9	10.9	LDH < 241 U/L	353	188
TPI < 0.75 mmol/l	< 0.20		gGT 5–35 U/L (women)	122	51
Na 136–145 mmol/l	140		TP 66–81 g/L	1.36	
Ca 2.25–2.75 mmol/l	1.9		Fe 8.9–30 μmol/l	7	
K 3.5–5 mmol/l	5.2	3.7	UIBC 2 5–59 μmol/l (women)	56	
HCO ₃ 24–29 mmol/l	32		TIBC 49–75 μmol/l (women)	62	
Glu 3.5–6.1 mmol/l	10.1	5	Pro BNP < 125 pg/ml	2800	243
Oncomarkers and thyroid gland hormones are in the reference range					
Microbiological analysis			<i>Corynebacterium spp.</i> – diphtheroids in the smear in the tip of the tubus		
Urine culture sterile					

**Figure 1.** Paroxysmal atrial fibrillation electrocardiography

some data, targeted anamnesis and/or heteroanamnesis have a high sensitivity of 90–100%, but significantly lower specificity: 50–70% [8]. Obesity per se leads to a greater likelihood of diseases such as systemic arterial hypertension, diabetes, dyslipidemia, and hypothyroidism [4]. Additional questions are directed towards sleep, snoring, daily somnolence, possible cyanosis, and pulmonary and

cardiovascular symptoms. In physical examination, respiratory noises are mostly reduced due to a thick layer of subcutaneous tissue on the thorax. In uncomplicated cases, early inspiratory basal crackles can be detected (in our patient on the left side). Heart tones are usually quiet, but during the aggravation of the illness, there may be arrhythmia. The ECG finding in our patient indicates an atrial fibrillation that has been arrested with amiodarone. Frequent finding is arterial hypertension due to obesity, smoking, hypoxemia (in our case SaO₂ was 44%), and other factors. Evidence of right ventricle enlargement from pulmonary hypertension that complicates advanced OHS may be seen on ECG and echocardiogram [9].

History and examination cannot diagnose OHS alone, but it requires the demonstration of daytime hypercapnia [5]. Certain laboratory results complete the anamnesis and physical examination [elevated serum bicarbonate (> 27 mEq/L), hypercapnia (arterial pressure of carbon dioxide PaCO₂ > 45 mmHg), hypoxemia (PaO₂ < 70 mmHg), polycythemia]. Patients suspected of having OHS can initially be screened by pulse oximetry and by determination of serum levels of venous bicarbonate. SpO₂ values < 93% on pulse oximetry would be suggestive of hypoventilation. A serum bicarbonate level ≥ 27 mEq/L had a sensitivity of 92% and a specificity of 50%, justifying its use in screening [10]. A raised bicarbonate (> 27 mmol/L) or base excess (> 3 mmol/L) in the absence of another cause for a metabolic alkalosis in an obese individual with a PaCO₂ < 45 mmHg may be an early indicator of OHS,

warranting closer investigation [11]. We noted similarly. Blood tests are also recommended for the identification of hypothyroidism and polycythemia. A chest radiograph should be performed to exclude parenchymal lung disease, chest wall disease, asymmetrical elevation of a hemidiaphragm (diaphragm paralysis), and cardiomegaly.

The gold standard for diagnosing OSAS is polysomnography, which involves non-invasive measurement of vital parameters during sleep. According to published allegations 90% of PS patients have coexisting OSAS, however, due to unsuccessful polysomnography and missing heteroanamnesis (the patient lived alone), we were unable to confirm this theory [9]. Because symptoms are nonspecific, the diagnosis of PS is frequently delayed. It is commonly misdiagnosed as asthma or chronic obstructive pulmonary disease, and some patients are not diagnosed until hospitalization for acute-on-chronic respiratory failure occurs [12]. However, recent data indicate the OHS is under-recognized and under-treated [13].

In our case, the diagnosis of PS was based on: BMI > 45.7 kg/m², hypercapnia, hypoxemia and respiratory acidosis (pCO₂ 41 mmHg, pO₂ 56 mmHg, pH 7.45) in the absence of other causes of hypoventilation. Comorbidities such as heart failure, coronary artery disease, and

cor pulmonale are more common in patients with OHS, and the likelihood that such patients will require invasive mechanical ventilation or intensive care unit admission is also increased. Non-invasive positive airway pressure, together with weight loss are the initial first line therapies for patients with OHS [14, 15]. After a global respiratory failure had developed, our patient was intubated and placed on a mechanical ventilator. Mortality rate in PS is increased due to the respiratory and cardiac consequences of obesity as such.

It is critical for physicians to be able to recognize and treat obesity-associated diseases because obesity has become a national epidemic. OHS is still a poorly recognized entity in Serbia. Delayed diagnosis of OHS is associated with an increase in morbidity, mortality, and costs of care of patients who are more severely ill.

Informed consent

Written informed consent in Serbian was obtained from the patient for this case report publication, including the accompanying images, case history and data.

Conflict of interest: None declared.

REFERENCES

- Government of the Republic of Serbia. Regulation on the National program for the prevention of obesity in children and adults. Official Gazette of the Republic of Serbia, No. 9/2018.
- Mialich SM, Silva RB, Jordao AA. Cutoff points of BMI for classification of nutritional status using bioelectrical impedance analysis. *J Electr Bioimp.* 2018;9(1):24–30.
- Fernandez C, Manuel A. Obesity, respiratory disease and pulmonary infections. *Ann Res Hosp.* 2017;38(1):1–9.
- Athayde RAB, Oliveira Filho JRB, Lorenzi Filho G, Genta PR. Obesity hypoventilation syndrome: a current review. *J Bras Pneumol.* 2018;44(6):510–8.
- Masa JF, Pépin JL, Borel JC, Mokhlesi B, Murphy PB, Sánchez-Quiroga MA. Obesity hypoventilation syndrome. *Eur Respir Rev.* 2019;28(151):1–14.
- Borel JC, Borel AL, Piper AJ. NERO: a pilot study but important step towards comprehensive management of obesity hypoventilation syndrome. *Thorax.* 2018;73(1):5–6.
- Elsayed AY, El-Shafey MM, Abdelgawad TT, Abdelhady Ali R. Predictors of early diagnosis of obesity hypoventilation syndrome among patients with sleep disordered breathing. *Egypt J Chest Dis Tuberc.* 2017;66(3):453–8.
- Selva A, Sanabria AJ, Pequeño S, Zhang Y, Solà I, Pardo-Hernandez H, et al. Incorporating patients' views in guideline development: asystematic review of guidance documents. *J Clin Epidemiol.* 2017;88:102–12.
- Alawami M, Mustafa A, Whyte K, Alkhatir M, Bhikoo Z, Pemberton J. Echocardiographic and electrocardiographic findings in patients with obesity hypoventilation syndrome. *Intern Med J.* 2015;45(1):68–73.
- BaHammam AS. Prevalence, clinical characteristics, and predictors of obesity hypoventilation syndrome in a large sample of Saudi patients with obstructive sleep apnea. *Saudi Med J.* 2015;36(2):181–9.
- Manuel AR, Hart N, Stradling JR. Is a raised bicarbonate, without hypercapnia, part of the physiologic spectrum of obesity-related hypoventilation? *Chest.* 2015;147(2):362–8.
- Tatusov M, Joseph JJ, Cuneo BM. A case report of malignant obesity hypoventilation syndrome: A weighty problem in our ICUs. *Respir Med Case Rep.* 2016;20:38–41.
- Msaad S, Kammoun S, Hajkacem F, Kammoun R, Masmoudi K, Marakchi R, et al. Reflections on Obesity Hypoventilation Syndrome. *Sleep Disord Ther.* 2018;7(1):1–2.
- Branstiter GW, Lempert NL, Sotomayor T, Crombet O, Murray PJ, Patra KP. Obesity hypoventilation syndrome in a 12-year-old child requiring therapeutic phlebotomy: case report and review of the literature. *Pediatr Int.* 2014;56(6):e99–e101.
- Zubair A, Imran MH, Muhammad K, Tanveer H, Abdul S, Arshad R. Pickwickian syndrome. *EC Pulmonology and Respiratory Medicine.* 2018;7(11):813–5.

Пиквиков синдром – „врх леденог брега“ код екстремно гојазних болесника

Јелена Кашћак, Слађана Анђелић

Градски завод за хитну медицинску помоћ, Београд, Србија

САЖЕТАК

Увод Пиквиков синдром (ПС), познат и као хиповентилациони синдром одраслих, чини тријада: гојазност [*Body Mass Index* (БМИ) > 30 kg/m^2], целодневна хиповентилација и поремећај дисања током спавања у одсуству алтернативних узрока алвеоларне хиповентилације. Благовремено препознавање ПС је од изузетног значаја јер овакви болесници имају знатан морбидитет и морталитет. Међутим, новији подаци указују на то да је ПС недовољно препознат и недовољно лечен. Приказујемо случај рано препознатог ПС на прехоспиталном нивоу са повољним исходом после болничког лечења.

Приказ болесника Шездесетседмогодишњој болесници постављена је прехоспитална дијагноза ПС, која је потврђена и у болници. Дијагностички критеријуми били су: БМИ > 45,7 kg/m^2 (висина 170 *cm*, маса 132 *kg*), хиперкапнија, хипоксемија и респираторна ацидоза (pCO_2 – 41 *mmHg*,

pO_2 – 56 *mmHg*, *pH* 7,45) у одсуству других узрока хиповентилације. Током хоспитализације урађене су следеће дијагностичке процедуре: стандардне лабораторијске анализе, радиографија грудног коша, електрокардиограм, ултразвук срца и абдомена. Покушана студија спавања (полисомнографија) прекинута је због пада SaO_2 (засићеност крви кисеоником). Као прва линија терапије примењене су неинвазивна механичка вентилација и дијета. Међутим, због развоја глобалне респирацијске инсуфицијенције болесница је интубирана и стављена на механички вентилатор. После 30 дана болничког лечења отпуштена је кући у задовољавајућем општем стању са препоруком за редукцију телесне тежине и применом симптоматске терапије.

Закључак Гојазност постаје епидемија савременог друштва, те је од кључног значаја рано препознавање и лечење ПС.

Кључне речи: гојазност; Пиквиков синдром; рано препознавање; лечење