



ORIGINAL ARTICLE / ОРИГИНАЛНИ РАД

Corneal collagen cross-linking in pediatric patients with keratoconus

Svetlana Stanojlović^{1,2}, Vedrana Pejin¹, Tanja Kalezić^{1,2}, Jelica Pantelić^{1,2}, Borivoje Savić²¹University of Belgrade, Faculty of Medicine, Belgrade, Serbia;²Clinical Center of Serbia, Clinic for Eye Diseases, Belgrade, Serbia**SUMMARY**

Introduction/Objective The aim of this study was to report visual, refractive, and tomographic outcomes of corneal collagen cross-linking (CXL) in pediatric keratoconus.

Methods This retrospective study included 17 eyes of 12 patients with progressive keratoconus who underwent epithelium-off CXL at the age ≤ 18 years. Following data were analyzed at baseline and postoperatively at one, three, six, nine, 12 months for all the patients, and annually where available: uncorrected distant visual acuity (UDVA) and best spectacle-corrected distant visual acuity (CDVA), refraction and corneal tomography.

Results Mean UDVA improved significantly from 0.52 ± 0.38 at baseline to 0.24 ± 0.29 logarithm of minimum angle resolution (log MAR) at one year ($p = 0.011$) and remained stable at two-year follow-up (0.21 ± 0.34 log MAR). Mean CDVA was 0.15 ± 0.21 at baseline and 0.06 ± 0.13 log MAR at one year ($p = 0.248$). Maximum keratometry showed a significant flattening of 1.30 ± 1.99 D ($p = 0.011$) after a year and remained stable two years after CXL. Minimum keratometry significantly decreased with a mean change of 1.34 ± 1.37 ($p = 0.001$). Mean reduction of corneal thickness after CXL was 55.35 ± 64.42 μm ($P = 0.003$). After a year, seven (42%) eyes showed Kmax regression, nine (53%) stabilization, and one (5%) progression.

Conclusion In our study CXL effectively prevented progression of keratoconus in 95% of pediatric patients after a year, while improving UDVA and keratometry values. One patient with eye rubbing behavior showed signs of keratoconus progression after CXL treatment.

Keywords: corneal collagen cross-linking; keratoconus; pediatric patients; CXL

INTRODUCTION

Keratoconus is a progressive, bilateral, and most commonly asymmetric ectatic disorder associated with localized corneal thinning and protrusion [1]. Keratoconus usually begins in puberty and progress during adolescence. Progression of keratoconus with subsequent corneal steepening induces irregular astigmatism and myopia leading to a decrease in visual acuity. Indeed, earlier age of onset is associated with faster progression. Keratoconus severity was also greater at the time of diagnosis in children and adolescents; almost 30% of pediatric keratoconus presented at stage four compared with 8% of their adult counterparts [2]. Therefore, it is critical to perform corneal collagen cross-linking (CXL) as early as possible to stop progression of pediatric keratoconus. The introduction of this procedure reduced the need for penetrating keratoplasty, which is usually required for advanced cases of keratoconus. This is particularly important for children since it was found that younger age is associated with a sevenfold increased risk of corneal transplantation [2].

The biomechanical resistance of the cornea in keratoconus is only 60% of the normal cornea [3]. Corneal CXL using ultraviolet light A and riboflavin as the photosensitizer was introduced by Wollensak et al. [4]. This treatment is aimed to increase the biomechanical stiffening

of the cornea and its biomechanical resistance to collagenase activity [5, 6]. The safety and efficacy of CXL for keratoconus has already been demonstrated in both adults and children [7, 8]. However, CXL in pediatric patients with keratoconus has been significantly less studied. It was also suggested that the effect of CXL in children may be temporary [7].

The aim of this study was to evaluate visual, refractive, and tomographic outcomes after standard corneal CXL for progressive keratoconus in patients younger than 19 years of age.

METHODS**Patients and methods**

This retrospective study was conducted in compliance with the institutional review board regulations, informed consent regulation and adhered to the tenets of the Declaration of Helsinki. Our single-centered study comprised 17 eyes of 12 pediatric patients with progressive keratoconus who underwent an epithelium-off CXL at the age ≤ 18 between June 2015 and June 2017. These patients were followed up one, three, six, nine months, and one year postoperatively (all patients, and annually where available).

A diagnosis of keratoconus was based on clinical findings and/or corneal images obtained

Received • Примљено:
January 8, 2019

Revised • Ревизија:
October 8, 2019

Accepted • Прихваћено:
November 19, 2019

Online first: November 26, 2019

Correspondence to:

Svetlana STANOJLOVIĆ
Clinic for Eye Diseases
Clinical Center of Serbia
Pasterova 2
11000 Belgrade, Serbia
stanojlovic.svetlana@gmail.com

by the Orbscan IIz Corneal Tomographer (Orbtek; Baush and Lomb, Salt Lake City, UT, USA). All patients underwent a complete ophthalmic evaluation before CXL and at all follow-up visits after undergoing CXL. Data analysis included uncorrected distant visual acuity (UDVA), best spectacle-corrected distant visual acuity (CDVA), refraction (spherical equivalent, refractive astigmatism), corneal tomography, slit-lamp evaluation and particularly associated allergic conjunctivitis. All UDVA and CDVA were recorded using Snellen chart and then converted to log MAR for statistical analysis. The following tomographic parameters were analyzed: simulated keratometry (SimK), maximum keratometry (Kmax), minimum keratometry (Kmin), minimum corneal thickness (MCT), anterior and posterior best-fit-sphere (ABFS and PBFS respectively), radius of anterior and posterior BFS, highest posterior elevation (HPE). The magnitude of highest posterior elevation was noted using the cursor within the central 8 mm zone in the best-fit-sphere map. The preoperative cone location was determined by the location of the highest posterior elevation. If it was within central 3 mm zone, it was termed a central cone. If it was outside this zone, it was termed paracentral (within central 3–5 mm zone) and peripheral (outside central 5 mm zone). The Amsler-Krumeich classification based on average keratometry was used to classify keratoconus as mild (< 48 D), moderate (48–53 D) and severe (> 53 D).

Inclusion criteria were pediatric patients underwent CXL in one or both eyes at the Clinic for Eye Diseases affiliated to the University of Belgrade and being followed up for at least one year. Exclusion criteria was preoperative minimum corneal thickness less than 350 μm . Changes in Kmax were defined as Kmax regression (> 1 D decrease in Kmax), Kmax stabilization (< 1 D change in Kmax), and Kmax progression (> 1 D increase in Kmax), as described by Koller et al. [9].

Surgical procedure

CXL with riboflavin and ultraviolet A (UV-A) was performed according to the standard (Dresden) protocol [4]. Inclusion criteria was preoperative minimum corneal thickness $\geq 400 \mu\text{m}$ (16 eyes of 11 patients). Most children were able to successfully tolerate surgical procedure under topical anesthesia alone, while adjunctive sedation before the procedure was required in 4 eyes of 2 patients. After insertion of lid speculum, an 8-mm marker was used to mark the central corneal epithelium; then the epithelium was removed with a blunt metal spatula and isotonic 0.1% riboflavin-20% dextran solution (10 mg riboflavin-5-phosphate in 10 ml dextran solution) was applied for 30 minutes at two-minute intervals. Ultrasonic pachymetry was obtained immediately after central epithelial removal and 30 minutes after the start of riboflavin drops. If the thinnest corneal thickness was less than 400 μm , hypotonic riboflavin was applied until the thinnest corneal stroma had swollen to 400 μm . Central cornea was then exposed to UV-A irradiation using a UV light lamp (Intacs XL corneal crosslinking system, Addition Technology, Des Plaines, IL,

USA) at 3 mW/cm² for 30 minutes (5.4 J/cm² total energy dosage) with reapplication of isotonic riboflavin solution every three minutes to ensure saturation. At the end of surgery, a therapeutic soft contact lens was applied until reepithelization of the cornea was completed. The postoperative treatment included ofloxacin eye drops four times a day (qid) for a week; fluorometholone eye drops qid with taper a month and artificial tears qid for six months.

In one eye a technique of contact lens-assisted collagen cross-linking (CACXL) was applied due to the estimated preoperative corneal thickness < 400 μm (367 μm). Surgical procedure was performed as previously described by Jacob et al. [10]. Briefly, after epithelial removal, isotonic 0.1% riboflavin-20% dextran solution was applied every two minutes for 30 minutes. An ultraviolet barrier-free soft contact lens (0.09 mm thickness, 14 mm diameter) soaked in isotonic 0.1% riboflavin for 30 minutes was placed on the cornea. Once the minimum corneal thickness with the contact lens was confirmed to be greater than 400 μm , CXL was proceeded. The UVA irradiance was performed for the next 30 minutes with reapplication of isotonic 0.1% riboflavin over and underneath the contact lens every three minutes. Postoperative treatment included soft contact lens and antibiotic drops as previously described for children underwent standard Dresden protocol.

RESULTS

A total of 17 eyes of 12 patients with the average age at surgery of 15 ± 1.7 years (range: 13–18) were included in this study. There were one (8.3%) female and 11 (91.7%) male patients. Preoperative, and follow-up data at one, three, six, nine and 12 months was available for all patients; two-year follow-up was available for eight patients; three-year follow-up for four patients. Tomographic values from patients exceeding one year of follow up are presented but have not been subjected to statistical analysis, as the sample size was considered insufficient. The changes in visual acuity, refractive and tomographic variables at baseline and one year after CXL are demonstrated in Tables 1 and 2.

Table 1. Preoperative and postoperative one-year visual acuity and refractive values and their statistical significance

Parameter	Preoperative	Postoperative (1 year)	p
UDVA (logMAR)	0.52 \pm 0.38	0.24 \pm 0.29	0.011
CDVA (logMAR)	0.15 \pm 0.21	0.06 \pm 0.13	0.248
Spherical Eq., D	-2.83 \pm 2.15	-2.42 \pm 1.89	0.67
Refractive astig., D	-2.69 \pm 3.6	-4.0 \pm 1.64	0.61

UDVA – uncorrected distance visual acuity; CDVA – corrected distance visual acuity; Spherical Eq. – spherical equivalent; Refractive astig. – refractive astigmatism

Eight patients (11 eyes) had a history of asthma and hay fever, three patients had no history of allergic eye diseases (five eyes), whereas one patient (one eye) had a history of eye rubbing behavior without atopy.

Interestingly, 13 eyes of 10 patients (76.5%) presented at stage two at the time of diagnosis with average Kmax

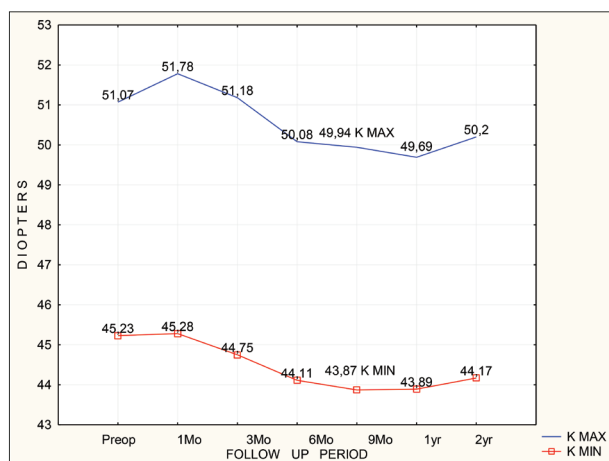


Figure 1. Changes in Kmax and Kmin over a two-year follow-up period; Kmax – maximum keratometry; Kmin – minimum keratometry

of 49.67 ± 1.48 D, whereas only four eyes of three patients (23.5%) presented at stage three, showing average Kmax of 55.62 ± 1.50 D. All patients had cone located inside the central 3 mm topographic zone.

Visual acuity and refraction

Mean UDVA improved significantly from 0.52 ± 0.38 at baseline to 0.24 ± 0.29 log MAR after a year ($p = 0.011$) (Table 1) and remained stable at the two-year follow-up (0.21 ± 0.34 log MAR). Mean spectacle CDVA was 0.15 ± 0.21 at baseline and 0.06 ± 0.13 log MAR after a year. However, this improvement was not significant ($p = 0.248$).

The mean preoperative and postoperative spherical equivalent and refractive astigmatism data are shown in Table 1. There was no significant difference between the preoperative and postoperative refractive values as well ($p > 0.05$). Mean spherical equivalent was 2.42 ± 1.89 D ($p = 0.67$); mean refractive cylinder was 4.0 ± 1.64 D ($p = 0.61$) after a year.

Tomography

Maximum keratometry value showed a significant flattening of 1.30 ± 1.99 D ($P = 0.011$) at one year and remained stable at two year follow-up (Figure 1). The baseline and follow-up measurements demonstrated that Kmax value decreased significantly six months after CXL and this improvement remained stable afterwards (Figure 1). Minimum keratometry value significantly decreased with a mean change of 1.34 ± 1.37 at one year compared with baseline ($p = 0.001$). A significant flattening of Kmin was observed at three month ($p = 0.039$) and remained statistically significant along the entire follow-up period (Figure 1). The SimK average values showed statistically significant worsening after three months, after CXL ($p = 0.036$), becoming statistically insignificant after the sixth month until the end of follow-up period (Table 2).

As presented in Table 2, compared with the baseline, the mean anterior elevation BFS decreased significantly one year after CXL ($p < 0.01$). In contrast, a significant

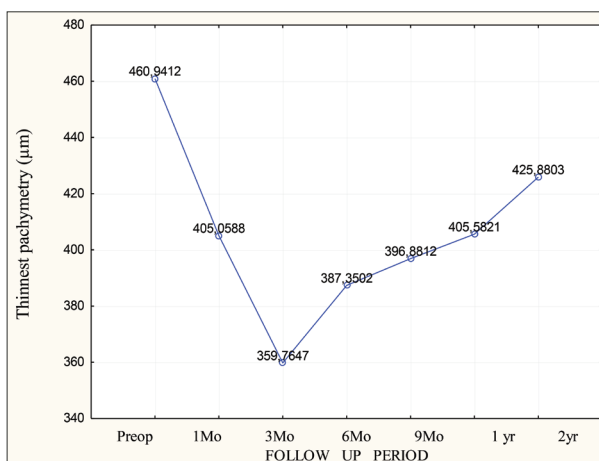


Figure 2. Changes in the thinnest corneal pachymetry over a two-year follow-up period

Table 2. Preoperative and postoperative one-year corneal tomography values and their statistical significance

Parameter	Preoperative	Postoperative (1 year)	p
SimK, D	5.52 ± 2.04	5.68 ± 1.89	0.702
Kmax, D	51.07 ± 2.97	49.69 ± 3.11	0.011
Kmin, D	45.23 ± 2.31	43.89 ± 2.57	0.011
MCT, µm	460.94 ± 44.94	405.58 ± 86.86	0.003
ABFS, D	42.79 ± 1.01	42.23 ± 1.33	0.003
ABFSr, mm	7.88 ± 0.2	7.95 ± 0.23	0.002
PBFS, D	53.7 ± 2.03	55.25 ± 1.95	0.008
PBFSr, mm	6.29 ± 0.23	6.11 ± 0.26	0.008
HPE, mm	0.2 ± 0.29	0.09 ± 0.04	0.658

SimK – simulated keratometry; Kmax – maximum keratometry; Kmin – minimum keratometry; MCT – minimal corneal thickness; ABFS – anterior best-fit-sphere; ABFSr – radius of the anterior best-fit-sphere; PBFS – posterior best-fit-sphere; PBFSr – radius of the posterior best-fit-sphere; HPE – highest posterior elevation

steepening of posterior elevation BFS was observed a year after CXL treatment ($p < 0.01$).

After a year, in comparison with baseline values, seven (42%) eyes showed Kmax regression; nine (53%), stabilization; and one (5%), progression. Keratoconus progressed in one eye with steepening of >1 D in both orthogonal meridians at one year. Interestingly, at one year majority of treated eyes (12/17) showed flattening of Kmin in combination with either stabilization (six eyes) or regression (six eyes) of the steeper orthogonal meridian. At two-year follow up, five out of eight eyes showed stabilization of both orthogonal meridians, whereas in three eyes regression ≥ 1 D of both, Kmax and Kmin meridian, was observed.

Pachymetry

Average preoperative pachymetry at the thinnest point as measured by Orbscan was 460.94 ± 44.95 µm. Only one patient had pachymetry value under 400 µm (368 µm). The changes of pachymetry over time are shown in Figure 2. There was a significant reduction of minimum corneal thickness after CXL in comparison with baseline values, with a mean reduction of 55.35 ± 64.42 µm after a year ($p = 0.003$) (Table 2).

Statistical analysis

Statistical analysis was performed using the SPSS software (IBM Corp. Armonk, NY, USA) version 23.0. The significance of the difference between the preoperative and postoperative variables was tested using a two-tailed paired samples Student's *t* test. The value of $p < 0.5$ was considered statistically significant. All values were expressed as mean \pm SD. Visual acuity was converted to logMAR for statistical analysis.

DISCUSSION

Different studies have confirmed that standard epithelium-off CXL protocol is safe and effective for the treatment of pediatric keratoconus [11]. Due to the rarer corneal stiffness in pediatric population, CXL is not as effective in children as it is in adults [12]. Recently, a 24% regression rate was contemplated in patients who were aged 15 years and younger at the time of inclusion in the treatment protocol [13].

In our study, we evaluated visual, refractive, and tomographic results in a group of pediatric patients with a mean age of 15 ± 1.7 years who had been treated with corneal CXL for progressive keratoconus. Majority of eyes (76.5%) presented at stage two at time of diagnosis with average K_{max} of $49.67 \pm 1.48D$. Both UDVA and CDVA improved at the one-year follow-up and remained stable two years after CXL procedure; however, the improvement in CDVA was not statistically significant. Similar to other studies [7, 8, 14], spherical equivalent and refractive astigmatism did not show any significant differences in comparison with preoperative values. Although the main objective of CXL treatment is to prevent keratoconus progression, flattening of the cornea is commonly reported [7, 15]. In ours, as well as in similar studies [8, 16], initial steepening of both keratometric indices, K_{max} and K_{min} was observed during the first three months. This has been suggested to be the result of early epithelial remodeling [17]. We also demonstrated continuous improvement in corneal topographic values with significant flattening of both K_{max} and K_{min} a year following CXL procedure; however, slight steepening was noticed after two years for available patients (eight eyes). This is in accordance with the results of previous studies with a follow-up duration ranging from one to three years [16]. Improvement in keratometric values was associated with significant decrease of ABFS suggesting global corneal flattening as well. Although PBFS increased at one-year follow up, no significant variation of highest posterior elevation has been observed indicating the effectiveness of the CXL treatment.

Interestingly, majority of eyes in our study (12/17) demonstrated flattening of K_{min} in combination with either stabilization or regression of the K_{max} . Corneal response to CXL treatment showed wide variability in reported studies and this was also observed in ours. Vinciguerra et al. [8] reported significant flattening of the flatter meridian but not of the steeper meridian at the two-year follow up. Some

other studies and ours also demonstrated no significant differences in simulated keratometry at one-year follow-up.

In pediatric patients, keratoconus is often more advanced in the worse-affected eye at diagnosis as compared with adult patients [2]. Chatzis and Hafezi [7] found a preoperative progression rate of 88% and recommended CXL treatment as soon as the diagnosis of keratoconus has been confirmed in children. In our study, all children subjected to CXL treatment had history of significant visual impairment accompanying keratoconus progression. We generally perform pediatric corneal CXL at presentation in the eye with more advanced stage of keratoconus, rather than to wait for documented progression. Until the age of 16, all patients were followed at three-month intervals. Serial tomographies were performed for both treated and untreated eyes to identify early keratoconus progression, which may occur after CXL as well. Chatzis and Hafezi [7] also observed that an initially significant improvement in K_{max} in the first two years was lost by the third year in pediatric keratoconus.

In our case series, 42% of eyes showed keratoconus regression a year after the standard epi off CXL treatment, which was manifested as flattening of the steepest keratometry meridian more than 1D; whereas, 53% of treated eyes remained stable with average changes in K_{max} less than 1D. One patient with compulsive eye rubbing behavior (5%), showed signs of keratoconus progression after CXL treatment with an increase of both orthogonal meridians. Allergy, atopy, and eye rubbing are identified as possible causes of keratoconus progression after CXL treatment [2, 18]. Therefore, patients should be counseled to avoid eye rubbing. The paracentral cone location and the thinnest corneal thickness below 450 μm were also linked to possible keratoconus progression [19]. However, all patients in our case series exhibited central topographic pattern. The average minimum pachymetry corneal thickness was $460.94 \pm 44.95 \mu m$. The CXL procedure was well tolerated by all patients with corneal re-epithelization completed three days postoperatively. We did not observe any side effects of the procedure. Mild temporarily corneal haze was noticed in all patients. This was also described in similar studies [13, 20].

For pediatric keratoconus, it is of vital importance to avoid more aggressive procedures, such as keratoplasty, even in patients with advanced form of the disease. Jacob et al. [10] have recently described CACXL technique for performing cross-linking in thin corneas with less than 400 microns after epithelial abrasion. Endothelial cell counts have been shown to remain unaffected after CACXL [10]. Here we also observed that CACXL was effective and safe in stabilization of keratoconus progression at one-year follow up in a patient with minimum corneal thickness of 367 microns. Alternative protocols, such as transepithelial CXL may also be effective in stabilizing corneal topography [21]. However, several studies showed inferior efficacy of the epithelium on CXL procedure in comparison with standard CXL treatment [22, 23]. Due to the reduced treatment time, accelerated CXL is also likely to be better tolerated in pediatric patients than standard CXL treatment.

The long-term efficacy of accelerated pediatric CXL is yet to be determined.

CONCLUSION

We confirmed efficacy and good safety profile of pediatric corneal CXL. In this age group, keratoconus remained stable without signs of progression in 95% of eyes following standard epithelium off CXL treatment at the two-year follow up. Keratoconus in younger patients is often more aggressive and the effect of CXL may be temporary. Progression of pediatric keratoconus after CXL may also

be related to the intense eye rubbing habit. Furthermore, special attention should be given to the pediatric population with more advanced stages of keratoconus. Alternative protocols, such as contact lens assisted CXL might be considered in eyes with thin cornea.

NOTE

This work was presented in part at the annual meeting of the Serbian Society of Ophthalmology, Kopaonik, 2018.

Conflict of interest: None declared.

REFERENCES

- Rabinowitz YS. Keratoconus. *Surv Ophthalmol.* 1998; 42(4):297–319.
- Léoni-Mesplé S, Mortemousque B, Touboul D, Malet F, Praud D, Mesplé N, et al. Scalability and severity of keratoconus in children. *Am J Ophthalmol.* 2012; 154(1):56–62.e1.
- Andreassen TT, Simonsen AH, Oxlund H. Biomechanical properties of keratoconus and normal corneas. *Exp Eye Res.* 1980; 31(4):435–41.
- Wollensak G, Spoerl E, Seiler T. Riboflavin/ultraviolet-a-induced collagen crosslinking for the treatment of keratoconus. *Am J Ophthalmol.* 2003; 135(5):620–7.
- Wollensak G, Spoerl E, Seiler T. Stress-strain measurements of human and porcine corneas after riboflavin-ultraviolet-A-induced cross-linking. *J Cataract Refract Surg.* 2003; 29(9):1780–5.
- Spoerl E, Wollensak G, Seiler T. Increased resistance of crosslinked cornea against enzymatic digestion. *Curr Eye Res.* 2004; 29(1):35–40.
- Chatzis N, Hafezi F. Progression of keratoconus and efficacy of pediatric corneal collagen cross-linking in children and adolescents. *J Refract Surg.* 2012; 28(11):753–8.
- Vinciguerra P, Albé E, Frueh BE, Trazza S, Epstein D. Two-year corneal cross-linking results in patients younger than 18 years with documented progressive keratoconus. *Am J Ophthalmol.* 2012; 154(3):520–6.
- Koller T, Pajic B, Vinciguerra P, Seiler T. Flattening of the cornea after collagen crosslinking for keratoconus. *J Cataract Refract Surg.* 2011; 37(8):1488–92.
- Jacob S, Kumar DA, Agarwal A, Basu S, Sinha P, Agarwal A. Contact lens-assisted collagen cross-linking (CACXL): A new technique for cross-linking thin corneas. *J Refract Surg.* 2014; 30(6):366–72.
- McAnena L, Doyle F, O'Keefe M. Cross-linking in children with keratoconus: a systematic review and meta-analysis. *Acta Ophthalmol.* 2017; 95(3):229–39.
- Kamiya K, Shimizu K, Ohmoto F. Effect of aging on corneal biomechanical parameters using the ocular response analyzer. *J Refract Surg.* 2009; 25(10):888–93.
- Mazzotta C, Traversi C, Baiocchi S, Bagaglia S, Caporossi O, Villano A, et al. Corneal Collagen Cross-Linking With Riboflavin and Ultraviolet A Light for Pediatric Keratoconus: Ten-Year Results. *Cornea.* 2018; 37(5):560–6.
- Caporossi A, Mazzotta C, Baiocchi S, Caporossi T, Denaro R, Balestrazzi A. Riboflavin-UVA-induced corneal collagen cross-linking in pediatric patients. *Cornea.* 2012; 31(3):227–31.
- Chunyu T, Xiujun P, Zhengjun F, Xia Z, Feihu Z. Corneal collagen cross-linking in keratoconus: a systematic review and meta-analysis. *Sci Rep.* 2014; 10(4):5652.
- Padmanabhan P, Rachapalle Reddi S, Rajagopal R, Natarajan R, Iyer G, Srinivasan B, et al. Corneal Collagen Cross-Linking for Keratoconus in Pediatric Patients-Long-Term Results. *Cornea.* 2017; 36(2):138–43.
- Rocha KM, Perez-Straziota CE, Stulting RD, Randleman JB. Epithelial and stromal remodeling after corneal collagen cross-linking evaluated by spectral-domain OCT. *J Refract Surg.* 2014; 30(2):122–7.
- Léoni-Mesplé S, Mortemousque B, Mesplé N, Touboul D, Praud D, Malet F, et al. Epidemiological aspects of keratoconus in children. *J Fr Ophtalmol.* 2012; 35(10):776–85.
- Sarac O, Caglayan M, Cakmak HB, Cagil N. Factors Influencing Progression of Keratoconus 2 Years After Corneal Collagen Cross-Linking in Pediatric Patients. *Cornea.* 2016; 35(12):1503–7.
- Knutsson KA, Paganoni G, Matuska S, Ambrosio O, Ferrari G, Zennato A, et al. Corneal collagen cross-linking in paediatric patients affected by keratoconus. *Br J Ophthalmol.* 2018; 102(2):248–52.
- Filippello M, Stagni E, O'Brart D. Transepithelial corneal collagen crosslinking: bilateral study. *J Cataract Refract Surg.* 2012; 38(2):283–91.
- Soeters N, Wisse RP, Godefrooij DA, Imhof SM, Tahzib NG. Transepithelial versus epithelium-off corneal cross-linking for the treatment of progressive keratoconus: a randomized controlled trial. *Am J Ophthalmol.* 2015; 159(5):821–8.e3.
- Leccisotti A, Islam T. Transepithelial corneal collagen cross-linking in keratoconus. *J Refract Surg.* 2010; 26(12):942–8.

Корнеални колагени крос-линкинг код педијатријских болесника са кератоконусом

Светлана Станојловић^{1,2}, Ведрана Пејин¹, Тања Калезић^{1,2}, Јелица Пантелић^{1,2}, Боривоје Савић²

¹Универзитет у Београду, Медицински факултет, Београд, Србија;

²Клинички центар Србије, Клиника за очне болести, Београд, Србија

САЖЕТАК

Увод/Циљ Циљ овог рада био је да прикажемо видну оштрину, рефракционе и томографске резултате после корнеалног колагеног крос-линкинга (ККЛ) због прогресивног кератоконуса код деце.

Метод Ретроспективна студија обухватила је 17 очију код 12 болесника узраста до 18 година код којих је урађен ККЛ са уклањањем епитела. Анализирани су преоперативни и постоперативни подаци свих болесника који су добијени на прегледима један месец, три месеца, шест, девет и 12 месеци после урађеног ККЛ, као и једном годишње код болесника са дужим периодом праћења. Анализа је обухватила некориговану видну оштрину (НКВО), најбоље кориговану видну оштрину (КВО), рефракцију и корнеалну томографију.

Резултати Средња НКВО значајно се побољшала од $0,52 \pm 0,38$ до $0,24 \pm 0,29$ логаритама минималног угла резолуције (логМУР) после годину дана ($p = 0,011$). Ова вредност остала је стабилна до краја друге године праћења ($0,21 \pm 0,34$ логМУР).

Преоперативна средње КВО износила је $0,15 \pm 0,21$ логМУР, а годину дана после ККЛ $0,06 \pm 0,13$ логМУР ($p = 0,248$). Највећа средња кератометријска вредност смањила се за $1,30 \pm 1,99$ Д ($p = 0,011$). Најмања кератометријска вредност смањила се за $1,34 \pm 1,37$ Д ($p = 0,001$). Дебљина рожњаче смањила се за $55,35 \pm 64,42$ микрометра ($p = 0,003$). После годину дана седам (42%) очију показало је смањење максималне кератометријске вредности; девет (53%) стабилизацију максималне кератометријске вредности; једно (5%) око напредовање кератоконуса.

Закључак У нашој студији ККЛ је ефикасно спречио напредовање кератоконуса код 95% педијатријских болесника уз побољшање НКВО и кератометријских вредности. Код једног болесника, који има навику да трља очи, дошло је до напредовања кератоконуса после крос-линкинга рожњаче.

Кључне речи: корнеални колагени крос-линкинг; кератоконус; педијатријски болесници