

ORIGINAL ARTICLE / ORIGINARNI RAD

Upper and lower gastrointestinal endoscopy in patients with iron deficiency anemia

Dušan Đ. Popović^{1,2}, Simon Zec², Ivan V. Ranković¹, Tijana M. Glišić^{1,2}, Tamara M. Milovanović^{1,2}¹Clinical Centre of Serbia, Clinic for Gastroenterology and Hepatology, Belgrade, Serbia;²University of Belgrade, Faculty of Medicine, Belgrade, Serbia**SUMMARY****Introduction/Objective** The most common cause of iron deficiency anemia (IDA) in both men and postmenopausal women are gastrointestinal diseases.

This study aimed to determine the frequency of pathological and diagnostic findings observed on esophagogastroduodenoscopy (EGDS) and colonoscopy in IDA patients, and examine associations between demographic, anamnestic, and clinical features, with findings found on endoscopy.

Methods A retrospective cross section study of patients with IDA was conducted.**Results** Eighty-five patients with IDA were included, mean age of 60.3 ± 18.8 years, with 51.8% being women. Esophagogastroduodenoscopy, colonoscopy, or both was performed in 96.5%, 71.8%, and 70.6% of patients, respectively. The cause of IDA was established in 65.9% of cases. Diagnostic findings were observed in those who underwent EGDS, colonoscopy, or both in 43.9%, 47.5%, and 15.9% of patients, respectively. Diagnostic findings on EGDS were significantly more common in patients older than 50 years than in younger patients ($p = 0.031$). Patients with a diagnostic finding on colonoscopy more commonly reported weight loss ($p = 0.046$) and change in bowel habit ($p = 0.012$), alongside positive fecal occult blood test (FOBT; $p = 0.012$); they rarely had anemia previously ($p = 0.001$), rarely used iron supplements ($p = 0.022$), and were more likely to have malignancy in their past medical history ($p = 0.043$).**Conclusion** Diagnostic findings on EGDS were more commonly observed in older patients, while diagnostic findings on colonoscopy were more common in those with weight loss, change in bowel habit, positive FOBT, and prior malignancy. Colonoscopy was more often diagnostic in patients without anemia or iron supplementation in the past.**Keywords:** anemia; endoscopy; neoplasm; angiodysplasia**INTRODUCTION**

Iron deficiency anemia (IDA) is the most common type of anemia. It is estimated that its incidence in the general population is 12% and 23% in the population of hospitalized patients [1–4]. Approximately 1–5% of men, and 5–12% of women who are not pregnant have IDA [5, 6, 7]. In premenopausal women, the most common cause of IDA is menstrual bleeding, whereas in both men and postmenopausal women, the underlying cause is most often gastrointestinal blood loss [7, 8].

This study aimed to determine the frequency of pathological and diagnostic findings observed on esophagogastroduodenoscopy (EGDS) and colonoscopy in IDA patients, and examine associations between demographic, anamnestic and clinical features, with findings found on endoscopy.

METHODS

A retrospective cross section study was conducted for one year, from January 2014 to January 2015, at the Clinic for Gastroenterology and Hepatology, Clinical Center of Serbia.

The inclusion criterion was IDA. Anemia was defined as a reduction in hemoglobin level below 130 g/L or hematocrit level below 0.40 for men, and hemoglobin level below 120 g/L or hematocrit level below 0.35 for women [2]. IDA was defined as an anemia with the following characteristics: reduced serum iron (men $< 11 \mu\text{mol/L}$; women $< 7 \mu\text{mol/L}$), decreased ferritin (men $< 20 \mu\text{g/L}$; women $< 10 \mu\text{g/L}$), transferrin saturation ($< 15\%$), elevated total iron binding capacity ($> 75.1 \mu\text{mol/L}$), elevated transferrin receptor ($> 1.76 \text{ mg/L}$) and/or reduced mean corpuscular volume ($< 80 \text{ fL}$). The exclusion criteria were the age < 18 years and the presence of another disease as the obvious cause of IDA. Patients with malignancy in the past medical history were only included if more than five years had passed since oncological treatment, and if they did not have a recurrence of the primary tumor.

A review of medical records was performed and the collected data included demographic, anamnestic and clinical data, as well as the results of endoscopic examination. Demographic data included sex and age. The anamnesis data included symptoms (including manifest bleeding), drug use, past medical history and comorbidities, and family history. Clinical data

Received • Примљено:

March 25, 2019

Revised • Ревизија:

July 3, 2019

Accepted • Прихваћено:

July 26, 2019

Online first: August 14, 2019**Correspondence to:**Tamara MILOVANOVIĆ
Clinical Center of Serbia
Clinic for Gastroenterology and
Hepatology
2 Dr. Koste Todorovica St.
Belgrade 11000
Serbiatamara.alempijevic@med.bg.ac.rs

included physical examination of the abdomen, digital rectal examination, and laboratory analysis (complete blood count, serum iron, total iron binding capacity, ferritin, transfer saturation, soluble transfer receptors, and fecal occult blood test). Laboratory analyzes were carried out at the Center for Medical Biochemistry, Clinical Center of Serbia.

The results of endoscopy were stratified into three groups: normal finding, pathological finding, and diagnostic finding.

Pathological finding was categorized as pathological changes which may or may not have been the underlying cause of IDA. Diagnostic findings were those which definitively established the cause of IDA. On EGDS diagnostic findings included severe esophagitis (grade 3 and 4 by Savary–Miller) with traces of blood/hematoma in the lumen of the gastrointestinal tract (GIT), esophageal varices with red spots, more serious form of erosive gastritis or duodenitis, ulcers (esophageal, gastric or duodenal), adenomatous polyps of at least 20 mm diameter, vascular ectasias, gluten-sensitive enteropathy and active inflammatory bowel disease (localized to esophagus, stomach, and duodenum) [7–10]. Based on data from previous studies, the findings of milder forms of esophagitis, hiatus hernia, esophageal varices without red spots, mild forms of erosive gastritis and duodenitis, and the presence of smaller polyps were classified as pathological rather than diagnostic findings on EGDS [7, 8, 11].

The diagnostic finding category on colonoscopy included: neoplasms (colon or terminal ileum), one or more polyps with a diameter > 15 mm, active colonic ulceration > 10 mm, vascular ectasias, inflammatory bowel disease, post radiation colitis and active colitis [7, 9, 12]. The findings of uncomplicated colonic diverticulosis, non-bleeding hemorrhoids, and small colonic polyps were classified into the pathological finding group, and were not diagnostic [7, 8].

Statistics

Descriptive and analytical statistics were used. Continuous variables were described as the average value \pm standard deviation, while frequency and proportions were utilized for discontinuous variables. The normality of the distribution for continuous variables was evaluated by the Kolmogorov–Smirnov test. To estimate the significance of the differences between continuous variables with a normal distribution, the t-test for independent samples was employed, while the Mann–Whitney U-test was used as a non-parametric alternative. Significance for categorical variables was assessed with the χ^2 test or, in the case of numerical constraints, the Fisher test. Significant difference was indicated as $p < 0.05$.

Ethics

The study was conducted according to the Declaration of Helsinki. The study was approved by the Collegium of the Clinic for Gastroenterology and Hepatology, Clinical Centre of Serbia, and the Council for Specialist Studies, Medical Faculty in Belgrade (04 Nr: 14-UGT-08, 23.12.2015).

RESULTS

Demographic data

The study included 85 patients with IDA. The average age of the patients was 60.3 ± 18.8 years (range 18–87 years). Of the total number of subjects, 51.8% ($n = 44$) were women.

Anamnestic data

The most commonly reported general symptoms were malaise and/or fatigue, as well as weight loss. The gastrointestinal-specific symptoms were present in 65.9% ($n = 56$) of the patients, the most common of which being abdominal pain and change in bowel habit. An active episode of GIT bleeding was evidenced in one third of the cases and included hematemesis in 3.5% ($n = 3$), melena in 24.7% ($n = 21$), and rectorrhagia in 22.4% ($n = 19$) of the patients. Of the comorbid diseases, most patients had arterial hypertension (44.7%), followed by diabetes mellitus (14.1%) and cardiac arrhythmia (12.9%). Of the concurrent GIT diseases, the most common was dyspepsia. One half of the patients had a prior history of anemia, for a period for 2–180 months. Regarding prior medication use, most patients reported taking iron preparations. The anamnestic data of the patients is shown in Table 1.

Table 1. Anamnestic data of the patients ($n = 85$)

Anamnestic data	%	n
Symptoms		
Malaise and/or fatigue	84.5	71
Abdominal pain	49.3	37
Weight loss	45.9	34
Irregular bowel emptying	43.2	32
Overt gastrointestinal bleeding	38.8	33
Dyspepsia	23.9	16
Heartburn	17.6	12
Tympanites	17.2	10
Vomiting	12.9	9
Loss of appetite	5.8	4
Syncope	2.9	2
Medication and alcohol consumption		
Iron preparations	27.1	23
Acetylsalicylic acid	22.4	19
Anticoagulants	16.5	14
Nonsteroidal anti-inflammatory drugs	11.8	10
Anti-platelet drugs	8.2	7
Alcohol consumption	4.7	4
Comorbidities		
Arterial hypertension	44.7	38
Diabetes mellitus	14.1	12
Arrhythmia	12.9	11
Cerebrovascular insult	9.4	8
Chronic obstructive pulmonary disease	3.5	3
Past medical history		
Dyspepsia	18.8	16
Ulcer disease	9.4	8
Gastroesophageal reflux disease	3.5	3
Overt gastrointestinal bleeding in past medical history	44.7	38
Malignancies	7.1	6
Anemia in past medical history	52.9	45
Family history		
Malignancies in family history	20	17

Clinical data

The majority of patients presented with abdominal tenderness and pallor. In a significantly lower percentage of patients, hepatomegaly, a palpable abdominal mass, and ascites were noted. None of the patients had splenomegaly. A pathological finding on digital rectal examination was present in slightly less than one half of the patients, with results of this examination not determined in 24.7% (n = 21) of the patients. A fecal occult blood test (FOBT) was performed in 56.5% (n = 48) of the patients, with a positive finding in 23.5% (n = 20) of the cases. The clinical data of the patients is shown in Table 2.

Table 2. The clinical data of the patients (n = 85*)

Signs	%	n
Pallor	51.8	44
Abdominal tenderness	65.9	56
Hepatomegaly	7.1	6
Abdominal mass	3.5	3
Ascites	2.4	2
Pathological finding of digital rectal examination	43.8	28
Melena	34.3	22
Rectorrhagia	3.1	2
Palpable mass of the rectum	3.1	2
Palpable internal hemorrhoids	3.1	2

*For digital rectal examination n = 64

Endoscopy

EGDS was performed in 96.5% (n = 82) of the subjects, and colonoscopy in 71.8% (n = 61). Both procedures were performed in 70.6% (n = 60) of the patients. Using these modalities, the cause of IDA was established in 65.9% (n = 56) of the cases. A pathological finding on EGDS was present in 93.9% (n = 77) of those included in the study.

A diagnostic finding on EGDS was present in 43.9% (n = 36) of the patients. The highest percentage of patients had angiodysplasia of the stomach and/or duodenum, gastric ulcer, stomach neoplasm, and duodenal ulcer. Detailed data of the diagnostic and pathological findings of EGDS is shown in Table 3. The selected diagnostic findings of EGDS is shown in Figure 1.

Table 3. Pathological and diagnostic finding of esophagogastroduodenoscopy (n = 82)

Finding	%	n
Gastroesophageal reflux disease*	8.5	7
Esophageal varices	1.2	1
Hiatus hernia*	6	5
Chronic gastritis/gastroduodenitis**	37.8	31
Gastric and/or duodenal angiodysplasia	14.6	12
Gastric ulcer	6	5
Gastric neoplasm	6	5
Duodenal ulcer	4.8	4
Duodenal neoplasm	1.2	1
Polyps	2.4	2
Mb. Crohn	2.4	2
Gluten sensitive enteropathy	1.2	1
Gastrointestinal stromal tumor	1.2	1

Bold – pathological and diagnostic finding;

*diagnostic finding in 2.4% (n = 2) of the patients;

**diagnostic finding in 10.9% (n = 9) of the patients

The pathological finding on colonoscopy was seen in 78.6% (n = 48) of the patients, 47.5% (n = 29) had a diagnostic finding. The most common were colonic neoplasms and inflammatory bowel disease. Diagnostic and pathological findings of colonoscopy are shown in Table 4.

In 15% (n = 9) of the patients, there was a positive finding on both EGDS and colonoscopy. The most common diagnostic finding in the upper and lower parts of the GIT is angiodysplasia, which was present in 4.7% (n = 4) patients.

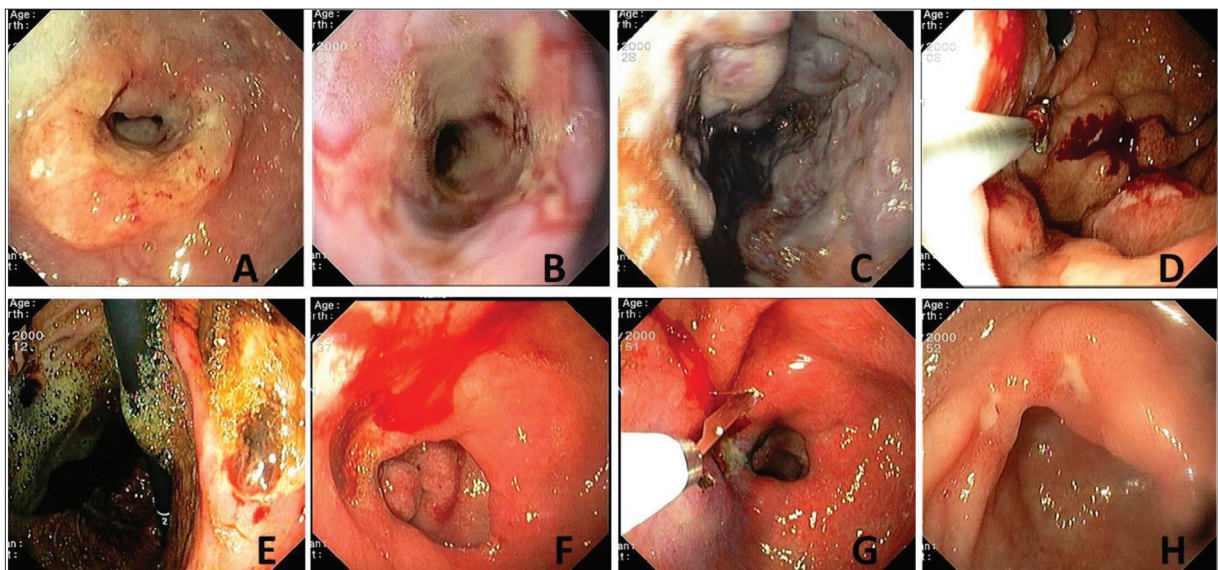


Figure 1. The selected diagnostic finding of esophagogastroduodenoscopy; A) esophageal carcinoma; B) gastro-esophageal reflux disease with stenosis after extraction of the foreign body; C) esophageal varices; D) gastric lymphoma infiltration; E) gastric ulcer, Forrest IIB; F) and G) bleeding gastric ulcer, Forrest IIB, during hemostasis; H) two ulcers of the antral region

Factors associated with diagnostic finding on endoscopy

A positive diagnostic finding on EGDS was significantly more common in patients older than 50 years compared to younger patients. For other socio-demographic, anamnestic, and clinical data there was no significant difference (Table 5). Patients with diagnostic findings on colonoscopy more commonly reported symptoms of weight loss, and change in bowel habit; they rarely had anemia prior, and rarely used iron supplements, and often had malignancy in their past medical history. Patients with diagnostic findings on colonoscopy often have a positive FOBT. For other assessed variables, no significant difference was found (Table 5).

Table 4. Pathological and diagnostic finding of colonoscopy (n = 61)

Finding	%	n
Colon neoplasm	19.6	12
Inflammatory bowel disease	14.7	9
Hemorrhoids*	9.8	6
Colonic polyps*	9.8	6
Diverticulosis*	8.1	5
Angiodysplasia	6.5	4
Post radiation colitis	4.9	3
Resected colon*	3.2	2
Colonic ulcer	1.6	1

Bold – pathological and diagnostic finding;

*pathological but not diagnostic finding for iron deficiency anemia

DISCUSSION

Gastroenterological and endoscopic examinations are a necessity in the workup of patients with IDA; in fact, 7.6% to 13% of patients are referred to the gastroenterologist because of IDA [13, 14].

In our study, the frequency of diagnostic findings on EGDS and colonoscopy was in line with previously published results, indicating that the incidence of positive endoscopic findings in IDA patients is in the range of 30–85% [8, 9, 15–19].

A high percentage of pathological findings but not diagnostic findings were observed for EGDS in our study, which can be explained by the subjective assessment of the endoscopist regarding the existence of gastritis/gastroduodenitis (the most common overall pathological finding). Another reason may be the fact that, in our study, we described uncomplicated hiatus hernia as a pathological finding. The impact of hiatus hernia on the development of IDA is a matter of some debate. In some studies, hiatus hernia was considered a normal finding [11]. The exception is a large hernia (hernia \geq 4 cm, measured by EGDS), as well as hernia with Cameron erosion [18, 20, 21, 22]. Large hiatal hernias are responsible for IDA in 9.2% of patients, with Cameron's erosion present in one third of patients [23]. In our study, hiatus hernia was a diagnostic finding only if it was \geq 4 cm with Cameron erosion, which was present in 2.4% of the patients.

A study by Majid et al. [24] found that the most common causes of IDA in the upper part of the GIT were erosive

Table 5. Diagnostic finding of esophagogastroduodenoscopy and colonoscopy in relation to patient characteristics

Variable	EGDS diagnostic finding			Colonoscopy diagnostic finding		
	%	n	p	%	n	p
Age 50 years	13.9	5	0.031	37.9	11	0.243
Female sex	52.8	19	0.957	48.3	14	0.622
Malaise and/or fatigue	88.6	31	0.454	82.8	24	0.693
Syncope	3.8	1	0.644	0	0	0.279
Weight loss	46.4	13	0.853	58.6	17	0.046
Loss of appetite	7.7	2	0.517	7.4	2	0.205
Abdominal pain	56.7	17	0.339	55.2	16	0.256
Dyspepsia	24	6	0.932	17.2	5	0.313
Heartburn	12	3	0.288	17.2	5	0.865
Tympanites	10	2	0.335	13	3	0.434
Vomiting	7.7	2	0.273	17.2	5	0.298
Irregular bowel emptying	34.5	10	0.271	59.3	16	0.012
Active overt gastrointestinal bleeding	47.2	17	0.120	37.9	11	0.082
Arterial hypertension	44.4	16	0.842	39.3	11	0.154
Diabetes mellitus	6.2	2	0.062	17.2	5	0.415
Arrhythmia	14.3	5	0.902	14.3	4	0.260
Cerebrovascular insult	9.4	3	0.572	3.4	1	0.074
Gastritis	12.5	4	0.144	24.1	7	0.992
Ulcer disease	15.6	5	0.192	6.9	2	0.270
GERD	6.3	2	0.365	3.4	1	0.721
Malignancies*	6.3	2	0.522	13.8	4	0.043
Overt gastrointestinal bleeding in past medical history	69.6	16	0.404	71.4	10	0.652
Iron preparations	27.8	10	0.961	20.7	6	0.022
Acetylsalicylic acid	27.6	8	0.805	17.2	5	0.313
Nonsteroidal anti-inflammatory drugs	20	6	0.191	13.8	4	0.289
Anti-platelet drugs	21.2	7	0.582	10.3	3	0.289
Alcohol consumption	6.7	2	0.577	3.4	1	0.357
Anemia in past medical history	80	20	0.198	47.8	11	0.001
Malignancies in family history	15.4	4	0.208	26.9	7	0.827
Pallor	52.8	19	0.803	48.3	14	0.482
Abdominal tenderness	33.3	12	0.945	34.5	10	0.877
Hepatomegaly	8.3	3	0.384	10.3	3	0.259
Ascites	2.8	1	0.688	0	0	0.178
Pathological finding of digital rectal examination	40	10	0.502	31.8	7	0.367
FOBT positive	36.8	7	0.866	66.7	12	0.012

Bold – p < 0.05; EGDS – esophagogastroduodenoscopy;

GERD – gastroesophageal reflux disease; FOBT – fecal occult blood test;

EGDS – esophagogastroduodenoscopy;

*malignancies in past medical history

gastritis (8.4%), erosive esophagitis (6.3%), gastric (5.3%), and duodenal ulcer (5.3%). In the same study, the most common causes in the lower part of the GIT were colonic ulcers (4.3%), colonic mass (2.1%), and colonic polyps (2.1%) [24].

Rockey et al. [9] found that the causes of IDA in the upper part of the GIT were duodenal ulcer (11%), esophagitis (6%), gastritis (6%), gastric ulcer (5%), vascular ectasia (3%), anastomosis ulcer (3%), gastric cancer (1%), and other causes (2%) [9]. Furthermore, they found that the most common cause of IDA in the lower part of the GIT was colon cancer (11%), polyps (5%), vascular ectasias

(5%), colitis (2%), cecum ulcer (2%), and parasite infestation (1.05%). In contrast to these studies, we found that the most common lesion underlying IDA in the upper GIT was gastric and/or duodenal angiodysplasia. The explanation for these results is multifactorial. We collected data on patients who were examined at a tertiary care institution, to where patients are generally referred when diagnosis and/or treatment cannot be carried out at the primary or the secondary level. Our sample included patients with an average age of about 60 years, and angiodysplasias are more common in the older population [25]. The average age of subjects in the study by Rockey et al. [9] was 60 ± 14 years, which is very similar to our sample; however, that study was conducted in the 1990–1992 period.

One third of our patients had a non-diagnostic finding of endoscopy. Based on recent literature data, 10–41% of IDA patients have a negative finding of endoscopy [26, 27]. The cause of the negative finding is also multifactorial; namely, anemia can be caused by a lack of iron in the diet, other organ and systemic diseases, significant lesions overlooked during endoscopy, and/or lesions unavailable to endoscopy (especially lesions in the small intestine). Exploration of the small bowel is indicated in patients who are transfusion-dependent or have persistent symptoms [28].

Our research concluded that the diagnostic finding on EGDS was significantly more frequent in patients older than 50 years, which is in line with previously published results [8, 13, 19, 24]. These results can be explained by the fact that GIT disorders, which cause chronic bleeding, are more common in the older population.

More than one half of our patients had symptoms specific to the digestive system, supporting previously published results [8]. By analyzing the effects of individual symptoms on a positive endoscopic finding, we concluded that weight loss and irregular bowel emptying were more frequent in patients with a diagnostic finding on colonoscopy. This is a logical conclusion considering that the highest percentage of our patients with a positive colonoscopy finding had colonic carcinoma or inflammatory bowel disease, and that weight loss and irregular bowel emptying form the basis of the clinical presentation of these conditions. Literature on abdominal symptoms and diagnostic endoscopic findings are contradictory. Rockey et al. [9] concluded that abdominal symptoms are associated with a pathological finding, adding that, symptoms “specific to the side” were specific for a positive finding of endoscopy of that respective side, whereas the absence of such symptoms did not exclude pathological changes on that side. Supporting the

predictive significance of abdominal symptoms in the diagnosis found on endoscopy are the results of Nahon et al. [8] and of Carter et al. [15]. In contrast, however, Fireman et al. [12] found no significant correlation between abdominal symptoms and endoscopic findings.

The use of alcohol as well as non-steroidal anti-inflammatory drugs were not associated with a higher incidence of EGDS and colonoscopy diagnostic findings amongst our patients, which is consistent with the results of other studies [9]. Furthermore, the use of other investigational drugs did not indicate a significant association. The exception was the use of iron preparations; namely, we found that patients who used iron supplementation, alongside those with anemia in their history, had a significantly lower occurrence of diagnostic findings on colonoscopy.

We concluded that a positive personal history of malignancy was associated with a higher incidence of a diagnostic finding of colonoscopy.

Our study had limitations. We did not have information about the patient's *H. pylori* status, and *H. pylori* infection can play an important role in IDA [29, 30]. The study included patients who were examined in a tertiary institution, so selection bias cannot be excluded.

CONCLUSION

Diagnostic findings on EGDS in patients with IDA was more common in older patients, while a diagnostic finding on colonoscopy was more frequent in those with presenting symptoms of weight loss, change in bowel habit, positive FOBT and malignancy in their personal history. Patients who had no history of anemia, and did not consume iron preparations previously, were more likely to show diagnostic findings on lower endoscopy.

NOTE

This manuscript was partially presented as an abstract “Endoscopy in patients with iron deficiency anemia,” ESGE Days 2018, April 19–21, 2018, Budapest (Endoscopy 2018; 50(04): S159). The manuscript is part of the postgraduate (subspecialist) thesis titled “Esophagogastroduodenoscopy and colonoscopy in patients with anemia due to iron deficiency,” which was finished in 2016.

Conflict of interest: None declared.

REFERENCES

- Lopez A, Cacoub P, Macdougall IC, Peyrin-Biroulet L. Iron deficiency anaemia. *Lancet*. 2016; 387(10021):907–16.
- WHO. Iron deficiency anaemia assessment, prevention, and control: a guide for programme managers. Geneva: World Health Organization; 2001.
- Terrier B, Resche-Rigon M, Andres E, Bonnet F, Hachulla E, Marie I, et al; Groupe de Recherche sur les Anémies en Médecine Interne. Prevalence, characteristics and prognostic significance of anemia in daily practice. *QJM*. 2012; 105(4):345–54.
- Clark SF. Iron deficiency anemia. *Nutr Clin Pract*. 2008; 23(2):128–41.
- Looker AC, Dallman PR, Carroll MD, Gunter EW, Johnson CL. Prevalence of iron deficiency in the United States. *JAMA*. 1997; 277(12):973–6.
- Goddard AF, James MW, McIntyre AS, Scott BB; British Society of Gastroenterology. Guidelines for the management of iron deficiency anaemia. *Gut*. 2011; 60(10):1309–16.
- Hardwick RH, Armstrong CP. Synchronous upper and lower gastrointestinal endoscopy is an effective method of investigating iron-deficiency anaemia. *Br J Surg*. 1997; 84(12):1725–8.

8. Nahon S, Lahmek P, Lesgourgues B, Nahon-Uzan K, Tuszynski T, Traissac L, et al. Predictive factors of GI lesions in 241 women with iron deficiency anemia. *Am J Gastroenterol.* 2002; 97(3):590–3.
9. Rockey DC, Cello JP. Evaluation of the gastrointestinal tract in patients with iron-deficiency anemia. *N Engl J Med.* 1993; 329(23):1691–5.
10. Sauerbruch T, Schreiber MA, Schüssler P, Permanetter W. Endoscopy in the diagnosis of gastritis. Diagnostic value of endoscopic criteria in relation to histological diagnosis. *Endoscopy.* 1984; 16(3):101–4.
11. Stephens MR, Hopper AN, White SR, Jugool S, Stratford R, Lewis WG, et al. Colonoscopy first for iron-deficiency anaemia: a Numbers Needed to Investigate approach. *QJM.* 2006; 99(6):389–95.
12. Fireman Z, Zachka R, Mouch SA, Kopelman Y. The Role of Endoscopy in the Evaluation of Iron Deficiency Anemia in Premenopausal Women. *IMAJ.* 2006; 8(2):88–90.
13. Aljebreen AM, Alswat K, Almadi MA. Appropriateness and diagnostic yield of upper gastrointestinal endoscopy in an open-access endoscopy system. *Saudi J Gastroenterol.* 2013; 19(5):219–22.
14. McIntyre AS, Long RG. Prospective survey of investigations in outpatients referred with iron deficiency anaemia. *Gut.* 1993; 34(8):1102–7.
15. Carter D, Maor Y, Bar-Meir S, Avidan B. Prevalence and predictive signs for gastrointestinal lesions in premenopausal women with iron deficiency anemia. *Dig Dis Sci.* 2008; 53(12):3138–44.
16. Wilcox CM, Alexander LN, Clark WS. Prospective evaluation of the gastrointestinal tract in patients with iron deficiency and no systemic or gastrointestinal symptoms or signs. *Am J Med.* 1997; 103(5):405–9.
17. Niv E, Elis A, Zissin R, Naftali T, Novis B, Lishner M. Iron deficiency anemia in patients without gastrointestinal symptoms – a prospective study. *Fam Pract.* 2005; 22(1):58–61.
18. Annibale B, Capurso G, Chistolini A, D'Ambra G, DiGiulio E, Monarca B, et al. Gastrointestinal causes of refractory iron deficiency anemia in patients without gastrointestinal symptoms. *Am J Med.* 2001; 111(6):439–45.
19. Brim H, Shahnaizi A, Nouraie M, Badurdeen D, Laiyemo AO, Haidary T, et al. Gastrointestinal Lesions in African American Patients with Iron Deficiency Anemia. *Clin Med Insights Gastroenterol.* 2018; 11:1179552218778627.
20. Cameron AJ. Incidence of iron deficiency anaemia in patients with large diaphragmatic hernia. A controlled study. *Mayo Clin Proc.* 1976; 51(12):767–9.
21. Cameron AJ, Higgins JA. Linear gastric erosion. A lesion associated with large diaphragmatic hernia and chronic blood loss anemia. *Gastroenterology.* 1986; 91(2):338–42.
22. Zullo A, Manta R, De Francesco V, Fiorini G, Lahner E, Vaira D, et al. Cameron lesions: A still overlooked diagnosis. Case report and systematic review of literature. *Clin Res Hepatol Gastroenterol.* 2018; 42(6):604–9.
23. Panzuto F, Di Giulio E, Capurso G, Baccini F, D'Ambra G, Delle Fave G, et al. Large hiatal hernia in patients with iron deficiency anaemia: a prospective study on prevalence and treatment. *Aliment Pharmacol Ther.* 2004; 19(6):663–70.
24. Majid S, Salih M, Wasaya R, Jafri W. Predictors of gastrointestinal lesions on endoscopy in iron deficiency anemia without gastrointestinal symptoms. *BMC Gastroenterol.* 2008; 8:52.
25. Regula J, Wronska E, Pachlewski J. Vascular lesions of the gastrointestinal tract. *Best Pract Res Clin Gastroenterol.* 2008; 22(2):313–28.
26. Soon A, Cohen BL, Groessl EJ, Ho SB. Long-term outcomes and prognostic factors for patients with endoscopy-negative iron deficiency. *Dig Dis Sci.* 2013; 58(2):488–95.
27. Apostolopoulos P, Liatsos C, Gralnek IM, Giannakouloupoulou E, Alexandrakis G, Kalantzis C, et al. The role of wireless capsule endoscopy in investigating unexplained iron deficiency anemia after negative endoscopic evaluation of the upper and lower gastrointestinal tract. *Endoscopy.* 2006; 38(11):1127–32.
28. Goddard AF, McIntyre AS, Scott BB. Guidelines for the management of iron deficiency anaemia. *British Society of Gastroenterology. Gut.* 2000; 46 (Suppl 3-4):IV1–IV5.
29. Malfertheiner P, Megraud F, O'Morain CA, Gisbert JP, Kuipers EJ, Axon AT, et al. Management of Helicobacter pylori infection-the Maastricht V/Florence Consensus Report. *Gut.* 2017; 66(1):6–30.
30. Yuan W, Li Yumin, Yang Kehu, Ma Bin, Guan Quanlin, Wang D, et al. Iron deficiency anemia in Helicobacter pylori infection: meta-analysis of randomized controlled trials. *Scand J Gastroenterol.* 2010; 45(6):665–76.

Горња и доња гастроинтестинална ендоскопија код болесника са анемијом услед недостатка гвожђа

Душан Ђ. Поповић^{1,2}, Симон Зеџ¹, Иван В. Ранковић¹, Тијана М. Глишић^{1,2}, Тамара М. Миловановић^{1,2}

¹Клинички центар Србије, Клиника за гастроентерологију и хепатологију, Београд, Србија;

²Универзитет у Београду, Медицински факултет, Београд, Србија

САЖЕТАК

Увод/Циљ Најчешћи узрок сидеропенијске анемије (СА) код мушкараца и жена у постменопаузи су гастроинтестиналне болести.

Циљ ове студије је одређивање учесталости патолошких и дијагностичких промена приликом езофагогастроудоденоскопије (ЕГДС) и колоноскопије код болесника са СА, као и испитивање повезаности демографских, анамнестичких и клиничких карактеристика болесника са налазом ендоскопије.

Метод Спроведена је ретроспективна студија у коју су били укључени болесници са СА.

Резултати У студију је укључено 85 болесника са СА, просечне старости $60,3 \pm 18,8$ година. Од укупног броја болесника 51,8% су жене. ЕГДС је спроведена код 96,5% болесника, колоноскопија код 71,8%, док су обе ендоскопске процедуре спроведене код 70,6% болесника. Узрок СА је утврђен код 65,9% болесника. Дијагностички налаз ЕГДС је био присутан код 43,9% болесника, колоноскопије код

47,5%, док је дијагностички налаз обе ендоскопске методе био присутан код 15,9% болесника. Дијагностички налаз ЕГДС је значајно чешћи код болесника старијих од 50 година него код млађих ($p = 0,031$). Болесници са дијагностичким налазом колоноскопије чешће имају губитак на тежини ($p = 0,046$), промене у цревном пражњењу ($p = 0,012$), позитиван тест на окултно крварење у столицу ($p = 0,012$), ређе имају анемију у личној анамнези ($p = 0,001$), ређе користе препарате гвожђа ($p = 0,022$) и чешће имају малигнитет у личној анамнези ($p = 0,043$).

Закључак Дијагностички налаз ЕГДС је чешћи код старијих болесника, док је дијагностички налаз колоноскопије чешћи код болесника који имају губитак телесне тежине, нередовно цревно пражњење, позитиван тест на окултно крварење и малигнитете у личној анамнези. Болесници који немају анемију у личној анамнези, као и они који не користе препарате гвожђа, чешће имају дијагностички налаз колоноскопије.

Кључне речи: анемија; ендоскопија; неоплазма; ангиодисплазија