

CASE REPORT / ПРИКАЗ БОЛЕСНИКА

The rare manifestation of pulmonary artery agenesis

Dragan Radovanović^{1,2}, Jelena Janković³, Marko Popović², Mihailo Stjepanović^{1,3}¹University of Belgrade, Faculty of Medicine, Belgrade, Serbia;²Clinical Center of Serbia, Clinic for Thoracic Surgery, Belgrade, Serbia;³Clinical Center of Serbia, Clinic for Pulmonology, Belgrade, Serbia**SUMMARY****Introduction** Unilateral absence of pulmonary artery is a rare vascular malformation. Because of this anomaly, the lungs are supplied by the system of collateral arteries.**Case outline** We present a case of the right pulmonary artery agenesis in a female patient. She was admitted to the hospital because of hemoptysis. A computed tomography scan revealed a congenital malformation – the right lung was smaller in size, the right principal pulmonary artery had not been developed along with aberrant tortuous blood vessels.**Conclusion** Symptomatic therapy was applied in the case of our patient. There was no need for any surgical treatment. However, in case of massive hemoptysis embolisation or lobectomy/ pneumonectomy will probably be applied.**Keywords:** pulmonary arteries; hemoptysis; computed tomography; angiogenesis**INTRODUCTION**

Unilateral absence of the pulmonary artery (UAPA) was first described by Frentzel in 1868, and was demonstrated angiographically in 1952 [1]. The most likely theory of UAPA is due to the developmental failure of the sixth left arch, resulting in the absence of the pulmonary artery [2].

Pulmonary artery agenesis can be localized to a single lobe, also can affect an entire lung or in very a rare case both lungs. Because of that, the lungs are supplied by the system of collateral arteries from bronchial, subclavian, intercostal and coronary arteries. The increased pressure in the collateral arteries may lead to pulmonary arteries damage, endothelial tissue damage, and pulmonary arterial hypertension. These submucosal collaterals hypertrophy with time and may rupture causing hemoptysis, which is the most common symptom [3–7].

Congenital UAPA is an extremely rare anomaly (includes approximately 0.39% of all congenital heart diseases), with a prevalence of 1 in 200,000 young adults [3]. This malformation occurs less often when compared to the total anomalous pulmonary venous connection (TAPVC) that is 0.7–1.5% of all congenital heart malformations [8]. Anatomical characteristic of TAPVC is an abnormal connection of pulmonary veins with systemic venous circulation, but so far, no association has been described with UAPA [8].

UAPA is usually associated with other cardiovascular abnormalities (tetralogy of Fallot, ventricular septal defect, coarctation of the aorta, subvalvular aortic stenosis, scimitar syndrome).

It is, in most cases, diagnosed in childhood. The average age of UAPA patients is 14.

However, because of the atypical symptoms, some patients can be diagnosed in adulthood with the symptoms: hemoptysis, dyspnea, reduced exercise tolerance, recurrent bronchopneumonia. In some patients, chronic infection can lead to bronchiectasis [9–12].

Treatment options include revascularization surgery, pulmonary vasodilator therapy (for pulmonary hypertension), pneumonectomy, or lobectomy, embolisation of collateral hemorrhage [11–16].

CASE REPORT

A 28-year-old female, a non-smoker, was admitted to the Clinic for pulmonology, at the Clinical Center of Serbia for evaluation of hemoptysis, which had first occurred four years ago. Hemoptysis, mostly during exertion, repeated again at the end of 2013 and early 2014, but the patient did not visit a doctor. In the meantime, until admission to the hospital, the patient led a normal life; she had a healthy baby by a normal delivery.

Physical examination was unremarkable. Her vital signs were normal, with oxygen saturation of 97% on room air. Her lungs were clear to auscultation, only over the basal part of the right lung the sound was weakened, without wheezes or rales. Her cardiovascular exam revealed normal heart rate and rhythm. Laboratory data showed normal complete blood count and chemistry.

On posteroanterior chest X-ray, the mediastinal shadow and heart were shifted to the right,

Received • Примљено:

April 16, 2018

Revised • Ревизија:

March 25, 2019

Accepted • Прихваћено:

April 17, 2019

Online first: May 10, 2019**Correspondence to:**Mihailo STJEPANOVIĆ
Clinic for Pulmonology
Clinical Center of Serbia
Koste Todorovica 26/20
11000 Belgrade

mihailostjepanovic@gmail.com

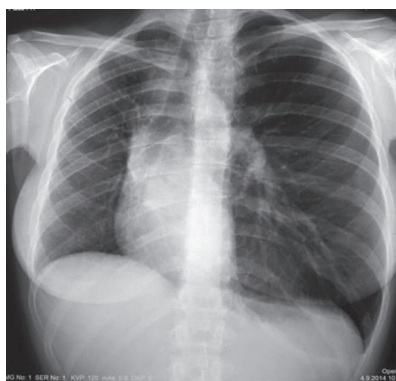


Figure 1. The chest X-ray radiograph reveals the mediastinal shadow, the heart that had shifted to the right, and the volume of the right lung is smaller with hyperinflated left lung

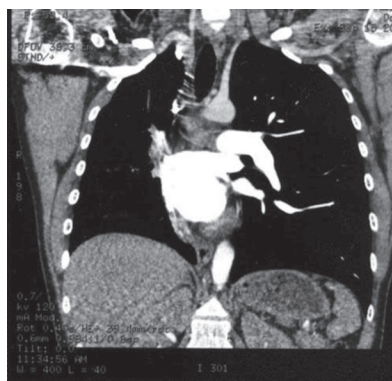


Figure 2. The computed tomography scan shows the pulmonary trunk after leaving the right atrium continues to the left principal pulmonary artery, while the right had not been developed (regular computed tomography scan)

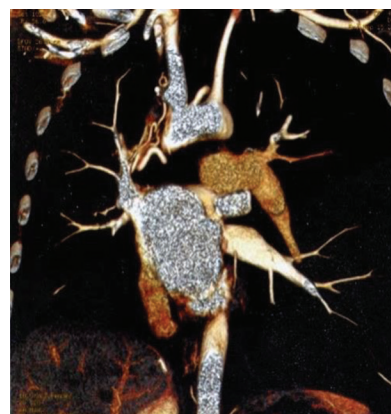

Figure 3. The color 3D computed tomography scan shows the pulmonary trunk after leaving the right atrium continues to the left principal pulmonary artery while the right had not been developed

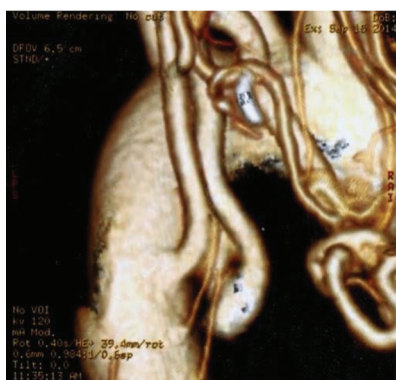


Figure 4. The computed tomography scan shows three main collateral from the descending aorta

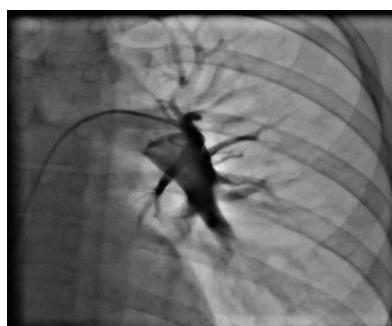


Figure 5. Selective aortography: multiple aortopulmonary collateral arteries

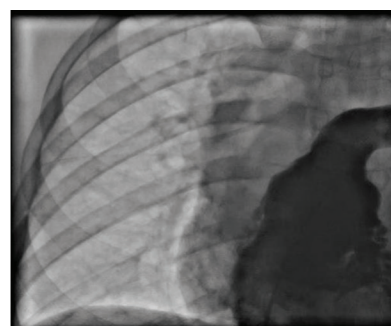


Figure 6. Selective aortography – absence of the right pulmonary artery on aortography

the volume of the right lung was smaller with hyperinflated left lung (Figure 1).

The total lung capacity amounted to 106% of predicted, residual volume to 101%, and a diffusion capacity for carbon monoxide to 72% of predicted.

A perfusion scintigram showed the absence of perfusion in the right lung.

Bronchoscopy was normal (no deformity in the bronchial tree, normal arborization of the airways), but incidental finding during bronchoscopy was nasal polyps that tend to bleed.

Echocardiography showed that dimensions of all cardiac chambers were normal. Atrial septum was normal with the suspected ductus arteriosus persistent, and there was absence of the right pulmonary artery. There was no pulmonary hypertension.

Hemodynamic examination (coronary angiography, right ventriculography) revealed tricuspid regurgitation 2+, pulmonary angiography revealed aplasia of the right pulmonary artery while the left pulmonary artery arborization was normal. Aortography revealed ductus arteriosus persistent. There was normal pressure in the right and left heart ventricles.

Another notable point of this case is that the CT scan revealed the congenital malformation – the right lung was

smaller in size, developed with all three lobes, the left lung was hyperinflated (Figures 2, 3, and 4). The pulmonary trunk continues to the left principal pulmonary artery after leaving the right atrium, while the right has not been developed. Immediately below the aortic arch are two separating aberrant tortuous blood vessels. Medial blood vessel is dominant and supplies the greater part of the right lung. All four pulmonary veins drain into the left atrium.

We found the existence of multiple aortopulmonary collateral arteries on selective aortography. The three main collaterals come from descending aorta and supply all three right lung lobes, and there is a secondary collateral from the brachiocephalic trunk which supplies the smaller parts of the upper right lobe. All collaterals were very tortuous, but at no time did it display the right pulmonary artery (Figures 5 and 6).

DISCUSSION

We report a case of a young woman, who was admitted to the hospital because of hemoptysis. During the hospital treatment, we found that the patient had UAPA.

Patients with UAPA can remain asymptomatic for a long period, or may include hemoptysis (in 20% of patients),

dyspnea in physical activity, recurrent respiratory infections, chest pain, or pleural effusion. The most common symptom is hemoptysis, though a massive and life-threatening hemoptysis could also occur. Pulmonary hypertension was diagnosed in 25% of the patients with UAPA and it is a poor prognostic sign [9].

Sometimes hemoptysis can be provoked by factors such as exercise or during pregnancy. Although our patient had one term delivery, she had no complaints.

Our patient had an isolated case of UAPA without any other cardiovascular anomaly. Optimal management requires a multi-disciplinary approach for diagnostic and treatment.

For diagnostics, chest radiography, multiple detector computed tomography scan, magnetic resonance imaging, ventilation-perfusion scintigraphy, and angiography can be used.

On the chest X-ray, there can be a reduction in the volume of hemithorax, an elevation in the hemidiaphragm and mediastinal shift in the affected side [3].

A ventilation-perfusion scintigraphy is rarely performed today and it can show absence of perfusion on the affected lung with normal ventilation [3].

Angiography is the gold standard for establishing a definitive diagnosis and identifying the collaterals in the affected lung [12]. In our case, the blood supply to the affected lung comes from a branch of the artery from the descending aorta, forming collateral circulation for the aorto-pulmonary artery.

Symptomatic treatment consists of medications such as antibiotics, expectorants and bronchodilators, the treatment of pulmonary hypertension and any other treatments for complications. Nowadays in such cases, prophylaxis is very important for respiratory syncytial virus, pneumococcus, and influenza infections [15].

Surgical UAPA treatment methods are revascularization (a systemic-pulmonary shunt involving the hilar arteries), lobectomy, pneumonectomy, and embolization of the developed aorto-pulmonary collateral arteries. In addition, reanastomosis of the peripheral pulmonary arteries, and the pulmonary trunk have been described in literature [11, 16].

We applied symptomatic therapy only according to our council's decision (pulmonologist, thoracic, and cardiovascular surgeons). There was no need for any surgical treatment at that moment because it was not a case of massive hemoptysis.

We advised the patient to visit the otolaryngologist because it is possible that the cause of hemoptysis was nasal polyps that bleed easily when touched. The mucosa of the polyp that was seen by bronchoscopy is very fragile and bleeds easily.

The patient will do follow-ups with a pulmonologist, thoracic, and cardiovascular surgeons. Given the fact that it was an innate birth defect detected at an older age, the symptoms (hemoptysis) are minimal, and mainly during physical exertion and since the patient had had a successful birth, it can be expected that massive hemoptysis is not going to occur. However, we advised the patient that in case of massive hemoptysis, she should immediately report to the hospital in order to decide on further treatment. In case of a massive hemoptysis, surgeons will probably apply embolectomy of the blood vessel that bleeds. As a final option, they might take into account lobectomy or pneumonectomy.

Unilateral absence of pulmonary artery is a very rare vascular malformation and may remain undiagnosed for prolonged periods. Although this malformation occurs in childhood, it manifested itself after 25 years, after our patient had become a mother. A delivery is like any other kind of activity, a risk factor for hemoptysis because the lungs are supplied by the system of collateral arteries. Therefore, it is necessary to think about UAPA in patients with other heart anomalies and if there is a reduced transparency or volume of one lung on a chest radiograph. Optimal management requires a multi-disciplinary approach for diagnostics and treatment. In the case of our patient, only symptomatic therapy was applied. There was no need for any surgical treatment. However, in case of massive hemoptysis, embolisation or surgical treatment of that lung can be applied.

Conflict of interest: None declared.

REFERENCES

1. Welch K, Hanley F, Johnston T, Cailles C, Shah MJ. Isolated unilateral absence of right proximal pulmonary artery: surgical repair and follow up. *Ann Thorac Surg.* 2005; 79(4):1399–402.
2. Rafiei P, Roda MS, Patel RB. Isolated unilateral absence of the right pulmonary artery. *South Med J.* 2011; 104(4):276–7.
3. Yiu MWC, Le DV, Leung Y, Ooi CGC. Radiological features of Isolated Unilateral Absence of the Pulmonary Artery. *J HK Coll Radiol.* 2001; 4:277–80.
4. Fraser RG, Pare JAP. Developmental anomalies affecting the airways and lung parenchyma. In: Fraser RG, Pare JAP, Eds. *Fraser and Pare's Diagnosis of Diseases of the Chest.* Philadelphia: W. B. Saunders Company; 1999. p. 597–635.
5. Mazurek B, Szydłowski L, Mazurek M, Kohut J, Głowacki J. Rare cardiovascular anomaly: congenital unilateral absence of the pulmonary artery. *Arch Med Sci.* 2013; 9(6):1162–4.
6. Maeda S, Suzuki S, Moriya T, Suzuki T, Chida M, Suda H, et al. Isolated unilateral absence of a pulmonary artery: influence of systemic circulation on alveolar capillary vessels. *Pathol Int.* 2001; 51(8):649–53.
7. Ten Harkel AD, Blom NA, Ottenkamp J. Isolated unilateral absence of a pulmonary artery: a case report and review of the literature. *Chest.* 2002; 122(4):1471–7.
8. Djukić M, Parezanović V, Ilić S, Jovanović I, Vulićević I, Ilišić T, Mimić B, et al. Outcomes of Surgery for Total Anomalous Pulmonary Venous Drainage. *Srp Arh Celok Lek.* 2014; 142(3–4):164–9.
9. Steiropoulos P, Archontogeorgis K, Tzouvelekis A, Ntoliou P, Chatzistefanou A, Bouros D. Unilateral pulmonary artery agenesis: a case series. *Hippokratia* 2013; 17(1):73–6.
10. Mohan V, Mohan B, Tandon R, Kumbkarni S, Chhabra ST, Aslam N, et al. Case report of isolated congenital absence of right pulmonary artery with collaterals from coronary circulation. *Indian Heart J.* 2014; 66(2):220–2.
11. Hamdan MA, Abu-Sulaiman RM, Najm HK. Sildenafil in pulmonary hypertension secondary to unilateral agenesis of pulmonary artery. *Pediatr Cardiol.* 2006; 27(2):279–81.
12. Bockeria LA, Makhachev OA, Khiriev TK, Abramyan MA. Congenital isolated unilateral absence of pulmonary artery and variants of

- collateral blood supply of the ipsilateral lung. *Interact Cardiovasc Thorac Surg.* 2011; 12(3):509–10.
13. Reading DW, Oza U. Unilateral absence of a pulmonary artery: a rare disorder with variable presentation. *Proc (Bayl Univ Med Cent).* 2012; 25(2):115–8.
 14. Kruzliak P, Syamasundar RP, Novaka M, Pechanova O, Kovacova G. Unilateral absence of pulmonary artery: pathophysiology, symptoms, diagnosis and current treatment. *Arch Cardiovasc Dis.* 2013; 106(8–9):448–54.
 15. Furuta A, Nagashima M, Hiramatsu T, Matsumura G, Yamazaki K. Surgical repair of a truncus arteriosus with unilateral absence of the right proximal pulmonary artery. *J Card Surg.* 2016; 31(11):703–5.
 16. Saladi L, Roy S, Diaz-Fuentes G. Unilateral pulmonary artery agenesis: An unusual cause of unilateral ARDS. *Respir Med Case Rep.* 2018; 23:148–51.

Ретка манифестација агенезије плућне артерије

Драган Радовановић^{1,2}, Јелена Јанковић³, Марко Поповић², Михаило Стјепановић^{1,3}

¹Универзитет у Београду, Медицински факултет, Београд, Србија;

²Клинички центар Србије, Клиника за грудну хирургију, Београд, Србија;

³Клинички центар Србије, Клиника за пулмологију, Београд, Србија

САЖЕТАК

Увод Једнострано одсуство плућне артерије је ретка васкуларна малформација. Због ове аномалије плућа се васкуларизују системом колатералних артерија.

Приказ болесника Приказујемо редак случај агенезије десне плућне артерије код болеснице, која је иницијално хоспитализована због манифестних хемоптизија. Компјутеризована томографија грудног коша је показала конгениталне малформације, мању димензију десног плућа (десна

главна плућна артерија није била развијена) и аберантне крвне судове.

Закључак У случају наше болеснице примењена је симптоматска терапија. Није било потребе ни за каквим хируршким третманом. Међутим, у случају масовних хемоптизија вероватно ће се применити емболизација или лобектомија/пнеумонектомија.

Кључне речи: плућне артерије; хемоптизије; компјутеризована томографија; ангиогенеза