

ORIGINAL ARTICLE / ОРИГИНАЛНИ РАД

Early and midterm results after surgical repair of anomalous origin of the left coronary artery from the pulmonary artery

Sergej Prijjić^{1,2}, Staša Krasić¹, Jovan Košutić^{1,2}, Mila Stajević^{1,2}, Sanja Ninić¹, Saša Popović¹, Bojko Bjelaković³, Meho Mahmutović⁴, Vladislav Vukomanović^{1,2}

¹Mother and Child Health Care Institute of Serbia, Belgrade, Serbia;

²University of Belgrade, Faculty of Medicine, Belgrade, Serbia;

³University of Niš, Faculty of Medicine, Niš Clinical Centre, Clinic of Pediatrics, Niš, Serbia;

⁴Novi Pazar General Hospital, Novi Pazar, Serbia



SUMMARY

Introduction/Objective The anomalous origin of the left coronary artery from the pulmonary artery (ALCAPA) is rare congenital disease, which causes myocardial ischemia and subsequent heart failure in infants. The aim is early and mid-term follow up evaluation of the heart function after surgical repair of ALCAPA.

Methods Investigation was retrospective and included medical records of the ALCAPA patients treated surgically, between 2009 and 2017, at the tertiary referent heart center.

Results Five patients (four girls) with coronary anomaly were included in the study. All patients had significantly increased left ventricular end diastolic diameter (z-score 6.6 ± 2.43) and left atria size (z-score 3.09 ± 0.37), along with decreased systolic function (ejection fraction $34.8 \pm 7.4\%$ and fractional shortening $15.5 \pm 3.4\%$). The surgery was performed on average at the age of 8.2 ± 7.8 months. Operative treatment was associated with early improvement in echocardiographic parameters (except the size of the left atria). Patients were followed for 4.5 ± 2.6 years. Improvement in echocardiographic parameters was age-related. Patients under four months had recovery early after surgery, those treated at 5.5–6 months of age had normalization after 12 months, and patient who was recognized in the second year of life had late recovery (after ≥ 24 months).

Conclusion Operative treatment in the first 3–4 months of life is related with the most favorable prognosis and rapid normalization of the echocardiographic parameters.

Keywords: ALCAPA; cardiomyopathy; echocardiography

INTRODUCTION

The anomalous origin of the left coronary artery from the pulmonary artery (ALCAPA), also known as Bland-White-Garland syndrome, is a rare congenital disorder with prevalence of 0.25–0.5% and produces postnatal myocardial ischemia with the clinical presentation of the heart failure and mitral regurgitation [1, 2]. The symptoms occur after 6–8 weeks of life due to decrease in pulmonary vascular resistance and coronary steal phenomenon [1, 2, 3]. Ischemia is initially transient and the symptoms present only in periods of increased oxygen demand (e.g. feeding and crying). However, persistent myocardial ischemia induces microenvironment changes and subsequent congestive heart failure [2]. Historically, ALCAPA caused 90% deaths in infants. Advanced surgical methods have significantly reduced mortality rate (0–17%) [1, 3]. The aim of our investigation was evaluation of the heart function and reverse remodeling during early and mid-term follow-up after surgical repair.

METHODS

This study was conducted at the Dr Vukan Čupić Mother and Child Health Care Institute of Serbia and it reflected a period of eight years (2009–2017). We performed a retrospective analysis of medical records. Five patients were included in the study, and no patients were excluded.

The diagnosis was established by echocardiography and confirmed in two patients using cardiac catheterization after symptoms (sweating, feeding, and thriving difficulties and recidivism of bronchiolitis), specific ECG changes (anterolateral wall ischemia) and biochemical parameters appeared. The echocardiographic finding included abnormal movements of the anterolateral wall, left ventricular dilatation, systolic dysfunction, mitral regurgitation, and pathological origin of left coronary artery along with reverse blood flow in the pulmonary artery. Congestive heart failure was treated with diuretics (furosemide, spironolactone), ACE inhibitors (captopril) and cardiotonics (milrinone, dopamine, dobutamine), along with aspirin and fraxiparine during the average period

Received • Примљено:

July 30, 2018

Revised • Ревизија:

March 4, 2019

Accepted • Прихваћено:

March 5, 2019

Online first: April 17, 2019

Correspondence to:

Vladislav VUKOMANOVIĆ
Mother and Child Health Care
Institute of Serbia
6–8 Radoja Dakića St.,
Belgrade 11070, Serbia
vvukomanovicdr@gmail.com

of two weeks after diagnosis was established. All patients were treated surgically. The anomalous coronary artery is excised from pulmonary artery (PA) with button of PA wall and reimplanted into the left sinus of Valsalva without tension and torsion. For myocardial protection, crystalloid cardioplegic solution was used. The associated mitral valve surgery was not preformed.

Follow-up parameters were obtained every six months. Left ventricular end-diastolic diameter (EDD), end-systolic diameter (ESD), ejection fraction (EF), fractional shortening (FS), left atria (LA) and aortic dimensions, and mitral regurgitation were observed by M-mode, 2-D, Doppler echocardiography and z-scores estimations [4]. Mitral regurgitation was classified as mild (1+), moderate (2+), and severe (3+) [5].

Data are presented as percentages, mean, and standard deviation (SD). The analytic strategy included paired t-test for group comparisons. Relation between numeric variables is presented graphically by means and 95% confidence intervals. Analyses were performed in SPSS 23.0 for Windows, and 0.05 level defined statistically significant result. The study was approved by the institutional Committee on Ethics.

RESULTS

Five patients were included in the study, and their preoperative characteristics are presented in Table 1. Four patients had surgery in the first year of life (average 4.3 ± 1.2 months), while one patient had a late diagnosis and intervention at 22 months of age. All our patients underwent surgery within 15 days after being diagnosed.

Trend toward statistically significant improvement in echocardiographic parameters was revealed immediate after surgery. Namely, left ventricular EDD decreased in size (34.8 ± 9.9 mm; z-score 3.48 ± 2.18 ; $p = 0.053$), and both EF ($52.8 \pm 14.6\%$; $p = 0.069$) and FS ($27.0 \pm 7.2\%$; $p = 0.063$) increased in early postsurgical period (Table 2).

Echocardiographic follow-up (FU) was 4.5 ± 2.6 years (up to 8.1 years) after surgery. During follow-up, signifi-

Table 1. Patient's characteristics and initial preoperative echocardiographic parameters

Age at the time of surgery (months)	8.2 ± 7.8
Body weight (kg)	6.5 ± 1.7
Girls	4/5
Left ventricle EDD (mm)	42.2 ± 7.56
Left ventricle all (z-score)	6.60 ± 2.43
Age 3.5–4 months	7.53 ± 4.19
Age 5.5–6 months	5.52 ± 1.37
Age 22 months	6.89
All (%)	34.8 ± 7.4
Age 3.5–4 months	32 ± 11.31
Age 5.5–6 months	39 ± 5.66
Age 22 months	32
FS (%)	15.5 ± 3.4
LA (mm)	22.5 ± 1.3
LA (z-score)	3.09 ± 0.37
LA:Ao	1.9 ± 0.4
Mitral regurgitation (MR)	Moderate (2/5), severe (3/5)

EDD – end-diastolic diameter; EF – ejection fraction; FS – fractional shortening; LA – left atria; Ao – aorta

cant improvement in cardiac remodeling and contractility was registered (Table 2). Statistically significant improvement in left ventricular EDD z-score was demonstrated six months after surgical treatment ($p = 0.02$). However, complete myocardial recovery with significant improvement and normalization in both EF (64 ± 15.3 , $p = 0.02$) and FS (36 ± 6.2 , $p = 0.01$) was revealed after 12 and 18 months of follow-up, respectively. Normalization rate in cardiac remodeling and systolic function was related to age at the time of surgery (Figure 1). Patients who had surgery at the age of 3.5–4 months had immediate recovery of ejection fraction ($> 60\%$), and those who were treated at the age of 5.5–6 months had normalization in EF after 12 months. However, one patient who was recognized at the age of 22 months had a late EF recovery (after ≥ 24 months of FU). Similarly, normalization in left ventricular EDD was better in cases with early surgery. Nevertheless, one patient who had surgery at 3.5 months of age had a slightly prolonged EDD normalization regarding myocardial necrosis/infarction and serious dilation (EDD z-score 10.5) at the time of diagnosis. Further improvement

Table 2. Echocardiographic parameters after operative treatment

Parameters	After surgery	6 months FU	12 months FU	18 months FU	≥ 24 months FU
Body weight (kg)	6.6 ± 1.7	9.6 ± 1.7	10.3 ± 1.6	11.5 ± 1.1	19.6 ± 8.2
LVEDD (mm)	34.8 ± 9.9	35.3 ± 9.1	34.5 ± 5.2	34.0 ± 3.7	37.3 ± 4.9
LVEDD (z-score)	3.48 ± 2.19 ($p = 0.053$)	$2.22 \pm 2.28^*$ ($p = 0.02$)	$1.91 \pm 1.05^*$ ($p = 0.009$)	$1.35 \pm 0.97^*$ ($p = 0.005$)	$0.65 \pm 0.17^*$ ($p = 0.013$)
EF (%)	52.8 ± 14.6 ($p = 0.069$)	56.0 ± 13.8 ($p = 0.05$)	$64.0 \pm 15.3^*$ ($p = 0.02$)	$67.3 \pm 9.2^*$ ($p = 0.007$)	$66.7 \pm 6.7^*$ ($p < 0.001$)
FS (%)	27 ± 7.2 ($p = 0.063$)	27.5 ± 7.9 ($p = 0.076$)	26.0 ± 11.3 ($p = 0.40$)	$36.0 \pm 6.2^*$ ($p = 0.01$)	$36.8 \pm 3.4^*$ ($p = 0.013$)
LA (mm)	21.8 ± 4.8	21.0 ± 5.0	24.5 ± 2.1	24.3 ± 2.8	23.9 ± 2.2
LA (z-score)	2.72 ± 1.47 ($p = 0.633$)	1.89 ± 1.57 NA	2.59 ± 0.94 ($p = 0.76$)	2.21 ± 0.63 ($p = 0.64$)	$1.47 \pm 0.50^*$ ($p = 0.019$)
LA:Ao	1.6 ± 0.3	1.9 ± 0.4	1.6 ± 0.2	1.6 ± 0.2	1.4 ± 0.2
MR: mild/moderate/severe	0/2/3	0/2/3	1/2/2	1/2/2**	

LVEDD – left ventricle end-diastolic diameter; EF – ejection fraction; FS – fractional shortening; LA – left atria; Ao – aorta; NA – not available;

*statistically significant improvement regarding finding before surgery;

**one patient had mitral valve surgery

in echocardiographic parameters persisted during long term follow-up (≥ 24 months) in all patients, and included normalization of the LA diameter (z -score 1.47 ± 0.50 ; $p = 0.019$). There were no death outcomes in both early and late period after surgery.

DISCUSSION

The anomalous origin of the left coronary artery from the pulmonary artery causes heart failure in the early infancy. However, clinical symptoms are rare before 6–8 weeks of life resulting from appropriate coronary blood flow due to high pressure in pulmonary circulation. After the second month of life, hemodynamic changes are related to coronary steal phenomena, consequent ischemia and impaired left ventricular function [2]. In our study, patients underwent surgical treatment at 8.2 ± 7.8 months of age and diagnose was established 15 days earlier. Early diagnosis and surgical treatment of ALCAPA are crucial for favorable prognosis, and the management of the mitral regurgitation in the same procedure remains controversial (1–3). We confirmed that the patients' age at surgery influenced the time needed for recovery. Normalization of the cardiac function was reached in first days after surgery in patients who were treated in the first four months of life; in those who had operation at 5–6 months, normalization was present after one year; and in patient with late surgery (second year of life) recovery was demonstrated after 1.5–2 years. In our investigation, mitral valve repair was not performed.

The differences in recovery could be related to postnatal development of the cardiomyocytes. Infantile cardiomyocytes are small and round cells with 30% contractile proteins and 70% non-contractile mass (membranes, connective tissues, and organelles). In normal conditions, myocardial growth is based on cardiomyocytes enlargement and proliferation, along with cardiogenic/progenitor cells differentiation. Dynamic proliferation changes are revealed during the first year of life [6]. Namely, proliferative capacity in 1–3 months of age is 11 times bigger than at the age of six months, and 27 times at the age of one year [7]. Thereby, better recovery after cardiac surgery (not only for ALCAPA patients) could be expected in younger infants. Expected number of terminally differentiated cardiomyocytes in older surgical age groups is smaller, and those patients are much more sensitive to heart failure development during adulthood [6, 7].

In addition, the duration of myocardial hibernation may influences on postnatal development in patients with ALCAPA. Namely, normal circulation and microenvironment is needed for sufficient myocardial maturation. Mollova et al. [8] showed that manipulation with endogenous mechanisms could change myocardial cell differentiation in infancy. Similarly, survival, integration, proliferation, and

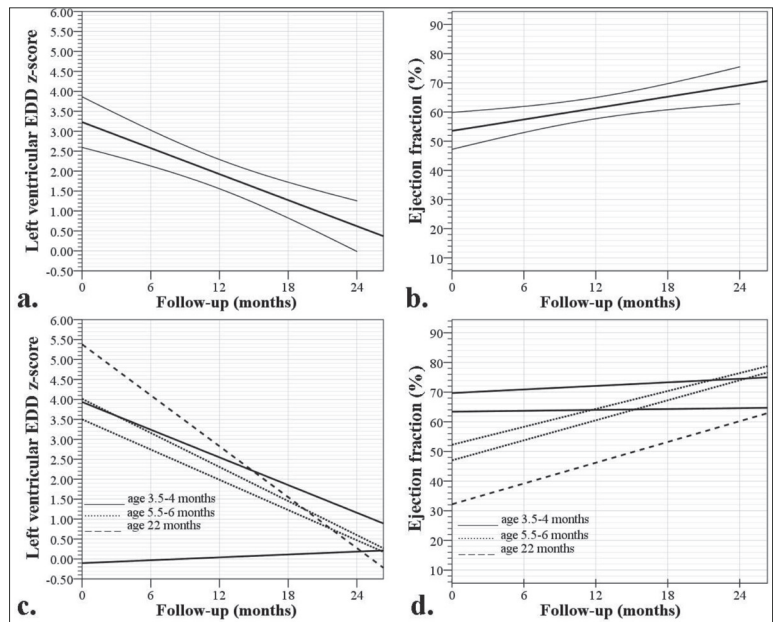


Figure 1. Recovery of the left ventricular end-diastolic diameter (EDD) and ejection fraction after surgical treatment (a. and b. lines represent means and 95% confidence intervals); graphs do not include preoperative values of EDD and ejection fraction

differentiation of the STEM cells, and fetal cardiomyocytes (with viability area increment that improves systolic function) is possible if extracellular matrix microenvironment is optimal [9]. In addition, cyanosis and chronic hypoxia in rat model increases cardiac mass in first four weeks of life mainly due to myocardial proliferation [9]. Consequently, hibernated myocardium should be rescued from irreversible ischemia as soon as possible [1, 2, 3, 10, 11].

The optimal change in the microenvironment after surgical treatment of ALCAPA could stimulate postponed proliferation and maturation, which cause significant improvement of both systolic and diastolic cardiac function in our patients (Figure 1). Additionally, almost complete resolution of the myocardial scar has been showed after surgery [10]. Our results showed that normalization in left ventricular remodeling (EDD z -score < 2) and systolic function (EF $> 60\%$) could be expected 12 months after surgery, with additional normalization in the left atria size after two years of follow-up. Weigand et al. [12] analyzed prognosis after surgery of ALCAPA and patients were divided in two groups (infant and non-infant). They have showed that the preoperative EDD was the only independent factor for time to normalization of LV function. However, infant group (up to 12 months) was not subdivided in that study [13]. Finally, patients with ALCAPA can deploy irreversible changes and myocardial infarction. In our patients, range of the myocardial injury before surgery (presented as impaired echocardiographic finding) was not significantly different, and age related capability for myocardial recovering was essential for prognosis.

In spite of appropriate recovery of the LV function after surgical treatment in majority of patients, complications as persistent mitral regurgitation, congestive heart failure, and coronary stenosis are noticed and lifelong echocardiographic follow up is necessary [2, 3, 9]. During FU period,

one of our patients had mitral valve repair. Pro-BNP analysis can help in functional assessment of patients with heart failure. Reoperation or heart transplantation are indicated in cases with unsuccessful either surgical or conservative treatment [2, 6].

Our clinical investigation can establish hypothesis about age-related difference in myocardial recovery based on cardiomyocytes proliferation in patients with ALCAPA. Further basic studies in these patients should be conducted, with aim to establish the relation between age at the time of surgical treatment and cardiac recovery.

REFERENCES

- Barretta JO. Anomalous origin of the left coronary artery from the pulmonary artery. *Rev Argent Cardiol.* 2010; 78:393–4.
- Dodge-Khatami A, Mavroudis C, Backer LC. Anomalous origin of the left coronary artery from the pulmonary artery: Collective Review of Surgical Therapy. *Ann Thorac Surg.* 2002; 74(3):946–55.
- Ojala T, Salminen J, Happonen J-M, Pihkala J, Jokinen E, Sairanen H. Excellent functional result in children after correction of anomalous origin of left coronary artery from the pulmonary artery – a population-based complete follow-up study. *Interact Cardiovasc Thorac Surg.* 2010; 10(1):70–5.
- Petersen MD, Du W, Skeens ME, Humes RA. Regression Equations for Calculation of Z-scores of Cardiac Structures in a Large Cohort of Healthy Infants, Children, and Adolescents: An Echocardiographic Study. *J Am Soc Echocardiogr.* 2008; 21(8):922–34.
- Zoghbi WA, Adams D, Bonow RO, Enriquez-Sarano M, Foster E, Grayburn PA, et al. Recommendations for Noninvasive Evaluation of Native Valvular Regurgitation A Report from the American Society of Echocardiography Developed in Collaboration with the Society for Cardiovascular Magnetic Resonance. *J Am Soc Echocardiogr.* 2017; 30(4):303–71.
- Martinsen BJ, Lohr JL. Cardiac development. In: Laizo AP. *Handbook of cardiac anatomy, physiology and devices.* 3rd edition. Switzerland: Springer; p. 2015:29–31.
- Ye L, Qiu L, Zhang H, Chen H, Jiang C, Hong H, et al. Cardiomyocytes in young infants with congenital heart disease: a three-month window of proliferation. *Sci Rep.* 2016; 6:23188.
- Mollova M, Bersell K, Walsh S, Savla J, Das LT, Park SY, et al. Cardiomyocyte proliferation contributes to heart growth in young humans. *Proc Natl Acad Sci.* 2013; 110(4):1446–51.
- Cabrera AG, Chen DW, Pignatelli RH, Khan MS, Jeewa A, Mery CM, et al. Outcomes of anomalous left coronary artery from pulmonary artery repair: beyond normal function. *Ann Thorac Surg.* 2015; 99(4):1342–7.
- Ben Ali W, Metton O, Roubertie F, Pouard P, Sidi D, Raisky O, et al. Anomalous origin of the left coronary artery from pulmonary artery: late results with special attention to the mitral valve. *Eur J Cardiothorac Surg.* 2009; 36(2):244–9.
- Fratz D, Hager A, Schreiber C, Schwaiger M, Hess J, Stern HC. Long-term myocardial scarring after operation for anomalous left coronary artery from the pulmonary artery. *Ann Thorac Surg.* 2011; 92(5):1761–6.
- Weigand J, Marshall CD, Bacha EA, Chen JM, Richmond ME. Repair of anomalous left coronary artery from the pulmonary artery in the modern era: preoperative predictors of immediate postoperative outcomes and long term cardiac follow-up. *Pediatr Cardiol.* 2015; 36(3):489–97.
- Azar N, Nasser M, Sabban ME, Bitar H, Obeid M, Dbaibo GS, Bitar FF. Cardiac growth patterns in response to chronic hypoxia in a neonatal rat model mimicking cyanotic heart disease. *Exp Clin Cardiol.* 2003; 8(4):189–94.

CONCLUSION

ALCAPA is one of the most important causes of heart failure in infants. Normalization of the left ventricular systolic and diastolic function is expected 12 months after surgery. In our opinion, diagnosis and operative treatment done in the first months of life are related to favorable prognosis and fast normalization of echocardiographic parameters.

Conflict of interest: None declared.

Рани и средњорочни резултати хирушког лечења анормалног исходишта леве коронарне артерије из плућне артерије

Сергеј Пријић^{1,2}, Сташа Красић¹, Јован Кошутић^{1,2}, Мила Стајевић^{1,2}, Сања Нинић¹, Саша Поповић¹, Бојко Бјелаковић³, Мехо Махмутовић⁴, Владислав Вукомановић^{1,2}

¹Институт за здравствену заштиту мајке и детета Србије „Др Вукан Чупић“, Београд, Србија;

²Универзитет у Београду, Медицински факултет, Београд, Србија;

³Универзитет у Нишу, Медицински факултет, Клинички центар Ниш, Клиника за педијатрију, Ниш, Србија;

⁴Општа болница Нови Пазар, Нови Пазар, Србија

САЖЕТАК

Увод/Циљ Анормално исходиште леве коронарне артерије из плућне артерије (ALCAPA) ретка је конгенитална аномалија, која проузрокује исхемију миокарда и срчану инсуфицијенцију код одојчади.

Циљ студије је евалуација срчане функције током раног и средњег периода праћења оперисаних болесника.

Метод Студија је била ретроспективна и анализирао је медицинску документацију болесника којима је оперативно лечена ALCAPA у периоду од 2009. до 2017. у терцијарној установи.

Резултати Пет болесника (четири девојчице) укључено је у студију. Сви болесници су имали значајно повишен енддијастолни дијаметар леве коморе (z-скор 6,6 ± 2,43) и леве преткоморе (z-скор 3,09 ± 0,37), уз ослабљену систолну функцију (ејекциона фракција 34,8 ± 7,4% и фракција

скраћења 15,5 ± 3,4%). Просечна старост болесника на операцији је била 8,2 ± 7,8 месеци. Операција је повезана са раним побољшањем ехокардиографских параметара (осим дијаметра леве преткоморе). Параметри су праћени 4,5 ± 2,6 година. Побољшање ехокардиографских параметара је било повезано са старошћу болесника. Болесници који су били оперисани ≤ 4 месеца имали су рани опоравак после хирургije, они који су третирани у узрасту 5,5–6 месеци имали су нормализацију после 12 месеци од операције, а болесник који је препознат у другој години живота имао је касни опоравак (после ≥ 24 месеца).

Закључак Оперативно лечење у прва 3–4 месеца живота је повезано са најповољнијом прогнозом и најбржом нормализацијом ехокардиографских параметара.

Кључне речи: ALCAPA; кардиомиопатија; ехокардиографија