



CASE REPORT / ПРИКАЗ БОЛЕСНИКА

A case of a three-month-old female infant with incarcerated femoral hernia

Jovan Mladenović, Nebojša Videnović, Milan Filipović, Raša Mladenović, Zlatan Elek
University of Priština – Kosovska Mitrovica, Faculty of Medicine, Kosovska Mitrovica, Serbia

SUMMARY

Introduction Femoral hernia in children is very rare and it appears in 0.2% of all hernias during childhood. It is three times more frequent in girls. The aim of this paper is to present a female infant with incarcerated femoral hernia.

Case outline A female infant aged three months was hospitalized with classical clinical signs of incarcerated left femoral hernia. After preoperative preparation, a transversal inguinal incision was performed on the left side and an incarcerated femoral hernia was confirmed with a torn and gangrenous left ovary and fallopian tube. Following adnexectomy, the hernia sac was ligated and resected and hernioplasty was made by the reconstruction of the Cooper's ligament.

Conclusion A delayed surgical intervention for incarcerated femoral hernia in a female can result in a loss of the ovary and the fallopian tube, which may lead to serious consequences later in life.

Keywords: femoral hernia; incarceration; ovary and fallopian tube

INTRODUCTION

According to McVay and Savage [1], hernias represent a defect in the continuity of the normal musculo-aponeurotic and fascial abdominal wall. They can be either congenital or acquired, with a protrusion of the abdominal cavity contents through the openings of the abdominal wall. Persistent patent *processus vaginalis* is presented by the peritoneal turn-up which goes from the inguinal region to the scrotum or labium [2]. Femoral and direct inguinal hernias in children are very rare.

Femoral hernia is the type of hernia in which a protrusion engages the femoral ring and *fascia transversalis*, penetrating into *regio cruralis* through relatively small femoral openings.

Femoral canal has got the shape of a cone with two holes. The first one, femoral ring, which is the entry part of the femoral canal, and the second one, much smaller, is the lower femoral hernia opening or saphenous opening, which stands a few centimeters lower of inguinal ligament. The saphenous opening is the exit part. Accordingly, femoral hernia is diagnosed only when the contents of the femoral hernia pass through the canal. In normal conditions, alongside the connective tissues are some small lymph nodes (Cloquet–Rosenmuller). Above the distal femoral hernia hole there is *fascia cribriformis*.

The anatomical variation of the narrow posterior inguinal wall attachment on to the pectineal ligament, resulting in an enlarged femoral ring, may be the primary etiological factor, according to Tasche [3]. The increased intraabdominal pressure enables the herniation.

Incarcerated femoral hernias are more frequent in comparison with direct and indirect inguinal hernias. It is important to diagnose this state in an appropriate time because complications can endanger a patient's life.

CASE REPORT

A girl of three months was admitted for immediate treatment at the local health center. Upon admission, the child showed clinical signs of a very ill patient. The abdomen was lightly painful in the lower parts. In the left inguinal area, there was a nut-sized lump with erythematous skin. The symptoms began five days previously with irritability and crying. She arrived to her doctor after three days due to objective reasons. The symptoms did not improve and she was hospitalized. According to the history and clinical work-up (Table 1), a surgical intervention under general anesthesia was indicated. A transversal inguinal incision was made. The

Table 1. Values of blood test results on admission

Blood element	Value
RBC	$3.7 \times 10^{12}/l$
HGB	113 g/l
HCT	0.32 l/l
WBC	$27 \times 10^9/l$
GRA	83%
LYM	12%
MON	4.5%
EO	0.5%

RBC – red blood cells; HGB – hemoglobin; HCT – hematocrit; WBC – white blood cells; GRA – granulocytes; LYM – lymphocytes; MON – monocytes; EO – eosinophils

Received • Примљено:

March 1, 2018

Revised • Ревизија:

June 11, 2018

Accepted • Прихваћено:

July 18, 2018

Online first: August 7, 2018

Correspondence to:

Jovan MLADENović
Faculty of Medicine
University of Priština
Anri Dinana bb
38220 Kosovska Mitrovica
Serbia
dr_jovan@yahoo.com

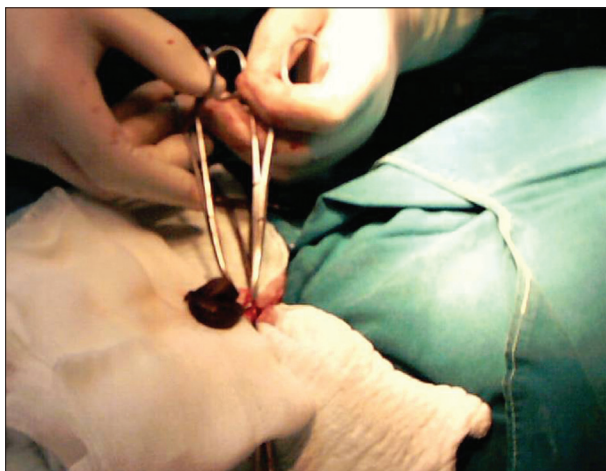


Figure 1. Femoral hernia with a gangrenous ovary

twisted and gangrenous ovary and fallopian tube were found in the hernial sac (Figure 1). Left adnexectomy was performed (Figure 2). The hernial sac was ligated and resected. Hernioplasty was made by the reconstruction of the Cooper's ligament and the wound was closed by layers. The operation was uneventful and postoperative period was without complications.

DISCUSSION

Femoral hernias are very rare in children. A review by Fonkalsrud et al. [4] of 5,452 cases, and Burke's [5] review of 4,567 patients showed only 21 (0.2%) patients with femoral hernias. The age of the patients was from six weeks to 13 years. Five patients had strangulated femoral hernias [4–7]. They are more frequent in girls than in boys (3:1) [8].

In our case, we had incarcerated femoral hernia on the left side, whose content was fallopian tube and ovary. In the literature it is described as a rare occurrence [9, 10].

In the modern surgical practice, there is a tendency to diagnose every type of hernia as soon as possible, which makes the intervention easier and provides better postoperative results.

Incarcerated hernias pose serious complications. Usually, incarcerated organs are the small intestine, the colon, the appendix, the omentum, the ovaries, and the fallopian tubes. In incarcerated hernias, manual reposition by taxis can be dangerous, so immediate surgical interventions are suggested.

The diagnosis, treatment, and the prognosis of incarcerated hernias depend on the degree of the pathological changes in venous and arterial blood flow of incarcerated




Figure 2. Adnexectomy on the left side

organs [11]. If this process continues for a sufficient period of time, which can vary from hours to days, herniated content becomes gangrenous and necrotic.

The optimal chosen method for the type of hernia is a precondition for optimal postoperative results. The method should be maximally physiological, and the disruption of the functional integrity of the back wall of the inguinal canal should be as little as possible. Our choice was the method which, in the presented case, provides the best result. A good result is characterized by small postoperative morbidity and low percentage of recurrence.

We used the McVay's repair method, which is usually the most common treatment for femoral hernias in children, and some surgeons state that it gives fewer recurrences [12, 8]. In femoral hernia surgery, it is essential to ligate the sac, manage the posterior wall of the inguinal canal, and suture the femoral ring regardless of which method is used [13, 14].

In order to avoid complications which can lead to strangulated hernias, adequate checkup is needed, as well as the correct and opportune diagnosis as an indication for surgical treatment. In the presented case, the situation was perceived and the baby girl of three months was brought to the surgeon too late. During the operation, the most appropriate surgical method for a twisted and gangrenous ovary and fallopian tube was adnexectomy.

Even with serious consequences for the patient, we expect her to retain adequate reproductive possibilities with preserved functionality.

Conflict of interest: None declared.

REFERENCES

1. McVay CB, Savage LE. Etiology of Femoral Hernia. *Annals of Surgery*. 1961; 154(Suppl 6):25–32.
2. Applebaum H, Bautista N, Cymerman J. Alternative method for repair of the difficult infant hernia. *J Pediatr Surg*. 2000; 35(2):331–3.
3. Tasche LW. Etiology of femoral hernia. *Arch Surg*. 1932; 25:749–82.
4. Fonkalsrud EW, de Lorimer AA, Clatworthy HW Sr. Femoral and direct inguinal hernias in infants and children. *J Am Med Assoc*. 1965; 192:101–3.
5. Burke J. Femoral hernia in childhood. *Ann Surg*. 1967; 166(2):287–9.
6. Al-Shanafey S, Giacomantonio M. Femoral hernia in children. *J Pediatr Surg*. 1999; 34:1104–6.

7. Radcliffe G, Stringer MD. Reappraisal of femoral hernia in children. *Br J Surg.* 1997; 84(1):58–60.
8. Tam PK, Lister J. Femoral hernia in children. *Arch Surg.* 1984; 119:1161–4.
9. Shepler NB, Smith CW. Femoral hernia in infancy. *Am J Surg.* 1949; 49:375–7.
10. Cloquet JG. Nouvelles recherches sur la hernies de l'ovarie [Cited in Puech, A]. *Ann Gyne'col (Paris).* 1878-1879; 10:321–38.
11. Rajput A, Gauderer MWL, Hack M. Inguinal hernias in very low birth weight infants: Incidence and timing of repair. *J Pediatr Surg.* 1992; 27(10):1322–4.
12. Marshall DG. Femoral hernias in children. *J Pediatr Surg.* 1983; 18:160–2.
13. Tsushimi T, Takahashia T, Gohraa H, Fukudaa S, Furukawaa S, Odaet T, et al. A case of incarcerated femoral hernia in an infant. *J Pediatr Surg.* 2005; 40(3):581–3.
14. Sorelli PG, El-Masry NS, Garrett WV. Open femoral hernia repair: one skin incision for all. *WJES.* 2009; 4:44.

Приказ тромесечног женског одојчета са инкарцерираном феморалном хернијом

Јован Младеновић, Небојша Виденовић, Милан Филиповић, Раша Младеновић, Златан Елек
Универзитет у Приштини – Косовска Митровица, Медицински факултет, Косовска Митровица, Србија

САЖЕТАК

Увод Феморална хернија код деце је изузетно ретка и јавља се у око 0,2% свих хернија дечје доби. Троструко је чешћа код деце женског пола. Приказујемо женско одојче са инкарцерираном феморалном хернијом.

Приказ болесника Женско одојче узраста три месеца хоспитализовано је са класичним клиничким знацима инкарцериране феморалне херније са леве стране. После преоперативне припреме направљен је попречни рез ингви-

нално лево, где је нађена укљештена феморална хернија са торквираним и гангренозно измењеним оваријумом и тубом утерином. После учињене аднексектомије, килна кеса је подвезана и ресецирана и направљена је пластика канала реконструкцијом Куперовог лигамента.

Закључак Прекасна хируршка интервенција је резултирала губитком левог аднекса, што може оставити озбиљне последице на њен даљи живот.

Кључне речи: феморална хернија; инкарцерација; оваријум