

ORIGINAL ARTICLE / ОРИГИНАЛНИ РАД

Laparoscopic technique as a method of choice in the treatment of non-parasitic splenic cysts

Vladimir Milosavljević¹, Boris Tadić², Nikola Grubor², Dragan Erić³, Slavko Matic²¹Stefan Visoki General Hospital, Smederevska Palanka, Serbia;²Clinical Centre of Serbia, First Surgical Clinic, Clinic for Digestive Surgery, Belgrade, Serbia;³University of Belgrade, Institute of Nuclear Sciences, Belgrade, Serbia**SUMMARY**

Introduction/Objective Splenic cysts are a rare clinical entity. In their origin, they may be parasitic or non-parasitic. They are classified as either primary (true) or secondary cysts (pseudocysts), depending on the presence or absence of an epithelial lining of the lumen.

Methods Using a retrospective case study, we included 29 patients undergoing laparoscopic surgery due to splenic cysts. The patients were treated within the 2007–2017 period at the Clinic for Digestive Surgery, the Clinical Center of Serbia. We analyzed pre-operative, intra-operative and post-operative characteristics of laparoscopic technique in treating non-parasitic splenic cysts.

Results The group of 29 patients treated with laparoscopic technique surgery due to the previously diagnosed splenic cyst, consisted of 12 (41.4%) men and 17 (58.6%) women. The average age of patients undergoing surgery was 38.86 ± 10.4 years (22–62). Based on the histopathological findings, there were eight epithelial cysts and 21 pseudocysts of the spleen. The maximal diameter of the splenic cyst, measured pre-operatively, was 10.09 ± 2.51 cm on average. The average operative time was 35 minutes, and the intra-operative bleeding amount was 11.48 ± 3.78 ml. None of the intra-operative complications, injury to the spleen or other organs of the abdomen, conversions to open surgery or reintervention were recorded.

Conclusion Laparoscopic fenestration with excision of the part of the spleen cyst wall (marsupialization) represents an effective and definitive treatment for this disease. It is an alternative to splenectomy, along with other well-known benefits ensured by the spleen preservation. Low probability of occurrence of intra-operative and post-operative complications, as well as minimal trauma of tissue, results in a shorter postoperative stay, rapid recovery, and better quality of life.

Keywords: cyst; spleen; laparoscopy; laparoscopic technique

INTRODUCTION

Splenic cysts are a rare disease. In their origin, they can be parasitic and non-parasitic. Echinococcal splenic cyst is the most common type of parasitic ones [1]. Depending on the presence of epithelium that covers the lumen of the cyst, cysts are divided into primary (true) and secondary (pseudocysts). The primary ones are epithelial (epidermoid, dermoid, mesothelial) or endothelial (hemangioma, lymphangioma) [2]. Primary cysts are most commonly found in children and younger persons, comprising about 25% of all non-parasitic cysts. In most cases, they are asymptomatic [3]. Secondary cysts are usually the result of trauma [1]. Common physical symptoms are pain or discomfort in the left upper abdominal quadrant, nausea and vomiting resulting from the compressive effect on the stomach. Larger sized splenic cysts can be presented as a palpable mass in the upper part of the abdomen [4].

Various treatment options are used to treat splenic cysts. A conservative treatment, followed through regular diagnostic examinations (abdomen ultrasound, computerized tomography, magnetic resonance), is generally applied when

the cyst is less than 5 cm in diameter and not a symptomatic one [5]. When the diameter of the cyst exceeds 5 cm or in case of any associated symptomatology, surgical treatment is required due to possible complications such as bleeding, cyst rupture and abscess formation [6]. Other treatment modalities include splenectomy, partial splenectomy, puncture-aspiration-injection-reaspiration (PAIR) technique, partial excision, and marsupialization of the splenic cysts. Spleen preservation should be considered as the most important factor in selecting a surgical procedure [7].

The benefit of the splenic preservation during surgery is in the fact that the splenectomized patients are at high risk of post-splenectomy sepsis. It can occur five years after the surgery, and in very rare cases a decade after the surgery. This indicates a long-term increased infection risk at splenectomized patients [8].

The objectives of this study are the analysis of the pre-operative characteristics of the patients treated with laparoscopic surgery, as well as the intra-operative parameters, bleeding, and surgery duration. Post-operative parameters, the duration of post-operative hospital stay, the timing of drain removal, as well as the evaluation

Received • Примљено:
October 8, 2018

Revised • Ревизија:
February 23, 2019

Accepted • Прихваћено:
April 2, 2019

Online first: April 3, 2019

Correspondence to:

Boris TADIĆ
Clinical Centre of Serbia
First Surgical Clinic
Clinic for Digestive Surgery
Dr Koste Todorovića 6
Belgrade 11000
Serbia
tadicboris@yahoo.com

of the effectiveness of laparoscopic treatment have also been within the scope of this analysis.

METHODS

Using a retrospective case study, we included 29 patients undergoing laparoscopic surgery due to splenic cysts. The patients were treated within the 2007–2017 period at the Clinic for Digestive Surgery of the Clinical Center of Serbia, Belgrade, in accord with standards of the institutional Committee on Ethics. As a part of the pre-operative investigation, the patients had undergone diagnostic imaging (ultrasound examination, computerized tomography or magnetic resonance imaging), which provided data regarding the size of the cyst. Serological analyses of parasitic diseases and tumor marker tests had been performed before surgery in the pre-operative assessment. Tumor markers Ca 19.9 and CEA had normal values in all the patients. The study excluded patients with proven parasitic splenic disorder, patients in whom, based on imaging findings (e.g. cystic change involves the splenic hilum, large cysts with minimal residual normal splenic tissue, etc.), decision to undergo total splenectomy had been made, as well as patients with contraindications for laparoscopic surgery due to comorbidity. Most of our patients were asymptomatic. A small group of patients had unspecific complaints in the form of dull pain in the upper abdomen or feeling of abdominal discomfort. We had no pregnant women in our study.

The parameters we monitored in this study were divided into the following three groups: 1. Pre-operative, including: sex, age, body mass index (BMI), size of splenic cysts; 2. Intra-operative, including the duration of the operation, intraoperative blood loss, intraoperative complications (conversions, instrumental injuries of the spleen and other organs) 3; Post-operative, including: the duration of postoperative stay, time of drain removal, post-operative complications, reintervention, histopathological findings based on which the cysts have been classified, as well as the average duration of postoperative monitoring of the treated patients.

In all the treated patients, laparoscopic fenestration and wall cyst excision was done along with the spleen preservation. Laparoscopic fenestration with excision of the cyst wall is performed under general endotracheal anesthesia. The patients were placed in the right lateral position, i.e. so-called hanging spleen technique position, due to its advantages, which so far have been proven on numerous occasions [9]. Cyst fenestration and the aspiration of its content is performed by laparoscopic harmonic scalpel (Ultracision®, Ethicon Inc., Somerville, NJ, USA) (Figure 1). The cyst wall is excised to the maximum possible extent. A part of a large omentum is placed in the cyst cavity after rinsing, aspiration, and proven homeostasis. At the end of the surgery, the drain is placed in the left subphrenic space.

The Clavien–Dindo Scale was used to define the ranking of postoperative complications. The first postoperative examination took place three months after the operation and included an abdominal ultrasound. The second one,

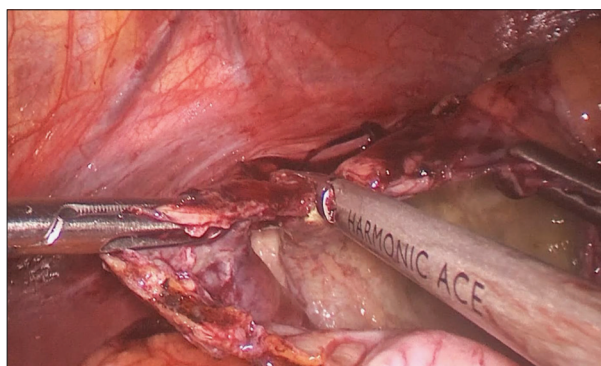


Figure 1. Intraoperative photo – cyst wall excision

a year after, included CT scan. Every six months from then, patients were checked-up by abdominal ultrasound. Five years after the operation, an abdominal ultrasound examination was performed once a year.

RESULTS

The group of 29 patients treated with laparoscopic technique due to previously diagnosed splenic cyst consisted of 12 (41.4%) men and 17 (58.6%) women. The average age of patients was 38.86 ± 10.40 years (22–62) and the average weight expressed in BMI was 23.03 ± 2.65 . The maximal diameter of the splenic cyst, measured pre-operatively, was 10.09 ± 2.51 cm on average (Table 1).

Abdominal drain was removed on the first postoperative day, while the average postoperative stay was two days (1–3). The average operative time was 35 minutes and intraoperative bleeding volume was 11.48 ± 3.78 ml (Table 2). Based on the histopathological findings, there were eight epithelial cysts and 21 pseudocysts of the spleen. Postoperative complications were classified based on the Dindo–Clavien Scale (Table 3). None of intraoperative complications, injury to the spleen or other organs of the abdomen, conversions to open surgery or reintervention were recorded. The average period of postoperative follow-up was four years (1–10).

DISCUSSION

In 1985, Salky et al. [6] initially reported laparoscopic surgery as a treatment option for splenic cyst, with a good outcome and without recurrence of the disease after eight months. In their series of 32 cases, Robertson et al. [10] found that the recidivism rate after the laparoscopic operation was 22%, but a new surgical intervention was required in only 3% of the patients. In order to reduce the risk of recurrence of the disease, it is considered necessary to remove as much of the wall of the cyst as possible [2, 11, 12].

The modalities of the surgical treatment of splenic cysts are different. They vary from the application of minimally invasive surgical procedures such as cyst fenestration, cyst marsupialization, PAIR, partial splenectomy, and total

Table 1. Preoperative patients' characteristics

Patients' characteristics	Male	Female	Description
Number of patients	12 (41.4)	17 (58.6)	29 (Summary)
Age	40.3	37.8	38.86 ± 10.40 ($\bar{x} \pm sd$)
BMI	22.5	23.4	23.03 ± 2.65 ($\bar{x} \pm sd$)
Cyst size (cm)	10.4	9.9	10.09 ± 2.51 ($\bar{x} \pm sd$)

BMI – body mass index

Table 2. Surgery data

Parameter	Med. (min.–max.) or ($\bar{x} \pm sd$)
Surgery time (minutes)	35 (28–65)
Intraoperative bleeding (ml)	11.48 ± 3.78
Postoperative stay (days)	3 (2–4)
Drainage (days)	2 (1–3)

Table 3. Postoperative complications according to Dindo–Clavien Scale

DC class	Patients n (%)
I	5 (17.2)
II	3 (10.3)
III	0
IV	0
V	0

DC – Dindo–Clavien

splenectomy [7, 13, 14]. Some studies have proven that laparoscopic fenestration in the treatment of non-parasitic splenic cyst is an acceptable treatment method, with an acceptable rate of disease recurrence. The accent is on the need for resecting as much of the cyst wall as possible, in order to prevent recurrence [15, 16]. In our series, a laparoscopic fenestration including wall excision of a splenic cyst was performed in all patients. PAIR technique is applicable in non-parasitic splenic cysts, but carries a higher risk of recurrence, up to 29% in some series [17]. This technique is justified in patients with severe comorbidities and contraindications for operative treatment, as well as in patients who do not consent to surgical treatment. Laparoscopic partial splenectomy can be applied in the treatment of non-parasitic splenic cysts with a low expectancy of recurrence. This technique is limited by the size and position of the cyst in regard to the vascular elements [5].

Spleen is an organ that has an important role in the human immune system. It also plays a significant role in filtering blood, removing old and dead erythrocytes and platelets. Considering all known modalities for treating non-parasitic splenic cysts, preservation of the spleen offers benefit, especially in the younger population [18]. The method of choice for the treatment of benign splenic disorders, particularly in case of simple cysts, is the laparoscopic cyst marsupialization. It can be safely performed provided that the surgeon and the surgical team have the necessary experience and skills in laparoscopy. The minimally inva-

sive surgery enables rapid recovery, without complications usually associated with large laparotomy incisions [19].

The spleen has an important role in clearing bacteria from the circulation. Asplenic individuals are at increased risk of postsplenectomy sepsis (PSS). This fulminant and rapidly fatal illness complicates bacteremic infections and can be seriously threatened in splenectomized patients. The incidence of this syndrome is the highest in children who undergo splenectomy in infancy [20].

Davidson and Wall [21] reported that PSS carries a rather high mortality rate of 50–70%. The highest risk of PSS occurs during the first few years following splenectomy but has been documented as late as 40 years after splenectomy [8]. If surgical preservation of the spleen is not possible, it is recommended to perform pre-operative or post-operative vaccination of the patients within two weeks after splenectomy [9].

The results of our study show that our patients did not have either intra-operative complications, or conversions, but only minimal intraoperative blood loss. In the results published by Cai et al. [16], it is stated that the period of post-surgery hospital stay varied 24–48 hours. The average hospital stay in our series was 48 hours, but some patients were discharged after the first postoperative day.

Postoperative complications were ranked according to the Dindo–Clavien Scale. We had five patients who required additional therapy in the form of analgesics and antiemetics, and only three patients to whom we prescribed additional antibiotic therapy. We did not experience any other complications.

Cuervo and Buela [22] recommended reviewing computerized tomography once a year. Patients had been followed by periodic abdominal ultrasound and computerized tomography scan once a year. The average follow-up period in our study was four years. No case of the disease recurrence was recorded.

CONCLUSION

Laparoscopic fenestration with excision of the part of the spleen cyst wall (marsupialization) represents an effective and definitive treatment for this disease. It is an alternative to splenectomy, along with other well-known benefits ensured by the spleen preservation. The method implies a safe treatment with minimal bleeding. Low probability of occurrence of intra-operative and post-operative complications, as well as minimal trauma of tissue, results in a shorter post-operative stay, rapid recovery and better quality of life.

Conflict of interest: None declared.

REFERENCES

- Adrian PE, Eduardo TM. Spleen. In: Brunicaardi FC, Andersen DK, Billiar TR, Dunn DL, Hunter JG, editors. *Schwartz's principles of surgery*. Tenth edition. ed. New York: McGraw-Hill Education; 2015. p. xviii, 2069 pages.
- Shabtaie SA, Hogan AR, Slidell MB. Splenic Cysts. *Pediatric Annals*. 2016; 45(7):e251–e6.
- Daniel AA. Spleen. In: Goldblum JR, Lamps LW, McKenney JK, Myers JL, Ackerman LV, Rosai J, editors. *Rosai and Ackerman's surgical pathology*. 11th edition ed. Philadelphia: Elsevier; 2018. p. 2 volumes.
- Mirilas P, Mentessidou A, Skandalakis JE. Splenic cysts: are there so many types? *J Am Coll Surg*. 2007; 204(3):459–65.
- Manciu S, Tudor S, Vasilescu C. Splenic Cysts: A Strong Indication for a Minimally Invasive Partial Splenectomy. Could the Splenic Hilar Vasculature Type Hold a Defining Role? *World J Surg*. 2018; 42(11):3543–50.
- Salky B, Zimmerman M, Bauer J, Gelernt I, Kreel I. Splenic cyst – definitive treatment by laparoscopy. *Gastrointest Endosc*. 1985; 31(3):213–5.
- Vijayaraghavan R, Chandrashekar R, Aithal S, Rashmi MV, Belagavi CS. Mesothelial cyst of the spleen in an adult: a case report. *BMJ Case Rep*. 2010; 2010.
- Fernández-López AJ, Candel-Arenas M, González-Valverde FM, Luján-Martínez D, Medina-Manuel E, Albarracín Marín-Blázquez A. Escisión laparoscópica en quiste esplénico sintomático. *Cirugía y Cirujanos*. 2017; 85:26–9.
- Buzele R, Barbier L, Sauvanet A, Fantin B. Medical complications following splenectomy. *J Visc Surg*. 2016; 153(4):277–86.
- Robertson FM, Doski JJ, Cofer BR, Kidd JN. Laparoscopic Splenic Cystectomy: A Rational Approach. *Pediatric Endosurgery & Innovative Techniques*. 2004; 8(4):321–6.
- Conlon KC, Geraghty M, Khan IZ. Large primary splenic cyst: A laparoscopic technique. *Journal of Minimal Access Surgery*. 2009; 5(1):14.
- Al Khafaji B, Younis MU. Laparoscopic splenic cyst fenestration-a viable spleen preserving option. *J Surg Case Rep*. 2017; 2017(8):rjx154.
- Quesada R, Poves I, Iglesias M, Berjano E, Grande L, Burdío F. Laparoscopic partial splenectomy for giant cyst using a radiofrequency-assisted device: a case report. *Surg Case Rep*. 2016; 2(1):82.
- Putnik S, Ilic M. Partial resection of the splenic cyst using radiofrequency ablation system. *Srp Arh Celok Lek*. 2017; 145(5–6):301–3.
- Farhangi B, Farhangi A, Firouzjahi A, Jahed B. Huge epithelial nonparasitic splenic cyst: A case report and a review of treatment methods. *Caspian J Intern Med*. 2016; 7(2):146–9.
- Cai H, An Y, Wu D, Chen X, Zhang Y, Zhu F, et al. Laparoscopic Partial Splenectomy: A Preferred Method for Select Patients. *J Laparoendosc Adv Surg Tech A*. 2016; 26(12):1010–4.
- Akhan O, Dagoglu-Kartal MG, Ciftci T, Ozer C, Erbahceci A, Akinci D. Percutaneous Treatment of Non-parasitic Splenic Cysts: Long-Term Results for Single- Versus Multiple-Session Treatment. *Cardiovasc Intervent Radiol*. 2017; 40(9):1421–30.
- Hassoun J, Ortega G, Burkhalter LS, Josephs S, Qureshi FG. Management of nonparasitic splenic cysts in children. *J Surg Res*. 2018; 223:142–8.
- Kenney CD, Hoeger YE, Yetasook AK, Linn JG, Denham EW, Carbray J, et al. Management of non-parasitic splenic cysts: does size really matter? *J Gastrointest Surg*. 2014; 18(9):1658–63.
- Theilacker C, Ludewig K, Serr A, Schimpf J, Held J, Bogelein M, et al. Overwhelming Postsplenectomy Infection: A Prospective Multicenter Cohort Study. *Clin Infect Dis*. 2016; 62(7):871–8.
- Davidson RN, Wall RA. Prevention and management of infections in patients without a spleen. *Clin Microbiol Infect*. 2001; 7(12):657–60.
- Cuervo JL, Buela E. [Splenic epidermoid cyst: laparoscopic partial decapsulation]. *Cir Pediatr*. 2007; 20(1):63–7.

Лaparоскопска техника као метод избора у третману непаразитних циста слезине

Владимир Милосављевић¹, Борис Тадић², Никола Грубор², Драган Ерић³, Славко Матић²

¹Општа болница „Стефан Високи“, Смедеревска Паланка, Србија;

²Клинички центар Србије, Клиника за дигестивну хирургију, Прва хируршка клиника, Београд, Србија;

³Универзитет у Београду, Институт за нуклеарне науке, Београд, Србија

САЖЕТАК

Увод/Циљ Цисте слезине представљају редак клинички ентитет. Према њиховом пореклу могу бити паразитне и непаразитне. У зависности од присуства или одсуства епителујалног омотача, цисте слезине се деле на примарне (праве) и секундарне (псеудоцисте).

Метод Студија је рађена као ретроспективна студија серије случајева у коју је укључено 29 болесника који су били подвргнути лапароскопском хируршком третману због циста слезине у периоду 2007–2017. године на Клиници за дигестивну хирургију Клиничког центра Србије. Анализиране су преоперативне, интраоперативне и постоперативне карактеристике болесника код којих је била примењена лапароскопска хируршка техника у третману непаразитних циста слезине.

Резултати У групи од 29 болесника оперисаних лапароскопском техником код којих је преоперативно дијагностиковано постојање непаразитних цисти слезине било је 12 (41,4%)

мушкараца и 17 (58,6%) жена. Просечна старост оперисаних болесника износила је 38,86 ± 10,40 година (22–62). Хистопатолошким прегледом верификовано је осам епителујалних циста и 21 псеудоциста слезине. Просечна димензија циста слезине која је мерена преоперативно износила је 10,09 ± 2,51 *cm*. Просечно време трајања операције било је 35 минута. Интраоперативни губитак крви износио је просечно 11,48 ± 3,78 *ml*. Није забележена ниједна интраоперативна компликација у смислу неконтролисаног интраоперативног крварења, повреде слезине или суседних органа.

Закључак Лапароскопска операција са одстрањивањем дела зида цисте слезине представља ефикасан третман овог обољења. Метода представља безбедан третман са минималним крварењем, уз малу вероватноћу појаве интраоперативних и постоперативних компликација.

Кључне речи: циста; слезина; лапароскопија; лапароскопска техника