

CURRENT TOPIC / AKTUELNA TEMA

Minimal invasive coronary bypass surgery – the robotic total endoscopic approach

Duško Terzić¹, László Göbölös², Jehad Ramahi², Johannes Bonatti²¹Clinical Center of Serbia, Clinic for cardiac surgery, Belgrade, Serbia;²Heart and Vascular Institute, Cleveland Clinic Abu Dhabi, Abu Dhabi, United Arab Emirates**SUMMARY**

The aim of this paper is to present the latest recommendations for practitioners for preoperative preparation, surgical procedures and postoperative treatment in patients with myocardial revascularization using robotic total endoscopic coronary artery bypass grafting (CARG), which is applied as daily clinical routine practice at the Heart and Vascular Institute, Cleveland Clinic Abu Dhabi. Many patients indicated for coronary bypass surgery may be candidates for robotic total endoscopic CARG. The paper illustrates eligibility criteria of this procedure, preoperative assessment and preparation principles, peripheral access for cardiopulmonary bypass and port insertion, then graft harvesting procedure, initiation of cardiopulmonary bypass and application of endoaortic clamping, identification and exposure of the target vessels, anastomosis procedure and postoperative care in this group of patients.

Keywords: robotic; endoscopic; coronary artery bypass; TECAB

INTRODUCTION

In recent years, cardiac surgery has shifted its focus to developing and using minimally invasive procedures. These procedures differ from conventional approaches in incision size and level of invasion. Some of the advantages that these methods have are pain relief, improved cosmetic outcome, better postoperative respiratory function, faster rehabilitation and reintegration of the patient into his/her social community. After various minimally invasive procedures using small thoracotomy, robotic coronary artery bypass grafting (CARG) is a new and upgraded type of surgical myocardial revascularization.

This robotic CARG technique is both single and a multi-vessel procedure that can be performed on a beating heart as well as the arrested heart. Moreover, totally endoscopic coronary artery bypass surgery (TECAB), can also be done with percutaneous coronary interventions at the same time [1].

The da Vinci™ surgical system (Intuitive Surgical Inc., Sunnyvale, CA, USA) consists of a surgeon's console, a vision cart, and a surgical cart. The master remote console has two master handles that are manipulated by a surgeon in order to achieve three-dimensional, binocular, high-resolution magnified view of the operative field that is equivalent to the one in the open surgery. The system can also be downscaled by tuning the handles' motion ratio to the one of surgical instruments. Also, there is a motion filter for the prevention of unintended movements that are caused by human tremor. Thanks to these previously mentioned technological advantages, it's possible to achieve high-precision micro

sutures. It usually takes about six hours for the procedure to be completed. When it comes to perioperative results, they are similar to those that CABG procedures through sternotomy have. Also, the long-term survival and lower risk for major adverse cardiac and cerebral events are similar too (96% and 73% at five years, respectively) [1, 2] (Figure 1).

The most commonly used TECAB procedures are left internal mammary artery (LIMA) to the left anterior descending (LAD) artery or right internal mammary artery (RIMA) to LAD artery combined with LIMA to the left coronary arteries [circumflex (Cx) or diagonal] and creation of Y anastomosis whereby the LIMA is anastomosed to LAD and RIMA to RCA or Cx artery.

Eligibility criteria

The absolute contraindications for this procedure are cardiogenic shock, diffusely diseased coronary arteries, or intra myocardial coronary arteries, significant peripheral vasculopathy, pulmonary hypertension, severe lung impairment chest deformities, ascending aortic diameter > 3.8 cm and severe aortoiliac calcification, hemodynamic instability. The procedure carries the increased risk for complications and possible forced Intra-aortic balloon pump, previous heart surgery, previous severe chest trauma and chest irradiation as adhesions severely impaired left ventricular function [3, 4].

Preoperative assessment and preparation

The preoperative preparation is no different than the one for full sternotomy CABG. This

Received • Примљено:

May 21, 2018

Revised • Ревизија:

December 26, 2018

Accepted • Прихваћено:

January 15, 2019

Online first: March 7, 2019**Correspondence to:**

Duško TERZIĆ
Clinic for Cardiac Surgery
Clinical Center of Serbia
8 Dr. Koste Todorovića Street
11000 Belgrade, Serbia
terzic.dusko@gmail.com




Figure 1. A) The da Vinci™ surgical system – surgeon's console, surgical cart and vision cart; B) the da Vinci™ surgical system – surgical robot; C) surgical robot is docked to the patient; D) different technical variable "hand" devices contribute to high-precision surgical work (forceps, scissors, cautery spatula...)




Figure 2. Thoracic cavity with the instrument ports in place

preparation also includes double lumen intubation or bronchial blocker, TEE during the procedure, percutaneous defibrillator pads as well as NIRS monitoring.

The essential tool for monitoring the overall heart function is transesophageal echocardiography (TEE). TEE is also used to check the position or detect the incidental migration of the endoballoon during cardioplegic TECAB. It is also important to determine the initiation of a single lung ventilation as well as setting the level of CO₂ inflation pressure [5, 6].

Peripheral access cardiopulmonary bypass and port insertion

Based on our experience, the Cx or right CARG is reliable only on the arrested heart since it is completely flaccid and the it can be rotated to the adequate position for the procedure. Also, the equipment for the open CABG should be at your disposal all the time during the procedure.

In case of cardioplegic TECAB, the usual vascular exposure target is the left groin or subclavian-axillary artery. In this case, the venous drainage is achieved through 25 Fr cannula that is forwarded to the superior vena cava under the TEE guidance while the arterial perfusion cannula (21 or 23 Fr, equipped with the side arm) is placed into the femoral artery. [7, 8, 9].

After the anesthesiologist confirms that the left wing is completely deflated, the ports are placed on the left side of the thorax.

The camera port is placed on the fifth intercostal space, at the level of the anterior axillary line. The CO₂ should be insufflated at the pressure of 8 mmHg. If sudden hypotension or any other hemodynamic instability happens during this phase, the CO₂ pressure should be adjusted in order to avoid the venous return hindrance. The thoracic cavity should be inspected under the scope in order to properly place the right and left instrument ports (Figure 2). After this, the surgical robot is docked to the patient with the

cautery spatula and forceps mounted on the left and right manipulator arm, respectively (Figure 1c) [7, 8, 9].

Graft harvesting procedure and utility port placement

The internal mammary artery (IMA) can be visualized in "camera up" view of the 30° angled robotic device. IMA can be harvested in either pedicle or skeletonized form. If both IMAs have to be harvested retro sternal robotic endoscopic dissection is done in order to access the right pleural cavity [10]. If you're harvesting both LIMA and RIMA, the RIMA should be harvested before the left one. If not, there's a high chance that the LIMA will compromise surgeon's view and accessibility for the rest of the procedure. After the IMA is harvested, a 5 mm utility port is placed under the scope control in the left parasternal region, on the opposite side of the camera port. This port will allow the delivery of supplies for the surgical procedure [8, 9, 10].

Initiation of the cardiopulmonary bypass and application of endoclamp (ballon) occlusion.

It is important that there is no significant atherosclerosis in the thoracic aorta. Also, the ascending diameter should not exceed 38 mm and the aortic valve has to be fully functional in order to place the endoballoon (guide wire is inserted through a special arterial cannula side-arm under continuous ultrasound control) above the aortic valve in case of the endoclamp occlusion. The endoballoon system has a special line for management of cardioplegia, which is connected with the extracorporeal device. The system possesses manometers, which measure the endoballoon and root pressures precisely [11].

If significant atherosclerosis of lower arterial trunk is present, the left subclavian artery should be used for cannulation. Initial suturing of 8 mm Dacron graft to subclavian artery or axillary artery is suggested, which serves to connect the arterial line.

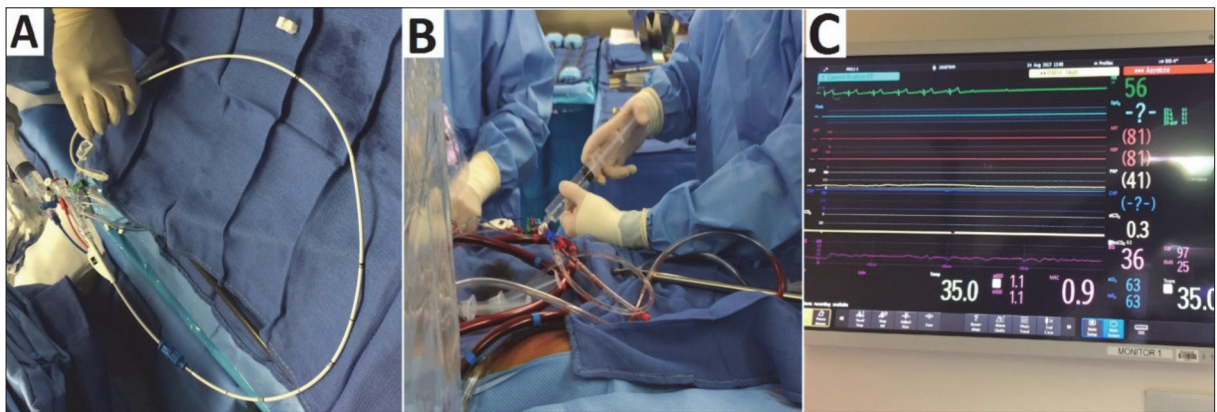


Figure 3. A) The endoballoon system; B) rapid cardioplegic induction can be established by the administration of adenosine; C) ECG confirmation of stopping the heart immediately after adenosine infusion

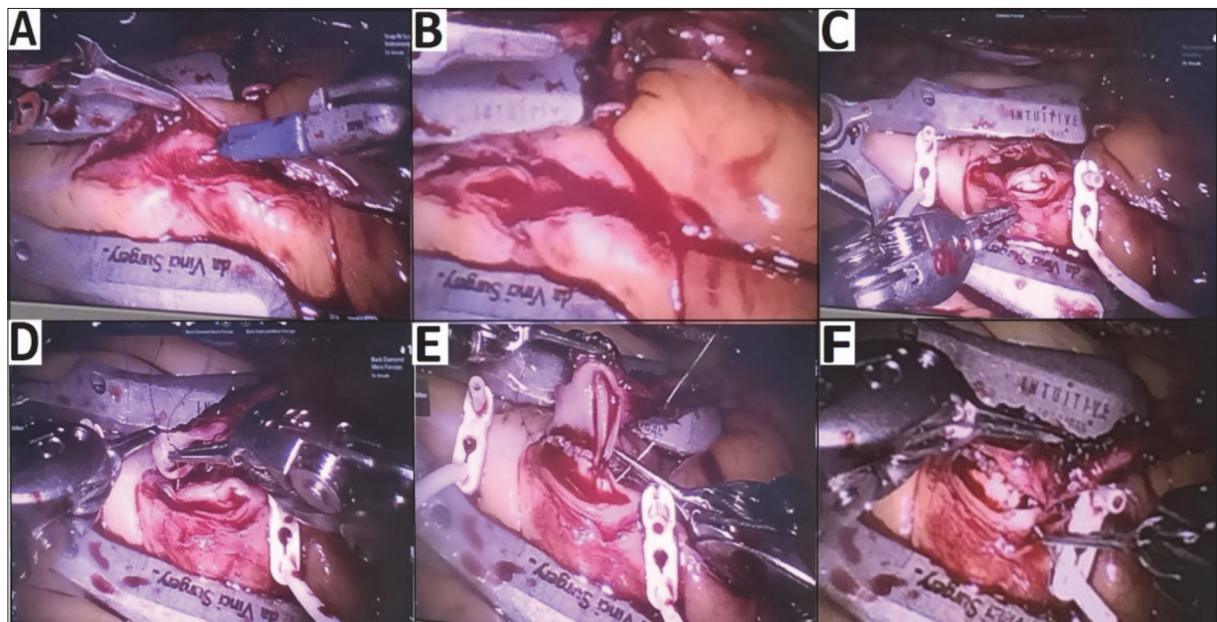


Figure 4. A) With DeBakey forceps and a robotic beaver knife the target vessel is opened; B) incision is extended to approximately 4 mm; C) the blood flow of the vessel has to be ensured; D) the initial stitch is placed "back hand" on the toe of the coronary in an inside-out fashion; E) after the first three throws the graft is parachuted down to the coronary level; F) adequate suture line tension on the back wall in order to avoid leaks

The endoballoon catheter might still be inserted in most cases through a separate 19 Fr cannula placed into the common femoral artery [12, 13]. If the insertion of endoballoon through the femoral artery is assessed to be an extremely high-risk procedure, the method of choice would be a beating heart TECAB with formerly provided support of extracorporeal circulation (stand-by cannula in axillary artery) [12, 13].

The endoballoon is inflated when a sufficient venous drainage is achieved along with low blood pressure and no ventricular ejections. The correct position of the endoballoon in the aortic root can be echocardiographically confirmed. The cardioplegic solution is administered after the inflation of the endoballoon. The fast cardioplegic induction can be achieved by administration of adenosine (6 mg/20 mL of normal saline). After the stable position of the endoballoon is confirmed, the cooling process can be initiated. The cardioplegia should be repeated once every 20 minutes [1, 2, 13] (Figure 3).

Identification and exposure of the target vessels

In "camera down" view, the pericardium is opened just above the right ventricular outflow tract. The incision is made towards the substernal part of the pericardial reflection, and extended laterally. In cranial direction, the aperture goes towards the phrenic nerve, which needs to be identified always [1, 3].

The robotic endostabilizer, inserted through a 12 mm port that is located two fingers away to the left side of the xiphoid, provides an effective support for different structures on the surface of the heart. The insertion process is guided by the robotic camera in "up facing" view. The subcostal port is connected to the fourth arm of the da Vinci system (Figure 4).

In order to have the optimal view and access to the target coronary arteries, the camera is set in the "face down" position. The LAD and Cx coronary artery branches can be adequately reached with the aid of subcostal endostabilizer




Figure 5. Final result – completed anastomosis

device. The endostabilizer is activated by a dedicated foot pedal while the suction pods are lined-up along the target area. This way, the local immobilization is achieved and the target coronary arteries are moved into position that is suitable for a surgeon [13]. The right ventricular acute margin can be lifted up with the aid of the endostabilizer, this provides an excellent access to the posterior descending artery or posterolateral artery. It should be noted that we've applied this method only for TECAB on the arrested heart. In case of a beating heart procedure, the endostabilizer has to be used cautiously on the right ventricular surface since there's a risk for accidental perforation [14, 15].

Robotic endoscopic coronary anastomosis procedure

After re-checking the graft suitability, the facet of the graft that was previously occluded by a bulldog is shaped in an oblique manner and opened for 4 mm in total length in order to achieve a "cobra head" anastomotic profile. The blood flow of the vessel has to be ensured.

After this, the incision is extended to about 4 mm in length while the 7 cm long double-armed polypropylene suture is supplied via parasternal utility port.

The initial stitch is placed "back hand" on the toe of the coronary in an inside-out fashion (Figure 4d, 4e, 4f). At the end of creation of anastomosis, the completed suture line has to be meticulously inspected for slings. Slings can be corrected with the aid of suture needles (Figure 5) [7, 10].

Detailed video presentation of the distal anastomosis creation with a review of technical challenges may be

found on the following link: <http://www.youtube.com/watch?v=l6DiBz2JUnY>

In case of beating heart procedures, proximal occlusion devices for bleeding control and intraluminal shunts providing distal flow during anastomosis creation are applied. Beta blockers are used to slow down heart frequency, which in turn ensures better visual control. Before clinical practice, during a surgeon's specialized training, he/she should be provided, with sufficient number of training hours in dry- and wet-lab settings [16].

Final tasks and postoperative care

The left pleural drainage is a must before ending the procedure. If necessary, it should be done with the right pleural cavity too, by using the thoracic drains. The robot is docked and the instruments are parked in the IMA bed after the anastomoses are created and patient is taken off the cardiopulmonary bypass machine. This step is necessary because the heart is filling with blood after decannulation. Also, it may be required to insert instruments again. After this, the last robotic inspection of the thoracic cavity is done, followed by an observation from both console surgeons and the tableside team. Once the sufficient hemostasis is achieved, the robotic system is undocked but the ports are still left in position. This is done in order to avoid the leakage of CO₂. Then the ports are removed under the scope vision, and the portholes are cauterized and packed with surgical hemostat material. The chest drain is inserted via the camera porthole. This procedure should be carried out with the inflated left lung in order to avoid graft injuries at the final phase of the operation. [3, 7, 13].

CONCLUSION

Nowadays, about 30% of CABG patients can be done in a robotic endoscopic fashion, and it is possible to revascularize any coronary artery at institutions that provide a competent practice in this field of medicine. Multi-vessel TECAB definitely takes more time than a single vessel procedure. Moreover, the rate of conversion to sternotomy is high due to the technical complexity of the procedure. Some of the most important advantages of multi-vessel TECAB are much shorter recovery, completely preserved sternum and utilization of double IMA.

Conflict of interest: None declared.

REFERENCES

- Bonatti J, Schachner T, Bonaros N, Lehr E, Zimrin D, Griffith B. Robotic assisted endoscopic coronary bypass surgery. *Circulation*. 2011; 124(2):236–44.
- Iribarne A, Easterwood R, Chan EY. The golden age of minimally invasive cardiothoracic surgery: current and future perspectives. *Future Cardiol*. 2011; 7(3):333–46.
- Bonatti J, Lehr E, Vesely M, Schachner T, Bonaros N, Zimrin D. Hybrid Coronary Revascularization – Which patients, when, how. *Current Opinion in Cardiology*. 2010; 25(6):568–74.
- Vallely MP, Edelman JJ, Wilson MK. Bilateral internal mammary arteries: evidence and technical considerations. *Ann Cardiothorac Surg*. 2013; 2(4):570–7.
- Bernstein WK, Walker A. Anesthetic issues for robotic cardiac surgery. *Ann Card Anaesth*. 2015; 18(1):58–68.
- Chauhan S, Sukesan S. Anesthesia for robotic cardiac surgery: an amalgam of technology and skill. *Ann Card Anaesth*. 2010; 13(2):169–75.

7. Bonatti J, Wehman B, De Biasi AR, Griffith B, Lehr EJ. Totally endoscopic quadruple coronary artery bypass grafting is feasible using robotic technology. *Ann Thorac Surg.* 2012; 93(5):e111–2.
8. Lytle BW. Bilateral internal thoracic artery grafting. *Ann Cardiothorac Surg.* 2013; 2(4):485–92.
9. Lehr EJ, Odonkor P, Reyes P, Bonatti J. Minimized extracorporeal circulation for the robotic totally endoscopic coronary artery bypass grafting hybrid procedure. *Can J Cardiol.* 2010; 26(7):e286–7.
10. Oehlinger A, Bonaros N, Schachner T, Ruetzler E, Friedrich G, Laufer G, et al. Robotic endoscopic left internal mammary artery harvesting: what have we learned after 100 cases? *Ann Thorac Surg.* 2007; 83(3):1030–4.
11. Canale LS, Mick S, Mihaljevic T, Nair R, Bonatti J. Robotically assisted totally endoscopic coronary artery bypass surgery. *J Thorac Dis.* 2013; 5(Suppl 6):S641–9.
12. Bonatti J, Garcia J, Rehman A. On-pump beating-heart with axillary artery perfusion: A solution for robotic totally endoscopic coronary artery bypass grafting? *Heart Surg Forum.* 2009; 12(3):E131–3.
13. Bonatti J, Schachner T, Bonaros N. How to improve performance of robotic totally endoscopic coronary artery bypass grafting. *Am J Surg.* 2008; 195(5):711–6.
14. Seco M, Edelman JJ, Yan TD, Wilson MK, Bannon PG, Vallely MP. Systematic review of robotic-assisted, totally endoscopic coronary artery bypass grafting. *Ann Cardiothorac Surg.* 2013; 2(4):408–18.
15. Robinson BM, Paterson HS, Naidoo R, Dhurandhar V, Denniss AR. Bilateral internal thoracic artery composite y grafts: analysis of 464 angiograms in 296 patients. *Ann Thorac Surg.* 2016; 101(3):974–80.
16. Gao C, Yang M, Wu Y. Hybrid coronary revascularization by endoscopic robotic coronary artery bypass grafting on beating heart and stent placement. *Ann Thorac Surg.* 2009; 87(3):737–41.

Минимално инвазивна хируршка реваскуларизација миокарда применом ендоскопске робот технологије

Душко Терзић¹, Ласло Гебелеш², Џехад Рамахи², Јоханес Бонати²

¹Клинички центар Србије, Клиника за кардиохирургију, Београд, Србија;

²Кардиоваскуларни институт, Клиника Кливленд Абу Даби, Абу Даби, Уједињени Арапски Емирати

САЖЕТАК

Циљ рада је да се прикажу најновије препоруке везане за преоперативну припрему, хируршке процедуре и постоперативни третман код болесника којима је учињена реваскуларизација миокарда методом минимално инвазивне хируршке реваскуларизације употребом робот технологије, а која се свакодневно примењује као рутинска пракса на Кардиоваскуларном институту на Клиници Кливленд Абу Даби. Многи болесници са индикацијом за реваскуларизацију миокарда могу се разматрати као кандидати за робот

ендоскопску процедуру реваскуларизације срца. У раду су представљени критеријуми за одабир болесника, принципи преоперативне припреме, периферни приступ за канулацију и успостављање екстракорпоралног крвотока, пласирање портова за уређај, покретање вантелесне циркулације, методе привременог заустављања срчаног рада, индентификација коронарних крвних судова, принципи креирања анастомоза и постоперативна нега ове групе болесника.

Кључне речи: робот; ендоскопски; коронарни артеријски бајпас; *TECAB*