

CASE REPORT / ПРИКАЗ БОЛЕСНИКА

Pregnant woman survives aortic dissection, dies later of coronary embolism – a unique case of a non-compliant patient

Andrej Preveden^{1,2}, Golub Samardžija^{1,2}, Stamenko Šušak^{1,2}, Aleksandra Ilić^{1,2}, Aleksandar Redžek^{1,2}

¹University of Novi Sad, Faculty of Medicine, Novi Sad, Serbia;

²Institute for Cardiovascular Diseases of Vojvodina, Sremska Kamenica, Serbia



SUMMARY

Introduction The incidence of aortic dissection ranges 3–5 cases per 100,000 person-years. In women under the age of 40 who acquire aortic dissection, almost half of the cases happen during pregnancy.

Case outline We report a case of a 22-year-old pregnant woman in the 16th gestational week with a history of arterial hypertension and known aortic dilatation, who was admitted with aortic dissection. She underwent the Bentall procedure, in which her aortic valve, ascending aorta, and proximal part of the aortic arch were replaced using valved composite graft. On the next day, the evacuation abortion was made, since the fetus didn't survive the operation. Six years later, the patient stopped taking anti-coagulation therapy and was admitted for prosthetic valve thrombosis, which was successfully treated with intravenous heparin. One year later, the patient died of a myocardial infarction due to coronary thromboembolism, confirmed on autopsy.

Conclusion Preconceptional counseling in women with a known aortic disease is of the utmost importance. Aortic dissection in pregnant women is an acute life-threatening condition for both mother and fetus that should be managed by a multidisciplinary team. After a mechanical heart valve implantation, lifetime oral anticoagulants are mandatory.

Keywords: aortic dissection; pregnancy; anticoagulation therapy; prosthetic valve thrombosis; coronary embolism

INTRODUCTION

Aortic dissection (AD) is not a common disease, its incidence ranges 3–5 cases per 100,000 person-years [1]. Although almost two thirds of patients are male, an important fact is that in women under the age of 40 who acquire AD, almost half of the cases happen during pregnancy [2, 3].

The most important risk factor is arterial hypertension, while the others include aortic dilatation and aneurysm, aortic coarctation, bicuspid aortic valve, and connective tissue diseases like Marfan syndrome [2, 4].

Hypertension is considered to be a common disorder during pregnancy. About 1% of pregnant women have preexisting hypertension and about 5% develop gestational hypertension [5].

CASE REPORT

In June 2008, a 22-year-old pregnant woman in the 16th gestational week (GW) was admitted with heavy back and chest pain of sudden onset. She had a history of hypertension for the last five years and had her regular checkups. The last transthoracic echocardiography (TTE) had been performed two years prior to her admittance, when the ascending aorta was found to be dilated with the inner diameter of 43 mm.

The patient stopped taking her antihypertensive medications at the start of her pregnancy. Her ambulatory and home-monitored blood pressure (BP) did not exceed 135/95 mmHg.

Admission electrocardiogram (ECG) was normal. TTE revealed dilated ascending aorta (52 mm in diameter on the 2D parasternal long axis view), with a clearly visible intimal flap (Figure 1) that originated from the area of the right aortic cusp. Significant aortic regurgitation grade 3/4 was registered with color Doppler. Fetal echocardiography registered normal fetal heart activity with the frequency of 165 bpm.

An interdisciplinary team consisting of cardiologist, cardiac surgeon, anesthesiologist and

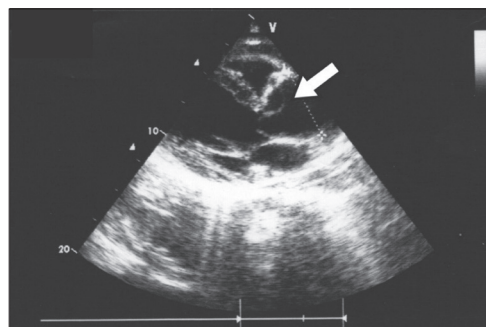

Figure 1. Transthoracic echocardiography (parasternal long axis view): image demonstrating dilated ascending aorta, the intimal flap (arrow) originating in the area of the right aortic cusp, prolapsing into the left ventricle outflow tract

Received • Примљено:
May 21, 2018

Revised • Ревизија:
January 16, 2019

Accepted • Прихваћено:
January 18, 2019

Online first: February 5, 2019

Correspondence to:

Andrej PREVEDEN
Jirečakova 3
21000 Novi Sad
Serbia
andrej.preveden@mf.uns.ac.rs

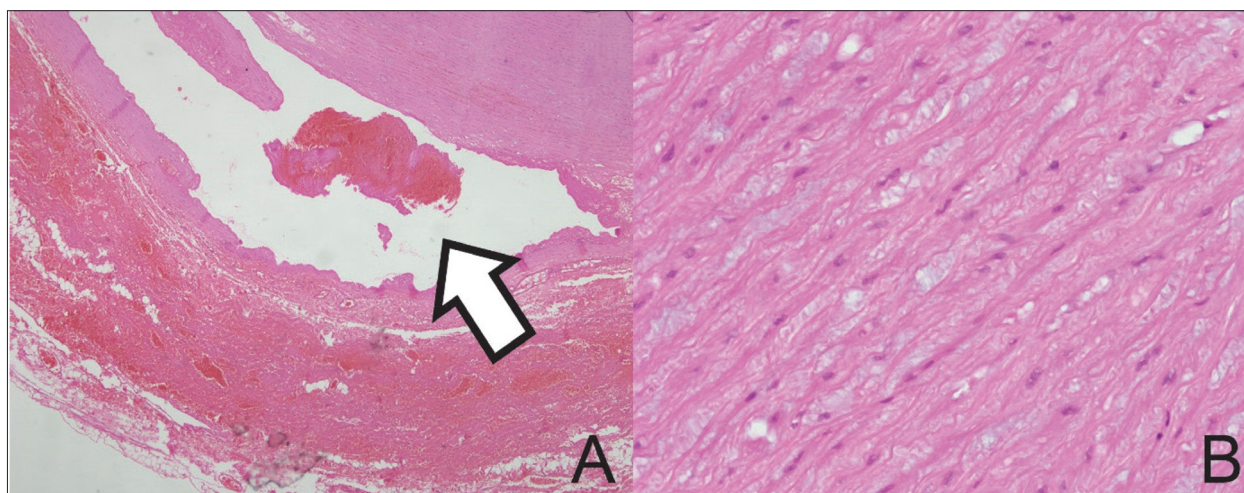


Figure 2. Light microscopy histopathology of the aortic wall: A – dissection of the aortic wall: dissection spreads characteristically along the laminar planes of the aorta, between the middle and outer thirds, fibrin thrombus is present in the false lumen (arrow), the adventitia is permeated with blood (H&E, 4×); B – cystic medial degeneration with elastic tissue fragmentation and separation of the elastic and fibromuscular elements of the tunica media by small cleftlike spaces with an absence of the normal elastic tissue; these areas are filled with an amorphous extracellular matrix of connective tissue (H&E, 40×)

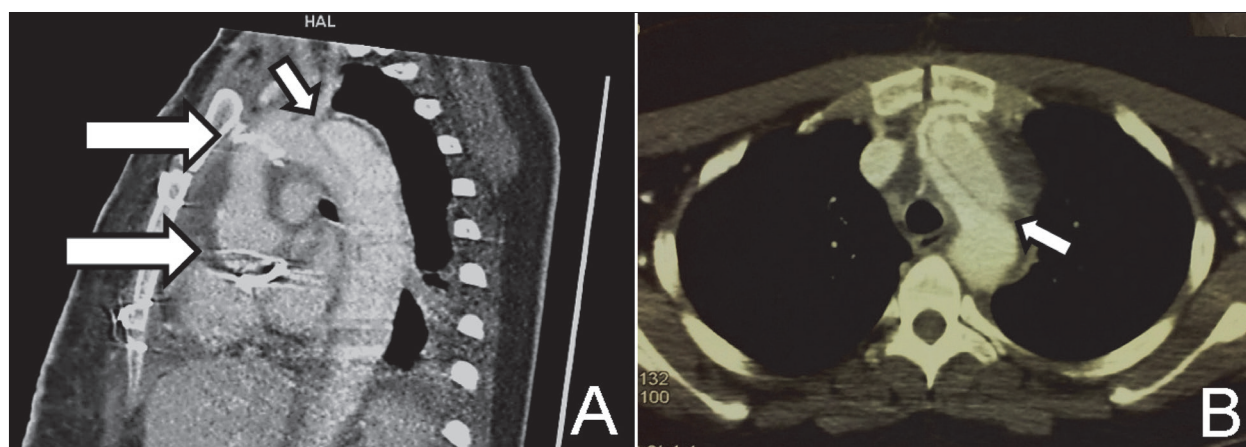


Figure 3. Postoperative computed tomography angiography of the aorta (A – sagittal plane and B – transversal plane): proximal and distal anastomosis of the graft with the prosthetic valve (large arrows) and intimal flap in the aortic arch (small arrows)

gynecologist decided to perform an urgent operation, with the fetus left inside the uterus. The Bentall operation was carried out replacing the aortic valve, ascending aorta, and the proximal part of aortic arch with valved composite graft. Light microscopic analysis of the aortic tissue showed a presence of cystic medial necrosis with elastic fibers that were torn and moved apart, as well as a large amount of mucoid substance (Figure 2). The aortic valve had all three cusps, but they were myxomatously degenerated on histology.

The patient left the operating room in a stable condition, but fetal echocardiography on the first postoperative day (POD) showed no heart activity. The team of doctors met once again and decided to terminate the pregnancy, considering the intrauterine death of the fetus and the patient's general condition. The dead fetus and the placental tissue were removed by dilatation and curettage on the second POD. Autopsy and histopathology showed maceration of the fetus without any malformations and abnormalities.

Further postoperative course was uneventful. Postoperative TTE showed normal prosthetic valve function with normal velocities [mean pressure gradient (PG)

8.5 mmHg]. Computerized tomography (CT) of the aorta on the 14th POD confirmed normal position of the tubular graft, but also an existing intimal flap in the aortic arch that extended all the way to the bifurcation of the aorta (Figure 3). After a 24-hour BP monitoring, the patient's antihypertensive therapy was adjusted. She was dismissed on the 20th POD in a good general condition with carvedilol, losartan and methyldopa. Acenocoumarol as an oral anticoagulant with a target internationalized normalized ratio (INR) of 2.0–3.0 was initiated.

Four months later, after heavy physical activity, the patient developed dehiscence of the sternal wound, which was hence resutured. The wound still failed to heal, so several weeks later another resuture had to be undertaken, after which the sternum was finally successfully managed.

The patient was free of symptoms on her medications for the next six years and went to checkups regularly, until July 2014, when she was admitted to the intensive care unit with severe shortness of breath and chest pain. Six days before she had carelessly stopped taking oral anticoagulant therapy.

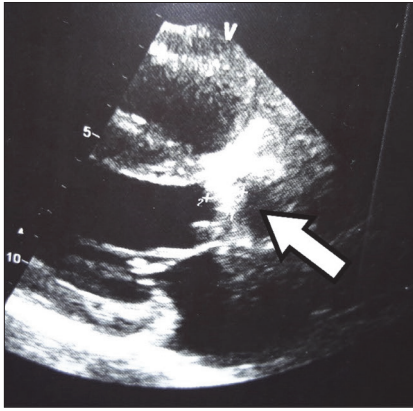


Figure 4. Transthoracic echocardiography (parasternal long axis view): thrombus on the ventricular side of the prosthetic valve in the aortic position (arrow)

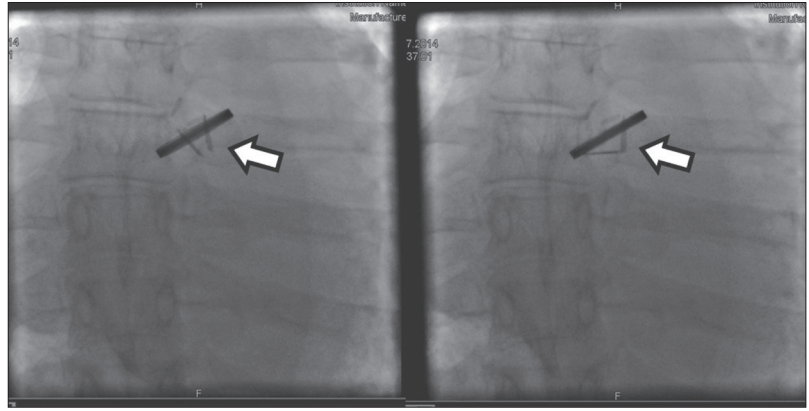


Figure 5. Cinefluoroscopy of the prosthetic valve: one of the leaflets is immobile in both systole and diastole (arrows)

TTE revealed severe dysfunction of the prosthetic valve with an echo formation measuring 15×10 mm in size, attached on the ventricular side with thrombus characteristics and a large embolic potential (Figure 4). The measurements showed obstruction across the valve with high PG (maximum PG 99 mmHg, mean PG 49 mmHg, V_{\max} 5 m/s), along with a significant insufficiency that had a central regurgitation jet. Cinefluoroscopy revealed one completely immobile leaflet (Figure 5). CT scans of the aorta showed the progress of the false lumen in the descending aorta with a significant parietal thrombosis. The diameter of the descending aorta on CT was 45 mm in total, out of which only 5 mm was the true lumen, since the false lumen was 21 mm and the thrombosis 19 mm.

The patient was considered to have a high risk for a redo operation (EuroSCORE II was 18.97%), so she was treated conservatively with an intravenous unfractionated heparin (UFH) infusion. The UFH dosage had been adjusted in the 1,200-1,700 IU/h interval, depending on the values of APTT that was checked on a regular basis.

Further TTE exams showed graduate lysis of the previously registered echo mass, normalization of the prosthetic valve function, and a PG decrease. After 40 days of continuous intravenous UFH infusion and regular periodic TTE exams, oral anticoagulation therapy with acenocoumarol was continued. Because of the prolonged heparin use and its potential effect on heparin-induced thrombocytopenia (HIT), platelet count was checked regularly. Nonetheless, it remained normal the entire time. The patient was dismissed from the hospital in a clinically stable condition with target INR between 2.0 and 3.0.

One year later, in April 2015, the patient was admitted as an emergency case once again because of chest pain and serious shortness of breath. The admission ECG raised a suspicion for a myocardial infarction (MI) (Figure 6) and laboratory tests revealed elevated cardiac enzymes. Shortly upon admission, the patient had cardiac arrest with pulseless electrical activity. Cardiopulmonary resuscitation was performed, but the patient died.

The autopsy discovered that the reason for the MI was a thromboembolus in the left anterior descending coronary artery (LAD) without any atherosclerotic changes. There

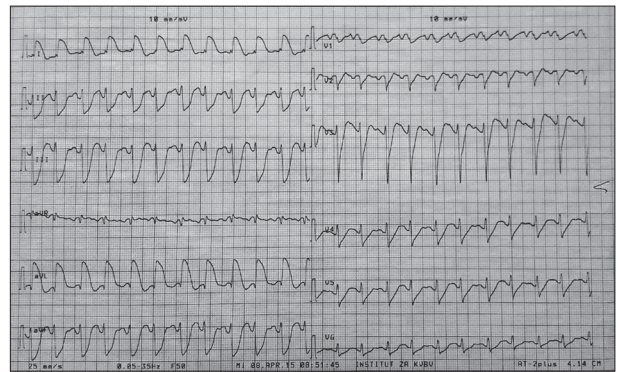


Figure 6. Electrocardiogram on admission: sinus rhythm, heart rate 100 bpm, widened QRS complexes – left bundle branch block type

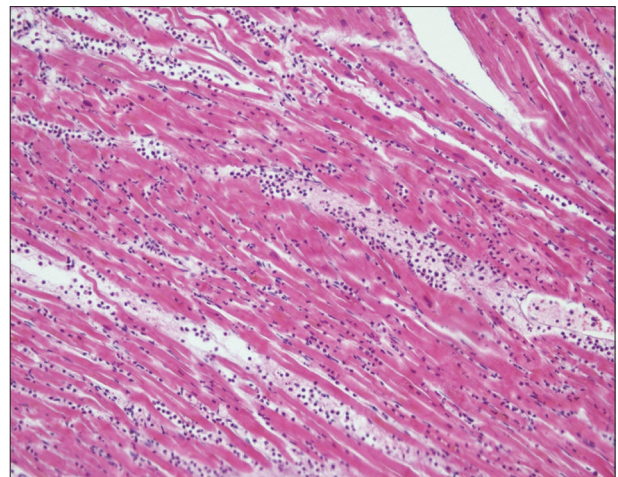


Figure 7. Light microscopy histopathology of the specimen from the anterior wall of the left ventricle: necrotic cardiomyocytes with the loss of nuclei and striations, the interstitium is edematous with the presence of a dense infiltrate of neutrophils (H&E, 20X)

were signs of acute transmural MI in the anterior and lateral wall of the myocardium. On the cross pathology, the area of the MI was pale yellow and soft, surrounded by a hyperemic zone. On the histologic section, cardiomyocytes were necrotic with the loss of nuclei and striations, the interstitium was edematous with the presence of a dense infiltrate of neutrophils (Figure 7). The prosthetic valve was correctly positioned. The inner wall of the aortic graft was covered with a large thrombi formation.

DISCUSSION

AD in pregnant women can be explained by hormone-mediated and hemodynamic changes during pregnancy that increase the aortic wall stress. Tachycardia and rise in cardiac output are the most prominent ones, because of their effect on hemodynamic stress on the arterial walls. Stimulation of the estrogen receptors in aortic tissue causes connective fiber fragmentations and acid mucopolysaccharides reduction, leading to the reduced wall elasticity. The aortic stress can also be increased by the gravid uterus that compresses the aorta [6].

Our patient had neither a positive family history of aortic diseases nor the other Marfan features like spine or chest deformities that would indicate the presence of this syndrome [7, 8]. Previously diagnosed hypertension and dilated aorta were the risk factors that immediately raised the suspicion for the right diagnosis in this case. Hypertension in pregnancy is often related to preeclampsia and eclampsia, however in this case it was present from before and there was no proteinuria [9]. The latest discoveries suggest that the loss of nocturnal BP drop (the so called non-dipping pattern) may be the main cause of cardiovascular dysfunction and hemodynamic impairment in pregnancy, rather than just hypertension by itself [10].

Most of the antihypertensive drugs are avoided during pregnancy because of their side effects on the fetus. Drugs that are recommended are methyl dopa, nifedipine, and labetalol, while angiotensin-converting enzyme inhibitors and angiotensin receptor blockers are contraindicated [11]. According to the current guidelines, antihypertensive therapy in pregnant women who are without any symptoms and signs of organ dysfunction is recommended when the BP levels reach > 160 mmHg for systolic or > 110 mmHg for diastolic BP, and may be considered for BP $\geq 150/95$ mmHg [9, 11]. Considering that our patient did not have BP levels above 140/90 mmHg during pregnancy according to the history data and home-based measurements, stopping her antihypertensive therapy was justified and according to guidelines.

Dilated ascending aorta in our patient was noticed two years prior to her pregnancy, 43 mm in diameter on TTE. An indication for elective surgery of the ascending aortic aneurysm is the diameter ≥ 55 mm, but for patients with Marfan syndrome or other risk factors, this threshold can be lowered to 45 mm according to the current guidelines [12]. As a separate recommendation, it is stated that lowering this threshold even more may be considered in the case of planned pregnancy, but thresholds are not specified.

TTE should be performed monthly or every other month during pregnancy in patients with known dilated ascending aorta to identify the potential progress of the aortic diameter, and if indicated undertake surgery on time, thus preventing potential unwanted incidents [13]. Unfortunately, our patient hadn't had a TTE exam during the pregnancy, so possible progressive dilatation of her ascending aorta couldn't have been recognized.

Management of AD involving ascending aorta (Stanford type A) is an urgent surgery, because of high mortality in

patients who are not operated on, which reaches 50% in the first 48 hours [12, 13]. In the case of acute AD during pregnancy, management protocols depend on the gestational age. If the pregnancy is older than 28 GW (third trimester), it is indicated to deliver the baby with caesarean section first, and then perform surgery of the aorta [14]. Our patient was in the 16th GW and the caesarean section was not an option, so the urgent surgery of the aorta was undertaken immediately.

Echocardiography is a basic diagnostic modality for aortic diseases. However, a negative TTE does not rule out AD. Other imaging techniques such as transesophageal echocardiography (TEE), CT, and magnetic resonance have a greater field of view and may provide additional information important for the operation [15], but in this case the diagnosis of the dissection and the decision for surgical treatment was made using solely TTE, which, according to the literature, has a sensitivity and specificity of 75% and 90%, respectively [4]. Precious time was saved by skipping TEE and CT scan, and the negative effects of CT radiation and contrast agents were avoided.

The patient survived the cardiac surgery, but the stress on the fetus was apparently too strong and it died, so the evacuation abortion was undertaken the next day. There is a limited number of similar cases in the literature. Majority of them describe the dissection in the third trimester, which is in fact the most vulnerable period [16, 17, 18]. Only two case reports describe the surgical repair of Stanford type A AD before the third trimester with maternal and fetal survival in both of them [19, 20]. Liu et al. [21] reported five cases of Bentall operation in Stanford type A AD during pregnancy, only one of which happened before the third trimester (22 GW), with both mother and fetus diseased.

There are multiple possible reasons for the fetal death. The main ones being the dissection itself, with the intimal flap potentially compromising the placental perfusion, as well as the factors associated with the operation, including cardiopulmonary bypass and circulatory arrest. Hypothermia during bypass has also shown to worsen the fetal prognosis [22].

The tissue sample of the ascending aorta that was sent to light microscopic histopathology showed cystic medial necrosis, which is a typical finding in Marfan syndrome [7]. Considering the significantly higher burden of acute aortic syndromes in Marfan patients, recognizing this syndrome in our patient could have improved her follow-up. She had an aneurysm of the ascending aorta, which is a major criterion for Marfan syndrome diagnosis, yet criteria on other organ systems (skeletal, ocular, respiratory, skin) were not fulfilled [8].

The patient was released from hospital with a combined antihypertensive therapy including losartan. A number of studies on animal and human models have demonstrated that losartan improves endothelial function and has a positive effect on aortic root stabilization [23].

The necessity of a lifetime anticoagulation therapy after mechanical valve implantation is clearly demonstrated in this case [24]. The patient had stopped taking oral anticoagulants for an unknown reason, and during that period of

time she was not protected with a low-molecular-weight heparin. This led to valve thrombosis in only a few days, causing its malfunction and resultant heart failure.

The diagnosis of prosthetic valve thrombosis was based on the findings of TTE and cinefluoroscopy. TTE provided a proper diagnostic assessment with 2D echo when an echo mass (15 × 10 mm) attached at the ventricular side of the prosthetic valve was registered. High velocity and elevated transprosthetic gradients were measured with Doppler echo.

Usually, urgent surgery is the treatment of choice in such critically ill patients with obstructive valve thrombosis [24]. Therapeutic strategy in this case was mainly influenced by the risk assessment, which was too high for a redo operation, so being aware of the prosthesis location, the presence of a valvular obstruction, and the patient's clinical status, heparin infusion was started. This led to prosthetic valve function recovery after two months. The prolonged heparin use did carry an increased risk of complications like hemorrhage and HIT; however, they were fortunately avoided. From the aspect of HIT, low-molecular-weight heparin might have been a better choice over UFH. Recent studies show lower incidence of HIT with the use of low-molecular-weight heparin in comparison to UFH, without a significant difference in therapeutic effect [25].

Nine months later, the cause of death was a massive transmural MI. The autopsy showed that the MI was caused by thromboembolism in the LAD. There were no atherosclerotic plaques in coronary arteries. The reported incidence of thromboembolism after Bentall operation is around 0.7% events per year, which is mainly associated with inadequate anticoagulation [26]. The main cause of coronary thromboembolism is atrial fibrillation [27]. Although our patient was in sinus rhythm, she did have a few other risk factors, including previous cardiac surgery, non-infected thrombi on prosthetic valve, and intraluminal

thrombosis inside the chronic dissection of the descending aorta, which are all described as rare but possible causes of coronary thromboembolism [27, 28]. There is scarce data in literature describing coronary thromboembolism after Bentall operation [29, 30]. As in our case, coronary thromboembolism was also caused by prosthetic valve thrombosis due to inadequate coagulation in the described cases.

In conclusion, we can say that even though this pregnancy could have been classified as a high-risk one, considering the patient's hypertension and known aortic disease, the follow-up was not as thorough as it should have been and the preconceptional counseling failed. Taking everything into account, it might have been wise to consult the patient against pregnancy. BP levels during pregnancy probably haven't been monitored regularly since the antihypertensive therapy was discontinued, which might have contributed to the damage of the aorta. In the setting of acute chest pain and distress in pregnancy, AD should always be suspected.

Echocardiography is rapid, accurate, and cost-effective in the diagnosis and follow-up of aortic diseases. In contrast to the poor pregnancy follow up, the reaction of the multidisciplinary team managing AD was prompt and appropriate to this life-threatening condition, saving the woman's life but unfortunately losing the baby. Mandatory lifetime oral anticoagulants after a mechanical valve implantation is clearly demonstrated in this case.

ACKNOWLEDGEMENT

The authors wish to thank Anastazija Stojšić-Milosavljević for her generous help and contribution to the writing of this paper.

Conflict of interest: None declared.

REFERENCES

- Meszaros I, Morocz J, Szilvi J, Schmidt J, Tornoci L, Nagy L, et al. Epidemiology and clinicopathology of aortic dissection. *Chest*. 2000; 117(5):1271–8.
- Hagan PG, Nienaber CA, Isselbacher EM, Bruckman D, Karavite DJ, Russman PL, et al. The International Registry of Acute Aortic Dissection (IRAD): new insights into an old disease. *JAMA*. 2000; 283(7):897–903.
- Mandel W, Evans EW, Walford RL. Dissecting aortic aneurysm during pregnancy. *N Engl J Med*. 1954; 251(26):1059–61.
- Khan IA, Nair CK. Clinical, diagnostic, and management perspectives of aortic dissection. *Chest*. 2002; 122(1):311–28.
- Al Khaja KA, Sequeira RP, Alkhaja AK, Damanhori AH. Drug treatment of hypertension in pregnancy: a critical review of adult guideline recommendations. *J Hypertens*. 2014; 32(3):454–63.
- Immer FF, Bansil AG, Immer-Bansil AS, McDougall J, Zehr KJ, Schaff HV, et al. Aortic dissection in pregnancy: analysis of risk factors and outcome. *Ann Thorac Surg*. 2003; 76(1):309–14.
- Ammash NM, Sundt TM, Connolly HM. Marfan syndrome—diagnosis and management. *Curr Probl Cardiol*. 2008; 33(1):7–39.
- Loeys BL, Dietz HC, Braverman AC, Callewaert BL, De Backer J, Devereux RB, et al. The revised Ghent nosology for the Marfan syndrome. *J Med Genet*. 2010; 47(7):476–85.
- American College of Obstetricians and Gynecologists, Task Force on Hypertension in Pregnancy. Hypertension in pregnancy. Report of the American College of Obstetricians and Gynecologists' Task Force on Hypertension in Pregnancy. *Obstet Gynecol*. 2013; 122(5):1122–31.
- Ilic A, Ilic DJ, Tadic S, Stefanovic M, Stojšić-Milosavljević A, Pavlović K, et al. Influence of non-dipping pattern of blood pressure in gestational hypertension on maternal cardiac function, hemodynamics and intrauterine growth restriction. *Pregnancy Hypertens*. 2017; 10:34–41.
- Task Force for the management of arterial hypertension of the European Society of Hypertension, Task Force for the management of arterial hypertension of the European Society of Cardiology. 2013 ESH/ESC Guidelines for the Management of Arterial Hypertension. *Blood press*. 2013; 22(4):193–278.
- Erbil R, Aboyans V, Boileau C, Bossone E, Bartolomeo RD, Eggebrecht H, et al. 2014 ESC Guidelines on the diagnosis and treatment of aortic diseases: Document covering acute and chronic aortic diseases of the thoracic and abdominal aorta of the adult. The Task Force for the Diagnosis and Treatment of Aortic Diseases of the European Society of Cardiology (ESC). *Eur Heart J*. 2014; 35(41):2873–926.
- Hiratzka LF, Bakris GL, Beckman JA, Bersin RM, Carr VF, Casey DE Jr, et al. 2010 ACCF/AHA/AATS/ACR/ASA/SCA/SCAI/SIR/STS/SVM guidelines for the diagnosis and management of patients with thoracic aortic disease: executive summary. A report of the American College of Cardiology Foundation/American Heart Association Task Force on Practice Guidelines, American Association for Thoracic Surgery, American College of Radiology, American Stroke Association, Society of Cardiovascular Anesthesiologists, Society for Cardiovascular Angiography and Interventions, Society of Interventional Radiology, Society of Thoracic Surgeons, and

- Society for Vascular Medicine. Catheter Cardiovasc Interv. 2010; 76(2):E43–86.
14. Atta E, Gardner M. Cardiopulmonary resuscitation in pregnancy. *Obstet Gynecol Clin North Am.* 2007; 34(3):585–97.
 15. Evangelista A, Flachskampf FA, Erbel R, Antonini-Canterin F, Vlachopoulos C, Rocchi G, et al. Echocardiography in aortic diseases: EAE recommendations for clinical practice. *Eur J Echocardiogr.* 2010;11(8):645–58.
 16. Ham S. Emergency repair of aortic dissection in a 37-week parturient: a case report. *AANA J.* 2010; 78(1):63–8.
 17. Kohli E, Jwayyed S, Giorgio G, Bhalla MC. Acute type A aortic dissection in a 36-week pregnant patient. *Case Rep Emerg Med.* 2013; 2013:390670.
 18. Guo C, Xu D, Wang C. Successful treatment for acute aortic dissection in pregnancy – Bentall procedure concomitant with cesarean section. *J Cardiothorac Surg.* 2011; 6:139.
 19. Barrus A, Afshar S, Sani S, LaBounty TG, Padilla C, Farber MK, et al. Acute Type A Aortic Dissection and Successful Surgical Repair in a Woman at 21 Weeks Gestational Pregnancy with Maternal and Fetal Survival: A Case Report. *J Cardiothorac Vasc Anesth.* 2018; 32(3):1487–93.
 20. Shaker WH, Refaat AA, Hakamei MA, Ibrahim MF. Acute type A aortic dissection at seven weeks of gestation in a Marfan patient: case report. *J Card Surg.* 2008; 23(5):569–70.
 21. Liu YY, Li HY, Jiang WJ, Guan XL, Wang XL, Liu O, et al. Treatment of patients with aortic disease during pregnancy and after delivery. *J Int Med Res.* 2017; 45(4):1359–68.
 22. Pomini F, Mercogliano D, Cavalletti C, Caruso A, Pomini P. Cardiopulmonary bypass in pregnancy. *Ann Thorac Surg.* 1996; 61(1):259–68.
 23. Vasilijevic Z, Dimkovic N, Lazarevic K, Burmazovic S, Krstic N, Milanovic S, et al. [Postmarketing study of efficacy and safety of losartan during the treatment of patients with mild and moderate hypertension: LOTAR (corrected) study]. *Srp Arh Celok Lek.* 2013; 141(1-2):22–8.
 24. Nishimura RA, Otto CM, Bonow RO, Carabello BA, Erwin JP 3rd, Guyton RA, et al. 2014 AHA/ACC Guideline for the Management of Patients with Valvular Heart Disease: a report of the American College of Cardiology/American Heart Association Task Force on Practice Guidelines. *Circulation.* 2014; 129(23):e521–643.
 25. Junqueira DR, Perini E, Penholati RR, Carvalho MG. Unfractionated heparin versus low molecular weight heparins for avoiding heparin-induced thrombocytopenia in postoperative patients. *Cochrane Database Syst Rev.* 2012; (9):CD007557.
 26. Mookhoek A, Korteland NM, Arabkhani B, Di Centa I, Lansac E, Bekkers JA, et al. Bentall Procedure: A Systematic Review and Meta-Analysis. *Ann Thorac Surg.* 2016; 101(5):1684–9.
 27. Shibata T, Kawakami S, Noguchi T, Tanaka T, Asaumi Y, Kanaya T, et al. Prevalence, Clinical Features, and Prognosis of Acute Myocardial Infarction Attributable to Coronary Artery Embolism. *Circulation.* 2015; 132(4):241–50.
 28. Preveden A, Kovačević M, Šušak S, Redžek A, Velicki L. Coronary embolism causing myocardial infarction after heart valve surgery. *Vojnosanit Pregl.* 2018; OnLine-First (00):180–180. doi: <https://doi.org/10.2298/VSP180809180P>
 29. Senguttuvan NB, Ramakrishnan S, Singh S, Mishra S. Percutaneous management of coronary embolism with prosthetic heart valve thrombosis after Bentall's procedure. *Indian Heart J.* 2015; 67(6):589–91.
 30. Nardi P, Russo M, Greci M, Pisano C, Saitto G, Pellegrini G, et al. Acute Myocardial Infarction Ten Days after Bentall Procedure due to Coronary Embolism: Etiology Discussion and Rare Case Presentation. *Clin Surg.* 2018; 3:2136.

Трудница преживела дисекцију аорте, а касније умрла због коронарне емболије – јединствен случај несарадљивог болесника

Андреј Преведен^{1,2}, Голуб Самарџија^{1,2}, Стаменко Шушак^{1,2}, Александра Илић^{1,2} Александар Реџек^{1,2}

¹Универзитет у Новом Саду, Медицински факултет, Нови Сад, Србија;

²Институт за кардиоваскуларне болести Војводине, Сремска Каменица, Србија

САЖЕТАК

Увод Учесталост дисекције аорте се креће између три и пет случајева на 100.000 људи годишње. Од жена млађих од 40 година које добију дисекцију аорте готово половина су труднице.

Приказ болесника Приказан је случај 22-годишње труднице у 16. гестацијској недељи са историјом артеријске хипертензије и дилатираном аортом, која је примљена због дисекције аорте. Урађена јој је операција по Бенталу, којом су јој замењени аортни залистак, асцендентна аорта и проксимални део лука аорте коришћењем композитног графта са залиском. Плод није преживео операцију, те је сутрадан начињена евакуациона киретажа. Шест година касније код болеснице је, услед престанка узимања антикоагулантне

терапије, дошло до тромбозе механичког залиска, која је успешно излечена интравенском применом хепарина. После годину дана болесница је умрла због инфаркта миокарда узрокованог коронарном тромбоемболијом, што је потврђено обдукцијом.

Закључак Код жена са познатом болешћу аорте веома је важно саветовање пре зачећа. Дисекција аорте код трудница је акутно, животно угрожавајуће стање како за мајку тако и за фетус, у чијем збрињавању треба да учествује мултидисциплинарни тим. После уградње механичког залиска неопходна је доживотна антикоагулантна терапија.

Кључе речи: дисекција аорте; трудноћа; антикоагулантна терапија; тромбоза механичког залиска; коронарна емболија