



ARTICLE FOR PRACTITIONERS / РАД ЗА ПРАКСУ

Protocols in classification of partially edentulous patients

Kosovka Obradović-Đuričić¹, Tijana Đuričić², Vesna Medić¹, Dejan Stamenković¹¹University of Belgrade, School of Dental Medicine, Department of Prosthodontics, Belgrade, Serbia;²NOVA Academy of Arts, Belgrade, Serbia**SUMMARY**

This paper shall discuss the importance of protocol application in modern dentistry. Literature data that include recommendations and consensuses in dental practice point out to their presence in available literature, printed papers, reviewed journals and supplements in the form of expert group conclusions. It should be noted that the protocols most commonly rely on valid postulates of different branches of medicine, supported by specific conditions of the environment in which they are implemented. Additionally, in our settings, applicable dentistry protocols are the result of requirements that institutions and practices should fulfil according to renewable accreditation, as well as following recommendations given in the good clinical practice guidelines with different binding obligations levels.

Certain protocols offer therapeutic modalities categorized into classes intended to help users to select appropriate treatments. The second part of this paper shall address one such protocol which classifies partially edentulous patients. The emphasis is on the partial edentulism classification recommended by The American College of Prosthodontists (ACP), which relies on four diagnostic criteria essential for therapeutic decision. Edentulous areas location and extent, abutment teeth health, occlusion model, and residual ridge characteristics represent the parameters which have defined the four classes of partial edentulism of different complexity. In this way, comprehensive approach to the clinical status of the patients has, for the first time been offered to the dental practitioners assuring, among others, higher uniformity of professional attitudes in selection of therapeutic modalities.

Keywords: protocols; classification of partial edentulism; diagnostic consistency

ABOUT PROTOCOLS

Protocols are exceptionally important in contemporary medical and dental practices. Although it was developed back in 1990, standard definition that describes practical clinical guides, has remained as relevant as ever. Field and Lohr [1] pointed out that protocols represent “systematically developed determinants that help practitioners and patients in making decisions on appropriate health care in specific conditions.”

More specifically, the task of a protocol is to identify, summarize and evaluate the most contemporary knowledge and facts related to prevention, diagnosis and treatment of the given health problem. Protocols define the most important issues related to clinical practice, taking into account differential diagnoses and consequences of possible decisions. Numerous protocols offer alternative therapeutic modalities categorized into classes, essentially helping users to make appropriate choice of treatment [2, 3].

Additional objectives that may be accomplished by implementation of protocols include: medical and dental care standardization, continuous care improvement, different levels of risk reduction (of patients, physicians, insurance services), as well as achieving higher quality of balance between expenses and medical treatment parameters (efficacy, specificity, sensitivity, decisiveness, etc.).

Unfortunately, practical implementation of protocols is not problem-free. It is considered that as much as 20% of strict recommendations are being revoked, particularly if they are only given as opinions and not based on experimental evidence [4]. Moreover, clinical practice guidelines show methodological problems and conflicts of interest. Their quality significantly varies, particularly if they are published online without reference to the existing standards [5]. Less frequently, the protocol recommendations are more strict and demanding than the facts that support them [6].

Usually, the protocols are developed and verified by national and international associations or governmental bodies. Additionally, special software packages are available (guideline execution engines) that are developed to facilitate medical protocols usage in electronic recording system. Regarding the former, concerns related to timely improvement of the existing protocols appears to be reasonable, with special focus on implementing multidisciplinary expert opinions in combination with scientific support [7]. Literature data that include protocols, recommendations and consensuses in dental practice are diverse. Usually, they may be found in available textbooks and printed papers in the reviewed journals as conclusions of expert groups and similar [8, 9]. They cover all dental specialties with basic information on the routes of

Received • Примљено:

April 3, 2018

Accepted • Прихваћено:

June 11, 2018

Online first: August 7, 2018**Correspondence to:**

Kosovka OBRADOVIĆ-ĐURIČIĆ
Stomatološki fakultet, Klinika za
stomatološku protetiku
Rankeova 4, Beograd
kosovkaobradovicdjuricic@gmail.com

infection transmission (HIV, HBV), control and standard precautions (protection of dentists and patients), effective hygiene protocols, asepsis and sterilization (type, instruments, duration, monitoring) and binding procedures related to storage or medical waste [10]. These recommendations significantly rely on valid postulates from different branches of medicine (epidemiology, hygiene, infectious diseases), supported by specific environmental conditions in which they are implemented. On the other hand, certain areas, such as esthetic dentistry and oral implantology, offer protocols adopted on consensus conferences, as well as recommendations of the professional associations. It is important to mention some of them, without which, contemporary practice would not be rationally sustainable: recommendations related to clinical procedures based on which esthetic rules related to placement of implants are defined [11], conditions and significance of immediate implantation [12], protocols in application of cemented and screwed implants [13], recommendations on management of edentulous patients determined by different parameters [14] as well as similar recommendations with longitudinal evidence based data [15–21] (Figure 1).

In our settings, dental protocols are the result of requirements that must be met by institutions and practices to comply with renewable accreditation and through observing the recommendations given in the good clinical practice guidelines with a different binding level (a, b, c).

It should be emphasized that guidelines and recommended protocols represent only one of the options for improvement of general quality of health protection and care. They must not be considered to be “magic solutions” of numerous problems, but instead, they should be understood, used and combined with the existing professional quantum of knowledge and overall skill.

To this end, objective of the authors is to inform the readers in the following segment of the paper on the most recent partial edentulism classification system that can also be regarded as contemporary protocol in the field.

CLASSIFICATION OF PARTIAL EDENTULISM

Partial edentulism is a syndrome of loss of one or more permanent teeth in the upper or lower jaw dental arch in adults [22]. It is most commonly caused by caries, periodontal problems, trauma or tumors. Clinically, partial edentulism results in tilting and displacement of the adjacent teeth, eruption of antagonist, altered speech and appearance of the patient, temporomandibular dysfunction, and compromised quality of life. Continuous loss and degradation of the bone as well as changes on the remaining teeth make rehabilitation of these patients rather difficult [23, 24].

The profession is faced with existence of different methods of classification of partial edentulism. In practice, majority of classifications rely on arrangement of the remaining teeth and edentulous areas in the mouth, which is considered to be a relatively simplified approach. On the other hand, mathematically calculated number of combinations of the lost teeth in booth dental arches exceeds 65,000, and therefore, having in mind these numbers, applicable topographic classifications may be considered clinically appropriate [22, 24].

However, in spite of the advantages of these classifications, such as: easier communication between the practitioners, technicians and dental industry, as well as establishment and respecting of doctrinal attitudes in treatment of partial edentulism, it appears that contemporary dental practice rightly considers topographic classification of partial edentulism insufficient. Major objection to numerous classifications of partial edentulism presented by renown authors (Cummer, Kennedy, Rumpel, Bailyn, Neurhor, Mauk, Wild, Betelman, Friedman, Austin-Lidge, Skinner, Avant, Miller, Costa, Kobes) is based on the fact that classification of partial edentulism does not include any information on the remaining teeth health status, antagonist teeth, residual ridges as well recommendations on possible therapeutic solutions (Table 1) [23, 25]. Therefore, it is reasonable to expect from the contemporary classifications to offer the practitioners a greater number of useful, pragmatic information.

Unfortunately, unnecessary complexity of classifications designed in this way may be confusing and nonapplicable in everyday practice, which is fast, efficient and cost-effective. With this regard, practical rules that should be followed in such cases include: simplicity, acceptability and possible treatment recommendations (Table 1).

It is considered that the ideal classification of partial edentulism should contain information that illustrate objective status of the patient and offer optimal therapeutic solutions. In this way, defined information may be selected in electronic, diagnostic, and procedural bases of national significance and improve to the extent of effective monitoring of patients’ health status.

One of the comprehensive classification systems is presented by American College of Prosthodontists in 2002 [26]. The main idea

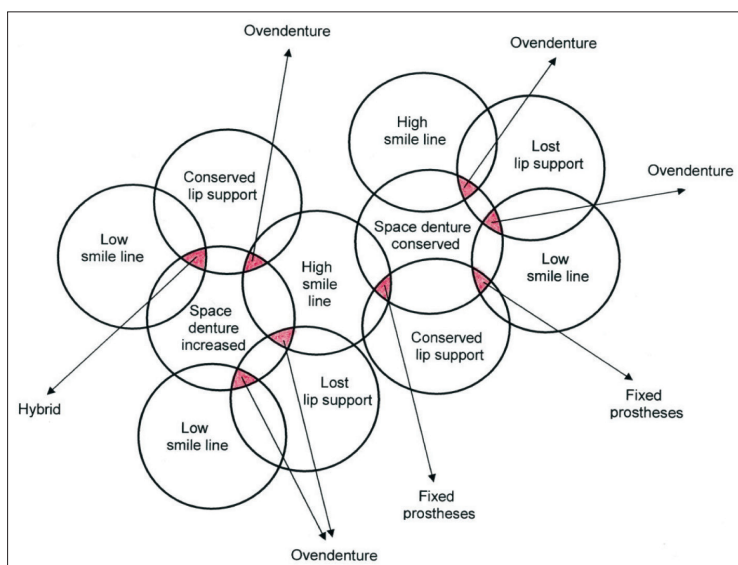


Figure 1. Recommended therapy in combination of three prosthetic parameters [14]

Table 1. Classification of partial edentulism according to different authors and parameters*

YEAR	NAME OF AUTHOR	CRITERIA
1921	Cummer	Topographic, therapeutic
1923	Kennedy	Topographic
1939	Martin	Topographic, biological
1940	Swenson Terkla	Topographic
1949	Wild	Topographic
1955	Eichner	Number of occlusal contacts
1958	Applegate	Topographic, therapeutic
1959	Skinner	Topographic
1961	Osborne	Therapeutic
1964	Friedman	Functional
1967	Eichner	Number of occlusal contacts
1973	Hoffman	Tooth position
1975	Kerl Heinz Körber	Biophysiological, therapeutic
1979	Kobes	Topographic
1981	Fabian	Teeth number and position
2002	American College of Prosthodontists	Clinical situation

*American College of Prosthodontists

of the classification was the possibility to help practitioners to define appropriate treatments to be recommended to partially edentulous patients. The system uses four basic criteria and their diversity to divide all partially edentulous patients in four classes, where Class I includes simple while Class IV exceptionally complicated clinical cases of partial edentulism. Advantages of this layered classification which takes into account location and size of the residual ridge, its characteristics, residual teeth health status, as well as occlusal characteristics in partially edentulous patients, are evidenced in a number of segments: 1. improvement of professional communication and consistency in therapeutic decisions; 2. objectification of the methodology used for follow-up of patients within the educative process; 3. standardized criteria necessary for evaluation of treatment/research outcomes and 4. improvement of diagnostic procedures and further development of organized simplified help in decision-making (Figure 2).

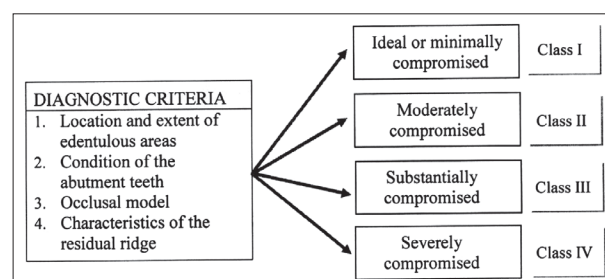
REVIEW OF DIAGNOSTIC CRITERIA AND CLASSES OF PARTIAL EDENTULISM ACCORDING TO THE AMERICAN COLLEGE OF PROSTHODONTISTS (ACP)

PARTIAL EDENTULISM CLASS I

Partial edentulism Class I is characterized by the most favorable location and extent of edentulous area, healthy retention teeth (abutment teeth), harmonious occlusion and favorable characteristics of the residual ridges.

Location and extent of edentulous area

Edentulous area is restricted only to one dental arch. It may be located in the frontal segment of the upper jaw, where it does not include more than two incisors, or in the frontal segment of the lower jaw, when it does not include

**Figure 2.** Review of diagnostic criteria and classes of partial edentulism according to the American College of Prosthodontists (ACP)

more than four incisors. If the edentulous area is located in the lateral segment of the upper or lower jaw, it should not involve more than two premolars or one premolar and one molar.

Health status of retention teeth (abutment teeth)

Health status of the remaining teeth that may be used as retention teeth for fixed or removable restorations is satisfactory and thus pre-prosthetic tooth preparation is not recommended, regardless of its type.

Occlusion model

Occlusion is stable and physiological, There is no evidence of disharmony between anatomical and physical determinants. The patients belong to skeletal class I and dentoalveolar class I, and thus pre-prosthetic therapeutic interventions (selective grinding) is not recommended.

Characteristics of residual ridge

Patients with partial edentulism class I show morphological features of the residual ridge which make good support for denture base preventing horizontal and vertical movements of the removable restoration; at the same time, optimally located muscle attachments help stabilization and retention of the denture base. The upper jaw belongs to type A while lower jaw can be either type A or B. While considering characteristics of the residual ridge, the following should be determined on the OPT image: height, that should be ≥ 21 mm when measured on the lowest position on the mandible, width and shape of the ridge if implant treatment is planned. Implantation procedure should be agreed with the surgeon with previous 3D diagnosis of jaw bone quality and other measurements on the jaws (proximity of sinus cavities and the mandibular canal) [14, 27, 28, 29].

PARTIAL EDENTULISM CLASS II

This class of partially edentulous patients is characterized by visible changes on some segments of orofacial system necessitating certain type of pre-prosthetic preparation. In practice, it means appropriate preparation of the patient (recognized by the dentist), which at the same time provides conditions for further quality prosthetic rehabilitation.

Location and size of edentulous area

Edentulous areas, found in one or both tooth arches are of the same size as in partial edentulism class I. Additionally, the situation is made difficult by the lack of canine teeth in the upper or lower jaw, and thus proposed therapeutic modalities become more complex for the patients and more difficult for the therapists.

Health status of retention teeth (abutment teeth)

Retention teeth in one or two sextants have insufficient tooth substance to retain fixed restorations. In order to include such patients in the prosthetic treatment, different interventions are required: endodontic, periodontal or orthodontic procedures. Topographically, sextant represents a part of the tooth arch, and thus maxillary and mandibular tooth arches may be divided into 6 parts: two left and two right posterior sextants, and two anterior sextants. Right posterior maxillary sextant includes teeth from 18–13, the left posterior from 23–28 while anterior maxillary sextant comprises teeth 13–23. Right posterior mandibular sextant includes teeth from 48–43, posterior left from 38–33 and anterior mandibular sextant covers teeth 33–43.

Occlusion model

It is observed that upon functional movements of the lower jaw, partially edentulous patients with skeletal class II show occlusal difficulties. Most commonly, they may be eliminated by well-planned selective grinding before prosthetic treatment. The patients belong to skeletal class I and dentoalveolar class I.

Characteristics of residual ridge

Morphological features of the ridge provide good retention and stabilization of the denture base, preventing its vertical and horizontal movements. Height of the residual ridge is 16–18 mm, measured at the least vertical height of the mandible on a panoramic radiograph. Both jaws belong to type A or B.

PARTIAL EDENTULISM CLASS III

Partial edentulism Class III shows severe changes in the stomatognathic system. Their complete management requires multidisciplinary approach and consultations with different dental specialists. Frequent symptoms in this group of patients include: reduced interocclusal space, enlarged tongue, signs of temporomandibular joint dysfunction (TMD), xerostomia, hyperactive gag reflex, and others. Different preparation procedures, such as multiple extractions, alveoloplasty and placement of implants are frequently necessary.

Location and size of edentulous area

Edentulous areas are found in one or both tooth arches. They are most commonly distributed in the posterior segments of the upper or lower jaw, include three or more missing teeth or two missing molars. Edentulous areas may also be anterior in the both jaws, extending to three or more missing teeth.

Health status of retention teeth (abutment teeth)

Potential abutment teeth for fixed restorations or retention teeth for partial restorations cannot sustain additional load in the initial phase of examination; therefore, they must be prepared for the planned tasks. Their preparation is endodontic, periodontal or orthodontic in three sextants. If the performed preparation proves to be successful, teeth are being designated as prognostically relatively good.

Occlusion model

Occlusal impediments resulting from disharmony of occlusal determinants are present in patients with partial edentulism class III. They cannot be eliminated by selective grinding and thus reconstruction of the occlusal plane is required however without alteration of the occlusal vertical dimensions. These patients most commonly belong to the skeletal class II, although they may also be class I or III.

Characteristics of the residual ridge

Due to its shape and dimensions, residual ridge of class III partially edentulous patients provides minimal conditions for stability and retention of the prosthesis while functional help of the muscles is moderate. Height of the residual ridge is 11–15 mm measured at the least vertical height of the mandible on a panoramic radiograph. Both jaws belong to type C.

PARTIAL EDENTULISM CLASS IV

This class of partial edentulism is characterized by significant changes in all segments of the stomatognathic system. The patients necessitate multidisciplinary pre-prosthetic treatment. However, even after completed preparation, prognostic success of rehabilitation of these patients is uncertain. The former is supported by the complexity of numerous surgical procedures that may be involved in preparatory activities: alveolar bone augmentation, correction of dentofacial deformities, implant placement, vestibuloplasty, etc. Clinical picture frequently gets complicated by the lack of interocclusal space, paresthesia, presence of congenital or acquired defects, systemic diseases or oncological sequelae. All this an indication of complex and high-risk prosthetic rehabilitation of these patients.

Location and size of edentulous area

Edentulous areas are found in both dental arches, their size is different and they are rather extensive. Edentulous areas are frequently associated with acquired or congenital maxillofacial defects.

Health status of retention teeth (abutment teeth)

Retention teeth arranged in four or more sextants are not capable of sustaining additional loads and thus they cannot support fixed restorations. They require different types of adjunctive dental therapy, with their quality still remaining uncertain.

Occlusion model

In class IV patients with partial edentulism instable occlusal relations are diagnosed. Vertical occlusal dimensions is changed, most commonly reduced. Preliminary reconstruction should start from as detailed as possible analysis of the study model on an articulator, and different forms of preparation should be suggested to the patient. Reconstruction of the complete existing occlusal model is required in final therapy along with correction of the vertical dimension. Skeletal class of the patients is II/2 or III, which additionally makes prosthodontic therapy more complex, particularly if orthodontic rehabilitation or orthognathic surgery are required.

Characteristics of residual ridge

Residual ridge size and design do not contribute to restoration stability, since both vertical and horizontal movements of the denture base are expected. Additionally, location of muscle attachment also significantly influences retention of the prosthesis. Height of the residual ridge is less than 10 mm, measured at the least vertical height of the mandible on a panoramic radiograph. Upper jaw belongs to type D, while lower jaw is classified as type D or E. Pre-prosthetic surgical treatment is necessary.

All information obtained upon examination of the patient are entered into the boxes of the worksheet designated for each criterion. Prosthodontic diagnostic index (PDI) for partially edentulous patients is created after filling out of the table. In this way, simple and professional communication is achieved, including issues related to complicated clinical symptoms. It should be stressed that regardless of the suggested future therapeutic modality, diagnostic level of the patients must not be changed (class categorization). The approach is considered to be correct when the situation achieved, after appropriate preparation, is assessed upon new examination and the patient is assigned to other class accordingly. Esthetic demands as well as presence of TMD signs and symptoms increase complexity of the class (applicable to classes I and II). Establishment of optimal oral hygiene regimen is necessary prerequisite for diagnostic examination (Table 2).

If the patient's upper jaw is edentulous and the lower one is partially edentulous, classification is performed

Table 2. Prosthodontic diagnostic index (PDI) according to the American College of Prosthodontists (ACP) recommendations

CRITERIA	Class 1	Class 2	Class 3	Class 4
Location and extend of the edentulous space				
On a single dental arch	√			
On both dental arches		√		
Extended edentulous space (more than 3 teeth missing)			√	
Guarded prognosis				√
Maxillo-facial defects				√
Abutments condition				
Ideal or minimally compromised	√			
Moderately compromised		√		
Substantially compromised			√	
Severely compromised				√
Occlusion				
Ideal or slightly affected	√			
Moderately compromised		√		
Substantially compromised			√	
Severely compromised – changes in vertical dimension				√
Residual ridge				
Class 1	√			
Class 2		√		
Class 3			√	
Class 4				√
Situations with guarded prognosis				
Oral manifestations of general diseases				√
Maxillo-mandibular dyskinesia and/or ataxia				√
Refractory patient				√

for each arch separately, and thus upper jaw is classified according to classification applicable to edentulism [27, 28]. A relatively frequent clinical situation characterized by edentulous lower jaw in combination with partially edentulous upper jaw or even completely dentate upper jaw is considered to be an exceptionally complicated situation with an uncertain prognostic outcome and it is categorized as class IV in both systems.

It should be noticed that although the system emphasizes significance and the role of each individual variable as a valid criterion, finally determined class corresponds to the factor of greatest complexity. Classification established in this way results in creation of individual PDI profile, which is of great help in defining of prognosis and treatment plan in each patient [30].

Additionally, it is evident that ACP classification system provides optimal space for organized clinical observations in which considered variables are systemized in ascending order of complexity, depending on the case of partial edentulism. With this respect, it is possible to suggest different types of preparations and referral to other specialties in order to assure long-term success of final prosthetic rehabilitation.

Despite numerous advantages, the proposed classification system appears to be complex in some way. It necessitates experienced prosthodontist who must be familiar with the classification protocols related to edentulous and

partially edentulous patients as well as completely dentate patients in order to systemize correctly the criteria that is important for partial edentulism [27, 31]. In this way, additional time is dedicated to conversing with patients (which is a time consuming procedure), processing the collected data and keeping the documents.

Regardless of the statement above, it should not be forgotten that modern dentistry largely supports all forms of wants-based service (custom driven). Therefore, outcome success of the practical application protocol may be mea-

sured largely by patients' satisfaction. It has been known that some forms of application confirmation of edentulous patient classification and their resulting therapeutic success are subject of university projects [30, 32, 33, 34].

The conclusion of the current issue is the fact that applying "instant" therapeutic solutions in the everyday dental practice does not always mean the best options for the patient. Therefore, only the respect for broadly defined protocol positions, can result in the detection of optimal modalities in solving complex professional problems.

REFERENCES

- Field MJ, Lohr KN. Clinical practice guidelines: directions for a new program. Washington, DC: National Academy Press; 1990.
- Woolf HS, Grol R, Hutchinson A, Eccles M, Grimshaw J. Potential benefits, limitations and harms of clinical guidelines. *BMJ*. 1999; 318:527–30.
- Siemieniuk RA, Agoristas T, Macdonald H, Guyatt GH, Brandt L, Vadvik PO. Introduction to BMJ Rapid Recommendations. *BMJ*. 2016; 354:i5191.
- Neuman MD, Goldstain JN, Cirullo MA, Schwartz JS. Durability of class I American College of Cardiology/American Heart association clinical guideline recommendations. *JAMA*. 2014; 311(20):2092–100.
- Norberg MM, Turner MW, Rooke SE, Langton JM, Gates PJ. An Evaluation of Web based Clinical Practice Guidelines for Managing Problems Associated with Cannabis Use. *J Med Internet Res*. 2012; 14(6):e169.
- Brito JP, Domecq JP, Murad MH, Guyatt GH, Montori VM. The Endocrine Society guidelines: when the confidence cart goes before the evidence horse. *J Clin Endocrinol Metab*. 2013; 98(8):3246–52.
- Shekelle P, Eccles PM, Grimshaw MJ, Woolf HS. When should clinical guidelines be updated? *BMJ*. 2001; 323(7305):155–7.
- Ahmad I. Protocols for predictable aesthetic dental restorations. Oxford: Blackwell Munksgaard, Blackwell publishing company; 2006.
- Clinical practice guidelines. ADA Clinical practice guidelines handbook; 2013.
- The basic protocols-IC Guidelines for dental service, DH; 2009.
- Belser U, Buser D, Higginbottom F. Consensus statements and recommended clinical procedures regarding esthetics in implant dentistry. *Inter J Oral Maxillofac Implants*. 2004; 19(suppl):73–4.
- Morton D, Jaffin R, Weber HP. Immediate restoration and loading of dental implants: clinical considerations and protocols. *Int J Oral Maxillofac Implants*. 2004; 19(suppl):103–8.
- AlHelal A, Kattadiyil MT, AlBader B, Clark LJ. A protocol for screw-retrievable, cement-retained implant-supported fixed partial dentures. *Int J Prosthodont*. 2017; 30:577–80.
- Largo L, Rilo B, Fernandez-Formozo N, DaSilva L. Implant rehabilitation planning protocols for the edentulous patient according to denture space, lip support, and smile line. *J Prosthodontics*. 2017; 26(6):545–8.
- Sadowsky SJ. Treatment considerations for maxillary implant overdenture: a systematic review. *J Prosthet Dent*. 2007; 97:340–8.
- Avrampou M, Mericske-Stern R, Blatz M, Katsoulis J. Virtual implant planning in the edentulous maxilla: criteria for decision making of prosthesis design. *Clin Oral Impl Res*. 2013; 24 (suppl A 100):152–9.
- Bedrossian E, Sullivan RM, Malo P, Indresano T. Fixed prosthodontic implant restoration of the edentulous maxilla: a systematic pretreatment evaluation method. *J Oral Maxillofac Surg*. 2008; 66(1):112–22.
- Malo P, Araujo M, Lopes I. A new approach to rehabilitate the severely atrophic maxilla using extramaxillary anchored implants in immediate function. A pilot study. *J Prosthet Dent*. 2008; 100(5):354–66.
- Calvani L, Michalakakis K, Hirayama H. The influence of full arch implant retained fixed dental prostheses on upper lip support and lower facial esthetic: preliminary clinical observations. *E J Esthet Dent*. 2007; 2(4):420–8.
- Bidra AS. Three-dimensional esthetic analysis in treatment planning for implant-supported fixed prosthesis in the edentulous maxilla: review of the esthetic literature. *J Esthet Restor Dent*. 2011; 23:219–36.
- Bidra AS, Agar JR. A classification system of patient for esthetic fixed implant-supported prostheses in the edentulous maxilla. *Compend Contin Educ Dent*. 2010; 31:366–8, 370, 372–4.
- Stamenković D. Stomatološka protetika, parcijalne proteze, II izdanje. Beograd: Datastatus; 2017. p. 78–81.
- Bratu E, Bratu D, Antonie S. Classification system for partial edentulism. *OHDMBSC*. VI, 4:50–55, 2007.
- Jeyapalan V, Krishnan SC. Partial edentulism and its correlation to age, gender, socio-economic status and incidence of various Kennedys classes-a literature review. *J Clinic Diagnostic Res*. 2015; 9(6):ZE14–7.
- Galagali G, Mahoorak S. Critical evaluation of classification system of partially edentulous arches. *Int J Dent Clin*. 2010; 2(3):45–52.
- McGarry TJ, Nimmo A, Skiba JF, Ahlstrom RH, Smith CR, Koumjian JH, et al. Classification system for partial edentulism. *J Prosthodont*. 2002; 11(3):181–93.
- McGarry TJ, Nimmo A, Skiba JF, Ahlstrom RH, Smith CR, Koumjian JH. Classification system for completely edentulism. *American College of Prosthodontics. J Prosthodont*. 1999; 8(1):27–39.
- Martinović Ž, Tihaček Šojić Lj, Živković R. Totalna zubna proteza. Beograd: autorsko izdanje; 2014. p. 90–104.
- Wismeijer D, Tawsw Smith A, PayneTGA. Multicentre prospective evaluation of implant-assisted mandibular bilateral distal extension removable partial dentures: patient satisfaction. *Clin Oral Impl Res*. 2013; 24:20–7.
- Mazurat RD, Mazurat NM. Communicating complexity: using a diagnostic classification system for edentulous patients. *J Can Dent Assoc*. 2003; 69(8):511–4.
- Mc Garry TJ, Nimmo A, Skiba JF, Ahlstrom RH, Smith CR, Koumjian JH, et al. Classification system for the completely dentate patient. *J Prosthodont*. 2004; 13:73–82.
- Douglass CW, Shih A, Ostry L. Will there be a need for complete dentures in the United State in 2020? *J Prosthet Dent*. 2002; 87(1):5–8.
- Felton D, Cooper L, Duquom I, Minsley G, Guckes A, Haug S, et al. Evidence-based guidelines for the care and maintenance of complete dentures. *JADA*. 2011; 142(2suppl):15–205.
- Obradović Đuričić K, Đuričić T, Medić V, Radović K. Ethics and marketing in esthetic dentistry. *Srp Arh Celok Lek*. 2017; 145(9-10):540–5.

Протоколи у класификацији крезубости

Косовка Обрадовић-Ђуричић¹, Тијана Ђуричић², Весна Медић¹, Дејан Стаменковић¹

¹Универзитет у Београду, Стоматолошки факултет, Клиника за стоматолошку протетику, Београд;

²НОВА Академија уметности, Београд, Србија

САЖЕТАК

У раду се дискутује о значају примене протокола у савременој стоматологији. Литературни подаци који обухватају препоруке и консензусе у стоматолошкој пракси говоре о њиховој присутности у доступним књигама, штампаним радовима у рецензираним часописима, и додацима часописа као закључци експертских група. Треба приметити да су протоколи најчешће ослоњени на валидне постулате различитих медицинских грана, помогнути специфичним условима средине у коју се имплементирају. Додатно, у нашим условима, протоколи у стоматологији су резултат захтева које институције и праксе морају да испуњавају сходно обновљивој акредитацији, као и поштовања препорука које су дате у водичима добре клиничке праксе различитог нивоа обавезности.

Поједини протоколи нуде терапијске модалитете који се категоризују у класе, помажући корисницима у избору пра-

вог третмана. О једном од таквих протокола који класификује крезубе пацијенте говори други део рада. Акцент је на примени класификације крезубости коју је препоручио Амерички колеџ протетичара, а која се ослања на четири дијагностичка критеријума, битна за терапијску одлуку. Локализација и величина безубих поља, стање здравља зуба носача, модел оклузије и карактеристике резидуалног гребена су параметри који су дефинисали четири класе крезубости различите сложености. Тако је, први пут, стоматолошкој пракси понуђен озбиљан, свеобухватни приступ клиничком статусу болесника, који обезбеђује, између осталог, и униформније стручне ставове у избору терапијских модалитета.

Кључне речи: протоколи; класификација крезубости; дијагностичка конзистентност