



CASE REPORT / ПРИКАЗ БОЛЕСНИКА

Successful surgical treatment of terminal heart failure in an adolescent – left ventricular assist device implantation and subsequent heart transplantation

Svetozar Putnik^{1,2}, Duško Terzić², Emilija Nestorović², Dejan Marković^{1,3}, Miljko Ristić^{1,2}¹University of Belgrade, Faculty of Medicine, Belgrade, Serbia;²Clinical Center of Serbia, Clinic for Cardiac Surgery, Belgrade, Serbia;³Clinical Center of Serbia, Center for Anesthesiology and Reanimation, Belgrade, Serbia**SUMMARY**

Introduction Implantation of the new-generation left ventricular assist device (LVAD) is an efficient therapeutic option as a bridge to transplantation in adults, as well as in children and adolescents with small body surface.

The aim of this work was to present a case of a successful surgical treatment of terminal heart failure in a male adolescent who had an LVAD implanted as a bridge to heart transplantation.

Case outline The patient, a 17-year-old male, was admitted with the end-stage heart failure due to the dilated cardiomyopathy and implanted LVAD. Fourteen months after LVAD implantation, a successful “second stage” surgical procedure was performed – orthotopic heart transplantation preceded by the LVAD explantation.

Conclusion Long-term mechanical circulatory support is an effective and safe method in treatment of the end-stage heart failure as a bridge to transplantation in the adolescent period.

Keywords: heart failure; heart transplant; left ventricular assist device; adolescents

INTRODUCTION

The first adult human heart transplant was performed by Christian Barnard in 1967. In 1966, Michael DeBakey implanted a left ventricular assist device (LVAD) for the first time. As the number of donors continues to decrease, raised demand in long-term circulatory support is registered. Implantable mechanical circulatory devices, such as the left ventricular assist device, have emerged as a standard option to improve survival and the quality of life of patients with end-stage heart failure. The indications for LVAD implantation include bridge to transplantation, bridge to recovery, and destination therapy. As technology advances, limitations due to age, body size, and comorbidities are becoming less prohibitive. Implantation of the last generation of LVAD became the standard therapeutic option for bridge to transplantation in adults, as well as for children and adolescents with lower body surface.

We present a case report of a successful surgical treatment of terminal heart failure in a male adolescent who had an LVAD implanted as a bridge to heart transplantation.

tions for a long-term mechanical circulatory support device implantation as a bridge to transplantation.

Prior to admission, the patient was hospitalized due to several episodes of cardiac decompensation. The echocardiographic findings showed the left ventricle severely dilated [end-diastolic diameter (EDD) 7 cm / end-systolic diameter (ESD) 6.6 cm), was globally hypocontractile, with reduced overall systolic function ejection fraction by Simpson (15%). The right ventricle was dilated (3.5 cm). Bilateral pleural effusion was marked, as well as the presence of fluid in the peritoneal cavity. Body surface area was 1.44 m². The patient was categorized as NIHA Class IV, INTERMACS Class 2.

The surgery was performed in general anesthesia through median sternotomy, with the use of extracorporeal circulation (CPB), on beating heart, without the need for aortic cross-clamping. After the institution of CPB, the inflow cannula site was marked in the apex of the left ventricle using echocardiographical guidance. The inflow cannula sited was reinforced with pledgeted sutures. After the inflow cannula implantation, the outflow graft was anastomosed to the aorta, which was followed by the drive-line tunneling in the upper right quadrant of the abdomen. The pump speed gradually increased with the weaning from the CPB.

The postoperative course was uneventful. Laboratory and radiological analyses were within the reference values (Figure 1).

CASE REPORT

A 17-year-old patient with the end-stage heart failure was admitted to the Clinic for Cardiac Surgery, Clinical Center of Serbia, with indica-

Received • Примљено:
February 23, 2017

Revised • Ревизија:
July 21, 2017

Accepted • Прихваћено:
July 24, 2017

Online first: August 4, 2017

Correspondence to:

Svetozar PUTNIK
Clinic for Cardiac Surgery
Clinical Center of Serbia
Dr. Koste Todorovića 8
11000 Belgrade, Serbia
svetozar073@yahoo.com

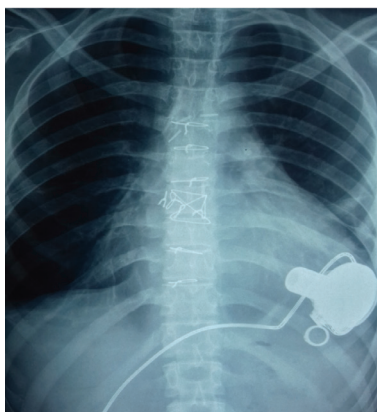


Figure 1. Radiographic finding after the left ventricular assist device implantation

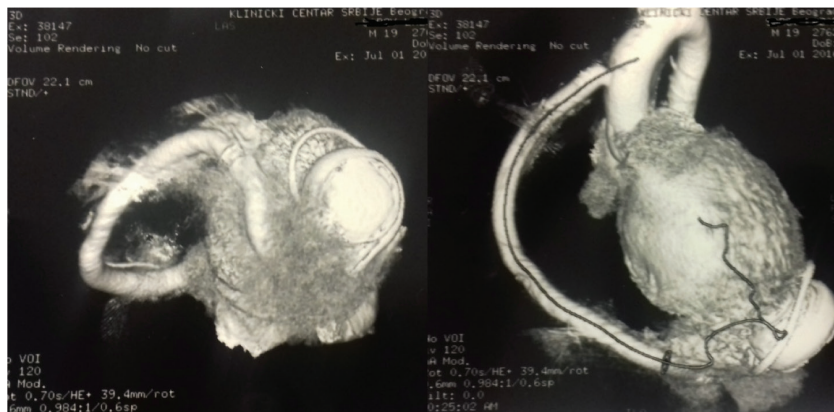


Figure 2. Multi-slice computed tomography finding – outflow cannula with the aorta and the inflow cannula with the left ventricle were competent

The echocardiography at discharge showed the left ventricle size decrease (EDD 6.7, ESD 6.1 cm). The right ventricle size was 1.6 cm with satisfactory systolic function. The inflow cannula had a good flow rate of 1.65 m/s.

The patient was discharged hemodynamically stable, in good general condition. The skin around the driveline exit site healed well, with no signs of infection.

In the follow up period, the patient was on a regime of regular clinical follow-up on the heart transplantation waiting list. International normalized ratio was controlled regularly, as well as the pump parameters and the driveline exit site. All the diagnostic procedures necessary for heart transplantation were done in the follow up period. Control computed tomography scan showed that the inflow and outflow cannulas were competent, with no signs of thrombosis (Figure 2).

Fourteen months after installing the HeartWare LVAD (HeartWare International Inc., Framingham, MA, USA), the heart transplantation was performed. Following the re sternotomy and the institution of CPB, explantation of the recipient’s heart and the LVAD was performed. We used standard aortic cannulation and the bicaval venous cannulation. The donor heart implantation was done using the biatrial technique (Figure 3).

The immediate postoperative course was uneventful, with no rejection elements found on the regular heart biopsies and with satisfactory echocardiographic findings.

The patient was discharged after a month, hemodynamically stable, in good general condition, with adequate cardiac and immunosuppressive therapy. After a one-year follow-up, the patient is alive and well, with no signs of the humoral rejection and satisfactory control echocardiography.

DISCUSSION

The prevalence of the advanced heart failure is increasing worldwide. Despite the limited availability of donor hearts, cardiac transplantation remains the gold standard for the treatment of terminal heart failure. One of the most promising new alternatives to heart transplantation is the use of ventricular assist devices [1].

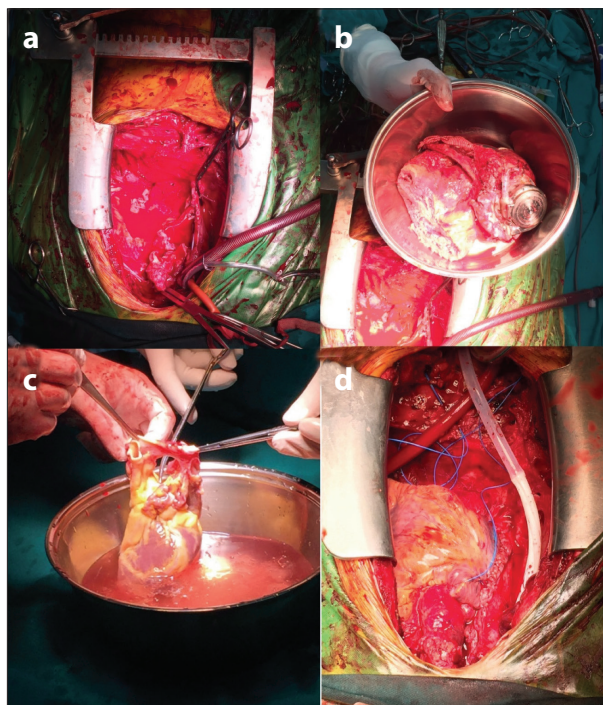


Figure 3. Heart transplantation after HVAD implantation; a, b) empty pericardial cavity after the HVAD and recipient’s heart explantation; c) preparation of the donor heart; d) transplanted heart

The number of LVAD systems implanted worldwide has increased due to significant improvement in survival rates in recent years. There are several factors that have contributed to these improved results. The systems are easier to implant than their forerunners, they are more durable and relatively easy to replace in the case of emergency, while the postoperative anticoagulation can be less intensive [2].

The HeartWare Ventricular Assist Device (HVAD) is a small, implantable centrifugal continuous-flow blood pump. It utilizes a hybrid magnetic/hydrodynamic impeller suspension for novel frictionless rotation, and optimizes flow, pump surface washing, and hemocompatibility. The HeartWare pump is connected to lightweight patient peripherals (controller, batteries) by a thin, flexible driveline with fatigue-resistant cables. In comparison with contemporary marketed VAD pumps, the HVAD has an integrated inflow cannula, allowing implantation within the pericardial

space, requiring no abdominal surgery for the formation of a pump pocket. The pump controller permits accurate flow estimation and maintains log files to enable flow and power waveform analyses [3].

Different devices for long-term mechanical support of circulation are in use in our department (Heart Mate 2, Heart Mate 3, Excor Berlin Heart, HeartWare). The Heart Mate 2 device is an axial pump that requires a tissue pocket to be created and larger body surface of the patient, while Heart Mate 3 is a centrifugal pump of significantly larger dimensions than the HeartWare. The Excor Berlin Heart is a pulsatile, pneumatically controlled external device that provides biventricular support. Having in mind the limited body surface of the patient and the fact that the patient's right ventricular function was acceptable at the moment of implantation, the heart team made the decision to implant the HeartWare device.

Implantation of the LVAD was previously restricted to patients with a body surface area of 1.5 m², which are primarily children and adolescents, but the continuous flow LVADs have been proven as safe in patients whose body surface area is as low as 1.3 m². The HeartWare LVAD,

which is implanted intrapericardially, practically does not have body size limitations. This is in contrast to heart transplantation, where most programs limit donors to 15% of the weight of the recipient [4].

Adolescents with heart failure can be successfully supported on a long-term basis with the LVAD as a bridge to transplantation [5].

This case represents successful use of the HVAD as a bridge to transplantation in an adolescent patient with small body surface. The LVAD improved the patient's end organ function and symptoms, leading to rehabilitation and weight gain that made him a more suitable heart transplant candidate.

The presented case of an adolescent with small body surface has shown that the implantation of the last-generation devices for long-term mechanical circulatory support is a contemporary, effective, and safe therapeutic option in the treatment of terminal-stage heart failure. Although technically challenging due to extensive adhesions and the proximity of the right ventricle to sternum, the subsequent heart transplantation has been performed successfully, with the uneventful recovery of the patient.

REFERENCES

1. Miller LW, Guglin M. Patient selection for ventricular assist devices: a moving target. *J Am Coll Cardiol.* 2013; 61(12):1209–21.
2. Krabatsch T, Potapov E, Soltani S. Should LVAD implantation be the new gold standard for terminal heart disease? *Herz.* 2015; 40:231.
3. Slaughter MS, Pagani FD, Rogers JG. HeartMate II Clinical Investigators. Clinical management of continuous-flow left ventricular assist devices in advanced heart failure. *J Heart Lung Transplant.* 2010; 29:S1–S39.
4. Slaughter MS, Rogers JG, Milano CA. Advanced heart failure treated with continuous-flow left ventricular assist device. *N Engl J Med.* 2009; 361(23):2241–51.
5. Helman DN, Addonizio LJ, Marales DLS, Catanese KA, Flannery MA, Quagebeur JM, et al. Implantable LVADs can successfully bridge adolescent patients to transplant. *J Heart Lung Transplant.* 2000; 19(2):121–6.

Успешно хируршко лечење терминалне срчане инсуфицијенције код адолесцента – имплантација уређаја за механичку потпору циркулације леве коморе и каснија трансплантација срца

Светозар Путник^{1,2}, Душко Терзић², Емилија Несторовић², Дејан Марковић^{1,3}, Миљко Ристић^{1,2}

¹Универзитет у Београду, Медицински факултет, Београд, Србија;

²Клинички центар Србије, Клиника за кардиохирургију, Београд, Србија;

³Клинички центар Србије, Центар за анестезиологију и реанимацију, Београд, Србија

САЖЕТАК

Увод Имплантација уређаја за механичку потпору циркулације леве коморе нових генерација је ефикасна терапијска опција као „мост“ до трансплантације код одраслих, али и код деце и адолесцената са мањом телесном површином. Циљ рада је био презентација хируршког лечења терминалне срчане слабости код мушког адолесцента коме је имплантиран уређај за трајну механичку потпору циркулације као „мост“ до касније успешне трансплантације срца.

Приказ болесника Болесник је хоспитализован у терминалном стадијуму срчане инсуфицијенције на бази дилатативне

кардиомиопатије. Четрнаест месеци касније, после појаве адекватног донора, извршена је експлантација уређаја заједно са болесним срцем примаоца и успешна трансплантација срца.

Закључак Уређаји за трајну механичку потпору циркулације су ефикасна терапијска опција у третману терминалне срчане инсуфицијенције као „мост“ до трансплантације срца.

Кључне речи: срчана слабост; трансплантација срца; уређаји за потпору леве коморе, адолесценти