

CASE REPORT / ПРИКАЗ БОЛЕСНИКА

Facial nerve paralysis as the first sign of metastatic breast cancer to the temporal bone

Miljan Folić^{1,2}, Dragoslava Đerić^{1,2}¹University of Belgrade, Faculty of Medicine, Belgrade, Serbia;²Clinical Centre of Serbia, Clinic for Otorhinolaryngology and Maxillofacial Surgery, Belgrade, Serbia**SUMMARY**

Introduction Facial nerve paralysis originates from various factors, although in most cases etiology is idiopathic. Temporal bone metastases are quite rare, but should still be suspected in cases when congenital disorders, inflammatory disease, infection or trauma are excluded as cause of facial palsy. We present an unusual case of facial nerve paralysis as the initial sign of temporal bone metastasis of breast carcinoma and discuss diagnostic pitfalls.

Case outline A 70-year-old patient presented with facial nerve palsy, severe otalgia, hearing loss and vertigo. Patient underwent steroid treatment 6 months earlier due to peripheral facial palsy with complete neurological resolution. CT scan revealed osteolytic lesion of the right temporal bone with extension into the parietal bone and soft-tissue. Additional examination confirmed ductal breast carcinoma and osteolysis of the ribs and vertebrae. After four months, the patient with metastatic breast carcinoma to the temporal bone died despite chemotherapy.

Conclusion Temporal bone metastasis of breast cancer is very rare condition with poor prognosis. Late diagnosis and inadequate management of breast cancer are factors that contribute to the temporal bone metastasis formation. Temporal bone metastasis should be excluded in elderly patients, both with and without any history of malignancy, especially in cases of peripheral facial palsy refractory to treatment.

Keywords: breast neoplasms; neoplasm metastasis; facial paralysis; temporal bone

**INTRODUCTION**

Facial nerve paralysis originates from various factors, although in most cases etiology is still defined as idiopathic. After excluding congenital disorder, inflammatory disease, infection or trauma as the possible cause of facial palsy, one should arouse suspicion of metastatic tumors to the temporal bone, as well as primary malignancies. However, temporal bone metastases are quite rare and early diagnosis is challenging due to asymptomatic course of the disease [1].

In some cases, coexistence of several pathological conditions may affect the diagnostic process and treatment approach. Difficulties in distinction between temporal bone metastasis and some inflammatory ear diseases might be explained with overlapping signs and symptoms. In patients with a history of malignancy, persistent otologic symptoms should actuate an otorhinolaryngologist to investigate the possibility of a metastatic tumor to the temporal bone.

We present an unusual case of facial nerve paralysis as initial sign of temporal bone metastasis of breast carcinoma and discuss diagnostic pitfalls.

CASE REPORT

A 70-year-old female patient presented with peripheral facial nerve palsy (PFNP), severe

otalgia, hearing loss and vertigo. Patient underwent steroid treatment 6 months earlier due to peripheral facial palsy with complete neurological resolution, which sustained a diagnosis of Bell's palsy. During the second episode of PFNP, physical examination revealed right facial paralysis (House-Brackmann scale, grade IV) with no signs of acute inflammation on otomicroscopy. A pure-tone audiometry showed profound sensorineural hearing loss on the right ear and moderate sensorineural hearing loss on the left ear. Hearing loss, type B tympanogram and peripheral vestibular lesion on the right side arose suspicion for neoplastic process in the temporal bone.

Computed tomography and magnetic resonance imaging of the temporal bone revealed expansive osteolytic lesion of squamous and mastoid parts of the right temporal bone with extension into the parietal bone and soft-tissue (Figure 1). Despite the fact that extraosseous part of the tumor had affected the epidural space and dura mater, creating the compressive impact on middle temporal gyrus of the brain, patient had no cognitive impairments.

Further examination revealed a lump in the left breast, so surgical biopsy was performed to obtain tissue samples. Histopathological and immunohistochemical analysis confirmed infiltrative ductal breast carcinoma and chest CT scan showed large expansive lesion in the right breast that infiltrate pectoral muscle and pericardium,

Received • Примљено:

January 10, 2018

Accepted • Прихваћено:

March 16, 2018

Online first: March 20, 2018**Correspondence to:**

Miljan FOLIĆ
Clinic for Otorhinolaryngology
and Maxillofacial Surgery, Clinical
Centre of Serbia, Pasterova 2,
11000 Belgrade, Serbia
mfolic@yahoo.com

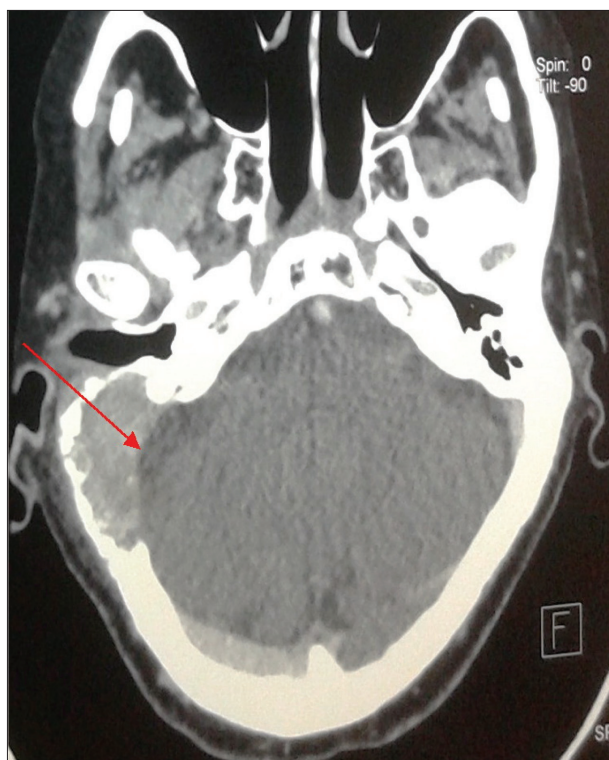


Figure 1. Computed tomography scan: osteolytic tumor of the right temporal bone with extension into the parietal bone and soft-tissue. Arrow shows compressive effect on the middle temporal gyrus of the brain.

pleural effusion as well as osteolysis of third and fourth right ribs, sternum and several thoracic vertebrae.

Although patient had received chemotherapy, malignant disease was evaluated as progressive with further intracranial extension (Figure 2). Four months after PFNP appearance, the patient with incurable metastatic breast carcinoma died.

DISCUSSION

The most frequent causes of sudden unilateral facial paralysis are Bell's palsy, Ramsey Hunt syndrome, Lyme disease and complications of chronic otitis. On the other hand, PFNP as the first sign of temporal bone metastasis is very uncommon. Furthermore, our patient recovered from PFNP after steroid treatment, which drew attention away from the real cause of paralysis. This is quite unique, since we found no recorded cases in literature concerning facial paralysis recovery in patients with temporal bone metastasis. We presume that steroid treatment has temporarily sustained compressive effects of the tumor which has made possible the neurological resolution. Additionally, our patient was not aware of the breast cancer at the moment of PFNP occurrence. Delayed diagnosis of primary breast cancer affected treatment options and made a great impact on the survival of the patient.

Metastatic tumors in the temporal bone are relatively rare and usually originate from the breast, lung or kidney [2, 3]. The true prevalence of metastatic tumors to the

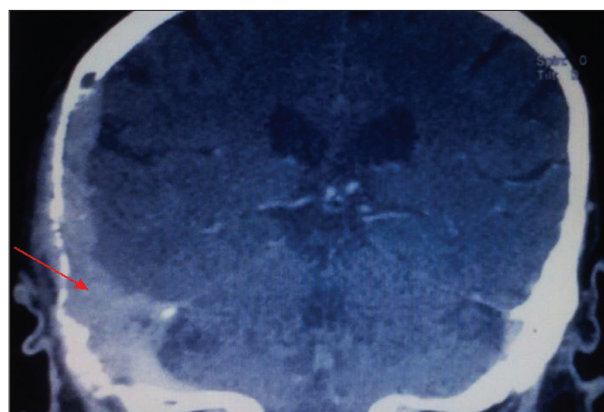


Figure 2. Coronal view of the computed tomography scan: progressive metastatic breast cancer after chemotherapy treatment (arrow)

temporal bone is unknown and diagnosis may encounter some difficulties due to fact that histopathological evaluation of temporal bones is not a part of routine autopsy examination in patient with primary malignant diseases [4]. Also, literature data are scanty and had been obtained mostly from case reports and several studies based on a small number of cases.

In the largest study of post-mortem examination on temporal bones of 212 patients with primary malignant neoplasms, Gloria-Cruz et al. [5] reported temporal bone metastases in 22% of patients. Temporal bone metastases are reported to originate from 20 different primary malignant tumors and the most common were breast and lung carcinoma. These results are contradictory with previous Maddox's findings, where renal carcinoma is the most frequent malignancy to metastasize to the temporal bone [6]. This is not surprising, considering the tendency of those cancers to metastasize to bone and the fact that about 75% of temporal bone metastases demonstrate hematogenous spread. Berlinger et al. [7] described five distinct patterns of temporal bone involvement with secondary malignant processes and concluded that hematogenous route is typical form of spreading to marrow tissue of the temporal bone. Additionally, breast carcinoma can pass through blood-brain barrier and form a brain metastasis. Temporal bone can be involved afterwards by direct or leptomeningeal extension, which is the sign of very advanced malignant disease.

Interestingly, it is reported that coexisting metastases are found elsewhere in each patient with temporal bone metastasis [5]. Therefore, temporal bone seems to be another site for metastatic spread along hematogenous course of dissemination. Detection of breast carcinoma metastasis to the temporal bone is potential indicator of the secondary deposits in other organs. Furthermore, there was a 100% correlation between absence of local recurrence and absence of temporal bone dissemination, which highlights the importance of adequate treatment of primary breast cancer.

Metastatic tumor to the temporal bone is usually asymptomatic for a certain period of time. In some cases, hearing loss could be the only sign of the disease. The

presentation of a patient with otalgia, facial nerve paralysis and periauricular swelling should raise a suspicion for a metastasis to the temporal bone [6]. Other symptoms include hearing loss, tinnitus, vertigo, ear secretion or aural mass. Different authors reported various incidence of facial paralysis in patients with temporal bone metastasis, ranging 15–50 % [5–8]. There is not a consistent correlation between invasion of the facial canal and facial paralysis. It seems that facial paralysis is exhibited in about 50% of patients with facial canal involvement [9], which excludes it as an early sign of temporal bone metastasis.

Inflammatory diseases, infections and some benign tumors should be considered in differential diagnosis. Suryanarayanan et al. [10] reported a case of secondary deposit in the temporal bone mimicking facial nerve schwannoma, and stressed the importance of suspecting metastatic tumors in patients with a previous history of malignancy. Considering the fact that some patients with chronic otitis may have similar presentation, temporal bone imaging is mandatory. Imaging studies have an irreplaceable role in determining the disease extent and possible surgical treatment assessment.

CT scans typically reveal expansive osteolytic lesion, devastating various portions of the temporal bone. Further extending to the soft tissue, surrounding bones or brain could be detected as indicators of advanced stage of the disease and poor prognosis. Differentiation between inflammatory and neoplastic process of the temporal bone is a difficult challenge due to osteolytic pattern observed on CT scans in patients with cholesteatoma or necrotizing otitis externa. Progressive bony destruction doesn't seem to be pathognomonic sign of metastatic disease to the temporal bone and should be interpreted with caution [11].

MRI is superior to CT in detecting soft-tissue mass involving meninges or brain. It is a powerful diagnostic tool to assess pathological processes along whole course of facial nerve, which makes MRI obligatory in case of an unusual PFNP. If there is a suspicion of skull base involvement, additional CT scanning is strongly recommended. The main advantage of CT scan is excellent evaluation of bone erosion, especially petrous part of the temporal bone.

Novel radiological methods provide us a possibility to detect multiple, coexisting breast cancer metastases. Caglar et al. [12] reported 97.6% sensitivity of FDG-PET/CT for the detection bone metastases, as well as high precision in identifying the soft-tissue extension. PET and MRI showed an even higher sensitivity in detecting breast cancer bony metastases than PET and CT [13]. Their utilization in determining local or metastatic recurrence is crucial for assessment of treatment response.

The treatment comprises chemotherapy with radiotherapy of the affected temporal region. Prognosis of breast cancer metastasis to the temporal bone is poor and it depends on coexisting metastasis elsewhere and primary site status. The two year survival rate is less than 40% due to asymptomatic course and late diagnosis of the disease. The absence of temporal bone involvement in cases with adequately treated primary tumors stresses the importance of early diagnosis and management of breast cancer. Temporal bone metastasis should be excluded in elderly patient with and even without history of malignancy, especially in cases of peripheral facial palsy refractory to treatment. In today's society with increased incidence of breast cancer, determining individual risk is the key factor for prevention of breast neoplastic transformation and metastatic dissemination.

REFERENCES

1. Đerić D, Boričić I, Tomanović N, Čvorović L, Blažić S, Folic M, et al. The facial palsy as first symptom of the temporal bone lung cancer metastasis. *Braz J Otorhinolaryngol*. 2017; 83(6):720–2.
2. Streitmann MJ, Sismanis A. Metastatic carcinoma of the temporal bone. *Am J Otol*. 1996; 17(5):780–3.
3. Cumberworth VL, Friedmann I, Glover GW. Late metastasis of breast carcinoma to the external auditor canal. *J Laryngol Otol*. 1994; 108(9):808–10.
4. Nelson EG, Hinojosa R. Histopathology of metastatic temporal bone tumors. *Arch Otolaryngol Head Neck Surg*. 1991; 117(2):189–93.
5. Gloria-Cruz TI, Schachern PA, Papaella MM, Adams GL, Fulton SE. Metastases to temporal bones from primary nonsystemic malignant neoplasms. *Arch Otolaryngol Head Neck Surg*. 2000; 126(2):209–14.
6. Maddox HE. Metastatic tumors to the temporal bone. *Ann oto Rhino Laryngol*. 1967; 76(1):149–65.
7. Berlinger NT, Koutroupas S, Adams G, Maisel R. Patterns of involvement of the temporal bone in metastatic and systemic malignancy. *Laryngoscope*. 1980; 90(4):619–27.
8. Schuknecht HF, Allam AF, Murakami Y. Pathology of secondary malignant tumors of the temporal bone. *Ann Otol Rhinol Laryngol*. 1968; 77(1):5–22.
9. Saito H, Chinzei K, Furuta M. Pathological features of peripheral facial paralysis caused by malignant tumour. *Acta Otolaryngol Suppl*. 1988; 446:165–71.
10. Suryanarayanan R, Dezzo A, Ramsden RT, Gillespie JE. Metastatic carcinoma mimicking a facial nerve schwannoma: the role of computerized tomography in diagnosis. *J Laryngol Otol*. 2005; 119(12):1010–2.
11. Lan MY, Shiao AS, Li WY. Facial paralysis caused by metastasis of breast carcinoma to the temporal bone. *J Chin Med Assoc*. 2004; 67(11):587–90.
12. Caglar M, Kupik O, Karabulut E, Hoiland-Carlson PF. Detection of bone metastases in breast cancer patient in the PET/CT era: Do we still need the bone scan? *Rev Esp Med Nucl Imagen Mol*. 2016; 35(1):3–11.
13. Catalano OA, Nicolai E, Rosen BR, Luongo A, Catalano M, Iannace C, et al. Comparison of CE-FDG-PET/CT with CE-FDG-PET/MR in the evaluation of osseous metastases in breast cancer patients. *BR J Cancer*. 2015; 112(9):1452–60.

Парализа фаџијалног живца као први знак метастазе карцинома дојке у темпоралној кости

Миљан Фолић^{1,2}, Драгослава Ђерић^{1,2}

¹Универзитет у Београду, Медицински факултет, Београд, Србија;

²Клинички центар Србије, Клиника за оториноларингологију и максилофаџијалну хирургију, Београд, Србија

САЖЕТАК

Увод Парализа фаџијалног живца може настати услед разних фактора, али је етиологија у већини случајева идиопатска. Метастаза у темпоралној кости се јавља изузетно ретко, али треба посумњати на њу као узрок фаџијалне парализе у случајевима када су искључени конгенитални поремећаји, запаљенска обољења, инфекције или повреде.

Циљ овог рада је био да прикажемо необичан случај парализе фаџијалног живца као првог знака метастазе карцинома дојке у темпоралној кости и дискутујемо о дијагностичким замкама.

Приказ болесника Седамдесетогодишња болесница је испољила периферну парализу фаџијалног живца и жалила се на интензиван бол ува, ослабљен слух и вртоглавицу. Лечена је кортикостероидном терапијом шест месеци раније због

периферне фаџијалне парализе са потпуним неуролошким опоравком. Компјутеризована томографија је показала остеоолитичну лезију десне темпоралне кости са пропацијом у паријеталну кост и у мека ткива. Додатна испитивања су доказала постојање дукталног карцинома дојке са остеолизом ребара и кичмених пршљенова. Болесница је преминула после четири месеца упркос спроведеној хемиотерапији.

Закључак Метастаза карцинома дојке у темпоралној кости је врло ретка и има лошу прогнозу. Њено постојање би требало искључити код старијих, са подацима о претходном малигнитету или без њих, а нарочито у случајевима периферне парализе фаџијалног живца који не реагује на терапију.

Кључне речи: тумор дојке; метастаза тумора; фаџијална парализа; темпорална кост