

## CASE REPORT / ПРИКАЗ БОЛЕСНИКА

**Bilateral abdominoscrotal hydrocele in childhood**Zlatan Elek<sup>1</sup>, Boban Mitrović<sup>1</sup>, Saša Dimić<sup>1</sup>, Aleksandar Božović<sup>1</sup>, Jovan Mladenović<sup>2</sup>, Zoran Marjanović<sup>3</sup><sup>1</sup>Kosovska Mitrovica Clinical Hospital Centre, Department of Pediatric Surgery, Kosovska Mitrovica, Serbia;<sup>2</sup>University of Priština, Faculty of Medicine, Kosovska Mitrovica, Serbia;<sup>3</sup>Clinical Centre Niš, Clinic for Children's Surgery and Orthopedics, Niš, Serbia**SUMMARY****Introduction** Bilateral abdominoscrotal hydrocele is a rare entity in childhood. The etiology of abdominoscrotal hydrocele has not been fully clarified. The diagnosis is based on clinical examination, ultrasound and magnetic resonance imaging. The treatment is surgery.**Case outline** This paper presents an eight-month-old boy who was admitted at the department of pediatric surgery due to bilateral swellings in the scrotum area. The changes were first noticed when he was three months old and the diagnosis of bilateral abdominoscrotal hydrocele was confirmed after the scrotum ultrasound examination. When the patient was six and eight months old, the symptoms have significantly increased, the magnetic resonance of the abdomen and the lesser pelvis was performed, and the bilateral abdominoscrotal hydrocele was successfully treated with inguinal surgery. The operative and postoperative course was uneventful.**Conclusion** In this paper, we presented a rare form of hydrocele in children, as well as diagnostic evaluation that involved ultrasound and magnetic resonance examination. Surgical treatment by inguinal approach is also presented.**Keywords:** bilateral; abdominoscrotal hydrocele; magnetic resonance**INTRODUCTION**

Abdominoscrotal hydrocele (ASH) is a rare form of hydrocele in children. Dupuytren was the first to describe it in 1834 [1]. Bickel introduced the term ASH in 1919 [1]. The reported incidence of ASH is 0.17–3.1% of hydroceles.

ASH has the shape of an hourglass and is made up of two parts: inguinoscrotal part and abdominal part which intercommunicate through the deep (internal) inguinal ring. The etiology and pathogenesis of ASH have not been clarified yet. The diagnosis is based on clinical appearance, ultrasound, and magnetic resonance imaging [2].

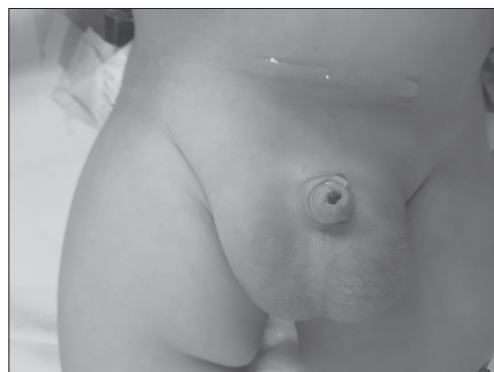The treatment of ASH is surgery. Generally, as in all hydroceles in children, the inguinal approach is considered standard, although there are cases in which the operation was done by the scrotal approach. The paper presents a case

of bilateral ASH that was surgically treated by the inguinal approach [3, 4, 5].

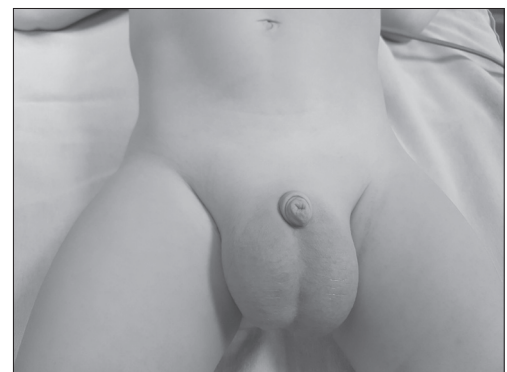**CASE REPORT**

We present an eight-month-old boy who was admitted to the department of pediatric surgery for an intervention.

The first time the patient was admitted for examination at the age of three months because of a bilateral scrotum swelling. Clinical examination showed both testicles in the scrotum and bilateral hydrocele (Figure 1). An ultrasound exam of the scrotum, pelvis, and urinary tract was performed. The diagnosis of ASH on the left side, and hydrocele on the right side was established. Urinary tract was normal. Control exam was scheduled in three months. An ultrasound check-up exam of the scrotum and



**Figure 1.** Bilateral hydrocele was diagnosed in the third month of age



**Figure 2.** Bilateral hydrocele in the eighth month of age

**Received • Примљено:**  
February 14, 2018

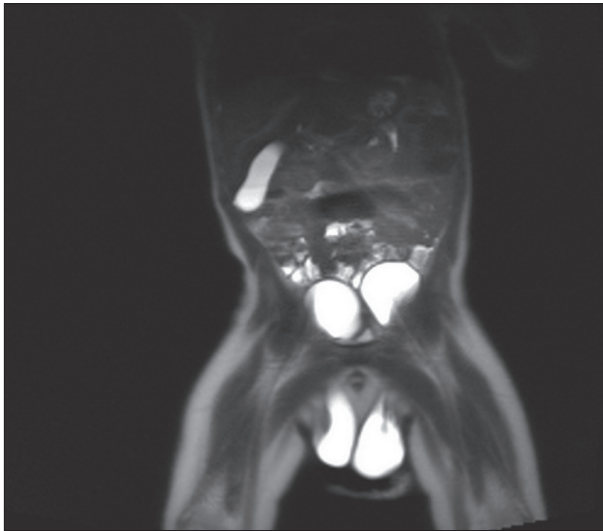
**Revised • Ревизија:**  
June 25, 2018

**Accepted • Прихваћено:**  
June 27, 2018

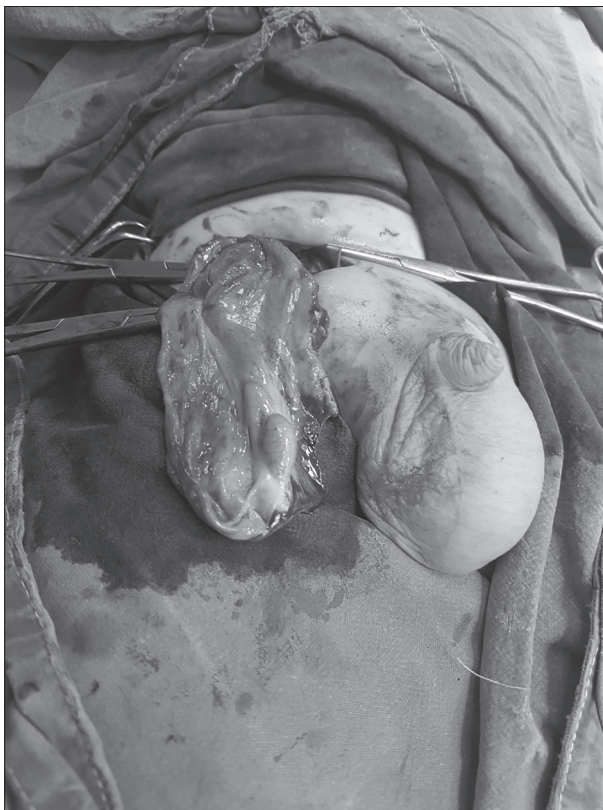
**Online first:** June 29, 2018

**Correspondence to:**

Zlatan ELEK  
Džona Kenedija 19/15  
38220 Kosovska Mitrovica  
[drzelek@gmail.com](mailto:drzelek@gmail.com)

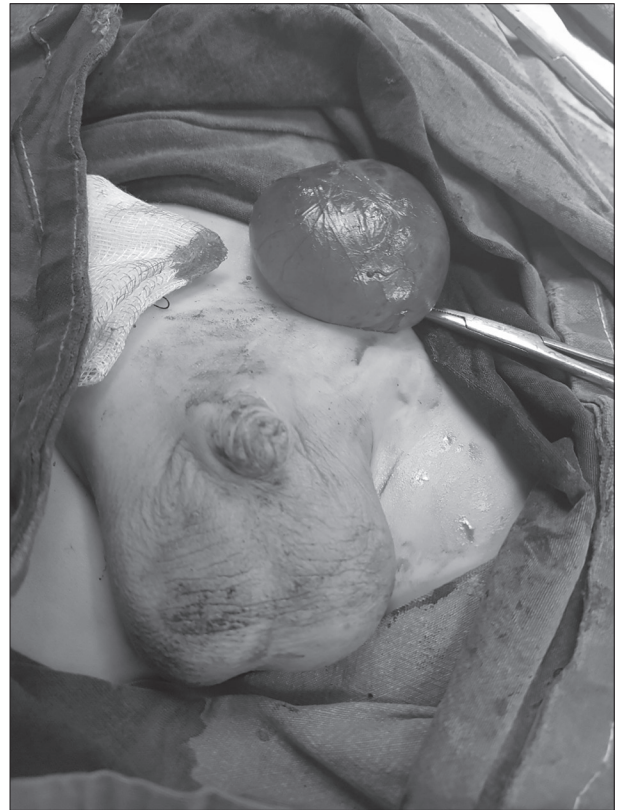

**Figure 3.** Magnetic resonance imaging findings of bilateral abdominoscrotal hydrocele

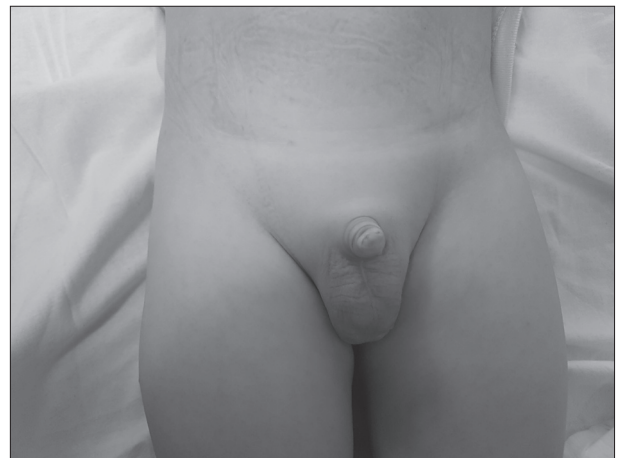

**Figure 4.** Operative finding after resection of right-sided abdominoscrotal hydrocele

pelvis were done when the patient was six months old. A 36-milimeter wide bilateral ASH was diagnosed, extending upwards through the inguinal canal into the abdominal cavity, with the diameter of 56 mm on the left side and 38 mm on the right side. The proximal part of hydrocele covered and compressed the urinary bladder. Since the hydroceles have grown from the previous examination, MRI of the abdomen and pelvis were performed. The MRI findings showed liquid deposits in the scrotum with a maximum diameter of 58 mm on the left side and 40 mm on the right



**Figure 5.** Operative finding after resection of left-sided abdominoscrotal hydrocele – abdominal component



**Figure 6.** Postoperative finding six months after surgery

side. The described changes extended through the inguinal canal, compressing within the abdominal cavity the urinary bladder and reaching the common iliac artery branches, corresponding to ASH (Figures 2 and 3).

The child was admitted to the department and prepared for surgical intervention. The surgical intervention was done under the usual conditions of endotracheal anesthesia for the inguinal approach (Figures 4 and 5).

Operative and postoperative courses were uneventful. Wounds healed *per primam intentionem*. Stitches were removed on the seventh postoperative day, when the child was discharged. Regular checkups on the seventh, 14th, and 30th day after the operation showed regular clinical findings (Figure 6).

## DISCUSSION

The exact etiology of ASH is unclear. Multiple theories have tried to explain ASH. According to Dupuytren, excessive distension of tunica vaginalis dislocates the hydrocele upwards through the inguinal canal into the abdomen leading to the formation of the abdominal mass [5]. A second theory suggests that the intrascrotal pressure raises when the scrotal hydrocele spreads to the abdomen using the valvular mechanism of the peritoneal vaginal process. The third theory postulates the presence of a preformed congenital peritoneal diverticulum with an underlying anatomic abnormality of the preexisting abdominal sac [5, 6].

ASH looks similar to an inguinoscrotal hernia, and the adequate diagnosis is based on ultrasound and magnetic resonance findings. If the connection between the cystic abdominal mass and the hydrocele is not clearly established by ultrasound, the traditional modality like magnetic resonance or computed tomography should be considered for imaging the abdomen and scrotum of a child. ASH is sometimes complicated by other pathological conditions. Estevão-Costa et al. [7] recorded acute bleeding in ASH. Velasco reported malignant mesothelioma of tunica vaginalis in ASH. Gentile and his co-workers cited that ASH can be a cause of ureterohydronephrosis in children [8, 9]. It has been reported in ASH cases that testicular dysmorphism is common because of the increased hydrocele pressure.

Vaos et al. reported that 30.1% of infants with unilateral ASH had contralateral testicular abnormalities like hydrocele, undescended testicles, intraabdominal testicular torsion and testicular regression [10, 11]. Dandapat et al. noted arrested spermatogenesis in 18% of adults with ASH [12, 13].

The most frequent complications of a hydrocele abdominal mass can cause compression of adjacent structures leading to oedema of lower limbs and hydronephrosis [1].

Secondary ureterohydronephrosis, lymphedema, acute bleeding, cryptorchism, transversal testicular ectopy, and

pretesticular malignant mesothelioma can be linked to ASH [14]. Other differential diagnostic entities include mesenteric and enteric duplications, massive hydronephrosis with extension into pelvis, bladder diverticulum, and cystic ovarian neoplasm [5].

The treatment of ASH is surgical, although there are cases of spontaneous regression. Some authors recommend early correction, between six and 12 months of age to prevent testicular abnormalities like testicular dysmorphism. In 2006, Upadhyay et al. reported a case of spontaneous resolution of ASH [3, 11]. That same year, De Renzo and Barong underline the natural remission of the intraabdominal pouch in a case of an infant [3, 15].

The operative approach to resection of an ASH depends on the size of the abdominal component of the sac. There are reports in the literature of resection solely through an inguinal approach [5, 16]. Other surgical techniques described include the intraperitoneal, preperitoneal, and scrotal approach. The preperitoneal approach was described by Luks et al. and the scrotal approach with laparoscopic assistance was described by Kinoshita et al. [10, 15, 16, 17]. The scrotal approach was proposed by Ferro alone, then Belman et al. described Lords modified technique (application of *tunica vaginalis*) [10, 12, 18].

During surgical intervention, special attention is given to the protection of funicular elements and to ensure adequate hemostasis [3, 14]. Surgery in ASH is not a simple procedure, review Cuervo et al. [3, 14]. Large, tense, protruding, thickened wall hydrocele makes it difficult to separate the surrounding structures, like spermatic cord elements. Transaction of the *vas deferens* or difficult hemostasis with postoperative hematoma has been reported. Insufficient excision of the pathogenic tunica vaginalis can result in recurrent hydrocele [3].

ASH is diagnosed after a complete physical examination and is successfully treated with surgical inguinal approach. This surgical procedure is associated with few intraoperative and postoperative complications.

## REFERENCES

- Spelman K, Stock JA, Norton KI. Abdominoscrotal hydrocele: a rare cause of a cystic abdominal mass in children. *Urology*. 2008; 71(5):832-3.
- Brodman HR, Brodman LE, Brodman RF. Etiology of abdominoscrotal hydrocele. *Urology*. 1977; 10(6):564-5.
- Spataru RI, Iozsa DA, Nisipasu CI. Abdominoscrotal hydrocele an underestimated entity. *Jurnalul Pediatrului*. 2014; 17(65/66):58-61.
- Pogorelič Z, Jurić I, Bogdanić Ž, Krželj V. Bilateral abdominoscrotal hydrocele in a 5-month-old infant presented with a left leg edema and cyanosis. *Hernia*. 2013; 17(4):533-5.
- Yarram SG, Dipietro MA, Grayiano K, Mychaliska GB, Strouse PJ. Bilateral giant abdominoscrotal hydroceles complicated by appendicitis. *Pediatr Radiol*. 2005; 35(12):1267-70.
- Hisamatsu E, Takagi S, Nomi M, Sugita Y. A case of bilateral abdominoscrotal hydroceles without communication with the peritoneum. *Indian J Urol*. 2010; 26(1):129-30.
- Estevao-Costa J, Morgado H, Soares-Oliveira M, Campos M, Carvalho JL. Hemorrhagic abdominoscrotal hydrocele: a challenging entity. *J Pediatric Surgery*. 2005; 40(40):731-3.
- Velasco AL, Ophoven J, Priest JR. Paratesticular malignant mesothelioma associated with abdominoscrotal hydrocele. *J Pediatric Surgery*. 1988; 23(11):1065-7.
- Gentile DP, Rabinowitz R, Hubler WC. Abdominoscrotal hydrocele in infancy. *Urology*. 1998; 51:20-2.
- Cuervo JL, Ibarra H, Molina M. Abdominoscrotal hydrocele: its particular characteristics. *J Pediatric Surgery*. 2009; 44(9):1766-70.
- Belman AB. Abdominoscrotal hydrocele in infancy: a review and presentation of the scrotal approach for correction. *J Urol*. 2001; 165(1):225-7.
- Perez J, Dominguez C. Scrotal approach for the correction of an abdominoscrotal hydrocele: Medium term follow-up. *Ped Urol case Rep*. 2015; 2(4):25-30.
- Kinoshita Y, Shono T, Nishimoto Y, Masunato K, Taguchi T, Suita S. A case of an abdominoscrotal hydrocele surgically treated under laparoscopic assistance. *J Pediatr Surg*. 2006; 41(9):1610-2.
- Vaos G, Zavras N, Eirekat K. Testicular dysmorphism in infantile, abdominoscrotal hydrocele: insights into etiology. *Int Urol Nephrol*. 2014; 46(7):1257-61.
- Luks FI, Yazbeck S, Homsy Y, Collin PP. The abdominoscrotal hydrocele. *Eur J Pediatr Surg*. 1993; 3(3):176-8.
- Dandapat MC, Padhi NC, Patra AP. Effect of hydrocele on testis and spermatogenesis. *Br J Surg*. 1990; 77(11):1293-4.
- De Renzo CC, Barone JG. Nonoperative management of abdominoscrotal hydroceles in an infant. *Urology*. 2006; 68(2):428.e9-11.
- Ferro F, Spagnoli A, Lucchetti MC, Marchetti P. Abdominoscrotal hydrocele: a reliable surgical technique. *Urology*. 2000; 55(5):771-3.

## Билатерална абдоминоскротална хидроцела у дечјем узрасту

Златан Елек<sup>1</sup>, Бобан Митровић<sup>1</sup>, Саша Димић<sup>1</sup>, Александар Божовић<sup>1</sup>, Јован Младеновић<sup>2</sup>, Зоран Марјановић<sup>3</sup>

<sup>1</sup>Клиничко-болнички центар Косовска Митровица, Одељење дечје хирургије, Косовска Митровица, Србија;

<sup>2</sup>Универзитет у Приштини, Медицински факултет, Косовска Митровица, Србија;

<sup>3</sup>Клинички центар Ниш, Клиника за дечју хирургију и ортопедију, Ниш, Србија

### САЖЕТАК

**Увод** Билатерална абдоминоскротална хидроцела је редак ентитет у дечјем узрасту. Етиологија абдоминоскроталне хидроцеле није у потпуности разјашњена. Дијагноза се поставља на основу клиничке слике, ултразвучног прегледа и магнетне резонанце. Лечење је хируршко.

**Приказ болесника** У раду је приказан дечак стар осам месеци који је примљен на одељење дечје хирургије због обостраног отока у пределу скротума. Први пут су промене уочене у трећем месецу старости, а дијагноза је потврђена на основу ултразвучног прегледа скротума и мале карлице. На контролним прегледима у шестом и осмом месецу ста-

рости промене су се значајно увећале, урађена је магнетна резонанца абдомена и мале карлице и предузето је оперативно лечење. Оперативни и постоперативни ток протекли су уредно.

**Закључак** У раду смо приказали један од ретких случајева хидроцеле у дечјем узрасту, као и дијагностичку евалуацију која је обухватала ултразвучну дијагностику и магнетну резонанцу. Такође је приказано хируршко лечење ингвиналним приступом.

**Кључне речи:** билатерална; абдоминоскротална хидроцела; магнетна резонанца