

CASE REPORT / ПРИКАЗ БОЛЕСНИКА

Oral rehabilitation of a patient with systemic lupus erythematosus using implant-supported fixed dentures – a case report with review of important considerations

Vladimir S. Todorović¹, Marija S. Milić¹, Miroslav Vasović², Živorad Nikolić³¹University of Belgrade, School of Dental Medicine, Belgrade, Serbia;²University of Kragujevac, Faculty of Medical Sciences, Department of Dentistry, Kragujevac, Serbia;³University Business Academy, Faculty of Dentistry, Pančevo, Serbia**SUMMARY**

Introduction Systemic lupus erythematosus (SLE) is a chronic autoimmune inflammatory disease with a variety of oral manifestations (dry mouth, reduced salivary flow, painful mucosal lesions and restricted mouth opening, impaired oral hygiene maintenance), as well as possible far-reaching systemic implications. In the context of SLE, oral rehabilitation with dental implants might be the most appropriate solution. However, a lack of available literature, as well as the absence of treatment protocols, often leads to unsatisfactory management of these patients.

The aim of this paper was to describe oral rehabilitation of a patient with SLE using dental implants and fixed dentures in both jaws.

Case outline A 66-year-old female patient, who had suffered from SLE for over 30 years, was referred for oral rehabilitation as her chief complaints related to the existing mobile partial dentures in the jaws and poor chewing ability. Proposed oral rehabilitation with fixed dentures supported by six dental implants in the maxilla and four dental implants in the mandible, as well as prosthetic restoration of the mandibular teeth, was accepted by the patient. During the follow-up period of three years, no biological complications were observed related to the performed treatment.

Conclusion Dental implants might be the most suitable treatment modality for oral rehabilitation of patients suffering from SLE.

Keywords: dental implants; oral rehabilitation; systemic lupus erythematosus

INTRODUCTION

Systemic lupus erythematosus (SLE) is a chronic, autoimmune, inflammatory disease with multiple organ involvement and a broad spectrum of clinical manifestations, including mucocutaneous, cardiac, renal, pulmonary, and musculoskeletal complications [1]. The hallmark of this relapsing and remitting disease is the production of autoantibodies and immune complexes, with a consequent inflammatory response that may lead to cell death and organ failure [2].

Orofacial structures and functions may be adversely affected in the presence of SLE. Intraoral manifestations are most frequently presented as painful erythematous erosions, ulcerations and/or leukoplakic areas, localized on buccal, labial, lingual or palatal mucosa [1–3]. The most frequent complaints include xerostomia and burning mouth syndrome, while desquamative gingivitis, marginal gingivitis, and periodontitis are among common findings [1, 3–6]. Musculoskeletal complications may involve painful temporomandibular joint dysfunction, with possible repercussions on intraarticular mechanics. Additionally, immunosuppressive therapy, including cortico-

steroids and cytotoxic agents, poses a risk of inducing osteoporosis and altered immune response, with an increased susceptibility to oral infections [3]. Regarding reduced salivary flow, painful mucosal lesions may develop and impair oral hygiene regimen; often associated with restricted mouth opening and possible adverse effects of immunosuppressive therapeutic agents. Therefore, providing satisfactory oral rehabilitation of patients with SLE might prove challenging.

The main objective of this paper was to present the case of a patient with SLE, for whom oral rehabilitation with implant-supported fixed dentures was chosen as a treatment modality for partial edentulism. Considerations in regard to SLE complications and their possible impact on oral rehabilitation with dental implants were also discussed.

CASE REPORT

A 66-year-old female patient was referred for oral rehabilitation as her chief complaints related to the existing mobile partial dentures in jaws and poor chewing abilities. Medical records showed that the patient had suffered

Received • Примљено:

September 12, 2017

Revised • Ревизија:

December 20, 2017

Accepted • Прихваћено:

December 22, 2017

Online first: December 29, 2017**Correspondence to:**Vladimir S. TODOROVIĆ
35 Lješka Str.
Belgrade 11000, Serbia
todent@yahoo.com

from SLE for over 30 years. Treatment modality for SLE included 400 mg of hydroxychloroquine per day (Plaquenil, 200 mg tablets; Sanofi-Aventis, London, UK). Also, the patient was diagnosed with antiphospholipid syndrome treated with low doses of acetylsalicylic acid (Aspirin, 81 mg tablets; Bayer Pharma AG, Leverkusen, Germany; one tablet daily). Regarding other significant comorbidities, the patient had suffered from diabetes mellitus type 2 (DMT2) for 25 years. Metabolic control regarding DMT2 was satisfactory with glycosylated hemoglobin level < 8%, without microvascular and macrovascular complications registered in the patient's medical record, and DMT2 therapy consisted of diet, oral hypoglycemic agent metformin (Glucophage SR, 750 mg tablets; Merck Pharmaceuticals, UK; two tablets daily) and long-acting insulin analogue (Lantus SoloStar 100 unit/ml solution, Sanofi-Aventis; 36 units daily). A further daily therapy regimen included nifedipine with extended release (Adalat LA, 60 mg tablets; Bayer House, UK; one tablet daily) and atenolol (Atenolol, 50 mg tablets, Actavis, UK; one tablet daily) for essential hypertension treatment, as well as calcium + vitamin D₃ supplements (Calcium 600 mg +D₃, 600 mg – 200-unit tablets; Major Pharmaceuticals, Livonia, MI, USA; one tablet daily) for osteopenia.

Extraoral clinical inspection did not demonstrate facial skin involvement. Intraoral clinical examination presented characteristic bilateral discoid and pigmented lesions involving buccal mucosa, reddened tongue with atrophy of the filiform papilla and sore mouth, with no ulcerations observed (Figure 1). The patient complained of symptoms similar to burning mouth syndrome (BMS), especially when consuming acidic or spicy food, difficulties in swallowing, and dry mouth. However, after salivary flow measurement according to the protocol described by Speight et al. [7], the obtained unstimulated saliva flow rate was 0.2 mL/minute. A problem with limited mouth opening was also reported by the patient, as well as the slight pain in the temporomandibular joints (TMJ) while chewing. Clinical examination of the TMJ did not reveal signs of dislocation, subluxation, or crepitation during mandibular movements. Maximal inter-incisal distance was 24 mm. In

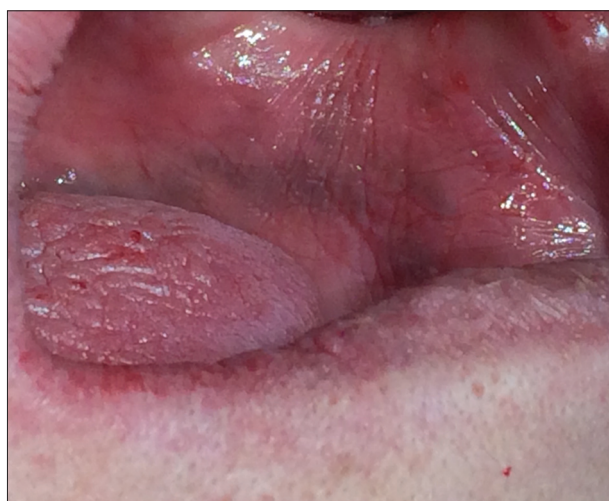

Figure 1. Intraoral manifestations of systemic lupus erythematosus

the maxilla, only two teeth were present (the second molar and canine on the left side); in the mandible, both central and lateral incisors were present, as well as the canine and second premolar on the left side.

Periodontal examination in the maxilla revealed severe bone loss, furcation involvement, and pathological mobility of the second molar, while the canine exhibited pathological mobility (an average probing depth of 6.73 mm), and both were determined as irrational for further treatment. In the mandible, gingivitis was present for an average probing depth of 1.62 mm. Moreover, bleeding on probing was observed in both maxillary teeth, as well as in central and lateral incisors on the right side in the mandible.

After taking into account medical history and intra-oral status, proposed oral rehabilitation with fixed dentures supported by six dental implants in the maxilla and four dental implants in the mandible, as well as prosthetic restoration of the mandibular teeth, was accepted by the patient.

Preoperative treatment

The patient underwent the hygienic phase of periodontal treatment, including extraction of the teeth that were determined as irrational for treatment (maxillary molar and canine) and scaling and polishing of the remaining teeth; root debridement was also done under local anesthesia (the left canine and the right lateral incisor in the mandible). Additionally, chlorhexidine 0.12% solution was prescribed to the patient to rinse twice daily for four weeks. The patient was advised not to wear partial dentures two weeks prior to surgery. After the hygienic phase and a four-week observation period, teeth preparation in the mandible was performed and temporary polymethyl methacrylate crowns were delivered.

On the morning of the surgical procedure, fasting plasma glucose level was determined and the obtained value was 6.9 mmol/L. The patient also confirmed that she regularly took prescribed therapy for autoimmune, metabolic, and cardiovascular disorders.

Surgical procedure

The surgical procedure was performed under local anesthesia. Previous partial dentures were modified and used as a template in order to more precisely transfer prosthetic planning during implant insertion. Midline crestal incision was performed in the maxilla; the mucoperiosteal flap was elevated and six implants (Straumann® Standard Plus, SLA, Basel, Switzerland) were installed according to manufacturer instructions in positions 16, 14, 12, 22, 24 (4.1 mm in diameter; 10 mm in length), and 26 (4.8 mm in diameter; 6 mm in length). In the mandible, in the same manner, four implants (Straumann® Standard Plus, SLA) were placed in positions 46, 45 (4.8 mm in diameter; 6 mm in length), 43 (4.1 mm in diameter; 10 mm in length) and 36 (4.8 mm in diameter; 8 mm in length and 6.5 mm platform). Appropriate healing abutments were positioned

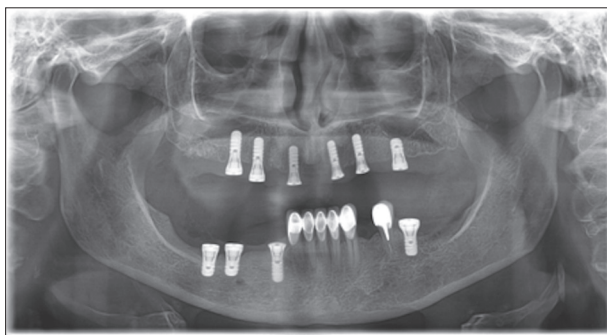


Figure 2. Postoperative panoramic X-ray

and the wounds were closed with monofilament sutures. No complications were observed during the surgery. A control panoramic X-ray was obtained immediately after surgery to ensure adequate implant placement (Figure 2).

Postoperative treatment

The postoperative regimen included antimicrobial therapy with 1 g of penicillin (Panclav, Hemofarm A.D., Vršac, Serbia) with probiotic prophylaxis, twice daily for five days and an antiseptic mouthwash (chlorhexidine 0.12% solution) twice daily for ten days. For postoperative pain control, rescue analgesics (Diclofenac Duo[®], 75 mg, Pharmaswiss, Nové Město, Czech Republic) were advised. The postoperative course proved uneventful and sutures were removed after eight days. A provisional denture was delivered for the upper jaw.

Prosthetic treatment

In the mandible, both central incisors were extracted due to unsuccessful endodontic treatment. Definitive implant-supported fixed denture in the maxilla, and two implant- and one tooth-supported fixed restorations in the mandible were delivered nine months after surgery, following a delayed implant loading protocol. Inter-arch distance was determined precisely, having in mind the TMJ problems that were previously detected. Bilaterally balanced occlusion was obtained during eccentric movements in order to minimize lateral forces.

During the 36-month follow-up period, no major complications occurred (Figure 3). After nine months, ceramic chipping was observed on one tooth, which was repaired during the same visit. Periodontal examination revealed no gingivitis, periodontitis, or periimplantitis. Additionally, the patient reported no subjective symptoms such as a burning sensation or difficulty in eating, and overall improvement and satisfaction with fixed restorations were noticeable.

DISCUSSION

Implant treatment for patients suffering from SLE is not documented to a satisfactory extent in current literature. Moreover, no clear clinical guidelines are available regarding this topic, which can lead to possible mistreatment of

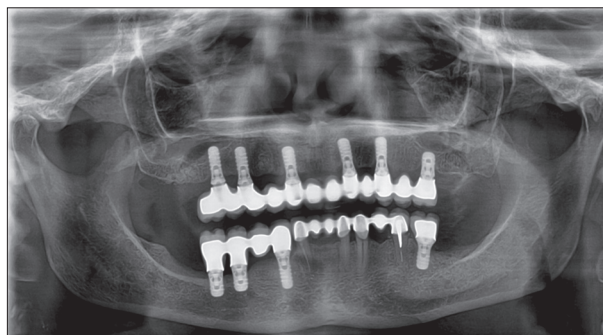


Figure 3. Panoramic X-ray after three years

patients. In this paper, the case of uneventful installation of dental implants and successful prosthetic rehabilitation of a patient with SLE was presented, and specific considerations with which a dentist should be familiar when treating such patients were pointed out.

Pathogenesis of SLE includes deposition of autoimmune antibody complexes in the connective tissue of various organs with subsequent immune response, and almost 90% of those affected are women ranging from young to middle age [8]. The presence of SLE may impair orofacial structures and functions in various ways. Major complaints include xerostomia, burning and tingling of oral mucosa, and painful mucosal lesions [1]. A patient's discomfort is aggravated by mobile dentures that constantly irritate oral mucosa, thus leading to a poorer quality of life. In the presented case, typical bilateral, painful mucosal lesions localized on buccal mucosa were confirmed, with symptoms of xerostomia and sore mouth, as well as the presence of unsatisfactory mobile dentures. Xerostomia, as the most common oral symptom in patients with SLE, is attributed secondarily to Sjogren's syndrome, but this diagnosis was not confirmed from the patient's medical chart [9]. Although the patient reported a subjective feeling of dry mouth, hyposalivation was not confirmed by measuring the resting saliva flow, since the obtained saliva volume was higher than 0.1 ml/minute. In this case, the presence of SLE was accompanied by long-term DMT2, which could also contribute to the aggravation of orofacial symptoms. It is reported that DMT2 by itself, due to underlying neuropathic and microvascular changes in oral tissues, may cause xerostomia, salivary gland dysfunction, periodontal disease, tooth loss, TMJ dysfunction, and burning and tingling of oral mucosa [10–14].

SLE may affect TMJ in up to 60% of patients, with painful and limited mouth opening [15]. The patient reported only slight pain bilaterally during mandibular movement with decreased interincisal distance. The observed condition was most probably due to tooth loss and inadequate interocclusal dimension achieved with previous removable dentures, rather than SLE itself, since mouth opening improved and interincisal distance increased after oral rehabilitation to 26 mm during the follow-up period. Also, the patient reported improvement in chewing, while pain during TMJ movement gradually disappeared.

Frequent systemic complications of SLE include Libman-Sacks endocarditis, which may be present in up to

50% of patients. Deposition of autoimmune complexes in the endothelium of cardiac valves leads to nonbacterial thrombotic endocardial lesions, which may be colonized during transient bacteremia [16]. Therefore, oral surgical treatment of such a patient would require antibiotic prophylaxis. Since there was no endocardial involvement recorded in the patient's medical chart, antibiotic prophylaxis was not performed. However, the usual postoperative antimicrobial regimen was prescribed.

Antiphospholipid syndrome, also known as a lupus anticoagulant syndrome, is an autoimmune prothrombotic disorder with deep venous thrombosis as the most frequent clinical manifestation. SLE is the most common cause of secondary antiphospholipid syndrome, since it affects 30–60% of patients suffering from SLE [17]. Thrombotic tendency in venous, arterial, or microcirculatory vascular beds is a consequence of antibodies binding with the phospholipids in the platelets' membrane, leading to increased activation and aggregation of platelets. The patient was treated daily with 81 mg of Aspirin, since these low doses (up to 100 mg per day) are effective in the prevention of thromboembolic episodes [17, 18]. Adverse bleeding events were not observed intraoperatively or postoperatively, and hemostasis was obtained with usual local hemostatic measures. During outpatient dental surgery, it is not recommended to interrupt low-dose Aspirin therapy in patients at risk of thromboembolic events, since local hemostatic measures are usually effective if intraoperative or postoperative bleeding occurs [19].

Osteopenia and osteoporosis are considered a significant comorbidity of SLE and decreased bone mineral density may be present in up to 67% of women with SLE [20]. Corticosteroid therapy is regarded as one of the major risk factors, but other factors such as early menopause, renal impairment, low levels of vitamin D, lupus duration and older age may also contribute to the risk [21]. In the presented case, where the patient also suffered from osteopenia, SLE was treated with an antimalarial agent, and corticosteroids were not included in regular therapy. Antimalarial therapy is proven to be safe with respect to spine and hip-bone mineral density in female patients with SLE, although there is no data available concerning the impact of antimalarials on jaw bone metabolism [22].

While it is well documented that the presence of DMT2 may lead to altered bone metabolism, it seems that DMT2 does not impair mandibular bone mineral density [23]. In this case, it was not observed that the presence of SLE and the prescribed antimalarial therapy affected the osseointegration of dental implants and soft tissue healing over a 36-month follow-up period. Likewise, no signs of periimplantitis were noticed during functional loading during the same observation period.

Recently, Ergun et al. [24] also reported implant-supported prosthetic rehabilitation of a middle-aged female patient with SLE. The patient's complaints were similar to those experienced by the patient in this case, including xerostomia, sore mouth, and difficult opening of the mouth. However, characteristic mucosal lesions were more pronounced, involving hard palate and lips' mucosa. After the uneventful installation and healing of six implants in the posterior parts of both jaws, fixed implant-supported restorations were delivered. At the end of a 24-month follow-up period, the authors concluded that rehabilitation was successful, with improvements regarding subjective symptoms and limited mouth opening, and proposed that dental implants may be successful and preferred treatment option in patients with SLE. Correspondingly, in the presented case, clinical and radiographic findings revealed that peri-implant bone levels, as well as soft tissue volume remained stable after a 36-month follow-up period.

In conclusion, on the basis of currently limited data, clinicians might consider dental implants as probably the most satisfactory treatment modality when planning prosthetic rehabilitation for patients suffering from SLE. The present report showed an uneventful follow-up period of three years, with only minor dental complications observed (ceramic chipping). Regarding oral manifestations of SLE and imposed challenges in oral rehabilitation, fixed dentures supported by implants or teeth should be the therapeutic goal. SLE is characterized by multiple systemic complications and often accompanied by concomitant chronic diseases, which may affect physical condition to varying degrees, and meticulous assessment of each individual patient is necessary before any procedures are performed. Further clinical trials are warranted, to result in clear guidelines for clinicians regarding implant treatment of patients with SLE.

REFERENCES

- Rhodus NL, Johnson DK. The prevalence of oral manifestations of systemic lupus erythematosus. *Quintessence International*. 1990; 21(6):461–5.
- Louis PJ, Fernandes R. Review of systemic lupus erythematosus. *Oral Surg Oral Med Oral Pathol Oral Radiol Endod*. 2001; 91:512–6.
- De Rossi SS, Glick M. Lupus Erythematosus – considerations for dentistry. *JADA*. 1998; 129:330–9.
- Albilila JB, Lam DK, Clokie CML, Sandor GKB. Systemic Lupus Erythematosus: A Review for Dentists. *JADA*. 2007; 73(9):823–8.
- Mays JW, Sarmadi M, Moutsopoulos NM. Oral manifestations of systemic autoimmune and inflammatory diseases: diagnosis and clinical management. *J Evid Base Dent Pract*. 2012; 12(3 Suppl):265–82.
- Sridevi P, Munisekhar MS, Harika CH, Rama Krishna A. Oral manifestations of autoimmune diseases. *Int J Oral Maxillofacial Pathology*. 2012; 3(4):27–33.
- Speight PM, Kaul A, Melsom RD. Measurement of whole unstimulated salivary flow in the diagnosis of Sjogren's syndrome. *Ann Rheum Dis*. 1992; 51(4):499–502.
- Lourenco SV, de Carvalho FR, Boggio P, Sotto MN, Vilela MA, Rivitti EA, et al. Lupus erythematosus: clinical and histopathological study of oral manifestations and immunohistochemical profile of the inflammatory infiltrate. *J Cutan Pathol*. 2007; 34(7):558–64.
- Andonopoulos AP, Skopouli FN, Dimou GS, Drosos AA. Sjogren's syndrome in systemic lupus erythematosus. *J Rheumatol*. 1990; 17:201–4.
- Newrick PG, Bowman C, Green D, O'Brien IAD, Porter SR, Scully C, et al. Parotid salivary secretion in diabetic autonomic neuropathy. *J Diabetic Compl*. 1991; 5(1):35–7.
- Moore PA, Guggenheimer J, Orchard T. Burning mouth syndrome and peripheral neuropathy in patients with type 1 diabetes mellitus. *J Diabetes Complications*. 2007; 21(6):397–402.

12. Collin H, Niskanen L, Uusitupa M, Töyry J, Collin P, Koivisto A, et al. Oral symptoms and signs in elderly patients with type 2 diabetes mellitus. A focus on diabetich neuropathy. *Oral Surg Oral Med Oral Pathol Oral Radiol Endod.* 2000; 90(3):299–305.
13. Loe H. Periodontal disease. The sixth complication of diabetes mellitus. *Diabetes Care.* 1993; 16:329–34.
14. Arap A, Siqueira SRDT, Silva CB, Teixeira MJ, Siqueira JTT. Trigeminal pain and quantitative sensory testing in painful peripheral diabetic neuropathy. *Arch Oral Biol.* 2010; 55(7):486–93.
15. Aliko A, Ciancaglini R, Alushi A, Tafaj A, Ruci D. Temporomandibular joint involvement in rheumatoid arthritis, systemic lupus erythematosus and systemic sclerosis. *Int J Oral Maxillofac Surg.* 2011; 40(7):704–9.
16. Luce EB, Montgomery MT, Redding SW. The prevalence of cardiac valvular pathosis in patients with systemic lupus erythematosus. *Oral Surg Oral Med Oral Pathol Oral Radiol Endod.* 1990; 70(5):590–2.
17. Yepes JF, Sullivan JA, Castellanos AL, Sollecito TP. Hypercoagulability syndromes: what the dentist needs to know. *Oral Surg Oral Med Oral Pathol Oral Radiol Endod.* 2007; 104(1):3–11.
18. Greaves M. Antiphospholipid syndrome: unusual clinical presentations. *Thromb Res.* 2011; 127(Suppl. 3):S47–50.
19. Aframian DJ, Lalla RV, Peterson DE. Management of dental patients taking common hemostasis-altering medications. *Oral Surg Oral Med Oral Pathol Oral Radiol Endod.* 2007; 103 Suppl:S45.e1–11.
20. Pineau CA, Urowitz MB, Fortin PJ, Ibanez D, Gladman DD. Osteoporosis in systemic lupus erythematosus: factors associated with referral for bone mineral density studies, prevalence of osteoporosis and factors associated with reduced bone density. *Lupus.* 2004; 13(6):436–41.
21. Almedhed K, Forsblad d'Elia H, Kvist G, Ohlsson C, Carlsten H. Prevalence and risk factors of osteoporosis in female SLE patients—extended report. *Rheumatology.* 2007; 46(7):1185–90.
22. Ruiz-Irastorza G, Ramos-Casals M, Brito-Zeron P, Khamashta MA. Clinical efficacy and side effects of antimalarials in systemic lupus erythematosus: a systematic review. *Ann Rheum Dis.* 2008; 69(1):20–8.
23. Ay S, Gursoy UK, Erselcan T, Marakoglu I. Assessment of mandibular bone mineral density in patients with type 2 diabetes mellitus. *Dentomaxillofac Radiol.* 2005; 34(6):327–31.
24. Ergun S, Katz J, Demet Cifter E, Koray M, Esem Artim B, Tanyeri H. Implant-supported oral rehabilitation of a patient with systemic lupus erythematosus: case report and review of the literature. *Quintessence Int.* 2010; 41(10):863–7.

Орална рехабилитација болесника са системским еритематозним лупусом фиксним зубним надокнадама на зубним имплантатима – приказ случаја и преглед значајних сазнања

Владимир С. Тодоровић¹, Марија С. Милић¹, Мирослав Васовић², Живорад Николић³

¹Универзитет у Београду, Стоматолошки факултет, Београд, Србија;

²Универзитет у Крагујевцу, Медицински факултет, Одељење за стоматологију, Крагујевац, Србија;

³Универзитет Привредна академија, Стоматолошки факултет, Панчево, Србија

САЖЕТАК

Увод Системски еритематозни лупус (СЛЕ) јесте хронично аутоимуно обољење са различитим системским и оралним манифестацијама (ксеростомија, болне слузокожне лезије и болно отварање уста, отежано спровођење адекватне оралне хигијене), као и могућим системским компликацијама.

Орална рехабилитација болесника са СЛЕ фиксним зубним надокнадама ношеним зубним имплантатима може представљати најприкладнији вид терапије. Међутим, услед ограничених информација из доступне литературе, као и недостатка терапијских протокола, и данас се у пракси ови болесници неадекватно протетски збрињавају мобилним надокнадама.

Циљ овог рада је био да прикаже болесницу оболелу од СЛЕ која је збринута фиксним зубним надокнадама ношеним зубним имплантатима у обе вилице.

Приказ болесника Жена, 66 година стара, са еволуцијом СЛЕ од 30 година, упућена је на оралну рехабилитацију због проблема са мобилним парцијалним протезама обе вилице и немогућности жвакања. Прихватила је препоручену оралну рехабилитацију са шест деналних имплантата у горњој и четири у доњој вилици. Током периода праћења од три године нису уочене биолошке компликације.

Закључак Терапија зубним имплантатима се може сматрати најбољим терапијским модалитетом у оралној рехабилитацији болесника оболелих од СЛЕ.

Кључне речи: зубни имплантати; орална рехабилитација; системски еритематозни лупус