

CASE REPORT / ПРИКАЗ БОЛЕСНИКА

Thyroid gland metastasis from breast cancer – a rare case report and literature overview

Zorka Inić¹, Aleksandar Martinović¹, Momčilo Inić², Dijana Pilčević¹, Gordana Pupičić¹¹Institute for Oncology and Radiology of Serbia, Belgrade, Serbia;²Medical Center General Hospital, Belgrade, Serbia**SUMMARY**

Introduction The thyroid gland is a rare site for metastatic lesions from non-thyroid cancers. Due to the fact that achieving a diagnosis of thyroid gland metastasis from breast cancer prior to operation is challenging, the diagnosis thereof is mainly based on a pathological biopsy and immunohistochemical staining. The aim of this study was to present a rare case of thyroid gland metastasis from lobular breast cancer.

Case outline The patient was a 33-year-old female who had already had a five-year history of lobular cancer of the right breast and was thereafter found to have two suspicious tumors in the left breast, as well as a thyroid mass diagnosed as metastatic breast carcinoma.

Conclusion Patients who have a thyroid lesion and a history of malignancy are at a higher risk for metastasis and require additional caution during diagnosis and treatment.

Keywords: thyroid metastasis; breast cancer, diagnosis, treatment; histopathological analysis

INTRODUCTION

Although the thyroid gland is richly supplied with blood, the occurrence of a secondary malignancy of the thyroid gland is relatively rare. According to the literature of clinical papers, the incidence of a secondary malignancy of the thyroid gland is low, representing 2–3% of all malignant tumors of the thyroid gland [1]. However, the most common among metastasizing cancers related to this gland are melanoma, as well as kidney, breast, and lung cancer [2].

In autopsy series, the lung is the most common site of primary tumor metastatic to the thyroid, whereas in clinical series, renal cell carcinoma is the most frequent, followed by breast and gastrointestinal neoplasms [3]. According to Nixon et al. [4], the high oxygen and iodine environment may impair the ability of metastatic cells to settle and develop in the thyroid. Additionally, the fast blood flow could make adhesion and implantation of tumor cells difficult.

In this paper, a rare case of breast carcinoma metastatic to the bilateral thyroid lobes is presented. The thyroid metastasis appeared five years after the initial diagnosis of breast carcinoma in the right breast and was confirmed by histopathological analysis. After the surgery, it was also found that the patient had two new lobular breast carcinomas in the left breast. The patient was not found to have any other distant metastases.

breast reconstruction for right breast carcinoma in 2011 at the Institute for Oncology and Radiology of Serbia.

On histopathological examination, it was diagnosed as lobular carcinoma of the breast. The primary tumor was 52 × 22 × 20 mm in size and nine axillary lymph nodes showed a tumor deposit (9/10). Immunohistochemically, the tumor was positive for estrogen receptors (ER) and progesterone receptors (PR). The Ki67 marker was at 50% and negative for HER-2-neu. The patient then underwent adjuvant chemotherapy, endocrine therapy, and radiotherapy, and was followed up on every six months. The disease was asymptomatic for five years. After this time, two tumors in the left breast were found to be suspicious after clinical examination and MRI. Ultrasonography of the neck also showed a suspicious neoplastic lesion in the bilateral thyroid lobes.

According to subsequent testing, while the patient was euthyroid (serum TSH, fT4, and fT3 in the normal range), thyroglobulin level was elevated (98.6 ng/ml; normal: 1.4–78 ng/ml). Serum Ca 15.3 was elevated to a slightly higher level of 32.7 kU/L (normal: 0–25 kU/L). The patient was asymptomatic.

Histopathological examination of the left breast after surgery showed two lobular carcinomas of the breast, (12 × 10 × 9 mm and 18 × 8 × 6 mm in size, respectively) and negative sentinel lymph nodes (0/2). Both tumors also expressed positive receptors for ER, PR and negative ones for HER-2-neu, and had the same Ki67 of 40%. The total thyroidectomy revealed a metastatic lobular carcinoma of the breast in the bilateral thyroid lobes. Nine neck lymph nodes showed a tumor deposit (9/14) after the

CASE REPORT

The patient, a 28-year-old female, underwent a nipple areola-sparing mastectomy and primary



Received • Примљено:
May 4, 2017

Revised • Ревизија:
July 6, 2017

Accepted • Прихваћено:
July 7, 2017

Online first: July 11, 2017

Correspondence to:

Zorka INIĆ
Institute for Oncology and
Radiology of Serbia
Pasterova 14
11000 Belgrade, Serbia
zorkainic@gmail.com

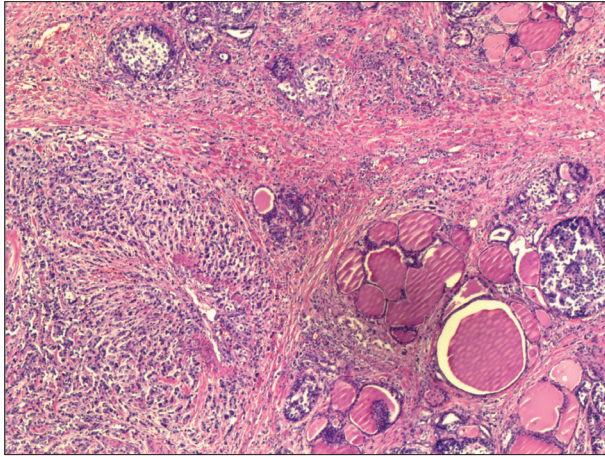


Figure 1. A histological section from the metastatic lesion of the thyroid originating from breast cancer (H&E; ×10)

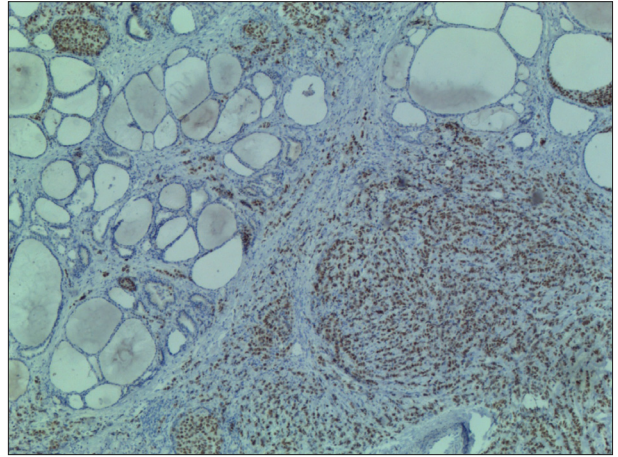


Figure 2. IHC staining for ER in the metastatic lesion of the thyroid originating from breast cancer; a positive reaction was observed in over 75% of the nuclei cells evaluated (×20)

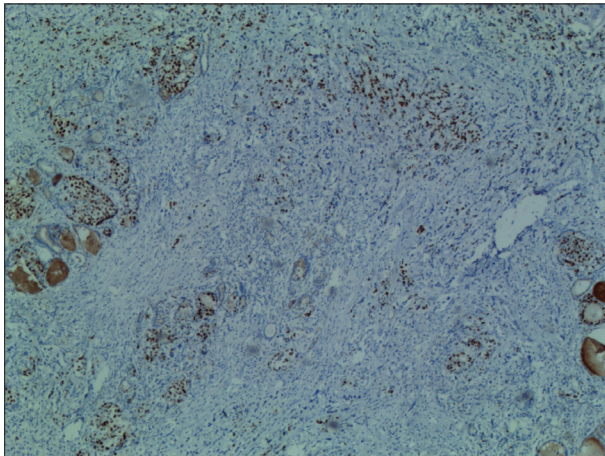


Figure 3. IHC staining for PR in the metastatic lesion of the thyroid originating from breast cancer; a positive reaction was observed in over 75% of the nuclei cells evaluated (×20)

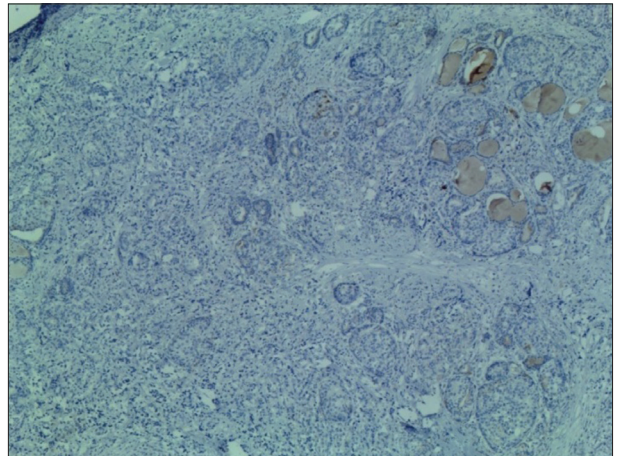


Figure 4. IHC staining for mammaglobin (×20)

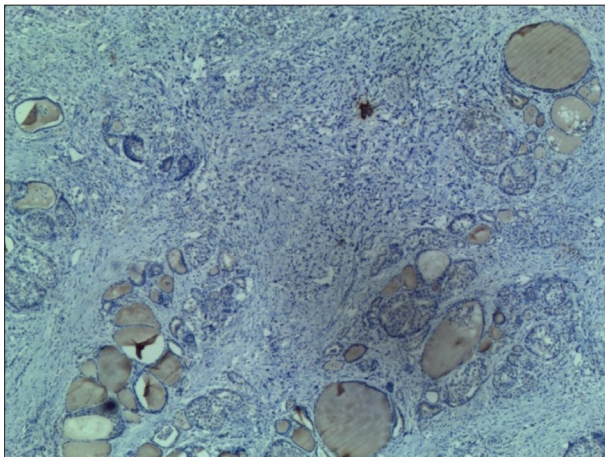


Figure 5. IHC staining for GCDFP-15 (×20)

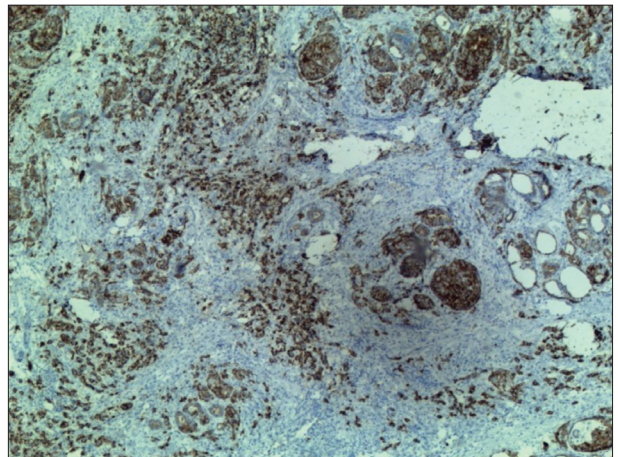


Figure 6. IHC staining for thyroglobulin (×20)

right modified radical neck dissection and extirpation of the lymph nodes in the central region of the neck.

Tumor cells in the metastatic foci (Figure 1) were also positive for ER (Figure 2) and PR (Figure 3), but negative for HER-2-neu. They were, however, positive for mammaglobin (Figure 4), GCDFP-15 (Figure 5), confirming their origin from breast. Furthermore, the metastatic cells were

negative for thyroglobulin (Figure 6), TTF-1 (Figure 7), and CK7; in the surrounding normal thyroid parenchyma, they were all positive, suggesting that neoplastic cells did not originate from the thyroid gland.

After the surgery, testing showed TG and CA 15-3 to be in their normal ranges.

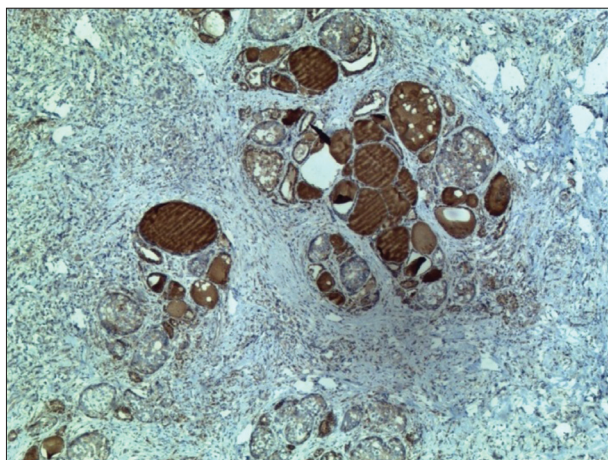


Figure 7. IHC staining for TTF1 (×20)

The metastasis to the thyroid gland occurred five years after the original diagnosis of the primary disease. The thyroid deposits were the only distant metastasis.

DISCUSSION

The thyroid gland is a rare site for metastasis to develop, and an infrequent location for metastatic lesions to appear [5, 6, 7]. Since it is a challenge to diagnose a thyroid gland metastasis in breast cancer prior to the actual operation, the diagnosis itself is mainly based upon a pathological biopsy and immunohistochemical staining.

According to the literature, the involvement of the thyroid generally becomes apparent either simultaneously or anywhere in the range from a few months to 14 years after the original diagnosis of the primary tumor [1, 8–15]. The long interval between the original primary tumor and subsequent thyroid metastases presents a diagnostic problem. In this case, we made the diagnosis five years subsequent to the history of the primary tumor.

Metastatic disease involving the thyroid is generally observed in elderly individuals in their sixth and seventh

decade of life [16]. However, the presently analyzed female patient was only 33 years old. Therein, it may be common for the clinical manifestation of metastatic disease to have no importance, as was in the presented case. In this regard, CA 15-3 and ultrasonography of the neck played a major role in the diagnostic process.

Although thyroid metastases from breast cancer are uncommon, the routine use of fine-needle aspiration may better assist in its more frequent detection due to its ready ability to confirm a clinical suspicion [6, 14]. Total thyroidectomy is recommended for patients with metastatic cancer limited to the thyroid because of the multifocality of metastases to the thyroid gland [17]. Our patient therefore underwent total thyroidectomy and nine neck lymph nodes showed a tumor deposit (9/14).

In the reported case, the diagnosis of metastatic breast carcinoma to the thyroid was confirmed with the help of histopathology and immunohistochemistry. The latter was particularly helpful in differentiating metastatic breast carcinoma from primary thyroid malignancy. Thyroglobulin, TTF1, and CK7 are tumor markers that are positive in thyroid follicular epithelial cells. In the presented case, all of these markers were found to be negative in the tumor cells, but strongly positive in the surrounding normal thyroid parenchyma. Furthermore, the tumor cells tested strongly positive for mammaglobin and GCDPF-15, confirming their origin from a breast lesion [18, 19]. The hormonal status (ER and PR) were found to be positive, and HER-2-neu was negative in the metastatic tumor, similar to the expression pattern of the primary breast carcinoma.

It may be concluded that a patient with a thyroid lesion and a history of malignancy is at a higher risk for metastasis. Such a patient therefore requires additional caution during their diagnosis and treatment. One method of screening is for clinicians to pay specific attention to the elevated CA 15-3 levels after surgery of the primary breast carcinoma. It is also, therefore, advisable to do a fine-needle aspiration, which may help detect metastasis in future cases.

REFERENCES

- Cichoń S, Anielski R, Konturek A, Barczyński M, Cichoń W. Metastases to the thyroid gland: seventeen cases operated on in a single clinical center. *Langenbecks Arch Surg.* 2006; 391(6):581–7.
- Shimaoka K, Sokal JE, Pickren JW. Metastatic neoplasms in the thyroid gland. Pathological and clinical findings. *Cancer.* 1962; 15(3):557–65.
- Nixon IJ, Coca-Pelaz A, Kaleva AI, Triantafyllou A, Angelos P, Owen RP, et al. Metastasis to the thyroid gland: a critical review. *Ann Surg Oncol.* 2017; 24(6):1533–9.
- Nixon IJ, Whitcher M, Glick J, Palmer FL, Shaha AR, Shah JP, et al. Surgical management of metastases to the thyroid gland. *Ann Surg Oncol.* 2011; 18(3):800–4.
- Chen H, Nicol TL, Udelsman R. Clinically significant, isolated metastatic disease to the thyroid gland. *World J Surg.* 1999; 23(2):177–80.
- Willis RA. Metastatic tumours in the thyroid gland. *Am J Pathol.* 1931; 7(3):187–208.
- Yang M, Wang W, Zhang C. Thyroid gland metastasis arising from breast cancer: a case report. *Oncol Lett.* 2013; 5(6):1836–8.
- Gerges AS, Shehata SR, Gouda IA. Metastasis to the thyroid gland: unusual site of metastasis. *J Egypt Natl Canc Inst.* 2006; 18(1):67–72.
- Jiménez-Heffernan JA, Perez F, Hornedo J, Perna C. Massive thyroid tumoral embolism from a breast carcinoma presenting as acute thyroiditis. *Arch Pathol Lab Med.* 2004; 128(7):804–6.
- Tutal E, Tütüncü NB, Akçaer N, Arican A, Bascil N, Güvener N, et al. Unusual case of metastatic thyroid nodule: nonpalpable breast mass as origin. *Endocr Pract.* 2001; 7(5):379–82.
- Leboeuf R, Bénard F, Langlois MF. Thyroid cancer presenting as a PET incidentaloma in a patient with concomitant breast cancer metastases to the thyroid. *Clin Nucl Med.* 2006; 31(7):382–5.
- Loo CK, Burchett IJ. Fine needle aspiration biopsy of neuroendocrine breast carcinoma metastatic to the thyroid. A case report. *Acta Cytol.* 2003; 47(1):83–7.
- Owens CL, Basaria S, Nicol TL. Metastatic breast carcinoma involving the thyroid gland diagnosed by fine-needle aspiration: a case report. *Diagn Cytopathol.* 2005; 33:110–5.

14. Gong Y, Jalali M, Staerckel G. Fine needle aspiration cytology of a thyroid metastasis of metaplastic breast carcinoma: a case report. *Acta Cytol.* 2005; 49(3):327–30.
15. Kim TY, Kim WB, Gong G, Hong SJ, Shong YK. Metastasis to the thyroid diagnosed by fine-needle aspiration biopsy. *Clin Endocrinol (Oxf).* 2005; 62(2):236–41.
16. Yu J, Seethala RR, Walls A, Cai G. Fine-needle aspiration of breast carcinoma metastatic to follicular variant of papillary thyroid carcinoma. *Diagn Cytopathol.* 2009; 37(9):665–6.
17. Calzolari F, Sartori PV, Talarico C, Parmeggiani D, Beretta E, Pezzullo L, et al. Surgical treatment of intrathyroid metastases: preliminary results of a multicentric study. *Anticancer Res.* 2008; 28(5B):2885–8.
18. Mazoujian G, Bodian C, Haagensen DE Jr, Cushman HD. Expression of GCDFP-15 in breast carcinomas. Relationship to pathologic and clinical factors. *Cancer.* 1989; 63(11):2156–61.
19. Wang Z, Spaulding B, Sienko A, Liang Y, Li H, Nielsen G, et al. Mammaglobin, a valuable diagnostic marker for metastatic breast carcinoma. *Int J Clin Exp Pathol.* 2009; 2(4):384–9.

Метастазе карцинома дојке у штитастој жлезди – редак приказ случаја и преглед литературе

Зорка Инић¹, Александар Мартиновић¹, Момчило Инић², Дијана Пилчевић¹, Гордана Пупић¹

¹Институт за онкологију и радиологију Србије, Београд, Србија;

²Општа болница „Медикал центар“, Београд, Србија

САЖЕТАК

Увод Штитаста жлезда је ретко место метастатских лезија из нетироидних карцинома. Постављање дијагнозе метастаза у штитастој жлезди порекла карцинома дојке пре операције је ретко, јер се заснива на патолошкој биопсији и имунохистохемијском бојењу.

Циљ овог рада је да прикаже редак случај метастаза лобуларног карцинома дојке у штитасту жлезду.

Приказ болесника Код жене старе 33 године, која је лечена због лобуларног карцинома десне дојке пет година раније,

утврђено је да има два суспектна тумора у левој дојци, као и у штитастој жлезди, који је дијагностикован као метастаза карцинома дојке.

Закључак Болесници са променом у штитастој жлезди и историјом малигнитета имају већи ризик од метастазе и потребан је додатни опрез током дијагностике и лечења.

Кључне речи: метастазе у штитастој жлезди; карцином дојке, дијагностика, лечење; хистопатолошке анализе