

Techniques of the Tympanomastoidectomy with Reconstruction of the Posterior Bone Wall of the External Auditory Canal

Dragan Dankuc^{1,2}, Ljiljana Vlaški^{1,2}, Nemanja Pejaković^{1,2}

¹University of Novi Sad, Faculty of Medicine, Novi Sad, Serbia;

²ENT Clinic, Clinical Centre of Vojvodina, Novi Sad, Serbia

SUMMARY

A combined tympanoplasty method, the mobile-bridge tympanoplasty, has been applied at the Clinic for Ear, Nose and Throat Diseases in Novi Sad since 1998. Mobile-bridge tympanoplasty is performed at our Clinic by applying Feldmann's procedure utilizing a microsurgical oscillating saw. It is a combination of closed and open techniques for surgical treatment of middle ear diseases. In addition to this technique, a method for reconstruction of the posterior bone wall of the external auditory canal was introduced. This procedure is applied in cases of damage or impairment of the bony ear canal wall using mastoid cortical temporal bone graft or modeled cartilage of the concha. Maintenance of general anatomical relations in the middle ear enables good ventilation of pneumatic spaces of the middle ear and Eustachian tube permeability, thus providing good conditions for ossicular chain reconstruction. The incidence of recurrent cholesteatoma in combined mobile-bridge tympanoplasty and tympanoplasty with reconstruction of the posterior bone wall was 6% in total. The incidence values for the recurrent cholesteatoma in closed tympanoplasty and in cases of open techniques were 10%. Mobile-bridge tympanoplasty and reconstruction of the posterior bone wall of external auditory canal are methods of choice in surgical treatment of middle ear cholesteatoma that progressed to the attic space, sinus tympani and facial recess.

Keywords: cholesteatoma; middle ear; tympanoplasty; ear canal; reconstructive surgical procedures

INTRODUCTION

Tympanoplasty is a surgical method that involves elimination of a pathological process from pneumatic space of the middle ear mostly resulting from a chronic purulent otitis. The aims of tympanoplasty include definitive elimination of the pathological process, reconstruction of a tympanic membrane and transmitting apparatus of the middle ear, hearing improvement and upgrading of overall life quality of the patient.

Chronic purulent inflammation of the middle ear and its adnexa, with or without cholesteatoma, is a severe otological problem, which is due to possible development of exocranial and endocranial complications.

The selection of appropriate surgical procedure for treating a chronic inflammatory process in the middle ear is performed by otosurgeon, depending on the type and extent of the pathological process, anatomic features of the middle ear pneumatic space, available microsurgical equipment and otosurgical skills of the surgeon.

The basic techniques for surgical treatment of chronic inflammatory processes in the middle ear include the closed, i.e. "intact canal wall" or "wall up", and open, i.e. "canal wall down" tympanoplasty methods.

Techniques including reconstruction of the posterior bone wall of the external auditory ca-

nal are a combination of formerly mentioned methods. These procedures involve partial or complete removal of the posterior bone wall of the meatus. Subsequently, after elimination of a pathological process, the reconstruction of the posterior wall of the external auditory canal is performed.

Numerous authors report on various methods of reconstruction of the posterior wall of the external auditory canal and its removal.

In 1959 Schüller and Singer [1] performed the reconstruction by using an autologous iliac crest bone graft, and Wullstein [2] used a homograft septal cartilage in 1961. Mahoney [3] suggested application of methacrylate, whereas Marquet [4] in 1966, as well as Pulec and Reams [5] in 1977 applied a homograft of the tympanic canal. Lapidot [6] in 1968 described a technique applying muscle-periosteum-bone flap. Shea and Gardner [7] in 1970 used femoral head fragments obtained from a bone bank. Aboulker et al. [8] and Marquet [4], as well as Perkins [9] in 1975 performed reconstruction of the posterior wall of the auditory canal by applying an autologous mastoid bone powder.

The new era in reconstruction of the posterior bone wall of the meatus started in 1979 with Wullstein [10], who first applied bio-materials. Diverse materials that have been used, such as porous plastic (Proplast® – Plastiport®, Johns, 1981) [11], ceramics (Ceravital® – hydroxylapatite) used by Gersdorff [12], Lacher [13], Reck

Correspondence to:

Dragan DANKUC
Vase Stajića 32
21000 Novi Sad
Srbija

dragan.dankuc@neobee.net

[14] in 1983 and by Grote and Van Blitterswijk [15] and Magnan et al. [16] in 1984. In 1992 Babighian [17] applied Corail® and ionomer, respectively. Magnan et al. [18] applied Titane® for reconstruction of the posterior bone wall of the external auditory canal in 1995.

The technique of temporary removal of the posterior bone wall of the external auditory canal en block, which is then put back into its anatomic place after elimination of the pathological process in the mastoid and middle ear, was first described by Guilford [19]. Considering the advantages and drawbacks of open and closed technique tympanoplasty many otosurgeons have been applying this method.

Schnee [20] first applied the technique of displacement of the posterior bone wall of the external auditory canal (osteoplastic mastoidectomy) in 1963, 1964 and 1969. Lapidot and Brandow [21], Richards [22] and Lin [23] also applied mobilization and repositioning of the bone canal in 1966, 1972 and 1990, respectively. Temporary removal and subsequent reconstruction of the posterior bone wall of the external auditory canal was applied by numerous authors, such as Gerlach [24] in 1969, Portmann [25] in 1979, Wullstein [26] in 1972, 1973 and 1974, Feldmann [27, 28] in 1977 and 1978, Tange [29] in 1988, Mercke [30] in 1987 and Babighian [31] in 1992.

To the purpose of eliminating the pathological process in the middle ear, tympanoplasty has been applied at the Clinic for Ear, Nose and Throat Diseases in Novi Sad for more than fifty years, i.e. from 1957. This method was introduced at our Clinic by Topolac [32]. The combined method, i.e. mobile-bridge tympanoplasty, has been performed at our Clinic since 1998. This technique was introduced by Dankuc et al. [33]. Introduction of this method resulted from increased incidence of recurrent cholesteatoma after closed technique tympanoplasty procedures with an aim of eliminating the pathological process in the middle ear and preserving the posterior wall of the external auditory canal. Furthermore, in case of posterior bone wall destruction or injury, its reconstruction is performed using autologous mastoid cortical bone graft or using modeled cartilage of the concha, as reported by Dankuc et al. [34-37] and Vlaški et al. [38, 39].

RECONSTRUCTION OF THE POSTERIOR BONE WALL

Our topics in this section are the following:

1. Demonstrating mobile-bridge tympanoplasty surgical technique and reconstruction of the posterior bone wall of the exterior auditory canal in the treatment of chronic middle ear diseases.
2. Identifying the indications and contraindications for the application of mobile-bridge tympanoplasty.
3. Presenting the outcomes of surgical treatment of middle ear cholesteatoma obtained by applying the aforementioned methods and evaluating their advantages and drawbacks in comparison to open and closed technique tympanoplasty.

Tympanoplasty mobile-bridge technique

Tympanoplasty mobile-bridge is performed at our Clinic by applying Feldmann's [27-28] procedure, i.e. osteoplastic meato-attico-antrotomy, using a microsurgical oscillating saw. The main features of this saw are cutting amplitude at continual span of 0-3 mm and saw thickness of 0.25 mm, thus the defects of the resected bone tissue are minimal. Moreover, a specific vibration mode involves minimal risk of surrounding soft tissue damage, such as skin in auditory canal, tympanic membrane or exposed hard brain membrane.

After retroauricular approach, attico-antro-mastoidectomy and preparation of the ear canal skin were performed with subsequent resection of the posterior bone wall of the external auditory canal. By the use of microsurgical saw four slant incisions were made to form V-shaped grooves.

The first incision starts at the anterior border, after performed atticotomy, extending parallel to the tegmen tympani and mastoid tegmen. Some bleeding may occur if the middle fossa dura is exposed due to a contact with the saw, which indicates the necessity of changing the direction of resection.

The second incision starts in the external auditory canal, just superior to the short process of the malleus. The resection extends through the entire lateral attic wall, meeting the first cut at an angle of 80-90°.

The third incision starts in the external auditory canal, running parallel to the course of facial ridge, at the level of the hole made previously through the facial recess. A microsurgical hook, pushed through the hole of recessus facialis from the mastoid side enables reliable control of the medial placement of the saw in relation to the facial nerve.

The fourth incision is made in the mastoid cavity. The saw is positioned in the hole in the facial recess, following the direction of the facial ridge toward the level of the third incision. The mediolateral direction of the fourth incision is exactly the same as that of the third incision, implying no risk of damage to the facial nerve (Figure 1A).

After resection of the posterior bone wall, it is carefully removed from its bed using surgical pincers (Figure 1B).

Subsequent to removing the posterior bony wall of the auditory canal, the pathological process is eliminated from all hardly accessible regions of the middle ear, i.e. medial and anterior attical space, tympanic sinus and facial recess (Figure 1C).

The removed bone wall of the external auditory canal is thoroughly cleansed of cholesteatoma and granulations and preserved in physiological saline until reconstruction.

Reconstruction of the posterior bone wall of the external auditory canal is performed by repositioning the bone bridge into the existent grooves without using any osteosynthetic materials (Figure 1D).

Replacement of the tympanomeatal lobe provides further sustaining and healing of replanted bone. Fascia of the temporal muscle is used as the material for neomembrane transplantation. Reconstruction of the ossicular chain is performed using modeled autologous incus body or applying alloplastic materials, partial ossicular replacement prosthesis and total ossicular replacement prosthesis.

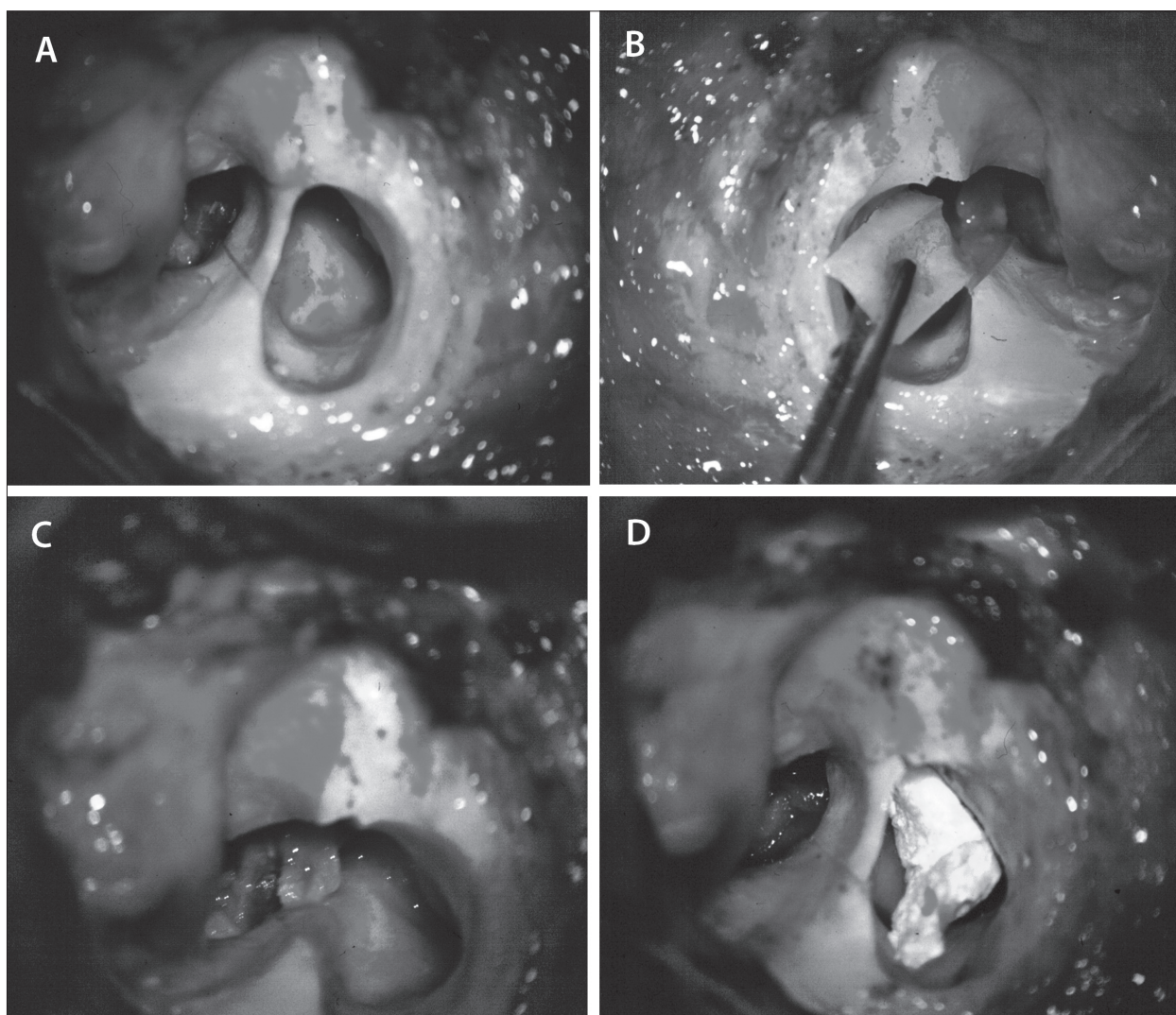


Figure 1. Tympanoplasty “mobile-bridge”: A. Resection of the posterior bone wall; B. Removal of the posterior bone wall; C. Elimination of pathological process; D. Reconstruction of the posterior bone wall

Reconstruction of the posterior bone wall of the external auditory canal

Severe damage of the posterior bone wall of the external auditory canal by an advanced pathological process strongly indicates its complete removal. After elimination of the pathological process from anatomical spaces of the middle ear, its reconstruction is performed using modeled bone transplant prepared from the mastoid cortical bone or using modeled cartilage of the concha.

This method enables excellent approach to the entire attic space and tegmen tympani, as well as to retrotympanum, including the sinus tympani and facial recess (Figure 2A).

Reconstruction of the posterior bone wall of the external auditory canal involves the following:

- Procedure 1 – The size of the posterior bone wall transplant is determined using a sterile material. It is adjusted to the existing height of the tegmen tympani to the level of the bony bridge of the nervus facialis (Figure 2B).
- Procedure 2 – Modeling of the autologous bone graft of the available mastoid cortical bone is performed using a hammer and a chisel (Figure 2C).

- Procedure 3 – The reconstruction of the posterior bony ear canal wall is performed by positioning the modeled bone graft into the existent grooves in the region of tegmen tympani and bony ridge of nervus facialis (Figure 2D).
- Procedure 4 – Transplantation of the tympanic neo-membrane is performed using the temporalis muscle fascia followed by reconstruction of the ossicular chain. Along with the reconstruction of the tympanic membrane applying the temporalis muscle fascia, a free periosteal flap and tympanomeatal skin flaps are used for covering the bone transplant inferolaterally and superolaterally, respectively. This procedure enables proper positioning of the reconstructed posterior bony ear canal wall and provides its further appropriate nourishment.

The technique of reconstruction of the posterior bony ear canal wall is also applicable in cases of previous open technique tympanoplasty, radical or conservative radical temporal bone trepanation, where the opened mastoid cavity is detached from tympanic cavity and closed in relation to the external auditory canal.

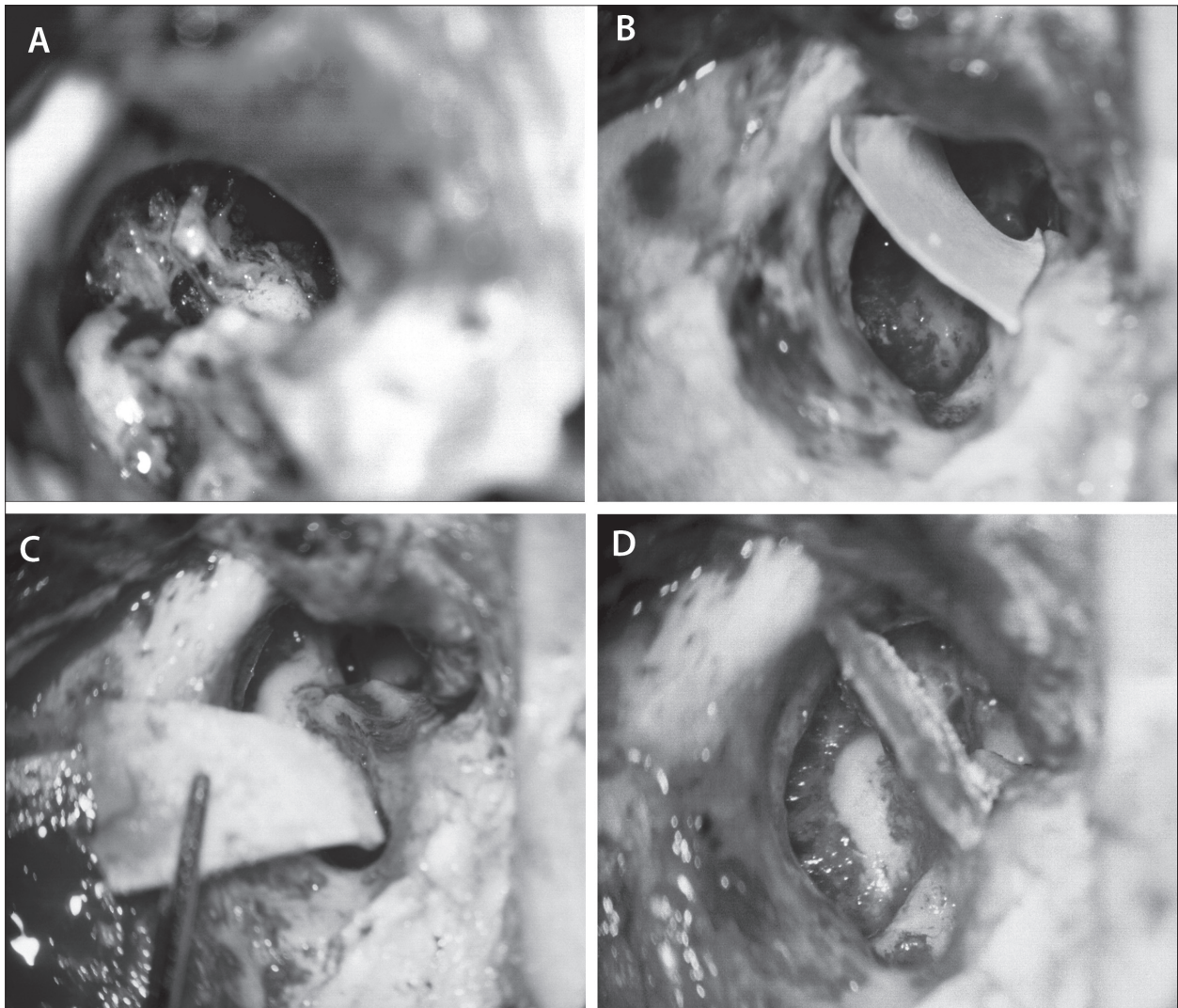


Figure 2. Posterior bone wall reconstruction: A. Posterior bone wall removal; B. Size determination of the posterior bone wall; C. Modeling of the autologous bone graft; D. Replacement of the posterior bone wall

During the postoperative follow-up period the following parameters were monitored: incidence of early and late complications, incidence and time needed for the recurrence of the disease, as well as duration of immediate postoperative care.

Monitoring early postoperative complications included monitoring the condition of the skin of the external auditory canal, condition of the neomembrane and replanted bone of the posterior meatus wall.

Inflammation of the skin of the external auditory canal was observed in one patient, showing tendency for stenosis of the external auditory canal. Neomembrane perforation was also apparent in one patient. Rejection of the replanted bone was observed in the same patient.

During this surgical procedure there was no damage inflicted on the hard brain membrane of the middle cranial fossa nor on the facial nerve.

The period of immediate postoperative care required for neomembrane acceptance ranged averagely between three to four weeks. After this period no particular treatment of the external auditory canal was necessary.

Incidence of residual cholesteatoma in such cases is significantly reduced compared to open and closed technique tympanoplasty. Patients with middle ear cholesteatoma, who underwent various microsurgery procedures, were monitored and evaluated in the period 1998–2014. The incidence of recurrent cholesteatoma in combined mobile-bridge tympanoplasty and tympanoplasty with reconstruction of the posterior bone wall was 6% in total. The incidence values for the recurrent cholesteatoma in closed tympanoplasty and in cases of open techniques were 10%.

The best surgical procedure for treating chronic diseases of the middle ear is still a matter of dispute among otosurgeons, and many of them emphasize the advantages and drawbacks of two basic tympanoplasty techniques, i.e. open and closed technique tympanoplasty.

Closed technique tympanoplasty involves preserving the posterior bony wall of the external auditory canal with attico-antro-mastoidectomy with or without posterior tympanotomy.

The principal disadvantages of this method are the following: (1) difficult elimination of a pathological process,

particularly cholesteatoma, from hardly accessible regions of the middle ear, such as medial and anterior attic, tympanic sinus and facial recess; (2) the epitympanum and mastoid are inaccessible during postoperative inspection and require the “second look” surgery; (3) higher incidence of residual disease, i.e. cholesteatoma; (4) recurrent cholesteatoma may develop from retraction pocket formation; (5) complete eradication of the disease requires multiple surgical procedures.

Rosenfeld et al. [40] conducted a retrospective study of cholesteatoma at pediatric age and tried to identify factors that may contribute to the development of residual and recurrent cholesteatoma. Their report indicated the highest incidence of residual/recurrent disease in the period of the first three years post surgery, reaching the rate of 61% in the sixth year post surgery. The aggressive nature of cholesteatomatous process is more prominent at pediatric age, thus a systematic long-term follow-up and prospective “second look” surgery are strongly recommended.

Dodson et al. [41] from Virginia University, USA, investigated incidence of recurrent cholesteatoma in cases of different tympanoplasty techniques, with an average follow-up period of 37.7 months. Recurrent disease was observed in 41% of patients who underwent “intact canal wall” mastoidectomy, whereas a 12% recurrence rate was observed after “canal wall down” tympanoplasty. The functional postoperative outcomes were satisfactory, showing a hearing level of 30 dB in 75% of the cases that underwent “intact canal wall” mastoidectomy, and in 70% of the cases after “canal wall down” procedure. The authors consider the closed technique tympanoplasty a method of choice for initial eradication of cholesteatomatous process, except where contraindicated by other reasons.

Topolac R. [32] described 905 cases that underwent surgery at the Clinic for Ear, Nose and Throat Disease in Novi Sad in the period 1978–1987. The closed technique tympanoplasty and open technique tympanoplasty were applied in 89.5% and 10.5% of patients, respectively. Complete eradication of pathological process was achieved in 86.6% of cases, whereas hearing improvement was observed in 69.8% of patients after reconstruction of the transmission mechanism of the middle ear applying only auto, i.e. homologous ossicles.

The main advantages of tympanoplasty with preserved posterior wall of the external auditory canal include the following: (1) faster recovery; (2) simple postoperative care procedure that does not require long-term cleansing of the post-operative cavity; (3) ear protection during water exposure is not necessary; (4) preservation of normal anatomical relations in the middle ear provides better conditions for transmitting apparatus reconstruction.

Contrary to the closed technique, the open technique tympanoplasty implicates removal of the posterior bony wall of the external auditory canal to the level or vertical course of the facial nerve and lateral attic wall.

Numerous authors report on significant advantages of this method, which include the following: no absolute anatomical contraindication to its application; it is the most reliable method for disease eradication; higher safety of the

method and better visualization of operative area; lower incidence of residual and recurrent cholesteatoma; easy detection of residual cholesteatoma without the “second-look” surgery; it is applicable in all age categories.

Radulović [42] reports very good results and curing in more than 90% of patients subjected to open technique tympanoplasty during the postoperative follow-up period of two to six years. Recurrent cholesteatoma and perforation of the neomembrane were observed in 6.5% of cases. Moreover, functional outcomes are comparable with results achieved with other tympanoplasty techniques.

Hirsch et al. [43] from Pittsburgh University, USA, who give preference to the open technique tympanoplasty in eradicating cholesteatoma in children, report on incidence of recurrent cholesteatoma during the five-year postoperative follow-up period. The rates of recurrent cholesteatoma were 11% with canal wall down mastoidectomy, 19% with preserved posterior wall of the external auditory canal, 5% with modified radical mastoidectomy and 0% with radical mastoidectomy. The authors also report on better functional outcomes and decreased rate of revision surgeries in canal wall down tympanoplasty.

The principal disadvantages of this method implicate an alteration of anatomical relations in the pneumatic space of the middle ear and the creation of a large, open operative cavity. Postoperative results involve (1) longer curing period; (2) the need for special care and periodical cleansing of postoperative cavity; (3) increased risk of infection; and (4) necessary ear protection during exposure to water.

Advantages and drawbacks of mobile-bridge tympanoplasty

Mobile-bridge tympanoplasty is a combination of closed and open techniques of surgical treatment of middle ear diseases. Temporary removal of the posterior wall of the external auditory canal during surgery results in better visualization of the entire attic space, including tegmen tympani, tympanic sinus and facial recess.

Djerić [44] emphasized the importance of the epitympanic portion of cavum tympani in the field of otosurgery due to frequent localization of cholesteatoma, which progresses from superoposterior regions to mesotympanum.

Postoperative care procedure is similar to that in closed technique tympanoplasty, yet long-term treatment of the external auditory canal is not necessary, and risk of the infection of the operative cavity is minimal.

The principal disadvantages of this technique are the impossibility of postoperative inspection and monitoring of the recurrent disease behind the reconstructed posterior wall of the external auditory canal and intact membrane. In case of suspect recurrent cholesteatoma during the postoperative period, a revision surgery is strongly indicated.

Richards [22] reports on the following complications of the mobile-bridge tympanoplasty performed in 76 patients: transient paralysis of the facial nerve in two cases, bone rejection in two patients and ear canal stenosis in one patient. This tympanoplasty technique was not applicable in two

cases due to large-scale spontaneous erosion of the bony wall of the auditory canal. During postoperative follow-up period of at least 18 months, residual cholesteatoma was observed in one patient, whereas otorrhea and retraction pocket were detected in three and five patients, respectively.

Vase et al. [45] described various methods for the reconstruction of the posterior wall of the meatus in 41 patients. A bone autograft or homograft cartilage was applied for reconstruction, as well as Feldmann's procedure. The recurrent disease was observed in 18% of patients during the postoperative follow-up period of 28 months.

Many authors have described reconstruction of the posterior canal wall and mastoid obliteration using various methods, e.g. Ucar [46] using composite osteoperiosteal flaps, Sudhoff et al. [47] using composite cartilage/titanium grafts, Bagot et al. [48] including ceramic alloplasts, Roberston et al. [49] using bone pate. Gantz et al. [50] described modified canal wall reconstruction tympanomastoidec-tomy with mastoid obliteration.

CONCLUSION

Tympanoplasty with mobile-bridge technique and tympanoplasty with reconstruction of the posterior canal wall proved to be reliable methods for eradication of pathological processes in the middle ear in 94% of cases.

REFERENCES

- Schüller A, Singer M. Mastoid osteoplasty using autogenous cancellous bone: a new procedure. *S Afr Med J*. 1960; 34:645-50. [PMID: 13747642]
- Wullstein HL. Operationen zur Verbesserung des Gehöres. Grundlagen und Methoden. Stuttgart: Thieme; 1968.
- Mahoney JL. Tympanoacryloplasty. A new mastoid obliteration procedure: preliminary report. *Arch Otolaryngol*. 1962; 75:519-23. [DOI: 10.1001/archotol.1962.00740040534007] [PMID: 14468461]
- Marquet J. Ten years of experience in tympanoplasty using homologous implants. *J Laryngol Otol*. 1976; 90(10):897-906. [DOI: 10.1017/S002221510008289X]
- Pulec JL, Reams CL. Reconstruction of radical mastoid cavities: methods and results. *Otolaryngol Clin North Am*. 1977; 10(3):529-40. [PMID: 927841]
- Lapidot A, Mazzarella LA, Afnan J. Constracing a new bony posterior canal wall in elimination of the radical mastoid cavity. Use of pedicled temporal bone-periosteum flap. *Acta Otolaryngol*. 1968; 66(1):113-9. [PMID: 5705459]
- Shea MC, Gardner G. Mastoid obliteration using homograft bone. *Arch Otolaryngol*. 1970; 92(4):358-65. [DOI: 10.1001/archotol.1970.04310040047009] [PMID: 4917080]
- Aboulker P, Demaldet JE, Prache H. Essais de réhabilitation fonctionnelle des évidements totaux. *Ann Otolaryngol Chir Cervicofac*. 1970; 87(1):35-47. [PMID: 5435038]
- Perkins R. Tympanomastoid reconstruction: an operative procedure for anatomical and functional restoration of the radicalized ear. *Laryngoscope*. 1976; 86(3):416-30. [DOI: 10.1288/00005537-197603000-00011] [PMID: 768667]
- Wullstein SR, Schindler K, Dall W. Further observations on application of plasticine in surgery: six years report. *Arch Otolaryngol*. 1979; 223:373-7.
- Johns AN. The use of Proplast in reconstruction of the posterior meatal wall. *J Laryngol Otol*. 1981; 95(9):899-904. [DOI: 10.1017/S0022215100091593] [PMID: 7288273]
- Gersdorff M. Notre expérience des prothèses ossiculaires en Cérovital. *Rev Laryngol Otol Rhinol (Bord)*. 1985; 106(5):329-34. [PMID: 3834549]
- Lacher G. La reconstruction du conduit auditif externe totale et partielle en Cérovital. *Rev Laryngol Otol Rhinol (Bord)*. 1985; 106(5):335-7. [PMID: 3834550]
- Reck R. Bio-active glass-ceramic: a new material in tympanoplasty. *Laryngoscope*. 1983; 93(2):196-9. [DOI: 10.1288/00005537-198302000-00013] [PMID: 6823191]
- Grote JJ, Van Blitterswijk CA. Reconstruction of the posterior auditory canal wall with a Hydroxylapatite prothesis. *Ann Otol Rhinol Laryngol Suppl*. 1986; 123:6-9. [PMID: 3083756]
- Magnan J, Chays A, Gignac D, Bremond G. Reconstruction of posterior canal wall: long-term results. In: Charachon R, Garcia-Ibanez E, editors. Long-term Results and Indications in Otology and Otoneurosurgery. Amsterdam: Kugler Publications; 1991. p.57-61.
- Babighian G. Posterior and attic wall "en bloc" osteoplasty in combined approach tympanoplasty. In: Nakano Y, editor. Cholesteatoma and Mastoid Surgery. Amsterdam: Kugler Publications; 1992. p.649-653.
- Magnan J, Chays A, Pencroff E, Locatelli P, Bruzzo M. Canal wall prosthesis – new devices. *Rev Laryngol Otol Rhinol (Bord)*. 1995; 116(1):19-21. [PMID: 7644841]
- Guilford FR. Obliteration of the cavity and reconstruction of the auditory canal in temporal bone surgery. *Trans Am Acad Ophthalmol Otolaryngol*. 1961; 65:114-22. [PMID: 13709585]
- Schnee IM. Methods and results of tympanoplasty. *J Med Soc N J*. 1969; 66(11):615-8. [PMID: 5259913]
- Lapidot A, Brandow EC. A method for preservation the posterior canal wall and bridge in surgery for cholesteatoma. Preliminary report. *Acta Otolaryngol*. 1966; 62(1):88-92. [DOI: 10.3109/00016486609119553] [PMID: 5967878]
- Richards SH. Tympanoplasty results following the mobile bridge technique. *Trans Am Acad Ophthalmol Otolaryngol*. 1972; 76:153-9. [DOI: 10.1016/S0002-7154(72)30137-7] [PMID: 5024600]
- Lin IF. A new external canal wall-preserving method for antral cholesteatoma surgery – the osteocutaneous flaps. *Gaoxiong Yi Xue Ke Xue Za Zhi*. 1990; 6:149-54. [PMID: 2342157]
- Gerlach H. Die hintere Gehörgangswand bei der Tympanoplastik. *Z Laryngol Rhinol Otol*. 1969; 48(3):214-8. [PMID: 5784887]

25. Portmann M. The Ear and Temporal Bone. New York: Masson; 1979.
26. Wullstein R. Die osteoplastische Epitympanotomie und ihre Resultate. Arch Klin Exp Ohren Nasen Kehlkopfheilkd. 1972; 202(2):655-8. [DOI: 10.1007/BF02413276] [PMID: 4646154]
27. Feldmann H. Osteoplastische Meato-Attiko-Antronomie. Laryngol Rhinol Otol (Stuttg). 1977; 56(9):786-95. [PMID: 143576]
28. Feldmann H. Osteoplastic approach in chronic otitis media by means of a microsurgical reciprocating saw. Clin Otolaryngol Allied Sci. 1978; 3(4):515-20. [DOI: 10.1111/j.1365-2273.1978.tb00744.x] [PMID: 743804]
29. Tange RA. The microsaw and fibrin sealant in middle ear surgery. In: Babighain G, Veldmann J. Transplants and Implants in Otolology. Amsterdam: Kugler; 1988. p.209-211.
30. Mercke U. The cholesteatomatous ear one year after surgery with obliteration technique. Am J Otol. 1987; 8(6):534-6. [PMID: 3434617]
31. Babighian G. Posterior and attic wall osteoplasty in canal wall up tympanoplasty. J Laryngol Otol. 1992; 106:954-9.
32. Topolac R. Cholesteatoma as a surgical problem. Cholesteatoma and Mastoid Surgery. In: Proceedings of the Third International Conference on Cholesteatoma and Mastoid Surgery held in Copenhagen, Denmark. Tos M, Thomsen J, Peitersen E, editors. Amsterdam, Berkeley, Milano: Kugler & Ghedini Publications; 1989. p.849-851.
33. Dankuc D, Vlaški Lj, Komazec Z. Techniques and results of surgical treatment cholesteatoma of middle ear. Med Pregl. 2008; 61(Suppl 2):13-20. [PMID: 18924585]
34. Dankuc D, Milošević D, Savić Lj. Istovremena egzokranijalna i endokranijalna otogena komplikacija. Med Pregl. 2000; 53(7-8):409-12. [PMID: 11214488]
35. Dankuc D, Milošević D, Komazec Z. Otogeni herpes zoster – Ramsay-Huntov sindrom. Med Pregl. 2000; 53(5-6):309-12. [PMID: 11089377]
36. Dankuc D, Pejaković N, Komazec Z, Vlaški Lj. Functional hearing results in patients with otosclerosis before and after stapedotomy. Med Pregl. 2012; 65(1-2):54-8. [DOI: 10.2298/MPNS1202054D] [PMID: 22452241]
37. Dankuc D, Šegan D, Komazec Z, Vlaški Lj, Lemajić Komazec S, Sokolovac I. Cochlear implant surgery at the Clinical center of Vojvodina – ten-year experience. Med Pregl. 2014; 67(Suppl 1):25-31. [DOI: 10.2298/MPNS14S1025D]
38. Vlaški Lj, Milošević D, Dankuc D, Komazec Z. Kongenitalna fistula stapedijusne ploče kao put rekurentnog purulentnog meningitisa. Med Pregl. 2001; 54(3-4):183-6. [PMID: 11759212]
39. Vlaški Lj, Dankuc D, Dragičević D, Lemajić-Komazec S. Otitis media in children – a parallelism between the state-of-the-art knowledge and the context of real clinical practice. Med Pregl. 2008; 61(Suppl 2):7-12. [PMID: 18924584]
40. Rosenfeld RM, Moura RL, Bluestone CD. Predictors of residual-recurrent cholesteatoma in children. Arch Otolaryngol Head Neck Surgery. 1992; 118(4):384-91. [DOI: 10.1001/archotol.1992.01880040042008] [PMID: 1554467]
41. Dodson EE, Hashisaki GT, Hobgood TC, Lambert PR. Intact canal wall mastoidectomy with tympanoplasty for cholesteatoma in children. Laryngoscope. 1998; 108(7):977-83. [DOI: 10.1097/00005537-199807000-00005] [PMID: 9665242]
42. Radulović R. Timpanoplastika: otvorena (wall-down) metoda. Acta Otorhinolaryngologica Serbica. 1994; 1:7-9.
43. Hirsch BE, Kamerer DB, Doshi S. Single-stage management of cholesteatoma. Otolaryngol Head Neck Surg. 1992; 106(4):351-4. [PMID: 1565484]
44. Djerić D. Značaj morfoloških varijacija epitimpaničnog dela kavuma timpani pri timpanoplastici. Acta Otorhinolaryngologica Serbica. 1994; 1:10-5.
45. Vase P, Larsen B, Walter B. Posterior meatal wall reconstruction in tympanoplasty. J Laryngol Otol. 1981; 95(9):893-8. [DOI: 10.1017/S0022215100091581] [PMID: 7288272]
46. Ucar C. Canal wall reconstruction and mastoid obliteration with composite multi-fractured osteoperiosteal flap. Eur Arch Otorhinolaryngol. 2006; 263(12):1082-6. [DOI: 10.1007/s00405-006-0164-1] [PMID: 17006636]
47. Sudhoff H, Brors D, Al-Lawati A, Gimenez E, Dazert S, Hildmann H. Posterior canal wall reconstruction with a composite cartilage/titanium mesh graft in canal wall down tympanoplasty and revision surgery for radical cavities. J Laryngol Otol. 2006; 120(10):832-6. [DOI: 10.1017/S0022215106001927] [PMID: 17038229]
48. Bagot d'Arc M, Daculsi G, Emam N. Biphasic ceramics and fibrin sealant for bone reconstruction in ear surgery. Ann Otol Rhinol Laryngol. 2004; 113(9):711-20. [DOI: 10.1177/000348940411300907] [PMID: 15453528]
49. Roberson JB Jr, Mason TP, Stidham KR. Mastoid obliteration: autogenous cranial bone pate reconstruction. Otol Neurotol. 2003; 24:132-40. [DOI: 10.1097/00129492-200303000-00002] [PMID: 12621322]
50. Gantz BJ, Wilkinson EP, Hansen MR. Canal wall reconstruction tympanomastoidectomy with mastoid obliteration. Laryngoscope. 2005; 115:1734-40. [DOI: 10.1097/01.MLG.0000187572.99335.cc] [PMID: 16222186]

Технике тимпаномастоидектомије с реконструкцијом задњег коштаног зида спољашњег слушног канала

Драган Данкуц^{1,2}, Љиљана Влашки^{1,2}, Немања Пејаковић^{1,2}

¹Универзитет у Новом Саду, Медицински факултет, Нови Сад, Србија;

²Клиника за болести ува, грла и носа, Клинички центар Војводине, Нови Сад, Србија

КРАТАК САДРЖАЈ

Комбинована метода тимпанопластике, тимпанопластика „покретни мост“, примењује се на Клиници за болести ува, грла и носа у Новом Саду од 1998. године. У извођењу ове методе користи се Фелдманов поступак уз примену микрохируршке осцилаторне тестере. Тимпанопластика „покретни мост“ је комбинација затворених и отворених техника хируршког лечења обољења средњег ува. Поред ове технике тимпанопластика, уведена је и метода реконструкције задњег коштаног зида спољашњег слушног канала, и то код његовог оштећења или недостатка, применом коштаног графта начињеног од дела мастоидног кортекса темпоралне кости или хрскавице ушне шкољке. Очувањем анатомских односа средњег ува одржава се добра вентилација пнеуматских простора средњег ува код проходне Еустахијеве тубе,

а самим тим и добри услови за реконструкцију оскуларног ланца. Учесталост резидуалног холестеатома код примењене технике тимпанопластике „покретни мост“ и тимпанопластике с реконструкцијом задњег зида спољашњег слушног канала била је укупно 6%. Код затворених техника тимпанопластика учесталост резидуалног холестеатома била је 10%, као и код отворених техника. Тимпанопластика „покретни мост“ и тимпанопластика с реконструкцијом задњег коштаног зида спољашњег слушног канала јесу методе избора хируршког лечења холестеатома средњег ува који се проширио у предео атика, тимпанични синус и рецесус фацијалног живца.

Кључне речи: холестеатом средњег ува; тимпанопластика; ушни канал; реконструктивне хируршке процедуре