

ORIGINAL ARTICLE / ОРИГИНАЛНИ РАД

The impact of pseudoexfoliation and artificial tear application on the tear film stability in a pseudophakic eye

Dušan Todorović^{1,2}, Tatjana Šarenac-Vulović^{1,2}, Svetlana Jovanović^{1,2}, Mirjana Janičijević-Petrović^{1,2}, Nenad Petrović^{1,2}, Marko Kontić³, Miloš Todorović², Katarina Janičijević⁴, Sunčica Srećković^{1,2}

¹University of Kragujevac, Faculty of Medical Sciences, Department of Ophthalmology, Kragujevac, Serbia;

²Kragujevac Clinical Centre, Clinic of Ophthalmology, Kragujevac, Serbia;

³Military Medical Academy, Eye Clinic, Belgrade, Serbia;

⁴University of Kragujevac, Faculty of Medical Sciences, Department of Social Medicine, Kragujevac, Serbia



SUMMARY

Introduction/Objective Dry eye development after phacoemulsification is a very common complication of cataract surgery. Combined with other risk factors, such as pseudoexfoliation (PEX), this complication becomes more frequent.

The aim of this study was to expose the influence of phacoemulsification associated with PEX on the development of dry eye in patients who underwent cataract surgery.

Methods The study included 160 eyes (160 patients) who underwent phacoemulsification. The patients were divided into four groups (n = 40 patients). Groups I and II involved patients without PEX. The patients from Group II were prescribed artificial tears (AT) postoperatively. The patients from Groups III and IV had a presentation of PEX. The patients from Group IV got AT postoperatively. Ocular Surface Disease Index, the tear breakup time (TBUT) test, fluorescein staining, and Schirmer's test served as "dry eye" tests in this study. The χ^2 test and paired t-test were used for data analysis.

Results Measurements were taken for every patient preoperatively, on the first and the seventh day after the surgery, one month and three months, and one year after the surgery. The tests showed postoperatively developed dry eye in all the groups, with the recovery of the tear film within three months, except for Group III. The highest statistical significance ($p < 0.001$) was recorded between Groups II and III, three and 12 months after the surgery. Values of TBUT (6.09 ± 1.29 seconds) and Schirmer's test (8.91 ± 2.14 mm) in Group III strongly indicated that dry eye was still present one year after phacoemulsification. The greatest recovery of the tear film was recorded in Group II in all the measurements.

Conclusion The study showed how strongly PEX and the use of AT affect the tear film during the first postoperative year. Based on our experience, we highly recommend the use of AT after performing phacoemulsification.

Keywords: phacoemulsification; dry eye; pseudoexfoliation; artificial tears

INTRODUCTION

Cataract surgery is one of the most commonly performed procedures in ocular surgery as well as in surgery in general in the world [1]. The technique of the cataract surgery can have impact on the development of dry eye [2]. The section of the corneal nerves is the basic step of the dry eye occurrence during the cataract surgery. Additionally, exposure to the microscope light deteriorates the dryness of the eye. Ocular surgeons must bear in their minds that the use of topical anesthesia and irrigation fluid during the surgery exacerbates already disturbed ocular surface [3].

Pseudoexfoliation (PEX) is an age-related disorder of the visceral organs, blood vessels, the skin, and the eye [4]. Histopathological verification of PEX in the conjunctival tissue explains its impact on the goblet cells and the function of accessory lacrimal glands [5]. This finding has the influence on the consecution of the dry eye, confirmed by different studies [5, 6].

Symptoms associated with dry eye are pain, irritation, and poor vision [7]. Dry eye symptoms have influence on the quality of life [8].

This study was conducted with the aim to examine the impact of the cataract surgery – phacoemulsification, combined with PEX, on the dry eye development in a one-year follow-up period.

METHODS

The study included 160 eyes scheduled for cataract surgery at the Clinic of Ophthalmology, Kragujevac Clinical Center, Kragujevac, Serbia. It was conducted between January 1, 2015 and January 1, 2016. The most important inclusion criterion was no dry eye diagnosis before the cataract surgery. Patients who used medications that provoke dry eye, such as antihistamines, antidepressants, contraceptive pills, anticholinergic drugs, were excluded from the study. Patients with cataract surgery complications were

Received • Примљено:
July 18, 2017

Revised • Ревизија:
September 4, 2017

Accepted • Прихваћено:
September 6, 2017

Online first: September 22, 2017

Correspondence to:

Tatjana ŠARENAC-VULOVIĆ
Clinic of Ophthalmology
Kragujevac Clinical Center
Zmaj Jovina 30
34000 Kragujevac, Serbia
tvoja.tanja@yahoo.com

also excluded from the study, as were patients with previous history of intraocular surgery, laser treatment, intraocular inflammation, glaucoma, ocular surface diseases, with lid abnormality or pterygium, and contact lens users.

With the approval of the institutional Ethics Committee and according to the tenets of the Declaration of Helsinki, all the patients gave their written consent at the beginning of the study.

The patients who underwent cataract surgery were divided into four groups according to preoperative clinical features (the presence of PEX) and the artificial tear status: the first group (40 patients) involved cataract patients without PEX and with no AT (artificial tears) therapy; the second group comprised patients with prescribed AT and no PEX presentation. The third and the fourth group, respectively, included cataract patients with PEX, without AT therapy (Group III) and with prescribed AT (Group IV).

In the PEX groups, one of the most important inclusion criteria was the presence of characteristic pseudoexfoliative material, but without a diagnosed PEX glaucoma. According to this, complete ophthalmological examination for excluding glaucoma was performed: intraocular pressure measurement, ophthalmoscopy, gonioscopy, corneal thickness measurement, and standard automated perimetry.

Before the surgery, according to the institutional protocol, the patients used topical ciprofloxacin eye drops for five days, five times per day (sol Floxal[®], Dr. Gerhard Mann, Chem.-Pharm. Fabric GmbH, Berlin, Germany).

All the patients underwent cataract surgery – phacoemulsification – performed by one surgeon. The patients were prepared for the surgery by applying the mydriatic eye drops (sol. phenylephrine 2.5%, sol. homatropine 1%; sol. Unotropic[®] 1%, Unimed Pharma S.R.O., Bratislava, Slovakia). After the topical anesthesia was induced with 0.5% tetracaine hydrochloride, phacoemulsification was performed with a 2.75 mm clear corneal incision and with two side ports 1.5 mm wide, 90° away from the main incision. “Stop-and-chop” surgery technique was used for the nucleus removing (Stellaris phaco machine, Bausch & Lomb, Bridgewater, NJ, USA). Phacoemulsification time was no more than 10 minutes. After the capsular bag was cleared, it was filled with cohesive viscoelastic, and foldable monofocal artificial intraocular lens was implanted through the injector system. Viscoelastic was removed by aspiration, and stromal hydration was performed for the ports, with intracameral application of diluted cefuroxime (sol. Nilacef[®], Hemofarm A.D., Vršac, Serbia; 1 mg / 0.1 ml balanced salt solution). Postoperatively, locally Tobradex (Alcon-Couvreur NV, Puurs, Belgium) was applied five times per day for one month.

Patients from two groups (Group II and Group IV) used AT three times per day (sol. Vismed Light[®], TRB Chemedica AG, Feldkirchen, Germany) according to our professional opinion.

Dry eye tests

Ocular Surface Disease Index (OSDI), a 12-item questionnaire, was used to evaluate symptoms associated with dry

eye [9]. We had to modify questions 4 and 5, since it was difficult to differentiate variants of visual acuity due to lens opacity. OSDI score was calculated using a formula, score ranging 0–100. Score above 25 was considered to signify dry eye.

Tear breakup time (TBUT), indicator of the lipid layer of the tear film, was determined by using fluorescein strips (Fluorets[®], Laboratoire Chauvin – Z.I. Ripotier, Aubenas, France) before the other planned intervention (measuring of the intraocular pressure, Schirmer’s test) and before using any ophthalmic drugs. Under the cobalt blue light, we measured time until the appearance of dry spots on the corneal surface. Values of less than 10 seconds indicated dry eye syndrome. Fluorescein staining was done for every patient using fluorescein strips (Fluorets[®]), and it was classified by using the Oxford Schema (grade 0–V) [10]. A score of 0–I indicates a normal eye, and of II–V a dry one.

A local anesthetic (tetracaine 0.5%) was applied before the test. Tear secretion test was done by using Schirmer’s strips (Schirmer Tear Test Strips[®], Optitech, Allahabad, Uttar Pradesh, India), applied in the lateral 1/3 of the inferior fornix. The wet part of the paper was observed for every eye separately. Values shorter than 5 mm indicated a dry eye syndrome.

Complete ophthalmological examination (visual acuity, intraocular pressure measuring, indirect fundus ophthalmoscopy, and detailed slit-lamp examination in mydriasis), including the mentioned tests, was performed for every patient one week before the surgery, one day, one week, one month, three months, and one year after the surgery.

Statistical analysis was done by using IBM SPSS Statistics, Version 22.0 (IBM Corp., Armonk, NY, USA). For comparing the data, the χ^2 test and paired t-test were used ($p < 0.05$ and $p < 0.001$ values were accepted as statistically significant).

RESULTS

Patients’ characteristics

Examined patients had the mean age of 70.24 ± 7.5 years. The age of our patients ranged from 45 to 81 years. In all groups, female to male ratio was equal.

Ocular Surface Disease Index questionnaire results

Preoperatively, by including criteria, all the patients had OSDI score under the limit (< 25 points) (Figure 1). Results indicated that all the patients had OSDI results above the limit on the seventh postoperative day (Group I: 32.48 ± 3.75 ; Group II: 24.13 ± 3.95 ; Group III: 39.46 ± 2.84 ; Group IV: 29.18 ± 3.01), with statistically significant differences between all the examined groups: $p < 0.05$; $p < 0.001$.

One month after the surgery, the patients from Groups I (18.29 ± 3.03) and II (19.43 ± 3.19) showed statistically significant lower scores compared to the patients from Groups III (32.14 ± 3.61) and IV (26.07 ± 3.02), $p < 0.05$; $p < 0.001$.

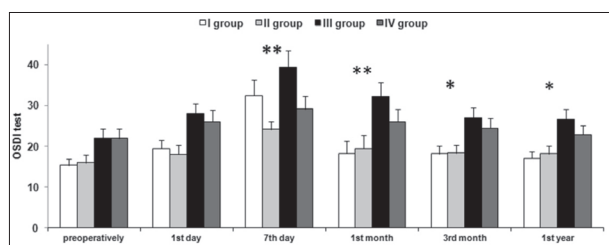


Figure 1. Ocular Surface Disease Index (OSDI) questionnaire results

* $p < 0.05$;
** $p < 0.001$

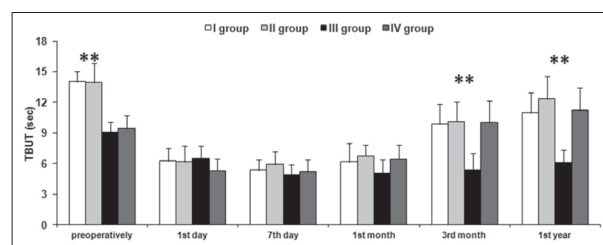


Figure 2. Tear breakup time (TBUT) test results

* $p < 0.05$;
** $p < 0.001$

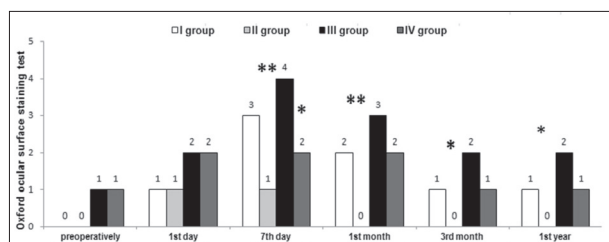


Figure 3. Oxford ocular surface staining test results

* $p < 0.05$;
** $p < 0.001$

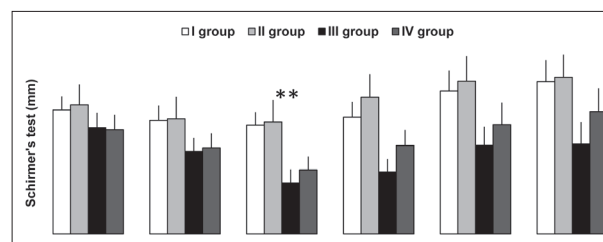


Figure 4. Schirmer's test results

** $p < 0.001$

OSDI questionnaire scores indicated that patients from all the examined groups, except Group III (Group III: 27.04 ± 2.53), had normal values three months after the surgery (Group I: 18.18 ± 2.04 ; Group II: 19.43 ± 2.04 ; Group IV: 24.46 ± 2.48). Results of the third group were statistically significantly higher than the results of the OSDI test of Groups I and II ($p < 0.05$).

Those values remained until one year after the surgery (Group I: 17.08 ± 1.65 ; Group II: 18.18 ± 1.94 ; Group IV: 22.82 ± 2.19). Only Group III patients had OSDI score of 26.64 ± 2.39 one year after the surgery, which was statistically significantly higher compared to patients from Groups I and II ($p < 0.05$).

This comparison indicated that tear film stability was worse in patients with PEX after cataract surgery compared to patients without PEX, regardless of the application of AT.

Tear breakup time test results

Preoperatively, patients with PEX (Group III: 9.08 ± 1.03 seconds; Group IV: 9.46 ± 1.29 seconds) had statistically lower results than patients without PEX (Group I: 14.02 ± 1.02 seconds; Group II: 13.92 ± 1.92 seconds), $p < 0.001$ (Figure 2).

On the first postoperative day, all examined patients (Group I: 6.26 ± 1.27 seconds; Group II: 6.16 ± 1.56 seconds; Group III: 6.48 ± 1.28 seconds; Group IV: 5.31 ± 1.19 seconds) had TBUT values under the limit (< 10 seconds), without statistical differences among the groups ($p > 0.05$).

The lowest values of the TBUT test were detected in all the groups (Group I: 5.38 ± 1.02 seconds; Group II: 5.92 ± 1.27 seconds; Group III: 4.88 ± 1.04 seconds; Group IV: 5.19 ± 1.23 seconds) on the seventh day after the surgery, with no statistically significant differences among the groups ($p > 0.05$).

A similar trend of values was maintained during the first postoperative month (Group I: 6.18 ± 1.78 seconds; Group II: 6.78 ± 1.02 seconds; Group III: 5.05 ± 1.36 seconds; Group IV: 6.46 ± 1.37 seconds), without statistical significances among the examinees ($p > 0.05$).

The recovery of the tear film and its value above 10 seconds was recorded three months after the surgery in patients from Group I (9.87 ± 1.94 seconds), Group II (10.14 ± 1.92 seconds), and Group IV (10.02 ± 2.1 seconds). Those results were highly statistically significantly different compared to patients from Group III (5.42 ± 1.63 seconds), $p < 0.001$.

Until the end of the first postoperative year, all examined patients (Group I: 10.98 ± 2.01 seconds; Group II: 12.35 ± 2.17 seconds; Group IV: 11.22 ± 2.19 seconds) except the patients from Group III (6.09 ± 1.29 seconds), had normal TBUT test results (> 10 seconds). Group III TBUT test result was highly statistically significantly different from other examined groups ($p < 0.001$).

Oxford ocular surface staining tests results

Oxford ocular staining tests results (Figure 3) obtained on the seventh day after the surgery revealed highly statistically significant staining in all the patients except the patients from Group II ($p < 0.001$). One month after the surgery, Group II patients showed no staining, in contrast to all other participants with high statistical significance ($p < 0.001$). After the third month, only patients from Group III showed intensive staining (score of 3), which was statistically significantly different from all other groups ($p < 0.05$). The same results of the Oxford ocular staining tests were obtained one year postoperatively ($p < 0.05$).

Schirmer's test results

The Schirmer's test results (Figure 4) indicated that on the day of surgery, PEX patients (Group III: 10.52 ± 1.34 mm; Group IV: 10.32 ± 1.42 mm) had statistically significantly lower values compared to patients from Group I (12.27 ± 1.48 mm) and Group II (12.78 ± 2.17 mm), $p < 0.05$.

The lowest values of the Schirmer's test, with high statistical significance ($p < 0.001$), were detected on the seventh postoperative day between Group III (5.06 ± 1.32 mm) and Group IV (6.34 ± 1.31 mm) participants compared to Group I (10.78 ± 1.28 mm) and Group II (11.08 ± 2.19 mm).

After one month, patients without PEX (Group I: 11.56 ± 1.52 mm; Group II: 13.52 ± 2.28 mm), had Schirmer's test results above the limit (> 10 mm), with statistically significantly higher values than PEX patients (Group III: 6.14 ± 1.29 mm; Group IV: 8.76 ± 1.53 mm), $p < 0.001$.

After three months, all the participants except Group III patients (6.14 ± 1.84 mm) had normal values of the Schirmer's test, which was statistically significantly lower compared to others (Group I: 14.15 ± 2.01 mm; Group II: 15.12 ± 2.48 mm; Group IV: 10.82 ± 2.18 mm), $p < 0.05$; $p < 0.001$.

After one postoperative year, only Group III patients (8.91 ± 2.14 mm) had abnormal Schirmer's test results, with statistically significantly lower values than other included participants (Group I: 15.02 ± 2.11 mm; Group II: 15.51 ± 2.24 mm; Group IV: 12.12 ± 2.31 mm), $p < 0.05$; $p < 0.001$.

DISCUSSION

Dry eye is a very common consequence of cataract surgery and is a multifactorial disease of the tear film stability and ocular surface. Many reasons provoke dry eye during ocular surgery.

A section of the corneal nerves, making-up the main part and corneal paracentesis, for the surgery, contributes to the defective tear-secreting reflex, so that tear production is out of order [11]. Cornea is innervated by long ciliary nerves, an ophthalmic branch of the fifth cranial nerve. Normal blinking and functional tear reflex, controlled by those nerves, are necessary for the healthy ocular surface [12].

Decreased blinking and reduced tear production can change permeability and metabolic activity of the corneal epithelial cells, by slowing the healing process [13]. Corneal incision provokes releasing of some proinflammatory mediators, which diminishes the tear film stability [14].

Corneal epithelium can be damaged by microscopic light exposure and by intensive irrigation of the ocular surface during surgery [3, 13]. Goblet cells can be disrupted by intensive irrigation – thus the basis for the tear film instability is created [15].

Also, tear film can be disturbed by applied topical anesthesia, containing preservatives (benzalkonium chloride), during surgery [16]. Postoperatively, corticosteroid and antibiotic eye drops are administered, in controlling the

inflammation and the healing process. They also contain preservatives, which disturb the tear film stability by decreasing the mucin producing cells [17].

During the healing process, growth factors are released, with the role to regenerate the subepithelial corneal axon. The process of regeneration is completed approximately within one month. These facts make the explanation for the aggravation of the dry eye symptoms during the first month after cataract surgery [18].

PEX is an age-related disorder of the whole body, characterized by abnormal production and accumulation of abnormal extracellular material in different tissues (the skin, visceral organs, the eye) [4]. In the eye, PEX material can be detected during detailed ophthalmological examination on the slit lamp: on corneal endothelium, pupillary margin, iridocorneal angle, iris, ciliary body, and lens anterior capsule [19]. Histological examination of the conjunctivae and periorbital tissues confirm the presence of PEX material [20]. The accumulation of PEX material in conjunctival tissue influences the accessory lacrimal glands' and goblet cells' function [5]. Some earlier studies indicated instability of the tear film in patients with PEX [21].

This study was conducted to demonstrate the importance of the tear film stability after cataract surgery. Our results from dry eye tests indicated that dry eye symptoms and clinical signs were developed in patients seven days after cataract surgery, especially in PEX patients without postoperatively prescribed AT. This fact is similar to some earlier studies [3, 21, 22]. One month after phacoemulsification, patients without PEX showed better results in all tests except in TBUT. This test shows the condition of the lipid component of the tear film [23]. Its stability was achieved three months after the surgery in this study. These data coincide with data of earlier studies [3, 22, 24]. We noticed that patients without PEX and with postoperatively prescribed AT achieved normal tear film characteristics earlier than patients without postoperatively applied AT. This was also recommended by Yao et al. [24] in their multicentric, randomized, open-label control study. We recorded the importance of dry eye development in patients with PEX after cataract surgery. PEX is a worldwide ophthalmological problem, because of its unknown nature and the problems it provokes in the eye. Earlier studies indicate that dysfunction of the goblet cells and accessory lacrimal glands, provoked by the inflammation of accumulated PEX material, deteriorated the tear film stability [5, 20, 25]. Our results indicated that patients with PEX had poorer results on all dry eye tests than patients without PEX, especially without the postoperative use of AT. Until the end of the study, PEX patients with the postoperative application of AT had statistically significantly better results in all applied tests compared to patients with PEX and without AT. These results were maintained until the end of the study. Comparing these two groups of patients (those with PEX and those without it), we can conclude that patients with PEX had poorer dry eye test results, which became more obvious after cataract surgery. The worsening was noted especially in patients with PEX who did not use AT after the surgery. Earlier studies did not

compare these two groups of patients, which makes these results remarkable [2, 3, 15, 16, 21].

CONCLUSION

According to our results, we concluded that dry eye development is very frequent after cataract surgery, especially in the first three months. PEX and the absence of AT use further deteriorate tear film postoperatively and represent the main reasons for dry eye even one year after phacoemulsification.

Clinical symptoms of dry eye can be the causes of inappropriate visual acuity and the patient's dissatisfaction

after correct cataract surgery. Hence, in conclusion, the use of AT after cataract surgery is recommended for all patients who undergo phacoemulsification, particularly if PEX is presented in the eye that was operated on. We must suggest our patients to be patient and to use AT after cataract surgery, and they can expect improvement of the clinical signs and symptoms approximately three months after the surgery.

ACKNOWLEDGMENT

We would like to thank Jasna Todorović for language revision of the manuscript.

REFERENCES

- Ram J, Gupta A, Brar G, Kaushik S, Gupta A. Outcomes of phacoemulsification in patients with dry eye. *J Cataract Refract Surg.* 2002; 28(8):1386–9.
- Afsharkhamesh N, Movahedan A, Motahari H, Djalilian AR. Cataract surgery in patients with ocular surface disease: an update in clinical diagnosis and treatment. *Saudi J Ophthalmol.* 2014; 28(3):164–7.
- Kasetsuwan N, Satitpitakul V, Changul T, Jariyakosol S. Incidence and pattern of dry eye after cataract surgery. *PLoS One.* 2013; 8(11):e78657.
- Tarkkanen A, Kivela T, John G, Lindberg and the discovery of exfoliation syndrome. *Acta Ophthalmol Scand.* 2002; 80(2):151–4.
- Kozobolis VP, Christodoulakis EV, Naoumidi II, Siganos CS, Detorakis ET, Pallikaris LG. Study of conjunctival goblet cell morphology and tear film stability in pseudoexfoliation syndrome. *Graefes Arch Clin Exp Ophthalmol.* 2004; 242(6):478–83.
- Öncel BA, Pinarci E, Akova YA. Tear osmolality in unilateral pseudoexfoliation syndrome. *Clin Exp Optom.* 2012; 95(5):506–9.
- García-Catalan MR, Jerez-Olivera E, Benitez-Del-Castillo-Sanchez JM. Dry eye and quality of life. *Arch Soc Esp Ophthalmol.* 2009; 84:451–8.
- Mertzanis P, Abetz L, Rajagopalan K, Espindle D, Chalmers R, Snyder C, et al. The relative burden of dry eye in patients' lives: comparisons to a U.S. normative sample. *Invest Ophthalmol Vis Sci.* 2005; 46(1):46–50.
- Schiffman RM, Christianson MD, Jacobsen G, Hirsch JD, Reis BL. Reliability and validity of the Ocular Surface Disease Index. *Arch Ophthalmol.* 2000; 118(5):615–21.
- Yoon KC, Im SK, Kim HG, You IC. Usefulness of double vital staining with 1% fluorescein and 1% lissamine green in patients with dry eye syndrome. *Cornea.* 2011; 30(9):972–6.
- Dartt DA. Neural regulation of lacrimal gland secretory processes: relevance in dry eye diseases. *Prog Retin Eye Res.* 2009; 28(3):155–77.
- Al-Aqaba MA, Fares U, Suleman H, Lowe J, Dua HS. Architecture and distribution of human corneal nerves. *Br J Ophthalmol.* 2010; 94(6):784–9.
- Cho YK, Kim MS. Dry eye after cataract surgery and associated intraoperative risk factors. *Korean J Ophthalmol.* 2009; 23(2):65–73.
- Sánchez MA, Arriola-Villalobos P, Torralbo-Jiménez P, Girón N, de la Heras B, Herrero Vanrell R, et al. The effect of preservative-free HP-Guar on dry eye after phacoemulsification: a flow cytometric study. *Eye (Lond).* 2010; 24(8):1331–7.
- Li XM, Hu L, Hu J, Wang W. Investigation of dry eye disease and analysis of the pathogenic factors in patients after cataract surgery. *Cornea.* 2007; 26(9):16–20.
- Nistor MC, Nistor C. Clinical correlations between dry eye and cataract surgery. *Ophthalmologia.* 2007; 51(4):79–82.
- Ishibashi T, Yokoi N, Kinoshita S. Comparison of the short-term effects on the human corneal surface of topical timolol maleate with and without benzalkonium chloride. *J Glaucoma.* 2003; 12(6):486–90.
- Belmonte C, Acosta MC, Gallar J. Neural basis of sensation in intact and injured corneas. *Exp Eye Res.* 2004; 78(3):513–25.
- Schlötzer-Schrehardt UM, Koca MR, Naumann GO, Volkholz H. Pseudoexfoliation syndrome. Ocular manifestation of a systemic disorder? *Arch Ophthalmol.* 1992; 110(12):1752–6.
- Ringvold A. On the occurrence of pseudo-exfoliation material in extrabulbar tissue from patients with pseudo-exfoliation syndrome of the eye. *Acta Ophthalmol (Copenh).* 1973; 51(3):411–8.
- Akdemir MO, Kirgiz A, Ayar O, Kaldirim H, Mert M, Cabuk KS, et al. The effect of pseudoexfoliation and pseudoexfoliation induced dry eye on central corneal thickness. *Curr Eye Res.* 2016; 41(3):305–10.
- Cetinkaya S, Mestan E, Acir NO, Cetinkaya YF, Dadaci Z, Yener HI. The course of dry eye after phacoemulsification surgery. *BMC Ophthalmol.* 2015; 15:68–73.
- Patel S, Farrell JC. Age-related changes in precorneal tear film stability. *Optom Vis Sci.* 1989; 66(3):175–8.
- Yao K, Bao Y, Ye J, Lu Y, Bi H, Tang X, et al. Efficacy of 1% carboxymethylcellulose sodium for treating dry eye after phacoemulsification: results from a multicenter, open-label, randomized, controlled study. *BMC Ophthalmol.* 2015; 15:28–38.
- Sarenac Vulovic TS, Pavlovic SM, Zdravkovic NS. Proinflammatory Cytokines Induce XFG Development. *Ocul Immune Inflamm.* 2016; 24(6): 671–7.

Утицај псеудоексфолијација и коришћења вештачких суза на стабилност сузног филма у псеудофакном оку

Душан Тодоровић¹, Татјана Шаренац-Вуловић^{1,2}, Светлана Јовановић^{1,2}, Мирјана Јанићијевић-Петровић^{1,2}, Ненад Петровић^{1,2}, Марко Контић³, Милош Тодоровић², Катарина Јанићијевић⁴, Сунчица Срећковић^{1,2}

¹Универзитет у Крагујевцу, Факултет медицинских наука, Катедра за офталмологију, Крагујевац, Србија;

²Клинички центар Крагујевац, Клиника за офталмологију, Крагујевац, Србија;

³Војномедицинска академија, Клиника за очне болести, Београд, Србија;

⁴Универзитет у Крагујевцу, Факултет медицинских наука, Катедра за социјалну медицину, Крагујевац, Србија

САЖЕТАК

Увод/Циљ Развој сувог ока после факоемулзификације је честа компликација операције катаракте. Заједно са другим факторима ризика, као што је псеудоексфолијација (ПЕФ), чини ову компликацију још учесталијом.

Циљ ове студије је био да прикаже утицај факоемулзификације удружене са ПЕФ на настанак сувог ока код оперисаних од катаракте.

Методe Студија је обухватила 160 очију (160 болесника) код којих је извршена операција катаракте. Болесници су подељени у четири групе ($n = 40$). Прва и друга група обухватала је болеснике без ПЕФ. Болесници у другој групи добијали су вештачке сузе постоперативно. Трећу и четврту групу чинили су болесници са ПЕФ. Болесници у четвртој групи добијали су вештачке сузе постоперативно. Индекс обољења предње површине ока, тест бојења флуоресцеином, тест прекида сузног филма и Ширмеров тест коришћени су као тестови индикације сувог ока. За анализу података коришћени су χ^2 тест и упарни т-тест.

Резултати Мерење је вршено код сваког болесника понаособ преоперативно, првог и седмог дана, првог и трећег месеца и годину дана после операције. Тестови су показали постоперативни настанак сувог ока у свим групама, са опоравком сузног филма у оквиру три месеца, изузев у трећој групи. Највећа статистичка значајност забележена је између друге и треће групе, три и дванаест месеци после операције ($p < 0,001$). Вредности теста прекида сузног филма ($6,09 \pm 1,29 s$) и Ширмеровог теста ($8,91 \pm 2,14 mm$) у трећој групи снажно указују на присуство сувог ока и после годину дана од факоемулзификације. Најбољи опоравак сузног филма током свих мерења забележен је у другој групи.

Закључак Студија је показала да изражен ефекат на сузни филм имају ПЕФ и употреба вештачких суза током прве постоперативне године. Према нашем искуству, неопходна је примена вештачких суза после операције катаракте.

Кључне речи: факоемулзификација; суво око; псеудоексфолијација; вештачке сузе