

CASE REPORT / ПРИКАЗ БОЛЕСНИКА

Two-stage forearm brachio-basilic loop arteriovenous graft for hemodialysis

Branislav S. Donfrid¹, Olivera B. Lozančević², Zvezdan B. Stefanović^{1,3}, Aleksandar N. Janković⁴, Nada B. Dimković^{4,5}¹University of Belgrade, Faculty of Dentistry, Belgrade, Serbia;²University of Belgrade, Faculty of Veterinary Medicine, Department of Anatomy, Belgrade, Serbia;³Zvezdara University Medical Center, Clinic for Surgery, Belgrade, Serbia;⁴Zvezdara University Medical Center, Clinical Department for Nephrology, Belgrade, Serbia;⁵University of Belgrade, Faculty of Medicine, Belgrade, Serbia**SUMMARY**

Introduction The autologous radio-cephalic arteriovenous fistula (AVF) is the best vascular access for patients on chronic hemodialysis. In some patients with inadequate blood vessels, it is necessary to create proximal AVF, or arteriovenous grafts. High percentage of primary graft failure is noted in cases where diameters of the brachial artery and the basilic vein are insufficient.

The aim of this work was to introduce a new surgical technique for arteriovenous creation in patients with inadequate blood diameter.

Case outline The authors have proposed implantation of brachio-basilic polytetrafluoroethylene AV forearm loop graft in two acts. In the first act, the native brachio-basilic AVF was created in the distal region of the arm by side-to-end anastomosis. Three to four weeks after the first act, significant dilatation of brachial artery and basilic vein was noted (confirmed by the use of color duplex sonography technique). During the second act, polytetrafluoroethylene graft was implanted by end-to-end anastomosis on the dilated basilica vein.

Conclusion AV graft that was created in two acts has sufficient blood flow without early or late complications. Primary patency was 30 months and secondary patency was 50 months. As an original method in the current literature, we recommend it in different clinical settings when there are no better alternatives for vascular access.

Keywords: arterio-venous fistula; arterio-venous graft; hemodialysis; vascular access

INTRODUCTION

Adequate and functional long-term vascular access is crucial for efficient hemodialysis (HD) [1]. The new era of hemodialysis has begun thanks to the design of the native arteriovenous fistula (AVF) by Brescia et al. [2]. During the 60 years of application, this vascular access has showed the best results and now it is considered the “gold standard.” However, in some patients, native AVF cannot be done due to inadequate anatomical and functional characteristics of blood vessels, damage of the blood vessels due to frequent puncturing, exhaustion of blood vessels due to repeated surgical procedures, aging of the dialysis population, high prevalence of diabetics, mineral metabolism disturbances, pronounced vascular calcifications, etc. [3]. In these patients, the options are proximal AVF, arteriovenous grafts, and tunneled catheters [4].

Good understanding of the anatomy and topography of the vascular system, primarily of the brachial artery (a. brachialis) and the basilic vein (v. basilica) is very important for a good estimation of the possibilities for creating a vascular access for dialysis. In 80% of patients, brachial artery continues to the axillary artery, follows the medial nerve, and in the cubital

area gives two terminal branches – the radial and ulnar arteries [5]. Anatomical variations or deviations of the brachial artery refer to the phenomenon of double brachial arteries (superficial and deep), which occurs in 2–12% of cases [6]. Branching of the superficial brachial artery from the main brachial tree can occur at different levels. In the cubital part, this artery usually extends as radial, while the brachial artery continues to the ulnar artery [7]. At the level of the elbow, basilic vein is located in front of the medial humeral epicondyle, continues along the medial side of the arm, in the initial part just below the skin, and in the proximal part penetrating the deep fascia and stretching along the brachial artery until its confluence. In a situation when native AVF cannot be created, possible solutions are vascular graft and tunneled catheter [8]. Vascular graft has the advantage over tunneled catheter, particularly in the region of the forearm (brachio-basilic „loop graft“) [8].

CASE REPORT

We present a male patient, 23 years old, who was on hemodialysis for nine years due to severe congenital malformations of the urogenital

Received • Примљено:
December 28, 2016

Revised • Ревизија:
May 29, 2017

Accepted • Прихваћено:
May 30, 2017

Online first: July 7, 2017

Correspondence to:

Branislav DONFRID
KBC Zvezdara, D. Tucovića 161
11000 Belgrade, Serbia
branislav.donfrid@gmail.com

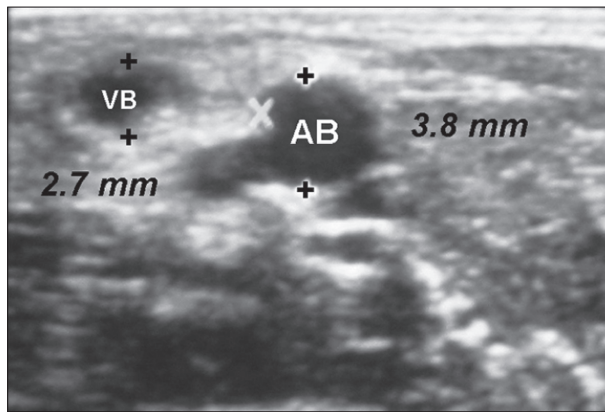


Figure 1. Initial color duplex sonography examination of the diameter of the brachial artery (3.8 mm) and the basilic vein (2.7 mm) in the region of the distal left arm

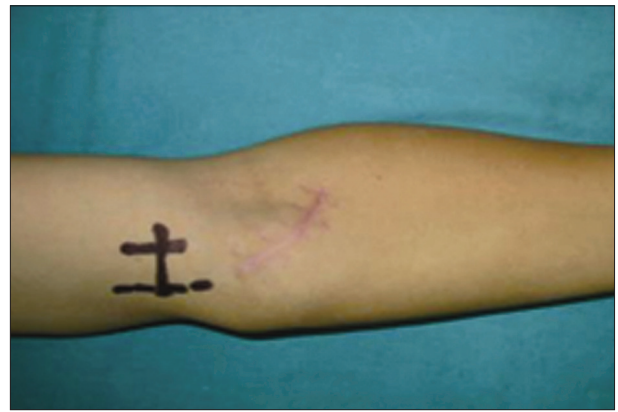

Figure 2. Mapping of the brachial artery and the basilic vein in the distal part of the left arm

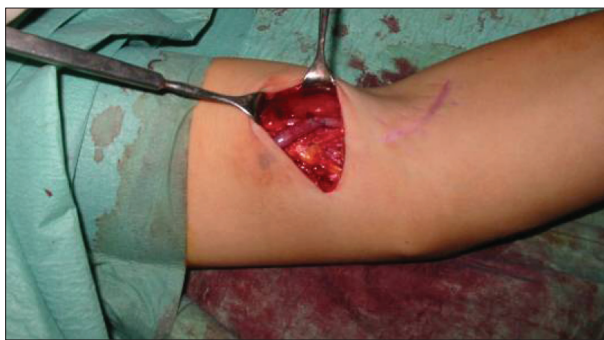

Figure 3. The first act shows latero-terminal anastomosis between the brachial artery and the basilic vein

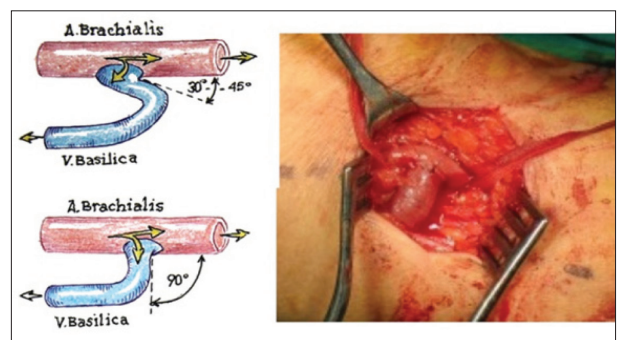


Figure 4. Brachio-basilic anastomosis; the angle of the vein to the artery has to be between 90° and 120°

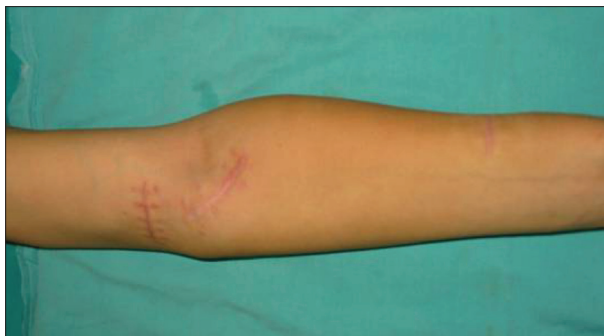

Figure 5. The left arm and forearm four weeks after the surgery – the first act

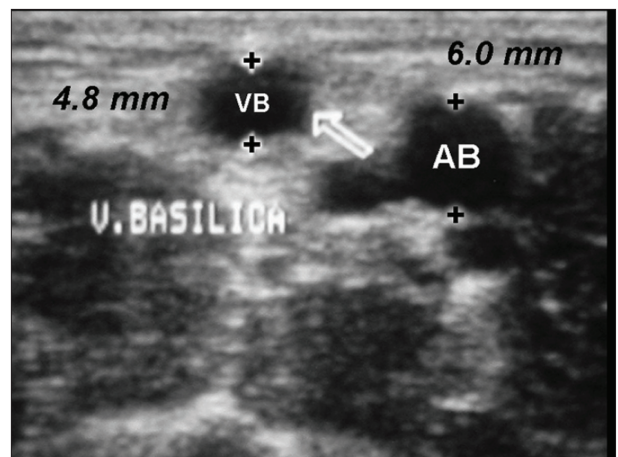


Figure 6. Color duplex examination after four weeks: both the basilic vein and the brachial artery were dilated to 4.8 mm and to 6.0 mm, respectively

tract. Native blood vessels (forearm cephalic vein, cubital vein, arm cephalic vein and radial artery, distal and proximal) on both arms were seriously damaged by repeated attempts to form an AVE. Over the last several months the patient was dialyzed through a central venous catheter in various positions. Color duplex examination was used to measure the diameters of the brachial artery (3.6 mm) and the basilic vein (2.7 mm) in the distal part of the left arm (Figures 1 and 2). In the middle third of the arm, basilic vein joins the deep venous system making it unfeasible for transposition and creation of native brachial-basilic AVE. Due to all of the above, implantation of the polytetrafluorethylene (PTFE) graft in two acts was attempted.

The first act of the procedure was performed under regional anesthesia (axillary block). After cross-section

of the distal third of the arm, side-to-end anastomosis of the brachial artery and the basilic vein was made (Figure 3). During the formation of the anastomosis, it is very important to adjust the angle of the vein to the artery, which has to be between 90° and 120° (Figure 4). Four weeks later, color duplex scan showed that the basilic vein was arterIALIZED (4.8 mm in diameter) and the brachial artery was dilated to 6.0 mm (Figures 5 and 6). These diameters of the blood vessels allowed for the safe graft implantation.

The second act of the procedure was also performed in regional anesthesia, through the scar tissue of the first

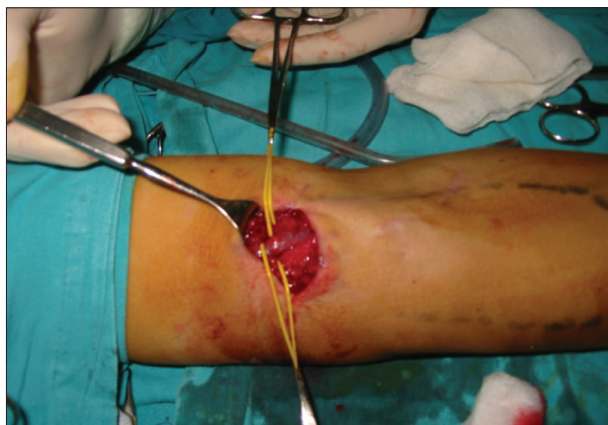

Figure 7. Through the previous scar, the basilic vein was prepared close to the brachial artery without attacks on the brachial artery (four weeks after the first act)

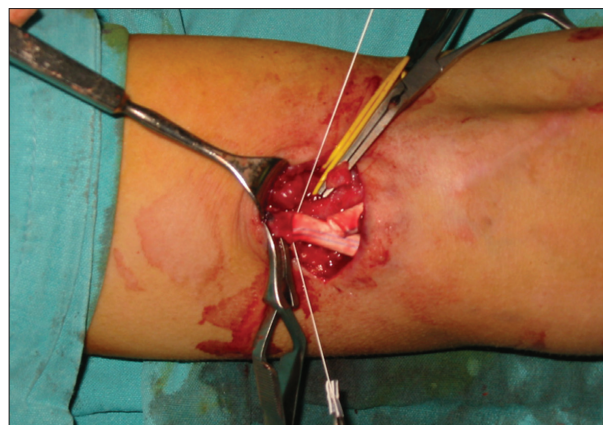

Figure 8. Implanted PTFE 5 mm graft in the loop position in the left forearm with two T-T anastomoses; the suture of the back wall of the basilica vein and the graft

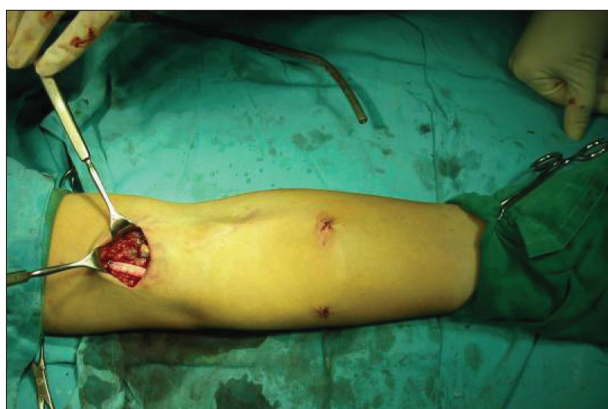

Figure 9. Implanted PTFE 5 mm graft in the loop position in the left forearm

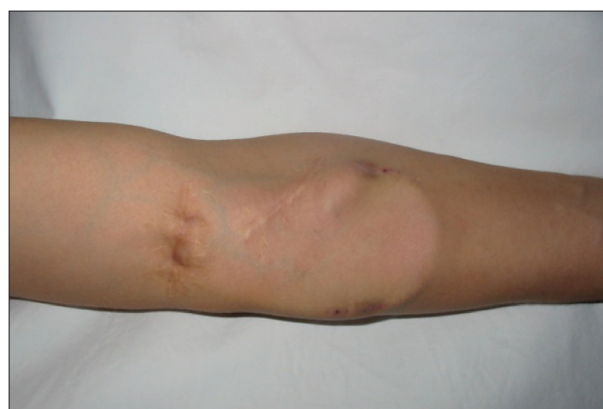

Figure 10. Forearm appearance at the 30th week after the implantation of the graft, which is in good function

surgery. The basilic vein near AVF anastomosis was prepared and a 5 mm e-PTFE vascular graft was placed subcutaneously in the position of the “loop” graft. Using vascular clamps, a cross-cut of the basilic vein was made 2 cm away from the anastomosis with the brachial artery. After instillation of heparin in both ends, the second act was completed by creation of end-to-end anastomosis between vein and graft using Gore-Tex (W. L. Gore & Associates, Inc., Newark, DE, USA) 6-0 suture (Figures 7, 8, 9). From the functional point, arterial anastomosis remained latero-terminal. The graft was ready to be used for hemodialysis after four weeks. Leaving about 2 cm of the basilic vein between the arterial end of the graft and the brachial artery significantly simplifies the process in the second act since the artery remains intact. This is particularly important in case of need for extirpation of the graft due to infection. In that case, the remaining part of the basilic vein is ligated by suture ligature and the infected graft is easily completely removed.

The patient was successfully treated by hemodialysis using the implanted graft over a period of 30 months (primary patency) (Figure 10). The partial replacement of the graft due to pseudoaneurysms at the puncturing places was done and the graft was used for additional 20 months (secondary patency 50 months).

DISCUSSION

Referral to the surgeon and waiting time for vascular access creation are important determinants of the type of vascular access and its usability [9]. According to the Dialysis Outcomes and Practice Patterns Study (DOPPS) V, in most of the DOPPS countries, the frequency of native AVFs is usually less than 80%, ranging from 49% in Canada up to 92% in Russia [10]. By multivariate logistic regression analysis, vein diameter was the sole independent predictor of functional fistula maturation [11].

Transposition of the basilic vein for arteriovenous fistula is the last possibility for the creation of vascular access native vessels in the upper extremity. It is important to have the basilic vein of sufficient length in order to obtain a sufficient conduit for the two-needle butting and to avoid recirculation.

In 66% of cases, the basilic vein can be used for the formation of native AVF after vein transposition and superficialization. However, in 34% of cases the basilic vein is short and cannot be used for native AVF [12]. In that case, superficialization on a deep brachial vein is possible, but the primary and secondary flow of such vascular access is insufficient. In addition, an aneurysm at the puncture site for hemodialysis, axillary vein thrombosis, “steal syndrome,” and other complications are frequent [13].

It is well known that implantation of the vascular graft requires appropriate diameter and quality of arterial and venous blood vessels, which may be a major obstacle for this type of surgery [14]. Literature data about graft implantation vary from center to center and it is not surprising that average primary and secondary patency after six months were found to be 58% and 76%, respectively [15].

In cases of inadequate blood vessels when there is no possibility of creating vascular access native vessels, we suggest arteriovenous graft implantation in two acts. Such operation should take place before the decision to create a vascular access of the lower extremities. Primary and secondary patency of this graft is excellent.

REFERENCES

- Ng YY, Wu SC, Hung YN, Ko PJ. Effect of demographic characteristics and timing of vascular access maturation on patency in Chinese incident haemodialysis patients. *Nephrol Dial Transplant*. 2009; 24(11):3447–53.
- Brescia MJ, Cimino JE, Appel K, Hurwicz BJ. Chronic hemodialysis using venepuncture and a surgically created arteriovenous fistula. *N Engl J Med*. 1966; 275:1089–92.
- Hammes M. Hemodynamic and biologic determinates of arteriovenous fistula outcomes in renal failure patients. *Biomed Res Int*. 2015; 2015:171674.
- Vascular Access 2006 Work Group. Clinical practice guidelines for vascular access. *Am J Kidney Dis*. 2006; 48(Suppl 1):176–247.
- Shenoy S. Surgical anatomy of upper arm: what is needed for AVF planning. *J Vasc Access*. 2009; 10(4):223–32.
- Krstonosic B, Srdic B, Maric D, Gudovic R, Mijatov S, Babovic S. An anatomical study of double brachial arteries – a case report. *International Journal of Anatomical Variations*. 2010; 3:6–8.
- Anaya-Ayala JE, Younes HK, Kaiser CL, Syed O, Ismail N, Naoum JJ, et al. Prevalence of variant brachial-basilic vein anatomy and implications for vascular access planning. *J Vasc Surg*. 2011; 53(3):720–4.
- Tordoir J, van Loon MM, ter Meer M, van Laanen J, Bode AS, Weijmer MC, et al. Hemodialysis vascular access management in the Netherlands. *J Vasc Access*. 2015; 16(Suppl. 9):S11–5.
- Schild AF, Gillaspie E, Perez E. When an AVF isn't possible for HD, AV grafts are the preferred access. *J Vasc Access*. 2007; 8(3):140–1.
- Pisoni RL, Zepel L, Port FK, Robinson BM. Trends in US vascular access use, patient preferences, and related practices: An update from the US DOPPS Practice Monitor with international comparisons. *Am J Kidney Dis*. 2015; 65(6):905–15.
- Lazarides MK, Georgiadis GS, Antoniou GA, Stamos DN. A meta-analysis of dialysis access outcome in elderly patients. *J Vasc Surg*. 2007; 45(2):420–6.
- Pach AR. A two-staged technique for basilic vein transposition. *J Vasc Access*. 2007; 8(4):225–7.
- Al Shakarchi J, Stolba J, Houston JG, Inston N. Surgical techniques for haemodialysis access-induced distal ischaemia. *J Vasc Access*. 2016; 17(1):40–6.
- Lauvao LS, Ihnat DM, Goshima KR, Gruessner AC, Mills JL Sr. Vein diameter is the major predictor of fistula maturation. *J Vasc Surg*. 2009; 49(6):1449–504.
- Goldin ShD, Verstandig I, Berelowitz D, Zagal I, Olsha O. Upper limb grafts for hemodialysis access. *J Vasc Access*. 2015; 16(Suppl. 9):S34–9.

Instead of conclusion, this case report demonstrates the successful creation of a vascular graft in a two time-separated acts in patients where it was not possible to create other vascular accesses (native AVF, standard graft). This technique has excellent early results, the same as the primary implanted grafts on good blood vessels. We recommend it for patients with previously exhausted vascular accesses, as well as for patients with pronounced and long-lasting hypotension (regardless of the quality of the blood vessels), diabetics, and the elderly who have advanced atherosclerosis. Since this method is not described in the available literature, we consider it an original contribution named “forearm brachio-basilic arteriovenous grafts in two acts – Zvezdara method.”

Подлакратни брахио-базилнични артериовенски графт за хемодијализу у два акта

Бранислав С. Донфрид¹, Оливера Б. Лозанче², Звездан Б. Стефановић^{1,3}, Александар Н. Јанковић⁴, Нада Б. Димковић^{4,5}

¹Универзитет у Београду, Стоматолошки факултет, Београд, Србија;

²Универзитет у Београду, Факултет ветеринарске медицине, Катедра за анатомију, Београд, Србија;

³Клиничко-болнички центар „Звездара“, Хируршка клиника, Београд, Србија;

⁴Клиничко-болнички центар „Звездара“, Клиничко одељење за нефрологију и метаболичке поремећаје са центром за дијализе, Професор др Василије Јовановић, Београд, Србија;

⁵Универзитет у Београду, Медицински факултет, Београд, Србија

САЖЕТАК

Увод Аутологна радиоцефалична артериовенска фистула је најбољи васкуларни приступ за болеснике на хемодијализи. Код неких болесника са неадекватним крвним судовима потребно је креирати проксималну артериовенску фистулу или имплантирати артериовенски графт. Високи проценат раног затајивања графта најчешће настаје услед малог пречника базилничне вене или брахијалне артерије.

Циљ овога рада је био да прикаже нову хируршку технику за креирање артериовенског графта код болесника са неодговарајућим дијаметром крвних судова.

Приказ болесника Урађена је имплантација PTFE графта у виду петље на подлактици у два акта. У првом акту је у дисталном делу надлактице креирана брахио-базилнична

латеро-терминална артериовенска фистула под углом од 90 степени. После четири недеље, контролном доплерсонографијом је констатовано знатно повећање пречника базилничне вене и брахијалне артерије. У другом акту је базилнична вена попречно пресечена и са две темино-терминалне анастомозе у виду петље уметнут PTFE графт.

Закључак Овако креиран артериовенски графт у два акта давао је задовољавајући проток крви без компликација. Примарна функционалност је износила 30 месеци, а секундарна 50 месеци. У доступној литератури овакав поступак није објављен, а препоручујемо га код болесника без других могућности за креирање васкуларног приступа.

Кључне речи: артериовенска фистула; артериовенски графт; васкуларни приступ; хемодијализа