

## ORIGINAL ARTICLE / ОРИГИНАЛНИ РАД

# Sensitivity and specificity of D-dimer tests compared to ultrasound examination of deep vein thrombosis

Dragan Marković<sup>1,2</sup>, Dragan Vasić<sup>1,2</sup>, Jelena Bašić<sup>3</sup>, Slobodan Tanasković<sup>1,4</sup>, Slobodan Cvetković<sup>1,2</sup>, Zoran Rancić<sup>5,6</sup>

<sup>1</sup>University of Belgrade, Faculty of Medicine, Belgrade, Serbia;

<sup>2</sup>Clinical Centre of Serbia, Clinic for Vascular and Endovascular surgery, Belgrade, Serbia;

<sup>3</sup>Rudolfstiftung, Department of Cardiology, Vienna, Austria;

<sup>4</sup>Dedinje Cardiovascular Institute, Vascular Surgery Clinic, Belgrade, Serbia;

<sup>5</sup>University Hospital Zurich, Department of Cardiovascular Surgery, Zurich, Switzerland;

<sup>6</sup>University of Zurich, Faculty of Medicine, Zurich, Switzerland



## SUMMARY

**Introduction/Objective** Untreated deep vein thrombosis (DVT) is associated with a high risk of pulmonary embolism (PE), and false diagnosis of DVT results in unnecessary anticoagulant therapy, with a risk of bleeding. Accurate diagnosis of DVT and prompt therapy are essential to reduce the risk of thromboembolic complications.

The aim of our study was to evaluate the sensitivity and specificity of three D-dimer tests (DD PLUS, HemosIL, and VIDAS) comparing to compression ultrasonography (CUS) examination.

**Methods** We observed 350 patients, some with different risk factors. The patients underwent the same protocol (evaluation of the patient's history, physical examination, and D-dimer testing), and CUS was used as a reference for all the patients. According to Wells score, the patients were divided into groups with low, moderate, and high pretest probability (PTP).

**Results** Most of the examined patients were with moderate PTP. The CUS showed that there was the highest number of examined patients without DVT. Most of the examined patients with a positive CUS finding had proximal iliac and femoral DVT.

VIDAS test was positive in the highest percentage in the group of patients with CUS-documented thrombosis.

**Conclusion** All three D-dimer tests used in our study had similar sensitivity and specificity. However, VIDAS test had higher levels of positive and negative predictive values comparing to the others. The comparison of three D-dimer tests by an ROC curve showed that VIDAS test has the highest overall statistical accuracy of all three D-dimer tests.

**Keywords:** D-dimer test; compression ultrasonography; deep vein thrombosis

## INTRODUCTION

Venous thromboembolism (VTE) is a common disorder associated with significant morbidity and mortality, with annual incidence in developed countries of 1 in 1,000 [1].

That might be a problem, because untreated deep vein thrombosis (DVT) is associated with a high risk of pulmonary embolism (PE), and false diagnosis of DVT results in unnecessary anticoagulant therapy, with a risk of bleeding. Accurate diagnosis of DVT and prompt therapy are essential to reduce the risk of thromboembolic complications. DVT also predisposes patients to post-thrombotic or post-phlebotic syndrome in 40–75% of cases. Between 90% and 95% of PEs arises from lower extremity DVT [2, 3].

In the past, contrast venography has been the gold standard for the diagnosis of DVT, but nowadays it has been replaced in most centers by color duplex ultrasonography. Venography is invasive and is associated with a small but significant risk of complications [4].

The recommended protocol for the diagnosis of DVT consists of the following: 1) Wells score used for diagnosing DVT [5]; 2) D-dimer assay for DVT; and 3) compression ultrasonography (CUS).

Careful history has to be taken considering risk factors. Physical examination is inadequate for establishing the diagnosis of VTE. In recent years, use of D-dimer tests has been increased since the testing is quick and non-invasive [6, 7].

The fragments of the disintegrating fibrin in the clot are fibrin degradation products. One of the fibrin degradation products produced is D-dimer, which consists of variously sized pieces of cross-linked fibrin. D-dimer levels in the blood are normally very low and concentrations are raised by thrombolysis. D-dimer tests generally have a high negative predictive value and should not be used in isolation as screening tests. Therefore, they are often used in conjunction with clinical probability scoring or CUS to reduce the need for further imaging.

There are four types of D-dimer assays commercially available: enzyme-linked im-

**Received • Примљено:**

February 22, 2018

**Revised • Ревизија:**

April 16, 2018

**Accepted • Прихваћено:**

April 18, 2018

**Online first:** April 25, 2018

**Correspondence to:**

Dragan VASIĆ  
Clinic for Vascular and  
endovascular Surgery  
Clinical Centre of Serbia  
Koste Todorovića 8  
11000 Belgrade, Serbia  
[dr\\_dragan\\_vasic@yahoo.com](mailto:dr_dragan_vasic@yahoo.com)

munosorbent assay (ELISA), latex agglutination assay, whole-blood agglutination assay (SimpliRED) and immunochromatographic test (Simplify). Many quantitative latex agglutination and ELISA tests are available and the conventional ELISA is considered the gold standard for determination of D-dimer concentration.

CUS, due to its high sensitivity, specificity, and reproducibility, has replaced venography as the most widely used test in the evaluation of this disease. In symptomatic patients, CUS has shown to be highly specific and sensitive for both proximal and distal DVT. The sensitivity has ranged 90–100% for the diagnosis of symptomatic DVT. The specificity has ranged 95–100%. In high-risk asymptomatic patients, its sensitivity ranges 50–80% and specificity ranges 95–100%. The safety, availability, and well-documented accuracy of this technique justify its widespread use [8, 9].

D-dimer tests should not be used as stand-alone tests, nor are they useful in situations of concurrent anticoagulant use, malignancies, post-surgery, pregnancy, or severe infections. Problems can also occur due to the fact that 30% of patients with PE will have normal D-dimer.

The aim of our study was to evaluate the sensitivity and specificity of three D-dimer tests (DD PLUS, HemosIL, and VIDAS), comparing to CUS examination.

## METHODS

This study has been performed over the June 2016 – October 2017 period at the Clinic for vascular and endovascular surgery, Clinical Centre of Serbia.

All the patients underwent the same protocol consisting of patient's history evaluation and physical examination, as well as D-dimer testing as a second step. Finally, CUS of the symptomatic leg was used as a reference test in all the patients.

Physicians at the Vascular Department filled in a questionnaire (modified Wells score) comprising details of history (risk factors) and physical examination (clinical signs). Pretest probability score models for predicting the probability of DVT, based on history and examination, were used in order to help clinicians improve the accuracy of diagnosis of DVT (Table 1).

According to Wells score, all the patients were divided into three groups: patients with a score of 0 or less had low pretest probability, patients with a score of 1 or 2 were considered moderate, and patients with a score that of 3 or more were with high pretest probability [5].

Three D-dimer assays were used: DD PLUS – a latex-enhanced immunoturbidimetric assay (Dade-Behring, Marburg, Germany) on the BCT analyzer, HemosIL – a latex-enhanced immunoassay (Instrumentation Laboratory, Milan, Italy) on the ACLTM 7000 analyzer, and VIDAS (ELISA) DD Exclusion (DD2) (bioMérieux, Marcy L'Étoile, France) on the VIDAS analyzer. D-dimer tests were performed within one hour of admission to the vascular ambulance.

**Table 1.** Pretest probability scale for deep vein thrombosis used in this study

Risk factors	Score
Active cancer: curative or palliative treatment initiated within 6 months	2
Prior history of idiopathic VTE or known primary thrombophilia	2
Paralysis, paresis, plaster immobilization within 12 weeks	1
Bedridden $\geq$ 3 days or major surgery within 12 weeks	1
Clinical signs	Score
Entire symptomatic leg swollen (the asymptomatic leg is not swollen)	2
Calf swelling $>$ 3 cm compared to the asymptomatic leg	1
Pitting edema, greater in the symptomatic leg	1
Alternative diagnosis (usually muscle pain or venous insufficiency)	-2
- Tenderness or Homan's sign is nonspecific and receives no points	
- High probability $\geq$ 3, Moderate probability 1–2, Low probability $\leq$ 0	

A D-dimer test was considered positive if the values were  $>$  149–196  $\mu\text{g/L}$  for DD PLUS,  $>$  268  $\mu\text{g/L}$  for HemosIL, and  $>$  650–676  $\mu\text{g/L}$  for VIDAS test.

CUS of the veins of the symptomatic leg was used as the reference test in all the patients. All examinations were performed on a single Acuson Antares ultrasound machine (Siemens, Munich, Germany), using a linear array 7 MHz scan head (7540) with standardized image settings, including resolution mode, depth of field, gain, and transmit focus. CUS examinations were made according to a standardized protocol and report form, performed within three hours of admission to the vascular ambulance. The patients were classified as DVT-positive if they had DVT confirmed with CUS, or as DVT-negative if they had no CUS-confirmed DVT. Patients with unclear CUS findings were excluded from the data analysis. The results of the D-dimer assay were unknown to the ultrasonographer.

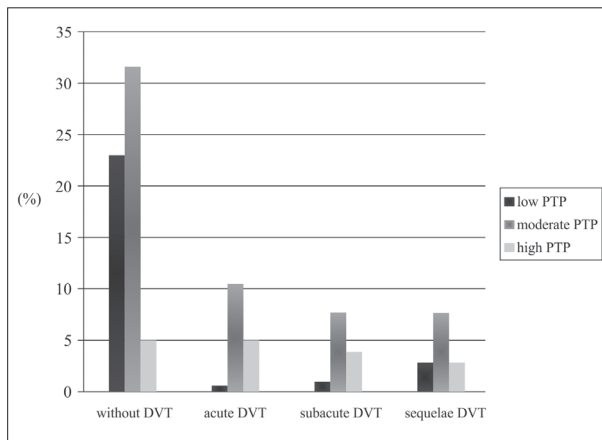
Data analysis was assessed using statistical evaluation in addition to various descriptive and analytic statistical methods (t-test,  $\chi^2$  test, McNemar's test, and others).

## RESULTS

We observed 350 patients, 168 of whom were male and 182 female. Their average age was  $62.5 \pm 8.4$ , the youngest being 18 and the oldest one 85 years old.

Several risk factors were present in our patients with different frequency. Malignant diseases were previously diagnosed in 24 patients (6.8%) included in our study (active cancer, either previously surgically treated, on chemo- or radio-therapy). There were six female patients with gynecologic cancers (cervical, ovarian, uterine, vaginal, and vulvar), five patients with cancer of the gastrointestinal tract and liver, four patients with leukemias and lymphomas, and two female patients with breast carcinoma.

Previous episodes of VTE had 26 (7.4%) patients, and seven patients (2%) were with known and documented primary thrombophilia [three patients with activated protein C resistance (factor V Leiden), three patients with



**Figure 1.** Cumulative compression ultrasonography results for low, moderate, and high PTP groups  
PTP – pretest probability; DVT – deep vein thrombosis

protein C and protein S deficiency, and one patient with prothrombin gene mutation].

DVT was present in 13 patients (3.7%) with lower-extremity plaster immobilization at the moment the diagnosis was established. Lower-extremity paresis and paralysis were present in nine patients (2.6%) – either as a result of spinal cord trauma (three patients), cerebrovascular insult (three patients), progressive myelitis (one patient), or cerebral tumor (two patients).

15 patients (4.3%) with CUS-documented DVT were bedridden (seven patients in the end-stage of malignant diseases, two patients in the end-stage of renal failure, two patients with AIDS, and four patients with sequelae of cerebrovascular disease).

Major surgery procedures were performed in 23 patients (6.6%) (orthopedic, vascular/cardiac, abdominal, gynecological, or neurosurgical procedures) two days to 12 weeks before the CUS examination.

The patients in our study had the following clinical sign distribution: entire leg swelling was present in 59 (16.9%) and calf swelling was present in 48 (13.7%) patients, 36 (10.3%) patients had unilateral pitting edema, and 52 (14.9%) patients had alternative clinical signs (i.e. muscle pain, chronic venous insufficiency, isolated joint pain, cellulitis, etc.).

Most of the examined patients (56.8%) were with moderate PTP according to the modified Wells score used.

CUS examination results for all three PTP groups are presented in Figure 1. The highest number of examined patients in all PTP groups was without DVT (59.2%).

Proximal DVT localization (iliac and femoral DVT) was found in 60.5% and distal DVT localization (popliteal and crural DVT) in 39.5% of patients with DVT.

The comparison of D-dimer test results and CUS examination is presented in Table 2. The results show that VIDAS test was positive in the highest percentage in the group of patients with CUS-documented thrombosis. In the group without CUS-documented thrombosis, HemosIL test was negative in the highest percentage.

Important statistical parameters of D-dimer tests compared in our study are presented in Table 3. VIDAS had the

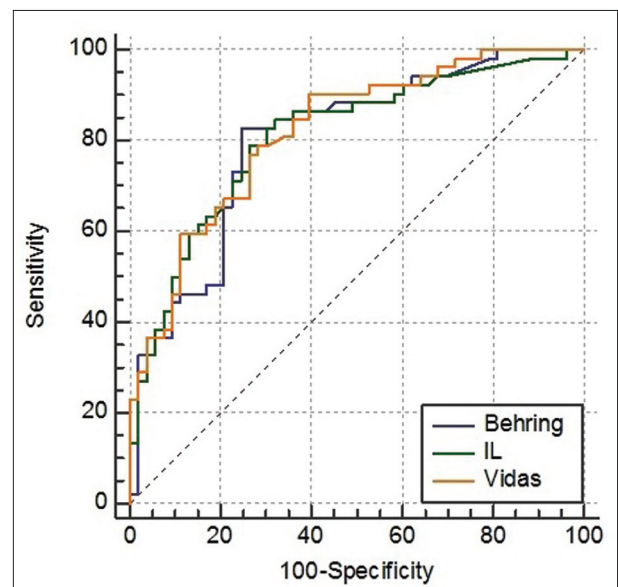
**Table 2.** Compression ultrasonography and D-dimer test results comparison

Tests	Without thrombosis		With thrombosis		Whole group	
	Positive (%)	Negative (%)	Positive (%)	Negative (%)	Positive (%)	Negative (%)
DD PLUS	40.3	59.7	93	7	73.3	26.7
HemosIL	33.8	66.2	88.4	11.6	56.1	43.8
VIDAS	42.6	57.4	95.3	4.7	62.8	37.2

**Table 3.** Statistical parameters of DD PLUS, HemosIL, and VIDAS test

D-dimer test	Sn (%)	Sp (%)	PPV (%)	NPV (%)
DD PLUS	93	40	51	89
HemosIL	84	66	62	89
VIDAS	95	59	64	94

Sn – sensitivity; Sp – specificity; PPV – positive predictive value; NPV – negative predictive value



**Figure 2.** D-dimer tests comparison by sensitivity and specificity (ROC curve)

highest sensitivity, while HemosIL had the highest specificity. Comparing to the other tests, VIDAS had the highest levels of both positive and negative predictive values.

The comparison of three D-dimer tests by receiver operating characteristic (ROC) curve is represented in Figure 2. In this curve, the sensitivity is plotted in function of the specificity for different cut-off points, where each point represents a pair corresponding to a particular decision threshold, and test with perfect discrimination has a plot that passes through the upper left corner. Therefore, the closer the ROC plot is to the upper left corner – the higher the overall accuracy of the test. In our study, it was the case with VIDAS test.

## DISCUSSION

Patients with acute VTE require clinical assessment and objective testing to be accurately diagnosed. Almost all patients with acute VTE have an elevated D-dimer level. An elevated D-dimer is associated with many illnesses and,



therefore, is not specific to VTE. D-dimer tests can have a high sensitivity, which is useful because a normal test excludes the diagnosis of VTE. D-dimer testing is most appropriate in the assessment of outpatients because the prevalence of disease and the likelihood of comorbidity are lower than in inpatient populations, making a test of exclusion particularly valuable [10, 11].

The role of the pretest clinical probability score and/or the D-dimer concentration in the diagnostic management of DVT has been the objective of many studies.

While reviewing management outcome studies, Carrier et al. [12] have found that the three-month PTE risk in patients left untreated on the basis of a low/intermediate or unlikely PTP and a negative D-dimer test was very low and that the combination of a negative VIDAS D-dimer result and a non-high PTP effectively and safely excludes PE.

The results of a study by Van der Graaf et al. [13] suggest that VIDAS and Tinaquant D-dimer assays have the highest sensitivity for the exclusion of DVT in outpatients. In outpatients that have a low or moderate pretest probability for DVT, these tests may be used in management studies where anticoagulation is withheld on the basis of D-dimer testing alone.

Vermeer et al. [14] tested samples from 274 consecutive symptomatic patients with suspected PE, DVT, or suspected for both complications, with DD PLUS assay. The conclusion of their study shows that this appears to be safe when implemented in an algorithm based on clinical assessment, D-dimer concentration, and radiological diagnostic techniques to stratify the risk for PE or DVT.

The objective of a study by Legnani et al. [15] was to evaluate possible advantages of using quantitative D-dimer assays (VIDAS, Innovance, HemosIL, and STA Liatest) performed in plasma aliquots sampled after cessation of vitamin K-antagonism in 321 patients enrolled in the PROLONG study. Their conclusion was that quantitative D-dimer assays may provide information useful for evaluating the individual risk of recurrent VTE and they seem particularly advantageous since they allow the selection of different cut-off levels according to the age and other patients' characteristics.

Djurabi et al. [16] studied the VTE failure rate of 2,206 consecutive patients with an unlikely clinical probability where VIDAS or Tinaquant D-dimer tests were performed. Their conclusion was that both tests perform equally well in combination with an unlikely clinical probability in excluding PE, but the VIDAS test was shown to be more efficient.

Gardiner et al. [17] evaluated the performance of eight D-dimer assays, including VIDAS, DD PLUS, and HemosIL, both as stand-alone tests and in combination with pretest probability. Their conclusion was that the highly variable diagnostic performance of these D-dimer assays means that some assays can be unsuitable for certain diagnostic strategies, but the combination of sensitive D-dimer assays with an assessment of PTP may be used to exclude the diagnosis of DVT.

Bogavac-Stanojević et al. [18] analyzed the total cost of three D-dimer assays (VIDAS, DD Plus, and HemosIL).

The total cost of the diagnostic procedure was calculated based on the consumed resources for diagnostic tests, laboratory time, and consumables). Their study group consisted of 96 outpatients with clinically suspected DVT. In the selection of patients for CUS, they used one diagnostic algorithm for the entire patient group and another for patients selected for CUS according to clinical PTP. The conclusion was that a diagnostic algorithm using PTP assessment, DD assay, and CUS could effectively diagnose DVT and reduce CUS utilization and costs per patient.

Many authors emphasize the advantages of other non-invasive diagnostic procedures in establishing the diagnosis of DVT. In combination with CUS, they can estimate the diagnostic accuracy, clinical and cost effectiveness.

CUS, due to its high sensitivity, specificity, and reproducibility has replaced venography as the most widely used test in the evaluation of this disease. The safety, availability, and well-documented accuracy of this technique justify its widespread use. In symptomatic patients, CUS has shown to be highly specific and sensitive for both proximal and distal DVT.

Michiels et al. [19] found that pulmonary angiography could be the gold standard for segmental PE and that normal pulmonary ventilation/perfusion scan and normal rapid ELISA VIDAS D-dimer test safely exclude PE. The combination of clinical assessment and a rapid ELISA VIDAS D-dimer, followed by CUS, will reduce the need for helical spiral CT by 40–50%.

Le Gal et al. [20] showed that the presence of a clot – even an asymptomatic one – in the proximal lower limb veins of a patient with clinically suspected PE, confirmed by CUS, provides evidence for VTE and indicates anticoagulant therapy in such patients. Their experience is that invasive tests are often unavailable and their use is therefore limited to selected patients and non-invasive management (clinical probability, D-dimer, and multislice CT) is feasible in most patients with suspected PE.

Goodacre et al. [21] searched through electronic medical databases and additional data from article bibliographies. Their conclusion was that old techniques as plethysmography and rheography have modest sensitivity for proximal DVT, poor sensitivity for distal DVT, and modest specificity. Ultrasound has 94% sensitivity for proximal DVT, 64% sensitivity for distal DVT, and 94% specificity. Computed tomography scanning has 95% sensitivity for all DVT (proximal and distal combined) and 97% specificity. Magnetic resonance imaging has 92% sensitivity and 95% specificity [21].

Diagnostic algorithms based on a combination of Wells score, D-dimer, and ultrasound (with repeat if negative) are feasible at most worldwide hospitals and are among the most cost-effective diagnostic methods. Pretest probability and D-dimer tests can decrease the need for CUS in young and healthy patients suspected of DVT. D-dimer tests should not be used as a stand-alone test or in situations such as the use of anticoagulants, presence of malignant diseases, post-surgical procedures, during pregnancy, in patients with severe infections, etc.

## CONCLUSION

All three D-dimer tests used in our study were with similar sensitivity and specificity. However, the VIDAS test had

higher levels of positive and negative predictive values compared to the DD plus and HemosIL tests. A comparison of the three D-dimer tests by the ROC curve showed that the VIDAS test has the highest overall statistical accuracy.

## REFERENCES

1. Heit JA. The epidemiology of venous thromboembolism in the community: implications for prevention and management. *J Thromb Thrombolysis*. 2006; 21(1):23–9.
2. Meissner MH, Strandness JR. Pathophysiology and natural history of acute deep venous thrombosis. In: Rutherford RB *Vascular surgery*. 6th ed. Philadelphia: Elsevier Saunders; 2005. p. 2124–57.
3. Sakuma M, Takahashi T. Epidemiology and therapy of acute pulmonary thromboembolism. In: Shirato K. *Venous thromboembolism, prevention and treatment*. Tokyo: Springer-Verlag; 2005. p. 3–47.
4. Bounameaux H. Integrated diagnostic approach to venous thromboembolism. In: Goldhaber SZ, Ridker PM. *Thrombosis and thromboembolism*. New York: Marcel Dekker; 2002. p. 225–34.
5. Wells PS, Anderson DR, Rodger M, Forgie M, Kearon C, Dreyer J, et al. Evaluation of D-dimer in the diagnosis of suspected deep-vein thrombosis. *New Engl J Med*. 2003; 349(13):1227–35.
6. Neale D, Tovey C, Vali A, Davies S, Myers K, Obiako M, et al. Evolution of the Simplify D-dimer assay as a screening test for the diagnosis of the deep vein thrombosis in an emergency department. *Emerg Med J*. 2004; 21(6):663–6.
7. Janes S, Ashford N. Use of a simplified clinical scoring system and D-dimer testing can reduce the requirement for radiology in the exclusion of deep vein thrombosis by over 20%. *Br J Haematol*. 2001; 112(4):1079–82.
8. Zwiebel WJ. *Venous thrombosis*. In: *Introduction to vascular ultrasonography*, 4th Ed. Zwiebel WJ. Elsevier Saunders: Philadelphia, 2000; 23:340.
9. Schäberle W. *Peripheral veins. Deep vein thrombosis of the leg*. In: *Ultrasonography in Vascular Diagnosis: A Therapy-Oriented Textbook and Atlas*. New York: Springer-Verlag; 2005.
10. Kearon C, Ginsberg JS, Douketis J, Crowther M, Brill-Edwards P, Weitz JJ, et al. Management of suspected deep venous thrombosis in outpatients by using clinical assessment and D-dimer testing. *Ann Intern Med*. 2001; 135:108–11.
11. Huisman MV, Klok FA. Diagnostic management of clinically suspected acute pulmonary embolism. *J Thromb Haemost*. 2009; 7(Suppl 1):312–7.
12. Carrier M, Righini M, Djurabi RK, Huisman MV, Perrier A, Wells PS, et al. VIDAS D-dimer in combination with clinical pre-test probability to rule out pulmonary embolism - A systematic review of management outcome studies. *Thromb Haemost*. 2009; 101(5):886–92.
13. van der Graaf F, van den Borne H, van der Kolk M, de Wild PJ, Janssen GW, van Uum SH. Exclusion of deep venous thrombosis with D-dimer testing – comparison of 13 D-dimer methods in 99 outpatients suspected of deep venous thrombosis using venography as reference standard. *Thromb Haemost*. 2000; 83(2):191–8.
14. Vermeer HJ, Ypma P, van Strijen MJ, Muradin AA, Hudig F, Jansen RW, et al. Exclusion of venous thromboembolism: evaluation of D-Dimer PLUS for the quantitative determination of D-dimer. *Thromb Res*. 2005; 115(5):381–6.
15. Legnani C, Palareti G, Cosmi B, Cini M, Tosetto A, Tripodi A. Different cut-off values of quantitative D-dimer methods to predict the risk of venous thromboembolism recurrence: a post-hoc analysis of the PROLONG study. *Haematologica*. 2008; 93(6):900–7.
16. Djurabi RK, Klok FA, Nijkeuter M, Kaasjager K, Kamphuisen PW, Kramer MH, et al. Comparison of the clinical usefulness of two quantitative D-Dimer tests in patients with a low clinical probability of pulmonary embolism. *Thromb Res*. 2009; 123(5):771–4.
17. Gardiner C, Pennaneac’h C, Walford C, Machin SJ, Mackie JJ. An evaluation of rapid D-dimer assays for the exclusion of deep vein thrombosis. *Br J Haematol*. 2005; 128(6):842–8.
18. Bogavac-Stanojević N, Dopsaj V, Jelić-Ivanović Z, Lakić D, Vasić D, Petrova G. Estimation of the total cost per patient with clinically suspected deep vein thrombosis in two diagnostic strategies. *Clin Chem Lab Med*. 2009; 47(Issue S1):S1–S409.
19. Michiels JJ, Gadisseur A, van der Planken M, Schroyens W, De Maeseneer M, Hermsen JT, et al. Screening for deep vein thrombosis and pulmonary embolism in outpatients with suspected DVT or PE by the sequential use of clinical score: a sensitive quantitative D-dimer test and noninvasive diagnostic tools. *Semin Vasc Med*. 2005; 5(4):351–64.
20. Le Gal G, Righini M, Sanchez O, Roy PM, Baba-Ahmed M, Perrier A, et al. A positive compression ultrasonography of the lower limb veins is highly predictive of pulmonary embolism on computed tomography in suspected patients. *Thromb Haemost*. 2006; 95(6):963–6.
21. Goodacre S, Sampson F, Stevenson M, Wailoo A, Sutton A, Thomas S, et al. Measurement of the clinical and cost-effectiveness of non-invasive diagnostic testing strategies for deep vein thrombosis. *Health Technol Assess*. 2006; 10(15):1–168.

## Компарација Д-димер теста са ултразвучним прегледом код дијагностике дубоке венске тромбозе

Драган Марковић<sup>1,2</sup>, Драган Васић<sup>1,2</sup>, Јелена Башић<sup>3</sup>, Слободан Танасковић<sup>1,4</sup>, Слободан Цветковић<sup>1,2</sup>, Зоран Ранчић<sup>5,6</sup>

<sup>1</sup>Универзитет у Београду, Медицински факултет, Београд, Србија;

<sup>2</sup>Клинички центар Србије, Клиника за васкуларну и ендоваскуларну хирургију, Београд, Србија;

<sup>3</sup>Болница „Рудолфштунг“, Клиника за кардиологију, Беч, Аустрија;

<sup>4</sup>Институт за кардиоваскуларне болести „Дедиње“, Клиника за васкуларну хирургију, Београд, Србија;

<sup>5</sup>Универзитетска болница у Цириху, Клиника за кардиоваскуларну хирургију, Цирих, Швајцарска;

<sup>6</sup>Универзитет у Цириху, Медицински факултет, Цирих, Швајцарска

### САЖЕТАК

**Увод/Циљ** Нелечена дубока венска тромбоза (ДВТ) повезана је са увећаним ризиком за плућну емболију, а погрешно дијагностикована ДВТ доводи до сувишне антикоагулационе терапије и тиме до повећаног ризика крварења. Тачна дијагностика и брза терапија ДВТ су важне за редукцију ризика од тромбоемболичких компликација.

Циљ наше студије је да процени сензитивност и специфичност три Д-димер теста (*DD plus*, *HemosIL* и *VIDAS*) у поређењу са ултразвучним испитивањем.

**Метод** У студију је укључено 350 болесника за различитим факторима ризика. Болесници су подвргнути истом протоколу (евалација историје болесника, физички преглед и контрола Д-димера), а ултразвучни (УЗ) преглед коришћен је као акредитив за све болеснике.

**Резултати** Болесници су по Велсовој скали подељени у групе са ниском, средњом и високом предтест вероватноћом. Већина прегледаних болесника је била у групи са средњом предтест вероватноћом. На УЗ је показано да највећи број болесника није имао ДВТ. Већина болесника са позитивним УЗ прегледом је имала проксималну – илијачну или феморалну ДВТ. *VIDAS* тест је у највећем проценту био позитиван у групи болесника са доказаном ДВТ на УЗ. Поређење сва три Д-димер теста на *ROC* кривој је показало највишу статистичку тачност *VIDAS* теста.

**Закључак** Сва три Д-димер теста коришћена у нашој студији имала су сличне вредности сензитивности и специфичности, с тим што је *VIDAS* тест имао виши ниво позитивне и негативне предиктивне вредности него тестови *DD plus* и *HemosIL*.

**Кључне речи:** Д-димер тест; компресивна ултрасонографија; дубока венска тромбоза