

CASE REPORT / ПРИКАЗ БОЛЕСНИКА

Penile leiomyosarcoma

Dragan Grbić¹, Alexander Cantrell², Nenad Šolajić^{3,4}, Mišo Dukić¹, Ivan Levakov^{1,4}, Saša Vojinović^{1,4}, Mladen Popov^{1,4}, Aleksandra Levakov-Fejsa^{4,5}, Goran Marušić^{1,4}

¹Clinical Centre of Vojvodina, Department of Urology, Novi Sad, Serbia;

²University of California, Davis, Department of Urology, Davis, CA, USA;

³Institute of Oncology of Vojvodina, Department of Pathology, Sr. Kamenica, Serbia;

⁴University of Novi Sad, Faculty of Medicine, Novi Sad, Serbia;

⁵Clinical Centre of Vojvodina, Center for Pathology and Histology, Novi Sad, Serbia



SUMMARY

Introduction Leiomyosarcoma of the penis (LSP) is an extremely rare form of penile tumor. LSP can be divided into two subtypes: deep and superficial.

The goal of this paper is to present a very rare case of LSP.

Case outline On examination, the patient presented with a slowly “growing penile bump,” for which an initial diagnosis of non-inflamed penile atheroma was given. Further diagnostic workup was omitted. Outpatient excisional biopsy was performed, and the tumor was sent for pathohistological examination, which revealed penile leiomyosarcoma. The patient has not received any further treatment. The most recent follow up was two and a half years after surgery, and the patient continues to do well without any complaints.

Conclusion LSP is an extremely rare disease, which can be cured if it is diagnosed in its early stage. Pathohistological examination is necessary for diagnosing LSP.

Keywords: penile tumor; penile atheroma; penile fibroma; penile leiomyosarcoma

INTRODUCTION

The incidence of penile malignancy in Europe is less than one case per 100,000 men. The most common type of penile malignancy is squamous cell carcinoma (more than 95%). The remaining 5% is mostly comprised of melanoma, lymphoma, mesenchymal tumors, and metastases. Leiomyosarcoma of the penis is an extremely rare penile tumor of mesenchymal origin.

The goal of this paper is to present a very rare case of penile leiomyosarcoma and to remind us of the existence, clinical course, treatment, and prognosis of this very rare subtype of penile tumor.

CASE REPORT

A 25-year-old male patient presented to clinic concerned about a firm nodule in the middle of his penile shaft. The nodule had been present for over a year, was not painful, and had been slowly growing. The patient's history was significant for juvenile diabetes mellitus of 10 years' duration, complicated by retinopathy leading to blindness. Exam revealed a painless, oval shaped penile shaft tumor, approximately 1.5 × 1 cm. The tumor had an irregular surface and was of a rubbery consistency. Examination of the abdomen and remaining external genitalia was unremarkable and there was no groin lymphadenopathy. Clinical diagnosis of

a non-inflamed penile atheroma was made. No further workup except for routine preoperative laboratory testing was pursued, with normal results.

Surgery was performed at an outpatient surgery center under local anesthesia. The tumor was completely excised and sent for histological examination. Intraoperatively, the clinical diagnosis was changed to penile fibroma due to its appearance and consistency. Histopathologic work-up included both routine hematoxylin and eosin staining and immunohistochemistry for smooth muscle actin, h-caldesmon, and S-100 protein (family of protein). Figure 1 contains four pictures: A and B – hematoxylin and eosin stain; C and D – immunoperoxidase with hematoxylin counterstain. Low magnification (40×) shows fascicular configuration (A). Higher magnification (400×) reveals conspicuous cytologic atypia and a mitotic figure below the center of the field (B). Tumor cells are strongly and diffusely immunopositive for h-caldesmon (C) and negative for S-100 protein with neural and perivascular structures as an internal positive control (D). Based on these findings, which are consistent with a malignant tumor of smooth muscle origin, a pathological diagnosis of penile leiomyosarcoma was made.

After obtaining the histopathology report, further metastatic work-up was pursued. Abdominal and pelvic computed tomography scan revealed one enlarged inter aorto-caval lymph node, 13 mm in size, though otherwise without evidence of the disease. The patient

Received • Примљено:

April 13, 2017

Revised • Ревизија:

May 5, 2017

Accepted • Прихваћено:

June 26, 2017

Online first: June 30, 2017

Correspondence to:

Dragan GRBIĆ
Clinical Centre of Vojvodina
Department of Urology
Hajduk Veljkova 1
21000 Novi Sad
Srbija
d_grbic@yahoo.com

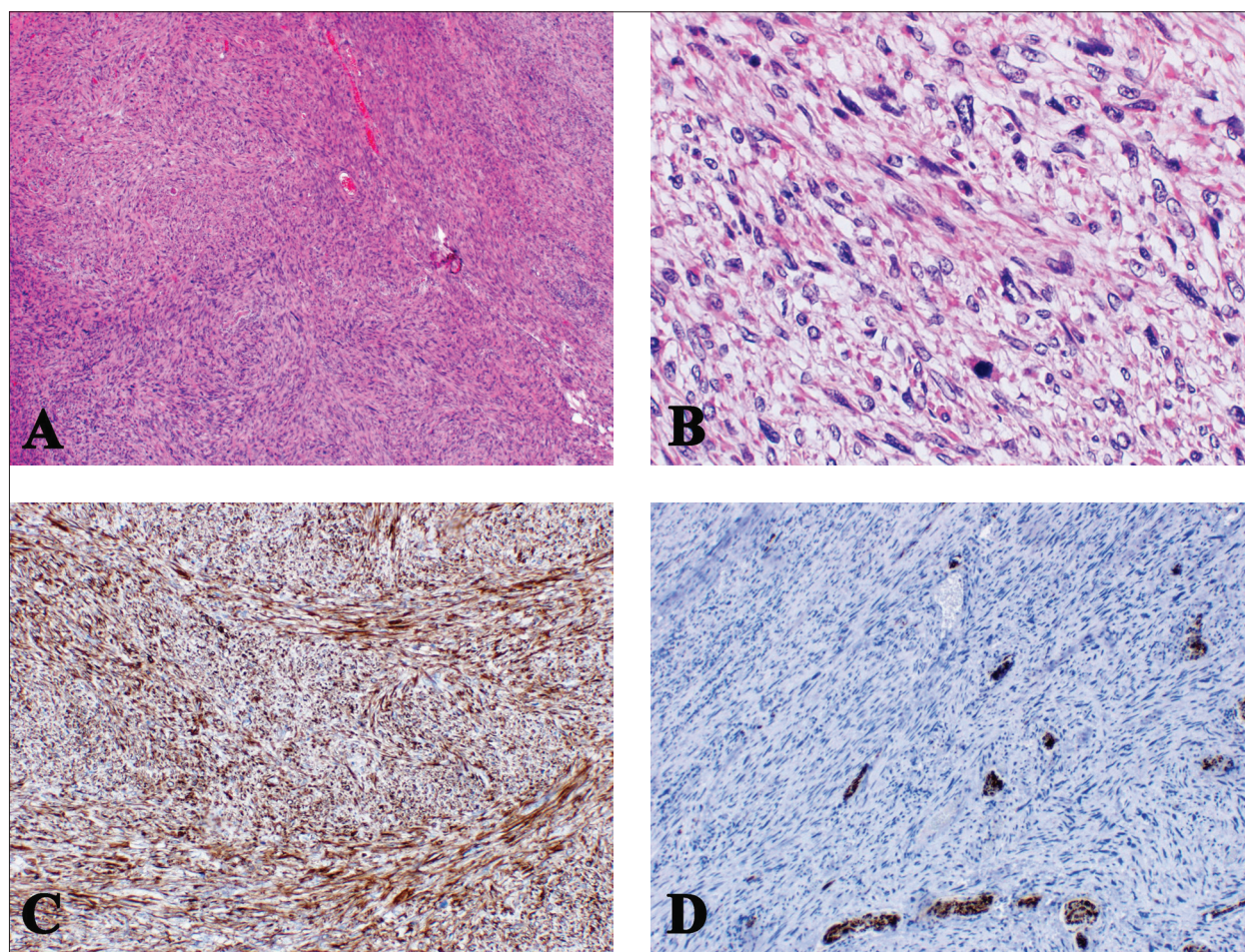


Figure 1. Intermingled fascicles of spindle tumor cells (H&E, ×40); B: pronounced cellular pleomorphism and mitotic activity (H&E, ×400); C: strong and diffuse immunoreactivity for h-caldesmon (immunoperoxidase with hematoxylin counterstain – immunopositive for h-caldesmon, ×100); D: no tumor cells positivity for S-100 protein (immunoperoxidase with hematoxylin counterstain – immunonegative for S-100 protein, ×100)

was followed with abdominal ultrasounds every three months for one year. No worrisome findings appeared on ultrasounds. One year after the surgery, the patient underwent repeat abdominal/pelvic computed tomography scan showing no signs of local or distant tumor recurrence, with the previously noted lymph node of unchanged size.

Further follow up was scheduled on an as-needed basis. The most recent follow up was two and a half years after surgery, and the patient continues to do well without any complaints or concerning symptoms.

DISCUSSION

Leiomyosarcoma of the penis is an extremely rare diagnosis. There are about 60 cases reported in the literature. The first case was described by Levi [1] in 1930. Clinically and histopathologically, there are two types of penile leiomyosarcoma: deep and superficial [2]. The more common superficial subtype originates from smooth muscle of superficial penile vessels (above tunica albuginea), dartos muscle of the penis, or erector pili muscle of the penile shaft. The deep subtype originates from the smooth muscle of the corpora cavernosa or spongiosa [2].

Recommended treatment of superficial penile leiomyosarcoma is wide local excision. This subtype has a much better prognosis compared to its deep counterpart. Superficial leiomyosarcoma shows a low recurrence rate and similarly low rates of metastasis (approximately 8%) [2, 3]. Incompletely resected superficial tumors tend to have a high recurrence rate and a wide re-excision should be pursued to guarantee negative margins. For deep leiomyosarcoma, partial or complete penectomy represent standard treatment. Lymph node involvement is rare and routine lymphadenectomy is not recommended [4]. Metastasis in the deep subtype can be up to 50%, with higher rates seen in patients with larger primary tumors [2].

The role of adjuvant chemotherapy and/or radiotherapy in the treatment of penile leiomyosarcoma is still not clear. However, due to the high rate of local recurrence and distant metastases even after complete excision of deep penile leiomyosarcoma, adjuvant chemotherapy and local radiation might be a reasonable option [5].

Because of the small number of cases reported so far, conclusions about standard treatment and prognosis of advanced leiomyosarcoma are difficult to draw [6].

In regard to this case specifically, the diagnosis of leiomyosarcoma came as a surprise to the performing urologist,

as the initial diagnosis of 'fibroma' or 'atheroma' gave way to the one of a penile cancer of extreme rarity. The authors would like once again to emphasize the importance of sending all excised tissue for routine histopathological examination, even in cases of clinically benign disease. In conclusion, because of the rarity of this disease, other than

extirpative surgery for diagnosis, we lack firm recommendations for the optimal treatment of patients with these tumors (especially deep leiomyosarcoma). Each patient's treatment should be individualized, and should rely heavily on the involvement of a multidisciplinary team, including a urologist, pathologist, oncologist and radiologist.

REFERENCES

1. Levi I. On a case of primary fibrosarcoma of the skin of the penis: clinical and histological study. *G Ital Dermatol.* 1930; 71:1559–74.
2. Fetsch JF, Davis Jr CJ, Miettinen M, Sesterhenn IA. Leiomyosarcoma of the penis: clinicopathologic study of 14 cases with review of the literature and discussion of the differential diagnosis. *Am J Surg Pathol.* 2004; 28(1):115–25.
3. Greenwood N, Fox H, Edwards EC. Leiomyosarcoma of the penis. *Cancer.* 1972; 29(2):481–3.
4. Pow-Sang MR, Orihuela E. Leiomyosarcoma of the penis. *J Urol.* 1994; 151(6):1643–5.
5. Nanri M, Kondo T, Okuda H, Tanabe K, Toma H. A case of leiomyosarcoma of the penis. *Int J Urol.* 2006; 13(5):655–8.
6. Valadez RA, Waters WB. Leiomyosarcoma of penis. *Urology.* 1986; 27(3):265–7.

Лејомиосарком пениса

Драган Грбић¹, Александер Кантрел², Ненад Шолајић^{3,4}, Мишо Дукић¹, Иван Леваков^{1,4}, Саша Војинов^{1,4}, Младен Попов^{1,4}, Александра Леваков-Фејса^{4,5}, Горан Марушић^{1,4}

¹Клинички центар Војводине, Клиника за урологију, Нови Сад, Србија;

²Калифорнијски универзитет у Дејвису, Катедра за урологију, Дејвис, Калифорнија, Сједињене Америчке Државе;

³Институт за онкологију Војводине, Одељење патологије, Сремска Каменица, Србија;

⁴Универзитет у Новом Саду, Медицински факултет, Нови Сад, Србија;

⁵Клинички центар Војводине, Центар за патологију и хистологију, Нови Сад, Србија

САЖЕТАК

Увод Лејомиосарком пениса (ЛСП) врло је редак тип тумора пениса, а разликују се површни и дубоки тип.

Циљ овог рада је да прикаже врло редак случај ЛСП.

Приказ болесника Болесник се јавио због „растућег чвора на пенису“ изгледа неинфламираног атерома на телу пениса. Додатне дијагностичке процедуре нису рађене. Амбулантно је урађена ексцизија тумора и промена послата на патохис-

толошки преглед (ПХП), којим је постављена дијагноза ЛСП. Нису коришћене друге методе лечења, а после редовних контрола у току 2,5 година нема рецидива болести.

Закључак Површни ЛСП је изузетно ретко уролошко обољење које може бити излечено уколико се дијагностикује у почетном стадијуму. За дијагнозу је неопходан ПХП.

Кључне речи: тумор пениса; атером пениса; фибром пениса; лејомиосарком пениса