

## CASE REPORT / ПРИКАЗ БОЛЕСНИКА

## Delayed diagnosis of homocystinuria presenting as bilateral congenital lens subluxation

Marija Jelić-Vuković<sup>1,2</sup>, Suzana Matic<sup>1,2</sup>, Josip Barac<sup>1,2</sup>, Tomislav Novinščak<sup>3</sup>, Mirna Belovari<sup>4</sup>, Hrvoje Barić<sup>4</sup>

<sup>1</sup>Osijek Clinical Hospital Center, Department of Ophthalmology, Osijek, Croatia;

<sup>2</sup>Josip Juraj Strossmayer University of Osijek, Faculty of Medicine, Osijek, Croatia;

<sup>3</sup>Institute for Emergency Medicine of Međimurje County, Čakovec, Croatia;

<sup>4</sup>Čakovec County Hospital, Department of Ophthalmology, Čakovec, Croatia

### SUMMARY

**Introduction** Homocystinuria is an autosomal recessively inherited defect leading to hyperhomocysteinemia and associated with ocular manifestations, mainly myopia and ectopia lentis.

**Case outline** A 26-year-old male with secondary glaucoma due to bilateral lens subluxation was admitted to the Department of vitreoretinal surgery. Horizontal nystagmus, bilateral lens subluxation, and bilateral amblyopia were first discovered at the age of three years. Preoperative laboratory workup revealed elevated levels of homocysteine. Bilateral pars plana lensectomy and vitrectomy followed by a sulcus fixation of the intraocular lens (ALCON MA60 Acrysof IOL) were performed. The patient was prescribed folic acid, methionine, and pyridoxine, and was urged to maintain a methionine-low diet. After a bilateral lensectomy and sulcus fixation of the intraocular lens and a methionine restriction therapy combined with vitamin B<sub>6</sub>, B<sub>9</sub>, and B<sub>12</sub> supplementation, his condition improved greatly.

**Conclusion** In this report of a rare case we emphasize the importance of examining differential diagnoses of lens subluxation, since early intervention can prevent serious complications.

**Keywords:** lens subluxation; homocystinuria; glaucoma

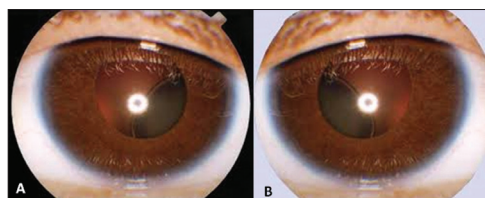
### INTRODUCTION

Homocystinuria is an autosomal recessive defect in methionine metabolism leading to hyperhomocysteinemia. It is associated with mental retardation, seizures, marfanoid habitus, and ocular manifestations, mainly myopia and ectopia lentis (EL) [1]. It has an estimated incidence of 1:50,000–200,000, sufficiently high to consider it for screening in newborns [2, 3]. After the condition is suspected based on physical findings, personal and family history, a workup is done for confirmation, including measuring homocysteine levels in blood and urine. Treatment consists of pyridoxine, vitamin B<sub>12</sub>, folic acid, anticoagulation agents for stroke prevention, and low-methionine diet in drug-resistant cases [4].

Since treatment can reduce mortality and severity of complications, early diagnosis is crucial. Neonatal screening tests used for testing other similar metabolic disorders lack sensitivity in detecting homocystinuria. In most cases, the condition is confirmed after three years of age, presenting with lens subluxation [5]. We report a case of homocystinuria diagnosed in a 26-year-old, who had experienced ocular manifestations of the disease since early childhood.

### CASE REPORT

A 26-year-old Caucasian male was referred to the Department of Vitreoretinal Surgery,



**Figure 1.** Biomicroscopic finding of the right (A) and left (B) eye shows bilateral inferotemporal subluxation of the lenses protruding in the inferior part of the vitreum

Osijek Clinical Hospital Center. The reason of the referral was the need for surgical treatment of a subluxated lens that had caused secondary glaucoma. At the age of two, he underwent a left nephrectomy and subsequent chemotherapy due to Wilms tumor. At the age of three, he was diagnosed with horizontal nystagmus, bilateral subluxation of lenses, and bilateral amblyopia, and was scheduled for periodical exams. During high school education he experienced learning difficulties.

On admission, light hair, short stature (height of 162 cm, weight of 73 kg, BMI 27.8 kg/m<sup>2</sup>), and bradydactylia were noted. The biomicroscopic ophthalmic examination showed bilateral inferotemporal subluxation of the lenses protruding in the inferior part of the vitreum (Figure 1). Zonular fibers were partially visible. Myopic changes were found on the fundus. Vitreal liquefaction was present.

Best corrected visual acuity was 0.4 LogMAR (Snellen acuity 6/15, decimal acuity 0.4) in the right eye and 0.7 LogMAR (Snellen acuity 6/30, decimal acuity 0.2) in the left eye.



**Примљено • Received:**  
September 7, 2016

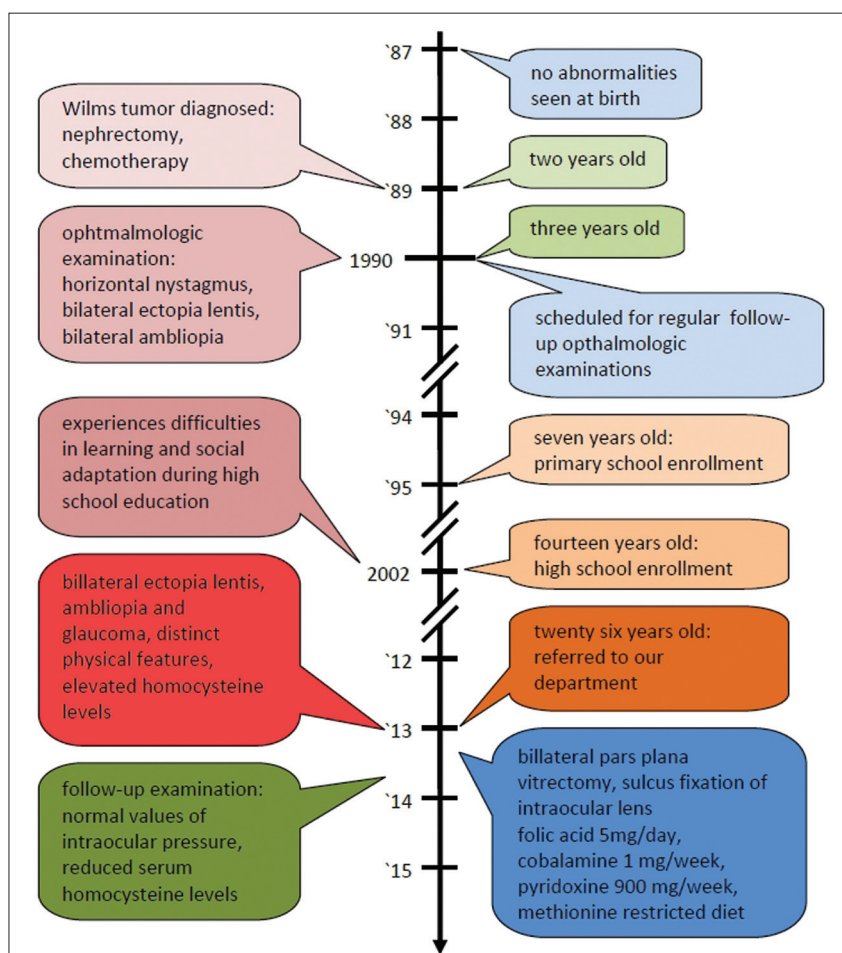
**Ревизија • Revised:**  
November 24, 2016

**Прихваћено • Accepted:**  
November 30, 2016

**Online first:** March 17, 2017

### Correspondence to:

Hrvoje BARIĆ  
Department of Neurosurgery,  
Zagreb Clinical Hospital Center,  
Kišpatičeva 12, 10000 Zagreb  
[hrvoje.baric00@kbc-zagreb.hr](mailto:hrvoje.baric00@kbc-zagreb.hr)



**Figure 2.** Flowchart of events

Applanation tonometry showed increased intraocular pressure (IOP; 33/31 mmHg).

The patient was referred to an internal medicine specialist. He underwent a physical examination and a complete ophthalmologic examination. Routine laboratory tests, including plasma homocysteine measurement, were ordered. Homocysteine level was 15  $\mu\text{mol/L}$ .

Systemic signs and elevated homocysteine levels suggested homocystinemia as the most probable underlying condition. Blood dyscrasia, Fabry disease, and acidemias were ruled out, since there was no history of thromboembolic events and coagulation test results were normal. There was no family history of serious diseases, including homocystinemia.

He was administered timolol/dorzolamide, brimonidine, and latanoprost in order to relieve elevated intraocular pressure. Since secondary bilateral glaucoma was unresponsive to treatment, a bilateral pars plana lensectomy, and vitrectomy followed by a sulcus fixation of the intraocular lens (ALCON MA60 Acrysof IOL; Alcon Inc., Hünenberg, Switzerland) were performed.

Also, a therapeutic regimen was established consisting of folic acid (5 mg/day), cobalamin (1 mg/week), pyridoxine (900 mg/day), and a methionine-restricted diet.

Three months upon the initiation of therapy, homocysteine levels were reduced to 10  $\mu\text{mol/L}$ . Ophthalmologic examination showed cIOL 0.1 LogMAR (Snellen acuity

6/7.5, decimal acuity 0.8) in the right eye, cIOL 0.3 LogMAR (Snellen acuity 6/12, decimal acuity 0.5) in the left eye, and normal values of IOP.

The timeline of events is shown in Figure 2.

## DISCUSSION

Early detection and treatment are of paramount importance in homocystinuria patients. Timely interventions can reduce the number and severity of complications. Abnormally high and progressive myopia at a young age combined with systemic complications are signs of suspected homocystinuria. Nevertheless, significant delays in diagnosis happen [6].

EL occurs in around 80% of patients and it is the most common involvement in homocystinuria [7, 8]. About 70% of patients will develop EL by eight years of age, and 82% by the age of 10 [9].

Signs that might suggest EL include very high myopia, abnormally progressive myopia, myopia at a young age, or high myopia without a myopic fundus [6]. Later signs include decreased vision, monocular diplopia or pain secondary to pupillary glaucoma, and vascular signs [10].

Even though EL is one of the most prominent symptoms of homocystinuria, and 5% of all lens dislocations may be attributed to this metabolic condition, homocystinuria is often neglected in the differential diagnosis of

EL, which leads to a delay in, or a lack of, correct diagnosis and treatment with a mean of 11 years from the onset of major signs until the diagnosis [6, 10]. In the case of our patient, the delay of diagnosis was 23 years.

Every EL requires a broad differential diagnostic approach since it is often a presentation of a systemic disease. It can be etiologically divided into two groups: hereditary and secondary to other causes [7]. The latter include trauma, infections, a large eye, anterior uveal tumors, pseudoexfoliation syndrome, and hypermature cataract. Hereditary EL occurs in systemic disorders such as Marfan syndrome, homocystinuria, Weil–Marchesani syndrome, Ehlers–Danlos syndrome, deficiency in sulfite oxidase, and hyperlysinemia. Hereditary EL without systemic associations includes aniridia, congenital glaucoma, familial EL, and ectopia lentis et pupillae.

Homocystinuria is divided into two groups based on the therapeutic response [9]. About 50% of patients respond well to vitamin B<sub>6</sub> (B<sub>6</sub>-responsive homocystinuria) supplements in high doses [10]. Vitamin B<sub>6</sub>-responsive

patients have lower incidence, and later occurrence of complications [7, 11]. B<sub>6</sub>-non-responsive patients require a methionine-restricted diet with daily intakes of methionine not exceeding 40 mg/day [9]. An alternative therapeutic approach can be considered in these patients, which involves the use of methyl donors, betaine or its precursor choline, that reduce homocysteine levels by promoting its conversion to methionine [6, 10]. A combined therapy was prescribed in our patient.

Treatment from infancy with pyridoxine, folic acid, and betaine reduces cardiovascular risk by 80–90% [12]. To prevent thromboembolism, antiaggregant treatment with acetylsalicylic acid should also be considered in cases of immobilization or after surgery [8].

Because of the increased probability of thromboembolism, conservative treatment of EL is advised when possible [10, 13]. Lensectomy is performed in cases of secondary complications, such as progressive lens subluxation, cataract formation, lens instability, retinal detachment, or pupillary block glaucoma, as was the case in our patient [13, 14].

## REFERENCES

1. Kaur M, Kabra M, Das G, Suri M, Verma I. Clinical and biochemical studies in homocystinuria. *Indian Pediatr.* 1995; 32(10):1067–75.
2. Mudd S, Skovby F, Levy H, Pettigrew K, Wilcken B, Pyeritz R, et al. The natural history of homocystinuria due to cystathionine beta-synthase deficiency. *Am J Hum Genet.* 1985; 37(1):1–31.
3. Walter JH, Jahnke N, Remington T. Newborn screening for homocystinuria. *Cochrane Database of Syst Rev.* 2015; (10):CD008840.
4. Blom H, Schiff M. Treatment of Inherited Homocystinurias. *Neuropediatrics.* 2012; 43(6):295–304.
5. Bhardwaj P, Sharma R, Sharma M. Homocystinuria: A rare condition presenting as stroke and megaloblastic anemia. *J Pediatr Neurosci.* 2010; 5(2):129–31.
6. Cruysberg J, Boers G, Trijbels J, Deutman A. Delay in diagnosis of homocystinuria: retrospective study of consecutive patients. *BMJ.* 1996; 313(7064):1037–40.
7. Sadiq M, Vanderveen D. Genetics of Ectopia Lentis. *Semin Ophthalmol.* 2013; 28(5-6):313–20.
8. Martínez-Gutiérrez J, Mencía-Gutiérrez E, Gracia-García-Miguel T, Gutiérrez-Díaz E, López-Tizón E. Classical familial homocystinuria in an adult presenting as an isolated lens subluxation. *Int Ophthalmol.* 2011; 31(3):227–32.
9. Burke J, O'Keefe M, Bowell R, Naughten E. Ocular complications in homocystinuria – early and late treated. *British J Ophthalmol.* 1989; 73(6):427–31.
10. Isherwood D. Homocystinuria. *BMJ.* 1996; 313(7064):1025–6.
11. Garland J, Prasad A, Vardy C, Prasad C. Homocystinuria: Challenges in diagnosis and management. *Paediatr Child Health.* 1999; 4(8):557–62.
12. Refsum H, Fredriksen Å, Meyer K, Ueland P, Kase B. Birth prevalence of homocystinuria. *J Pediatr.* 2004; 144(6):830–2.
13. Chandra A, Charteris D. Molecular pathogenesis and management strategies of ectopia lentis. *Eye.* 2014; 28(2):162–8.
14. Mulvihill A, Yap S, O'Keefe M, Howard P, Naughten E. Ocular findings among patients with late-diagnosed or poorly controlled homocystinuria compared with a screened, well-controlled population. *J AAPOS.* 2001; 5(5):311–5.

## Касна дијагноза хомоцистинурије приказана обостраном конгениталном сублуксацијом сочива

Марија Јелић-Вуковић<sup>1,2</sup>, Сузана Матић<sup>1,2</sup>, Јосип Бараћ<sup>1,2</sup>, Томислав Новиншчак<sup>3</sup>, Мирна Беловари<sup>4</sup>, Хрвоје Барић<sup>4</sup>

<sup>1</sup>Клинички болнички центар Осијек, Завод за офталмологију, Осијек, Хрватска;

<sup>2</sup>Свеучилиште Јосип Јурај Штросмајер, Медицински факултет, Осијек, Хрватска;

<sup>3</sup>Завод за хитну медицину Међимурске жупаније, Чаковец, Хрватска;

<sup>4</sup>Жупанијска болница Чаковец, Одељење офталмологије, Чаковец, Хрватска

### САЖЕТАК

**Увод** Хомоцистинурија је аутозомно рецесивни наследни поремећај који води у хиперхомоцистенемију и повезан је са очним поремећајима, у првом реду кратковидошћу и ектопијом сочива.

**Приказ болесника** Мушкарац старости 26 година са секундарним глаукомом због обостране сублуксације сочива примљен је на Одељење витреоретиналне хирургије. У доби од три године откривени су хоризонтални нистагмус, обострана сублуксација сочива и обострана амблиопија. Преоперативна лабораторијска обрада показала је пови-

шен ниво хомоцистеина. Урађена је обострана *pars plana* лensexтомија и витректомија и сулкус фиксација интраокуларног сочива (*ALCON MA60 Acrysof IOL*). Прописана му је фолна киселина, витамини B<sub>6</sub>, B<sub>9</sub> и B<sub>12</sub> и саветована дијета са ниским садржајем метионина. После оперативног захвата и примењене терапије стање му се значајно побољшало. **Закључак** У овом приказу ретког случаја наглашавамо важност диференцијалне дијагнозе сублуксације сочива, пошто рана интервенција може спречити озбиљне компликације.

**Кључне речи:** сублуксација; хомоцистинурија; глауком