

## ORIGINAL ARTICLE / ОРИГИНАЛНИ РАД

# The importance of compression elastography in the evaluation of thyroid nodule malignancy

Miloš Gašić<sup>1</sup>, Sava Stajić<sup>2</sup>, Biljana Vitošević<sup>3</sup>, Predrag Mandić<sup>1</sup>, Jasmina Ćirić<sup>4,5</sup>, Dorentina Bexheti<sup>6</sup>, Milan Milisavljević<sup>5</sup>, Zdravko Vitošević<sup>1</sup><sup>1</sup>University of Priština, Institute of Anatomy, Faculty of Medicine, Kosovska Mitrovica, Serbia;<sup>2</sup>University Clinical Center "Dr. Dragiša Mišović – Dedinje", Department for Radiological Diagnostics, Belgrade, Serbia;<sup>3</sup>University of Priština, Faculty of Sport and Physical Education, Medical Department, Leposavić, Serbia;<sup>4</sup>Clinical Center of Serbia, Clinic for Endocrinology, Diabetes and Metabolic Diseases, Belgrade, Serbia;<sup>5</sup>University of Belgrade, School of Medicine, Belgrade, Serbia;<sup>6</sup>State University of Tetovo, Faculty of Medical Science, Tetovo, Macedonia**SUMMARY**

**Introduction/Objective** Compression, also called strain elastography imaging techniques, represent new echotomographic modality, which is a promising method for the differentiation of benign from malignant lesions, not only in the thyroid gland but also in other organs.

The objective of this study is to evaluate the importance of compression elastography in the differentiation of benign and malignant thyroid nodules.

**Methods** We performed echotomographic examinations in B mode, and examinations using compression elastography in a total of 186 persons (152 females and 34 males, with the average age of  $45.3 \pm 13.5$  years), with 264 nodules in the thyroid gland. Elastography was done in two steps: the first one through scoring elastographic figures, and the second one through the determination of the resistance index (strain ratio – SR).

**Results** Using elastography scores by Fukunari, 44 of 60 malignant nodules had a score of 3–4, while 152 of the 204 benign nodules had a score of 1–2. Using the receiver operating characteristic (ROC) analysis, the best cut-off point obtained using elastography scores was 2, with a sensitivity of 73.3% and specificity of 74.5%. Using the software-calculated SR we found that out of 89 nodules with  $SR \geq 2.5$ , 52 were malignant nodules, while out of 175 nodules with  $SR < 2.5$ , 167 were benign nodules. Using the ROC analysis, the best cut-off point obtained using SR was  $> 2.5$ , with a sensitivity of 86.7%, and specificity of 81.9%.

**Conclusion** As a follow-up of standard echotomographic examination in B mode, compression elastography is a newly developed and promising technique in the differentiation of benign from malignant lesions.

**Keywords:** compression elastography; nodule; thyroid gland; malignancy

**INTRODUCTION**

Thyroid nodules are very common in the general population, especially in iodine-deficient areas. It is estimated that nodules are seen in 35–50% of people living in areas with deficiencies in iodine. However, a normal thyroid gland has some thyrocytes (follicular cells) with the tendency of autonomous growth. All of them can occur in nodules regardless of the amount of iodine, with increased frequency in the population [1]. Thyroid ultrasonography is one of the most practical, easily manageable, accessible, and non-invasive methods which can detect nodules. One of the most important assessments is to determine the nature of the nodules, or to differentiate benign from malignant thyroid nodules. The classical technique of echotomographic examination in B mode cannot differentiate benign from malignant nodules with great certainty. Hypoechoic changes, the presence of microcalcifications, variable peripheral edge, intranodal hypervascularization, and pathologically suspected lymph nodes in the neck are some of

the uncertain indicators of malignant nodules, insufficient to evaluate the nature of thyroid nodules. Today, thanks to different software modes and modern ultrasonography devices, it is possible to additionally assess the nature of various nodules of the thyroid gland [2, 3].

Elastography is a new, non-invasive method, which estimates the elasticity of tissue by measuring different degrees of distortion during the application of an external force. The basic principle of ultrasound elastography is that tested tissue compression shows resistance. As well as palpation, elastography can measure tissue deformation or strain caused by the external compression [4]. Nowadays, these assessment methods are showing promise in the differentiation of benign from malignant lesions, and not just in the thyroid gland but also in the breasts, liver, spleen, and prostate. Malignant lesions are characterized by lower elasticity compared to the structure of normal tissue, partly due to the uncontrolled proliferation of malignant cells, increased vascularization, and, somewhat less frequently, due to the presence of fibrotic changes in them.

**Примљено • Received:**

October 20, 2016

**Ревизија • Revised:**

February 22, 2017

**Прихваћено • Accepted:**

February 28, 2017

**Online first:** March 28, 2017**Correspondence to:**

Miloš GAŠIĆ  
Institute of Anatomy, Faculty of  
Medicine, University of Priština  
Anri Dinana bb  
38220 Kosovska Mitrovica, Serbia  
[gasic.milos@yahoo.com](mailto:gasic.milos@yahoo.com)

The aim of this study is to evaluate the importance of strain ultrasound elastography in the differentiation of benign from malignant thyroid nodules, especially when combined with standard echotomography examination in B mode.

## METHODS

This cross-sectional study included 186 patients with 264 thyroid nodules (152 females and 34 males, with the mean age of  $45.3 \pm 13.5$  years). All the patients had solid lesions (nodules) and were referred to the Department of Radiological Diagnostics of the KBC "Dr. Dragiša Mišović – Centar" in Belgrade, Serbia, from March 2014 to June 2016. Patients with nodules of over 3.5 cm in size, completely cystic, anechogenic without solid components, and nodules in close contact with the carotid artery, were excluded from the study in order to increase the reliability of the findings. Echotomographic thyroid examinations were performed using the Aplio XG (Toshiba, Tokyo, Japan) ultrasound device, with a 10 MHz linear transducer.

All the patients were examined by using three ultrasonic methods. The first step was a standard echotomographic examination in B mode, the second was to test the resistance of the tissue through elastography scores, and the third step was to measure the resistance index (strain ratio – SR) as an indicator of the semi-quantitative elastography method for tissue resistance.

To avoid potential differences in operation between different researchers, all examinations were performed by a single researcher with a long experience in dealing with different modalities of ultrasound equipment. Also, in this way we standardized and equalized the compression on the tissue, during the elastography performance. Strain elastography was performed by repeated compressions (up to seven), with the same volume, and in the same time intervals (about 0.5 seconds). All compressions were based on the centrally positioned nodules in a region of interest, in the longitudinal view of the surrounding normal thyroid tissue for elasticity comparison.

Based on the classification by Fukunari [5], each nodule was scored by the elastographic figure. A score of 1 means the majority of the nodule, fully stained in green. A score of 2 signifies that only the nodule center is stained green, and the periphery is blue. A score of 3 denotes a predominantly blue nodule with green parts, and the score of 4 means that the entire nodule is blue. Elastography scores represent different degrees of elasticity of the lesion, from the highest (score 1) to the lowest elasticity (score 4). Scores of 1 and 2 represent indicators of benign nodules, while scores of 3 and 4 represent indicators of malignant ones. After the scoring, we recorded the SR, which is the software-calculated ratio of elasticity between two regions of interest, in our case between the nodule and the rest of the normal thyroid tissue. We evaluated each lesion three times, using a variety of static images, and the average value was recorded as the final result.

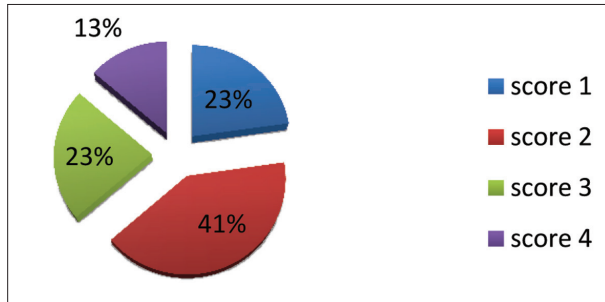
After the echotomographic examinations, all the patients were sent to perform the ultrasound-guided fine-needle aspiration biopsy. The results were processed by an experienced pathologist. Fifty-two patients (52 nodules) with cytological findings suspicious for malignancy, and 36 patients (48 nodules) with benign cytological findings, were operated on and histopathologic findings confirmed the earlier diagnoses. We compared the cytological and histopathological results with elastographic images, and evaluated the sensitivity, specificity, negative and positive predictive value, and accuracy of the techniques or methods. Quantitative data are presented in mean  $\pm$  standard deviation, and qualitative as frequencies. Receiver operating characteristic (ROC) curve was used to determine optimal cut-off values to differentiate between benign and malignant nodules. The value of  $p < 0.05$  was adopted as statistically significant. The data were statistically analyzed by MedCalc v.11.4.2 (MedCalc Software, Ostend, Belgium) statistical software.

## RESULTS

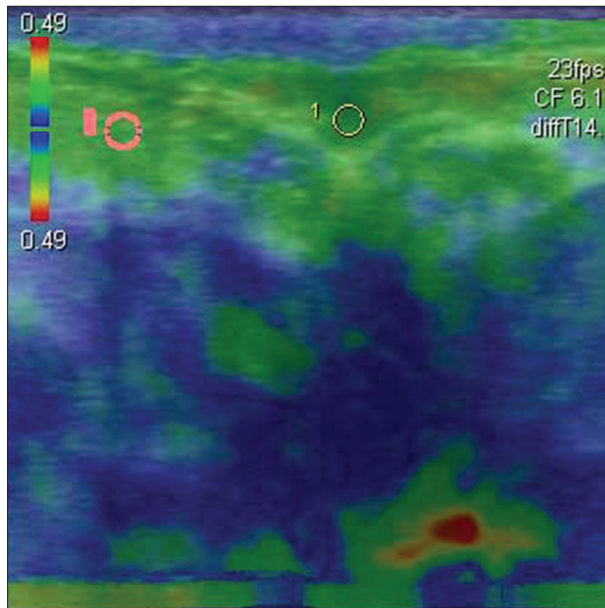
Among 186 patients who were included in the study (152 female and 34 male, with the mean age of  $45.3 \pm 13.5$  years), 264 nodules were obtained. Using classical echotomographic examination of the thyroid gland in B mode, out of 264 discovered nodules, 180 (68%) had homogeneous echostructure, while 84 nodules (32%) had heterogeneous echostructure – partially cystic. Most of the nodules (120; 45%) were isoechogenic, 104 (40%) were hypoechogenic, while the minority were hyperechogenic nodules (40; 15%). A total of 192 nodules (73%) had proper edges, while the edges were irregular in 72 nodules (27%). Visible calcifications were present in 56 nodules (21%), while calcifications were not seen in 208 nodules (79%) (Table 1). Using elastography scores by Fukunari [5], out of 204 benign nodules, 152 nodules (74%) had a score of score 1–2 (60 nodules had a score of 1, and 92 nodules a score of 2), and 52 nodules (26%) had a score of 3–4 (46 nodules had a score of 3, and 6 nodules a score of 4). Out of 60 malignant nodules, 44 nodules (73%) had a score of 3–4 (14 nodules had a score of 3, and 30 nodules a score of 4), while 16 malignant nodules (27%) had a score of 1–2 (all with a score of 2), as shown in Figures 1–5. The sensitivity of elastography scores for getting positive results in malignant nodules was 73.3%. The specificity of elastography scores for negative results in benign nodules was 74.5%. The positive predictive value was 45.8%, and the negative predictive value was 90.4%. The accuracy in the differentiation between benign and malignant nodules was 74.2% (Figure 6). Using the ROC analysis, the best cut-off point obtained using elastography scores to differentiate benign and malignant thyroid nodules was 2, with a sensitivity of 73.3% and a specificity of 74.5% (area under the ROC curve = 0.83, 95% confidence interval: 0.78–0.87,  $p < 0.0001$ ) (Figure 7). Using the ROC analysis, the best cut-off point obtained using SR to differentiate between benign and malignant thyroid nodule was found to be  $> 2.5$ , with sensitivity of 86.7% and specificity of 81.9% (area under the ROC curve = 0.88, 95% confidence

**Table 1.** Number of nodules in each score by Fukunari [5]

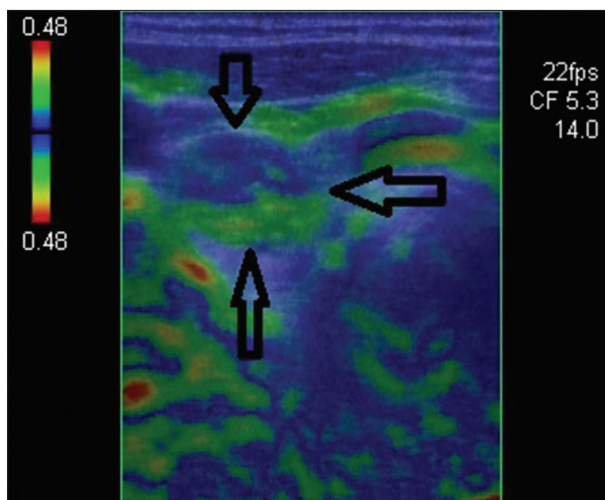
Elastographic score	Malignant nodules	Benign nodules	TOTAL
3-4	44	52	96
1-2	16	152	168
Total	60	204	264



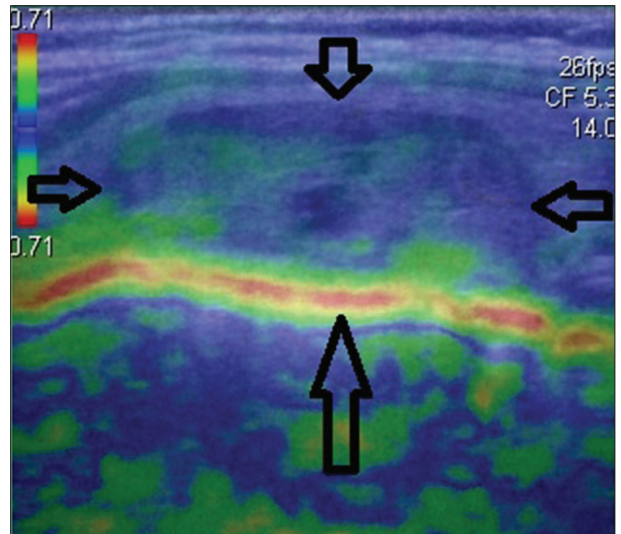
**Figure 1.** Total percentage of nodules in each score category



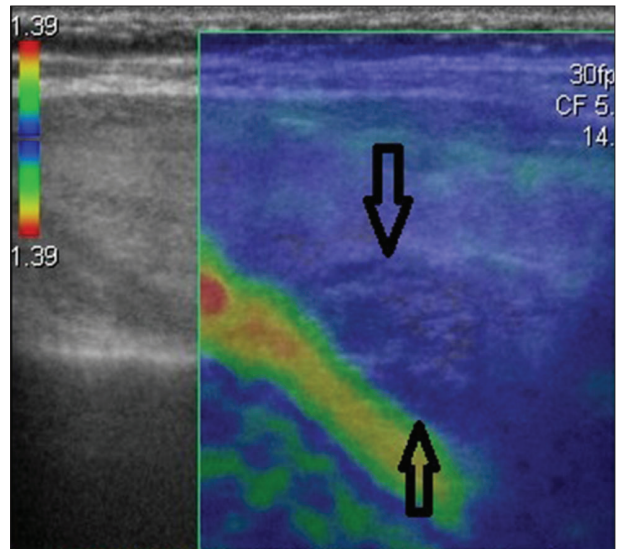
**Figure 2.** Score 1 by Fukunari [5] – findings obtained by biopsy proving benign nodule



**Figure 3.** Score 2 by Fukunari [5] – findings obtained by biopsy proving benign nodule



**Figure 4.** Score 3 by Fukunari [5] – findings obtained by biopsy proving papillary carcinoma



**Figure 5.** Score 4 by Fukunari [5] – findings obtained by biopsy proving papillary carcinoma

interval: 0.83–0.91,  $p < 0.0001$ ), as shown in Table 2 and Figures 8 and 9. Using the software-calculated SR, while performing elastography, we took the criterion that  $SR \geq 2.5$  was an indicator of malignancy. Out of 89 nodules with  $SR \geq 2.5$ , 52 were malignant. Out of 175 nodules with  $SR < 2.5$ , as much as 167 were benign. The SR for obtaining positive results in malignant nodules was 86.7%. The specificity of SR for obtaining negative results in benign nodules was 81.9%. The positive predictive value was 58.4%, and the negative predictive value was 95.4%. The accuracy of SR in differentiating benign from malignant nodules was 82.9% (Table 3). The results obtained by fine-needle aspiration biopsy showed that 204 nodules were benign (77%), while 60 nodules (23%) were malignant. Fifty-two patients (52 nodules) with malignant cells that are detected by fine-needle aspiration biopsy, and 36 patients (48 nodules) with benign cells, were operated on. Histopathologic findings for 52 patients (52 nodules) with malignant nodules were presented in Table 3.

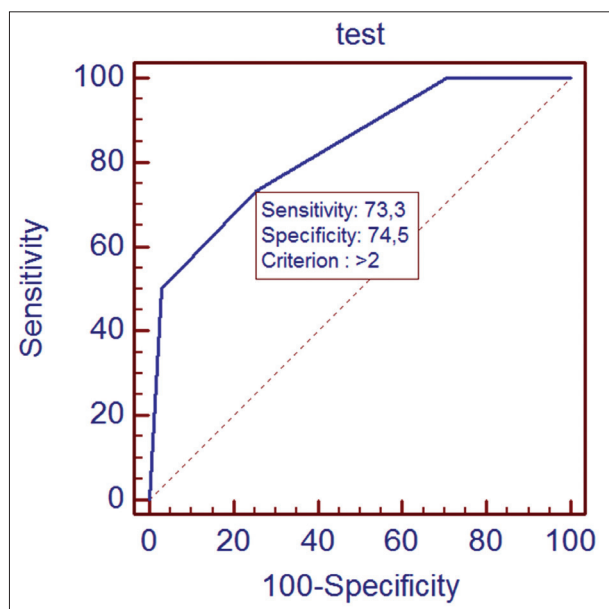


Figure 6. ROC analysis by using elastography scores

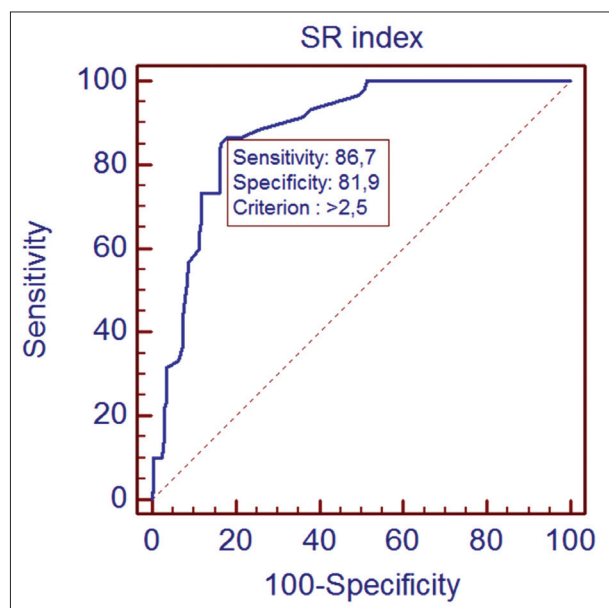


Figure 7. ROC analysis by using strain ratio

Table 3. Histopathologic types of malignant nodules in each elastographic score and strain ratio category

Type	Elastographic score 3–4 (%)	Elastographic score 1–2 (%)	SR $\geq$ 2.5 (%)	SR < 2.5 (%)	TOTAL (%)
Papillary carcinoma	33 (63.5)	7 (13.5)	38 (73.1)	2 (3.8)	40 (76.9)
Follicular carcinoma	3 (5.8)	4 (7.7)	4 (7.7)	3 (5.8)	7 (13.5)
Anaplastic carcinoma	2 (3.8)	2 (3.8)	2 (3.8)	2 (3.8)	4 (7.7)
Primary thyroid lymphoma	0 (0)	1 (1.9)	1 (1.9)	0 (0)	1 (1.9)
Total	38 (73.1)	14 (26.9)	45 (86.5)	7 (13.5)	52 (100)

## DISCUSSION

One of the primary methods of clinical examination of the thyroid gland includes the palpation. Palpation gives us information about the shape, size, as well as the hardness and elasticity of the thyroid gland. However, palpation is a subjective method of examination. Measurements of the elasticity and stiffness of soft tissue assessment are useful

Table 2. Number of nodules in each category by strain ratio

Strain ratio	Malignant nodules	Benign nodules	Total
SR $\geq$ 2.5	52	37	89
SR < 2.5	8	167	175
Total	60	204	264

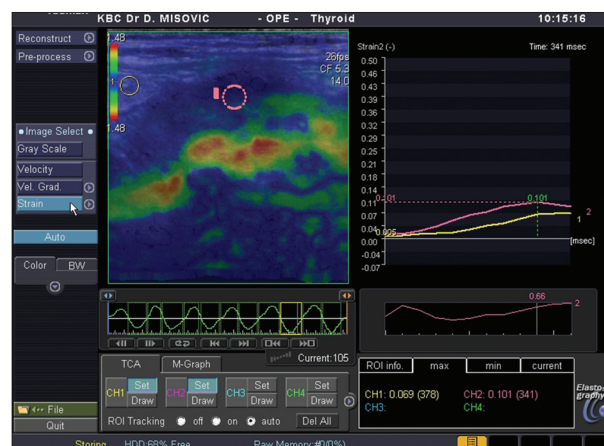


Figure 8. A nodule with elastography score of 2, SR 0.66 – biopsy-proven benign characteristics of a thyroid adenoma

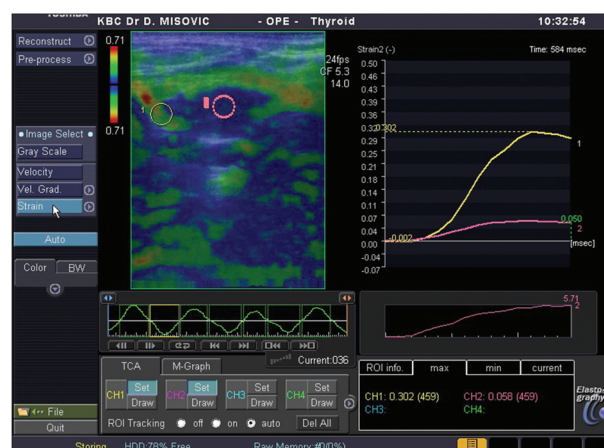


Figure 9. A nodule with an elastography score of 3–4, SR 5.71, biopsy-proven follicular carcinoma

in the differentiation of tumor, inflammation, and normal thyroid tissue. It is generally accepted that benign lesions show less stiffness and greater elasticity than malignant lesions, and higher stiffness and lower elasticity than normal tissue [4–7].

Classical echotomographic examination of the thyroid gland can detect characteristics of nodules that indicate malignancy. In addition to their appearance, ranging from

hypoechoic to almost anechoic, malignant nodules are echotomographically different, and the difference is mostly exhibited through the absent or incomplete (rarely closed) peripheral vascular edge. Microcalcifications are often present in the nodules, and intense central vascularization is almost always present. However, even at about 50% of benign nodules, intranodal vascularization may be present. Approximately, the most accurate echotomographic diagnosis of thyroid cancer is only possible when all the above symptoms are simultaneously present in thyroid nodules, with high specificity but low sensitivity [8, 9]. Therefore, unified and comprehensive information obtained by the classic echotomographic examination in B mode and color Doppler are the most reliable results predictive for malignancy.

Fine-needle aspiration biopsy under ultrasound control is still the most precise method for diagnosing cancer with high sensitivity and specificity, with a very small number of false-positive (2.3%) and false-negative (0.2%) results. The accuracy of differentiating benign from malignant lesions of the thyroid gland is more than 95% [10, 11].

We examined a newly-developed diagnostic method (ultrasound elastography), which estimates the degree of distortion of tissues when applying an external force. In the diagnostic algorithm, this method is placed between classic echotomographic examination in B mode, and fine-needle aspiration biopsy, and has been introduced in order to further increase ultrasound accuracy. It is based on the principle that softer tissue and tissue parts are more easily deformed, and have greater elasticity than harder tissues. Some of the main benefits of elastography are its simple feasibility, non-invasivity, and its convenience during a routine echotomography performance. In addition, this technique enables the dynamic visualization of lesions in the region of interest during the compression. Elastography is performed in two steps: determining scoring nodules on the elastography figure, and calculating the SR using the software. Scoring is a subjective estimate of the lesion of interest (nodule), classified into one of the scores based on the color distribution in B mode. Different colors (green, red, blue) on the echotomographic figure represent different elasticity areas of the tissue in the region of interest [12]. In our study, we used the scoring by Fukunara [5], ranging from the most elastic (score of 1; mostly benign nodules) to the least elastic (score of 4; mostly malignant nodules). Using these elastography scores, we discovered malignant nodules with the sensitivity of 73.3%. The same score system was used by Wang et al. [12], while the score of the Ueno classification was used by Ciledag et al. [4] and Itoh et al. [13]. Many studies indicate that this part of elastography is sufficient for the assessment of different tissue elasticity and for the differentiation between benign and malignant nodes [14, 15]. Malignant thyroid nodules have less elasticity (score 3–4), while benign nodules exhibit higher elasticity (score 1–2), as shown by our results of sensitivity (73.3%) and specificity (74.5%); ( $p < 0.05$ ) [14–18]. However, in determining the SR, we get even higher values of sensitivity (86.7%) and specificity (81.9%), and the results pointed to increased reliability and accu-

racy of the test (82.9%). We demonstrated that malignant nodules had a significantly higher SR than benign nodules ( $p < 0.001$ ). Determination of SR represents a software-calculated quantitative measure of elasticity, which may provide more reliable information. In our study, all SR values  $\geq 2.5$  represent a predictor of malignant nodules, in accordance with the values that we obtained by the ROC analysis. Lyshchik et al. [19] suggested that  $SR > 4$  is a strong predictor of malignant nodules, with a sensitivity of 82% and a specificity of 96%. However, Kagoya et al. [7] used the  $SR > 1.5$  as an indicator of malignant nodules, with sensitivity of 90%, and specificity of 50%.

While performing this technique, the depth of tissue should be taken into consideration when the comparison between the nodules and the normal tissue is made, and it should be the same or similar when calculating the SR. The estimation should be performed in the longitudinal mode of the thyroid gland examination because it shows a sufficiently large portion of normal tissues that are used to compare and calculate the SR [12, 20]. Rago et al. [14] showed that the size of nodules does not affect the value of the SR and elastography predictability. However, other researchers have indicated that the size of nodules may affect the SR, so in some studies all nodules up to 3 cm in size are included [12], while some studies include all nodules up to 4 cm in size [4]. In our study, we included all nodules up to 3 cm. Nodules larger than 3 cm were not compressed with the same intensity throughout, and the results of the SR index values were inadequate. Presently, there is no reliable information which indicates that minimal nodule size might be involved in this method. Researchers in some studies advise that, during the elastography procedure, nodules near the carotid artery must be treated with care due to the fact that pulsations of the carotid arteries can disrupt proper interpretation of the elastography figure [4, 12]. Consequently, our study avoided patients whose nodules were near the carotid artery, and the method was performed using the external compression. However, the study of Dighe et al. [21] showed that the pulsation of the carotid artery can be used, instead of external compression by researchers, for the evaluation of elastography figures. Elastography analysis results obtained in this way were similar to ours ( $p < 0.05$ ). In our study, a small number of false-negative results inform us that elastography can reduce the number of patients referred to surgeons for the suspicion of malignancy and therefore delay the eventual surgical intervention due to malignancy.

One of the biggest disadvantages of this method is subjectivity. Strain elastography in all its forms remains an examiner-dependent method and requires a trained and experienced operator to perform valid free-hand cyclic compressions that can yield reliable and reproducible readings. The free-hand probe pressure is difficult to standardize among different operators and strain variations due to changes in the amplitude and velocity of compression that cannot be avoided. Non-uniform compressions produce intra- and interobserver variability [20]. For this reason, a newer elastography technique, called shear wave elastography (SWE) has been developed. This method is designed

to provide quantitative, more objective information on elasticity in real time. SWE uses acoustic pressure from the probe for the standardization of compression. The tissue compression force does not depend on the skill of the person performing the examination, ensuring high reproducibility and objectivity of the results. SWE can produce quantitative and more precise results than strain elastography. Although SWE requires a more complex system to generate the shear waves, it allows visualization of smaller displacements compared to strain elastography [22].

Also, histological features of nodules may lead to pitfalls. Fibrosis within a nodule, calcification, partially cystic or colloid components, isthmus location, nodule size, and the multinodular nearness appearance are correlated to increased levels of stiffness [22, 23]. Follicular carcinomas may lead to false negative results in strain elastography, as they may be soft, and therefore may be missed [24].

## REFERENCES

- Schmidt M, Schicha H. Thyroid disorders. *Versicherungsmedizin*. 2011; 63(4):176–9. (German)
- Wienke JR, Chong WK, Fielding JR, Zou KH, Mittelstaedt CA. Sonographic features of benign thyroid nodules: interobserver reliability and overlap with malignancy. *J Ultrasound Med*. 2003; 22(10):1027–31.
- Iannuccilli JD, Cronan JJ, Monchik JM. Risk for malignancy of thyroid nodules as assessed by sonographic criteria. *J Ultrasound Med*. 2004; 23(11):1455–64.
- Ciledag N, Arda K, Aribas BK, Aktas E, Köse SK. The utility of ultrasound elastography and MicroPure imaging in the differentiation of benign and malignant thyroid nodules. *Am J Roentgenol*. 2012; 198(3):W244–9.
- Fukunari N. More accurate and sensitive diagnosis for thyroid tumors with elastography-detection and differential diagnosis of thyroid cancers. *Medix*. 2007; 05 Suppl.:S16–9.
- Menzilcioglu MS, Duymus M, Avcu S. Sonographic Elastography of the Thyroid Gland. *Pol J Radiol*. 2016; 81:152–6.
- Kagoya R, Monobe H, Tojima H. Utility of elastography for differential diagnosis of benign and malignant thyroid nodules. *Otolaryngol Head Neck Surg*. 2010; 143(2):230–4.
- Becker D, Bair HJ, Becker W, Günter E, Lohner W, Lerch S, et al. Thyroid autonomy with color-coded image-directed Doppler sonography: internal hypervascularization for the recognition of autonomous adenomas. *J Clin Ultrasound*. 1997; 25(2):63–9.
- Woliński K, Szkudlarek M, Szczepanek-Parulska E, Ruchała M. Usefulness of different ultrasound features of malignancy in predicting the type of thyroid lesions: a meta-analysis of prospective studies. *Pol Arch Med Wewn*. 2014; 124(3):97–104.
- Oertel YC, Miyahara-Felipe L, Mendoza MG, Yu K. Value of repeated fine needle aspirations of the thyroid: an analysis of over ten thousand FNAs. *Thyroid*. 2007; 17(11):1061–6.
- Hamburger JI. Diagnosis of thyroid nodules by fine needle biopsy: use and abuse. *J Clin Endocrinol Metab*. 1994; 79(2):335–9.
- Wang HL, Zhang S, Xin XJ, Zhao LH, Li CX, Mu JL, et al. Application of real-time ultrasound elastography in diagnosing benign and malignant thyroid solid nodules. *Cancer Biol Med*. 2012; 9(2):124–7.
- Itoh A, Ueno E, Tohno E, Kamma H, Takahashi H, Shiina T, et al. Breast disease: clinical application of US elastography for diagnosis. *Radiology*. 2006; 239(2):341–50.
- Rago T, Santini F, Scutari M, Pinchera A, Vitti P. Elastography: new developments in ultrasound for predicting malignancy in thyroid nodules. *J Clin Endocrinol Metab*. 2007; 92(8):2917–22.
- Asteria C, Giovanardi A, Pizzocaro A, Cozzaglio L, Morabito A, Somalvico F, et al. US-elastography in the differential diagnosis of benign and malignant thyroid nodules. *Thyroid*. 2008; 18(5):523–31.
- Tranquart F, Bleuzen A, Pierre-Renoult P, Chabrolle C, Sam Giao M, Lecomte P. Elastasonography of thyroid lesions. *J Radiol*. 2008; 89(1 Pt 1):35–9. (French)
- Sun J, Cai J, Wang X. Real-time ultrasound elastography for differentiation of benign and malignant thyroid nodules: a meta-analysis. *J Ultrasound Med*. 2014; 33(3):495–502.
- Andrioli M, Scacchi M, Carzaniga C, Vitale G, Moro M, Poggi L, et al. Thyroid nodules in acromegaly: The role of elastography. *J Ultrasound*. 2010; 13(3):90–7.
- Lyshchik A, Higashi T, Asato R, Tanaka S, Ito J, Mai JJ, et al. Thyroid gland tumor diagnosis at US elastography. *Radiology*. 2005; 237(1):202–11.
- Park SH, Kim SJ, Kim EK, Kim MJ, Son EJ, Kwak JY. Interobserver agreement in assessing the sonographic and elastographic features of malignant thyroid nodules. *AJR*. 2009; 193(5):W416–23.
- Dighe M, Bae U, Richardson ML, Dubinsky TJ, Minoshima S, Kim Y. Differential diagnosis of thyroid nodules with US elastography using carotid artery pulsation. *Radiology*. 2008; 248(2):662–9.
- Cantisani V, Grazhdani H, Ricci P, Morteale K, Di Segni M, D'Andrea V, et al. Q-elastasonography of solid thyroid nodules: assessment of diagnostic efficacy and interobserver variability in a large patient cohort. *Eur Radiol*. 2014; 24(1):143–50.
- Cantisani V, Lodise P, Grazhdani H, Mancuso E, Maggini E, Di Rocco G, et al. Ultrasound elastography in the evaluation of thyroid pathology. *Current status*. *Eur J Radiol*. 2014; 83(3):420–8.
- Bojunga J, Herrmann E, Meyer G, Weber S, Zeuzem S, Friedrich-Rust M. Real-time elastography for the differentiation of benign and malignant thyroid nodules: a meta-analysis. *Thyroid*. 2010; 20(10):1145–50.

## CONCLUSION

Elastography is a newly-developed and a very promising technique in the differentiation between benign and malignant lesions, especially when combined with standard echotomography examination in B mode. However, it is important that all of these newly-developed techniques are performed properly and with great attention because of their influence on the possible cancellation or reduction of unnecessary surgical procedures.

## ACKNOWLEDGEMENT

This work was supported by grant No. 175030 awarded by the Ministry of Education, Science and Technological Development of the Republic of Serbia.

## Значај компресионе еластографије у процени малигнитета чворова штитасте жлезде

Милош Гашић<sup>1</sup>, Сава Стајић<sup>2</sup>, Биљана Витошевић<sup>3</sup>, Предраг Мандић<sup>1</sup>, Јасмина Ћирић<sup>4,5</sup>, Дорентина Беџети<sup>6</sup>, Милан Милисављевић<sup>5</sup>, Здравко Витошевић<sup>1</sup>

<sup>1</sup>Универзитет у Приштини, Институт за анатомију, Медицински факултет, Косовска Митровица, Србија;

<sup>2</sup>Клиничко-болнички центар „Др Драгиша Мишовић – Дедиње“, Служба за радиолошку дијагностику, Београд, Србија;

<sup>3</sup>Универзитет у Приштини, Факултет за спорт и физичко образовање, Катедра за медицинске предмете, Лепосавић, Србија;

<sup>4</sup>Клинички центар Србије, Клиника за ендокринологију, дијабетес и болести метаболизма, Београд, Србија;

<sup>5</sup>Универзитет у Београду, Медицински факултет, Београд, Србија;

<sup>6</sup>Државни универзитет у Тетово, Факултет медицинских наука, Тетово, Македонија

### САЖЕТАК

**Увод/Циљ** Компресиона еластографија је нов начин ултразвучног прегледа за који се очекује да са већом поузданошћу разликује доброћудне од злоћудних промена не само у штитастој жлезди него и другим органима.

Циљ овог истраживања је да проценимо значај ултразвучне еластографије у разликовању бенигну и малигну чворова штитасте жлезде.

**Метод** Ултразвучне прегледе у Б моду и компресиону еластографију обавили смо код 186 особа (152 женског пола и 34 мушког пола, са  $45,3 \pm 13,5$  година живота), са 264 чвора у штитастој жлезди. Еластографију смо радили у два корака – најпре смо одредили степен растегљивости (еластичности) ткива, приказаног као колорна мапа, а потом, упоређујући са околним ткивом, одредили индекс еластичности (ИЕ).

**Резултати** Користећи скорове еластографије према Фукунари, 44 од 60 малигну чворова имало је скор 3–4, док је

152 од 204 бенигна чвора имало скор 1–2. Анализом пријемне карактеристике, најбоља гранична тачка добијена коришћењем скорова еластографије је 2, са сензитивношћу 73,3% и специфичношћу 74,5%. Користећи софтверски израчунат ИЕ, од 89 чворова са  $ИЕ \geq 2,5$  било је 52 малигну нодуса, док је од 175 нодуса са  $ИЕ < 2,5$  било чак 167 бенигну чворова. Користећи пријемну анализу, најбоља гранична тачка добијена коришћењем индекса отпора је  $> 2,5$ , са сензитивношћу од 86,7% и специфичношћу 81,9%.

**Закључак** Придružена стандардном ултразвучном прегледу, компресиона еластографија пружа нову могућност која обећава поузданије разликовање бенигну од малигну промена.

**Кључне речи:** компресиона еластографија; чвор; штитаста жлезда; малигност