

CASE REPORT / ПРИКАЗ БОЛЕСНИКА

Recurrence of a small primary iris stromal cyst following treatment with Nd:YAG laser photodisruption in an adult

Svetlana Stanojlović^{1,2}, Sanja Petrović-Pajić², Bojana Dačić-Krnjaja^{1,2}, Dejan Rašić^{1,2}, Miloš Jovanović^{1,2}¹University of Belgrade, Faculty of Medicine, Belgrade, Serbia;²Clinical Center of Serbia, Clinic of Eye Diseases, Belgrade, Serbia

SUMMARY

Introduction Primary acquired iris stromal cyst is rare in adults. In this group, they are generally stable lesions which require no treatment.

Case outline We describe a rare case of a small primary iris cyst in a 39-year-old patient, associated with unusual signs of irritation. Ultrasound biomicroscopy demonstrated iris stromal cyst measuring 3 × 2 mm. A neodymium-doped yttrium aluminium garnet (Nd:YAG) laser cystotomy was engaged as the least invasive treatment approach. However, the cyst recurred soon after repeated laser treatment and sector iridectomy with excision of the cyst was performed. Five years after surgery there was no evidence of recurrence.

Conclusion Although more benign clinical course of primary stromal iris cyst is generally assumed in adults as compared to children, complete cyst removal seems to be mandatory for preventing cyst recurrence regardless of the cyst size or patient age. To the authors' knowledge this is the first documented report of Nd:YAG laser photodisruption of acquired primary iris stromal cyst in an adult.

Keywords: primary iris stromal cyst; laser cystotomy; treatment

INTRODUCTION

Primary iris stromal cyst is uncommon unilateral lesion, usually presenting in the first few years of life [1]. Acquired primary iris stromal cysts in adults are extremely rare [2]. Most of these lesions behave in a benign fashion. Only a few cases in which rapid growth of iris stromal cyst required treatment have been described in adults.

Here we present a rare case of a small iris stromal cyst in an adult, associated with unusual symptoms. The aim is to present our experience in treating this kind of cyst and to determine the outcome of minimally invasive treatment approach using Nd:YAG laser.

CASE REPORT

Here we present a case of a 39-year-old man with a six-month history of tearing and redness of the left eye. There was no history of trauma or previous intraocular surgery. Visual acuity was 20/20 in both eyes, but the patient nevertheless complained about strong irritation associated with epiphora and photophobia, which interfered with his daily and particularly working activities. Intraocular pressure was within normal range. Slit-lamp examination of the left eye revealed a transparent inferior midzonal iris cyst (Figure 1). The cyst wall was opposite the corneal endothelium; however, there was no corneal edema. The right eye and the

remaining clinical examination were normal. Ultrasound biomicroscopy confirmed the presence of a midzonal stromal iris cyst measuring 3 × 2 mm with corneal touch (1.78 mm). There was no secondary angle closure. The posterior iris epithelium was intact (Figure 2).

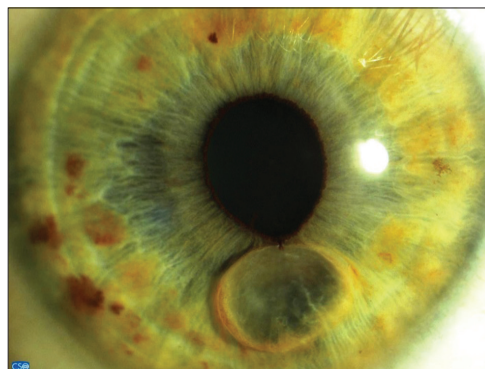


Figure 1. Clinical photograph of a small primary acquired iris stromal cyst at presentation

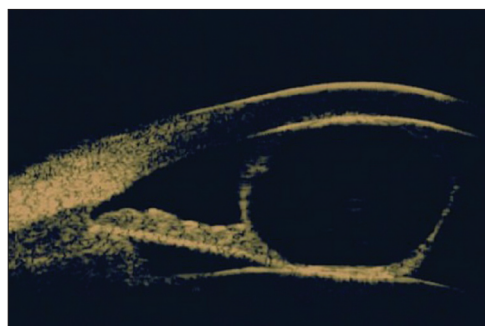

Figure 2. Ultrasound biomicroscopy showing the cyst extending into iris stroma

Received • Примљено:
September 6, 2016

Revised • Ревизија:
November 16, 2016

Accepted • Прихваћено:
December 22, 2016

Online first: March 14, 2017

Correspondence to:

Svetlana STANOJLOVIĆ
Jurija Gagarina 73
11000 Belgrade, Serbia
stanojlovic.svetlana@gmail.com

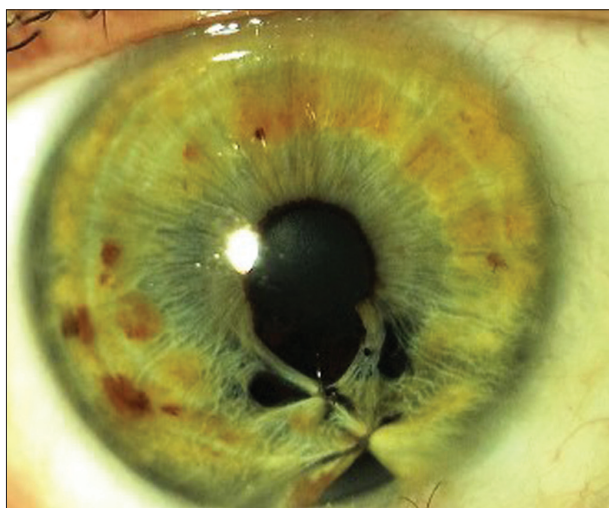

Figure 3. Clinical photograph showing the eye after surgical excision of the cyst

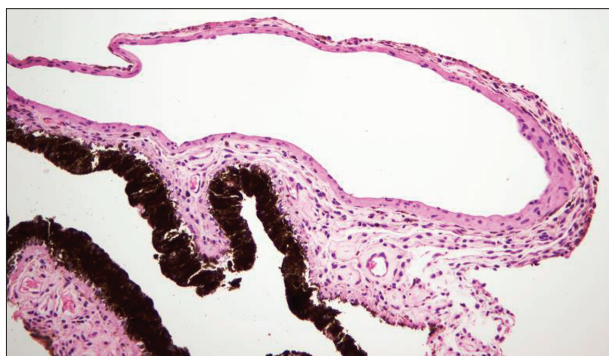

Figure 4. Histopathology of excised tissue demonstrating intrastromal iris cyst (H&E, $\times 200$)

Short course of steroid drops, 0.1% dexamethasone four times a day for four weeks, was ineffective in reducing signs and symptoms of irritation. Considering slow progressive growth of the iris stromal cyst, long-term consequences of steadily enlarging corneal endothelial touch surface as well as significant irritation of the left eye affecting the quality of life of this patient, we decided to perform laser photodisruption with cyst deflation, as the first step of the procedure. Nd:YAG laser puncturing of the cyst wall was done at a setting of 1.9 mJ for a total of five spots. The cyst collapsed and fluid leaked out in the anterior chamber. Postoperative medication included topical steroids and antibiotics four times a day for two weeks. However, at three weeks of follow-up, the cyst recurred and more extensive Nd:YAG laser photodisruption of the entire anterior cyst wall was carried out.

One month later, the cyst again recurred and surgical excision was performed. Intraoperatively, a limbal incision was made extending slightly longer than the diameter of the cyst. The anterior cyst wall was separated from the corneal endothelium by gentle viscoelastic dissection. Iris resection, including entire cystic lesion and iridoplasty, was performed (Figure 3). Postoperative uncorrected visual acuity was 20/20 and intraocular pressure measured 18 mmHg.

Histopathology showed the intrastromal (not epistromal) iris cyst lined by a nonkeratinizing stratified epithel-

ium (two to three layers of cubic epithelial cells), a cellular layer resembling conjunctival or corneal epithelium. No intraepithelial goblet cells were found. Superficial iridial stroma was stretched/rarefied. No superficial or deep lymphoplasmocytic infiltrate was found around the cyst. Posterior iris epithelial layers were intact (Figure 4). Five years after surgery, the clinical findings remained stable and there was no evidence of recurrence.

DISCUSSION

Primary iris stromal cyst is uncommon [1, 3]. Recently, Shields et al. [4] presented data on 3,680 iris tumors managed over a 36-year period. In this study, only 3% of cases were cystic tumors originated from iris stroma. Of the 96 iris stromal cysts, congenital iris stromal cyst was most common in children (71%, 25/35 cases) and acquired stromal cyst was most common in senior adults (19/49 cases, 39%) [4]. Primary iris stromal cysts are rarely seen in adults [2]. These kinds of cysts are larger in children (mean size of 7.8 mm) than in teenagers and adults (mean size of 4.7 mm). Overall, associated findings are more common in children than in the latter group requiring treatment in the majority of cases (88%). On the other hand, primary iris stromal cysts in adolescents and adults necessitated intervention in only two cases (25%) [2].

Here, we presented an unusual case of a relatively small primary acquired iris stromal cyst (the largest base of the cyst was 3 mm), in an adult patient, associated with signs of irritation, epiphora, and a slow progressive enlargement. Management strategy of such iris cysts is not clearly defined. Treatment approach is generally based on the anticipated cyst complications to the eye and its effect on visual acuity [5]. Different treatment approaches have been advocated, including excision, needle aspiration, cryotherapy, injection of chemical substances, treatment with argon laser, and a combination of these modalities. However, recurrences are common, mainly due to incomplete cyst excision.

Interestingly, Nd:YAG laser cystotomy, as a simple and effective treatment, has been reported in two children [6]. In these cases the cyst wall collapsed without complications and remained free of recurrences during the one year follow-up period. In iris stromal cysts diagnosed later in life, more favorable prognosis has been observed. Spontaneous collapse of this kind of cysts has also been described [7]. Thus, owing to persistent irritation, we decided to use Nd:YAG laser for puncturing the cyst wall, as the least invasive treatment approach, for a small primary iris stromal cyst. However, due to the cyst recurrence three weeks afterwards, an extensive Nd:YAG laser photodisruption of the entire anterior cyst wall was carried out. Although less aggressive clinical course of stromal iris cyst is generally assumed in adults as compared to children, in our patient the cyst recurred soon after repeated laser treatment.

We believe that residual cyst epithelium overlying the iris surface was the source of an early cyst recurrence in our patient. This was also addressed in previous documented

recurrences in children [8, 9]. Therefore, surgical excision was performed and there was no complication or cyst recurrence during the five-year follow-up period.

In conclusion, contrary to the expected outcome, our conservative stepwise approach using Nd:YAG laser for a small primary iris stromal cyst in adulthood was unsuccessful.

In the view of here presented case as well as previous reports [10], it seems important to provide adequate treatment while the cyst is still small, since the recurrence rate is likely to be only a function of the adequacy of initial epithelial cyst removal regardless of the cyst size or patient age.

REFERENCES

- Shields JA. Primary cysts of the iris. *Trans Am Ophthalmol Soc.* 1981; 79:771–809.
- Lois N, Shields CL, Shields JA, Mercado G, De Potter P. Primary iris stromal cysts. A report of 17 cases. *Ophthalmology.* 1998; 105(7):1317–22.
- Paridaens AD, Deuble K, McCartney AC. Spontaneous congenital non-pigmented epithelial cysts of the iris stroma. *Br J Ophthalmol.* 1992; 76(1):39–42.
- Shields CL, Kancherla S, Patel J, Vijayvargiya P, Suriano MM, Kolbus E, et al. Clinical survey of 3680 iris tumors based on patient age at presentation. *Ophthalmology.* 2012; 119(2):407–14.
- Shields CL, Arepalli S, Lally EB, Lally SE, Shields JA. Iris stromal cyst management with absolute alcohol-induced sclerosis in 16 patients. *JAMA Ophthalmol.* 2014; 132(6):703–8.
- Gupta A, Pandian DG, Babu KR, Srinivasan R. Primary stromal iris cysts treated successfully with ab externo laser Nd:YAG photocoagulation. *J Pediatr Ophthalmol Strabismus.* 2010; 47:e1–4.
- Brent GJ, Meisler DM, Krishna R, Baerveldt G. Spontaneous collapse of primary acquired iris stromal cysts. *Am J Ophthalmol.* 1996; 122(6):886–7.
- Shen CC, Netland PA, Wilson MW, Morris WR. Management of congenital nonpigmented iris cyst. *Ophthalmology.* 2006; 113(9):1639.e1–7.
- Xiao Y, Wang YH, Niu GL, Gao M. Primary iris stromal cyst with rapid growth. *Optom Vis Sci.* 2009; 86(11):E1309–12.
- Casey M, Cohen KL, Wallace DK. Recurrence of iris stromal cyst following aspiration and resection. *J AAPOS.* 2002; 6(4):255–6.

Рецидив мале примарне стромалне цисте дужице код одрасле особе након фотодисрупције ласером Nd:YAG

Светлана Станојловић^{1,2}, Сања Петровић-Пајић², Бојана Дачић-Крњаја^{1,2}, Дејан Рашић^{1,2}, Милош Јовановић^{1,2}

¹Универзитет у Београду, Медицински факултет, Србија;

²Клинички центар Србије, Клиника за очне болести, Београд, Србија

САЖЕТАК

Увод Примарно стечена стромална циста дужице веома је ретка код одраслих особа. У овом добу то су стационарне лезије које не захтевају лечење.

Приказ болесника Описали смо један редак случај мале примарне цисте дужице праћене неуобичајеним знацима иритације код мушкарца старог 39 година. Ултразвучном биомикроскопијом приказана је стромална циста дужице величине 3 × 2 mm. Помоћу ласера *neodymium-doped yttrium aluminium garnet (Nd:YAG)* урађена је цистотомија, као најмање инвазиван терапијски приступ. Међутим, циста је рецидивирала у кратком временском периоду и после

поновљене ласерске интервенције, па је урађена ексцизија цисте са секторастом иридектомијом. Пет година после хируршке интервенције није било знакова рецидива цисте.

Закључак Мада се сматра да примарна стромална циста дужице има бенигнији клинички ток код одраслих особа у поређењу са децом, укљањање цисте у целини неопходно је у циљу превенције рецидива без обзира на њену величину или старост болесника. Према нашем сазнању, ово је први документовани приказ фотодисрупције ласером Nd:YAG примарно стечене стромалне цисте дужице код одрасле особе.

Кључне речи: примарна стромална циста дужице; ласерска цистотомија; терапија