

CASE REPORT / ПРИКАЗ БОЛЕСНИКА

Necrotizing soft tissue infection in pregnancy

Milica Nestorović¹, Goran Stanojević^{1,2}, Vanja Pecić¹, Branko Branković^{1,2}, Milan Radojković^{1,2}, Ljiljana Jeremić¹, Goran Stevanović^{2,3}¹Clinical Center of Niš, Clinic for General Surgery, Niš, Serbia;²University of Niš, Faculty of Medicine, Niš, Serbia;³Clinical Center of Niš, Clinic for Plastic and Reconstructive Surgery, Niš, Serbia**SUMMARY**

Introduction Necrotizing soft tissue infection (NSTI) is a life-threatening condition, characterized by widely spread necrosis of skin, subcutaneous fat, fascia and muscles. Treatment involves surgical debridement and broad-spectrum antimicrobial therapy. Mortality is still high due to diagnostic delays. NSTI is rare in general population, there are even less literature data of this condition in pregnancy. Timely diagnosis and therapy is crucial for outcome of these patients. Clinicians should have in mind NSTI in patients with perianal infections, especially in cases where immunosuppressive role of pregnancy is present.

Case outline We present a case of a 21-year-old pregnant woman with NSTI spreading from perianal region. The patient was admitted to hospital in the 31st week of otherwise healthy twin pregnancy one day after incision of perianal abscess. At admission she was examined by a gynecologist; vital signs were stable, laboratory results showed the presence of infection. She was referred for another surgical procedure and broad-spectrum antibiotics were prescribed. The next morning the patient complained of intense abdominal pain. Clinical exam revealed only discrete redness of the skin tender on palpation, crepitating. She was immediately referred to surgery. Intraoperative findings revealed massive soft tissue infection spreading up to the chest wall. Wide skin incisions and debridement were performed. The patient developed septic shock and after initial resuscitation gynecologist confirmed intrauterine death of twins and indicated labor induction. Over the next few days the patient's general condition improved. On several occasions the wounds were aggressively debrided under general anesthesia, which left the patient with large abdominal wall defect. Twenty-three days after the initial operation, the defect was reconstructed with partial-thickness skin grafts, providing satisfactory results.

Conclusion Diagnosis and outcome of NSTI are challenging for many reasons. Course of the disease is rapid and hidden. Chances of survival depend on early recognition and prompt treatment.

Keywords: necrotizing soft tissue infection; necrotizing fasciitis; pregnancy

INTRODUCTION

Necrotizing soft tissue infection (NSTI) is a life-threatening condition, characterized by widely spread necrosis of skin, subcutaneous fat tissue, fascia and muscle [1]. In literature, it is also often referred to as necrotizing fasciitis (NF), or Fournier's gangrene, which is only one of the forms of necrotizing infection of soft tissues. Its diagnosis and outcome are challenging for many reasons. The course of the disease is rapid and hidden, and its rarity further complicates diagnosis and onset of treatment. Even in cases with optimal treatment, morbidity and mortality can be as high as 35% [2]. Of around 28 million patients in the NIS database (Nationwide Inpatient Sample of the Healthcare Cost and Utilization Project) in the US only, 0.04% were identified as having a NSTI [3]. Chances of survival depend on early recognition and prompt treatment. Because of the importance of early diagnosis, primary care physicians need to maintain high index of suspicion for these infections and should be aware of possible presenting features [4]. There are less data in literature on NSTI in pregnancy. Timely diagnosis and therapy is crucial for the outcome. Clinicians should have in

mind NSTI in patients with perianal infections, especially in cases where immunosuppressive role of pregnancy is present.

CASE REPORT

A 21-year-old woman was admitted to hospital in the 31st week of otherwise healthy spontaneously conceived twin pregnancy, which was regularly checked, according to the patient. Past medical and family history was unremarkable. She was referred from the regional hospital one day following incision of perianal abscess at the right side. Complaints started seven days prior to admission, described as discomfort and edema around the anus. She denied any recent trauma. Antibiotics were prescribed, but since there was no improvement, after four days she was hospitalized in the regional hospital for perianal abscess. An incision was performed under local anesthesia.

At admission, obstetrics ultrasonography examination confirmed living intrauterine fetuses of 31 weeks gestational age. The patient's vital signs were stable, body temperature was normal, laboratory results showed following

**Примљено • Received:**

May 19, 2016

Ревизија • Revised:

September 6, 2016

Прихваћено • Accepted:

October 11, 2016

Online first: March 3, 2017**Correspondence to:**

Milica NESTORVIĆ
Clinic for General Surgery, Clinical
Center of Niš
Bul. Zorana Đinđića 48
18000 Niš, Serbia
milica20@yahoo.com

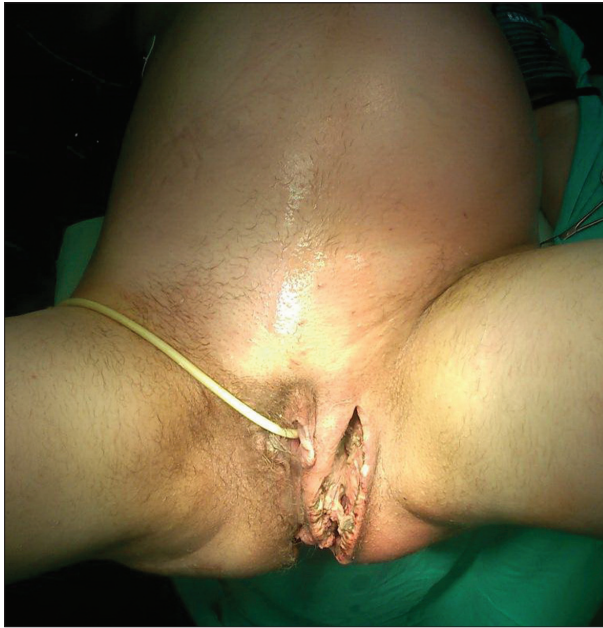

Figure 1. Clinical presentation prior to surgery

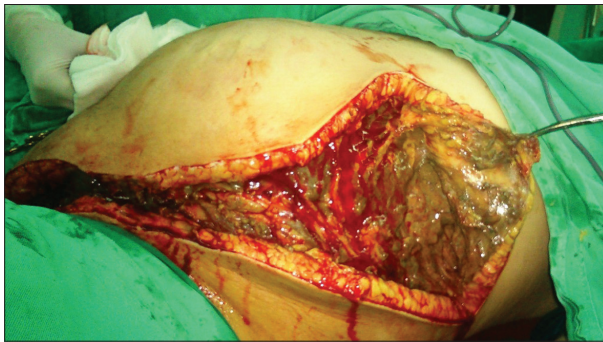


Figure 2. Intraoperative finding

abnormalities: white blood cell count 8.5, red blood cell count 2.88, hemoglobin 75 g/l, hematocrit (HCT) 26.9%, C-reactive protein (CRP) 294.2 mg/l, total protein 43.7 g/l, albumin 17.4 g/l. Clinical examination revealed an incision on the right side of the anus with secretion of small amounts of pus, with signs of cellulitis on the left side spreading up toward the left vulva area. Due to unsatisfactory clinical finding, the patient was referred to another surgical procedure the same day. After incision, antibiotics were prescribed (meropenem 1 g / 8 hours and ampicillin 1 g / 8 hours), as well as paracetamol and fluids in consultation with gynecologist. During the morning round, the patient complained on intense abdominal pain. Body temperature was still normal. Clinical examination revealed only discrete redness of the skin which was tender on palpation and crepitating (Figure 1). She was immediately referred to surgery, since NSTI was suspected. Intraoperative findings revealed massive soft tissue infection spreading from left perineal region up to the chest wall, predominantly on the left side (Figure 2). Wide skin incisions and excisions followed by necrectomy and debridement to the anterior abdominal wall were performed. Septic shock developed immediately, requiring mechanical ventilation in the postoperative course. The patient was hypo-

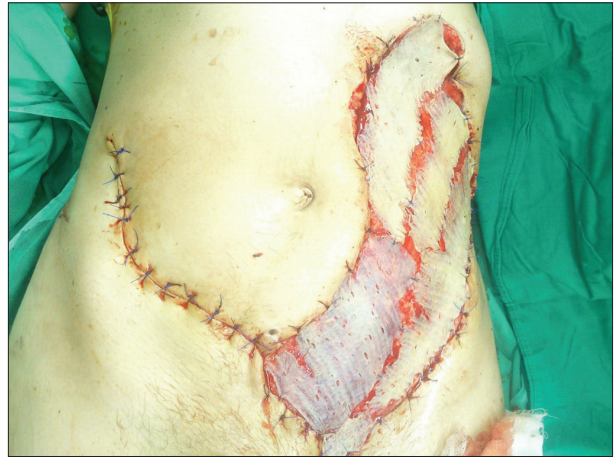

Figure 3. Abdominal wall reconstruction with partial-thickness graft

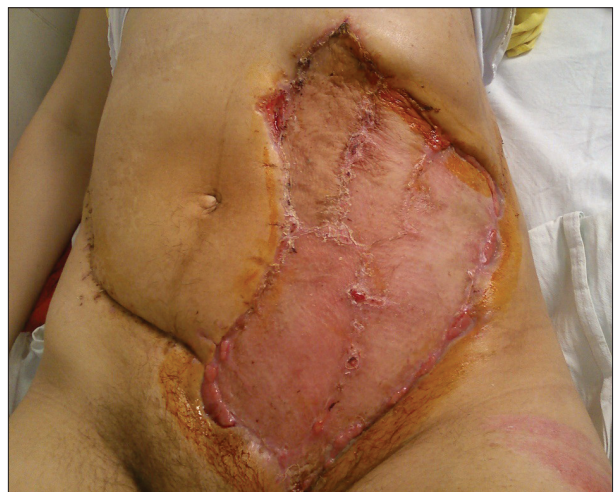

Figure 4. Abdominal wall at hospital discharge

tensive (80/40 mmHg), with heart rate of 128 beats/min., and arterial blood gas confirmed metabolic acidosis. Laboratory results showed hemoglobin to be 62 g/l, HCT 18%, total protein 35.1 g/l, albumin 12.5 g/l, CRP 206.7 mg/l, while body temperature rose to 38.6°C. After initial resuscitation, one day after admission, the gynecologist confirmed intrauterine death of twins based on ultrasonography and indicated labor induction. Over the next few days the patient was treated in the intensive care unit with broad-spectrum antibiotics, and her general condition improved. Wound dressing was performed at least twice a day. Wound cultures identified *Acinetobacter* spp. and *Enterococcus faecalis*, and antibiotic therapy was modified accordingly. On the seventh postoperative day, mechanical ventilation was no longer needed. On several occasions the wounds were aggressively debrided under general anesthesia, which left the patient with a large abdominal wall defect. After stabilization, she was referred to the Clinic for Plastic and Reconstructive Surgery for the further treatment. Twenty-three days after the initial operation, the skin defect was reconstructed with partial-thickness skin grafts (Figure 3). Eleven days post transplantation, the results were satisfactory. She was discharged from the hospital 44 days after admission (Figure 4).

DISCUSSION

According to the largest published retrospective population-based cohort study from Texas, USA, in a 10-year period (2001–2010) there were 4,060,201 pregnancy-associated hospitalizations, of which 148 were due to necrotizing infection. Only a minority of women (17.6%) were reported to have chronic comorbid conditions, of which diabetes mellitus was the most common one (50%). Drugs and tobacco abuse were rare, while obesity was reported in 22.3% [5]. Published data on NSTI in the general population show that 52.7–82% have at least one risk factor like diabetes mellitus or immunodeficiency of various degrees [6, 7, 8]. In a systematic review of Angoules et al. [9], diabetes mellitus was a predominant risk factor in 31%, smoking in 27%, alcoholism in 17%, cirrhosis in 8%, HIV in 6%, various stages of malignancy in 3%, corticosteroid therapy and chronic kidney insufficiency in 3% of NSTI cases. In this case, the patient's past medical history was unremarkable, suggesting that pregnancy might be as risk factor for necrotizing infection. We found only one similar case report on NSTI in pregnancy published in the English language, presenting a 15-year-old primigravid in the 29th week of pregnancy [10], since the majority of necrotizing infections related to pregnancy appears during the postpartum period (82.4%) [5]. In the presented case report by Nikolaou et al. [10], diabetes was diagnosed incidentally at the time of hospital admission. In addition to diabetes mellitus, pregnancy was suggested as a risk factor for necrotizing infection due to suppression of immune system during the second and third trimester and in postpartum period. This argument should be carefully considered since pregnancy is not a state of generalized immunosuppression, but instead, immune response is modulated in both systemic and, more effectively, local manner, which is focused on the maternal–fetus interface [11].

The course of NSTI varies, is often deceitful, and 35% of patients are initially misdiagnosed. The beginning ailment may suggest many other conditions, e.g., cellulitis, erysipelas, phlebitis, etc. [12]. A cardinal early symptom is disproportionately strong pain in comparison to clinical finding at examination. In a publication by Goh et al. [13], in nine studies, swelling was the most common presenting symptom (80.8%), followed by pain (79%) and erythema (70.7%). Initial finding in this case was not suggestive of NSTI, but rather of perianal abscess of cryptoglandular etiology, with one distinction – unusually intensive pain. In a previously mentioned case report, the diagnosis was established on the third day of hospitalization after unsuccessful treatment with incision and antibiotics, and after magnetic resonance imaging (MRI) confirmation [10]. According to data from literature, imaging techniques could be useful. Ultrasound or plain X-ray cannot reliably detect NSTI. Fascial thickening on T2-weighted MRI has a sensitivity of 90–100%, but a specificity of only 50–85% for NSTI. Computerized tomography should be considered as a diagnostic aid only when it can be obtained very quickly, having in mind that it may miss one in five cases

of deep NSTI. Macroscopic findings seem to be most reliable, those such as pasty gray necrotic tissue, thin purulent fluid with a gray-brown “dishwater” appearance, a lack of resistance to digital pressure against fascial planes (the finger test), a generalized lack of bleeding, visibly thrombosed vessels, and/or muscle that does not contract to electrocautery stimulation [2]. Although diagnosis of NF is clinical, it is often delayed, because the infection begins and progresses in the deep layers of subcutaneous tissues, giving initially a false impression of a typical cellulitis [14]. Meanwhile, infection spreads quickly, with the speed of 2–3 cm per hour in the anorectal region, as seen in this case – in less than 24 hours, infection spread more than 50 cm, from perianal region to the anterior chest wall [6, 15].

The treatment of NSTI implies wide incisions and excisions of the affected region, operative debridement, tissue decompression, and the use of broad-spectrum antibiotics.

Historical data report that the exclusive use of antibiotics leads to 100% mortality, indicating the necessity of surgical intervention, which substantially decreased mortality [7]. Timely intervention is probably more important. Multiple studies confirmed that mortality is increased when surgical treatment is delayed, as well in cases in which repeated excisions are needed [16]. According to Gallup et al. [17], any patient with inordinate pain and unilateral edema in the pelvis, especially in the puerperium, should be suspected of necrotizing infection. The triad of pelvic pain, edema, and any sign of septicemia carries an extremely grave prognosis and mandates immediate surgical intervention.

In the present case, rapidly progressive infection, treatment delay, and development of septic shock unfortunately led to intrauterine death. In another reported case by Nikolaou et al. [10], necrotizing infection caused preterm delivery of viable male fetus weighing 1,470 g by normal labor despite tocolytic therapy. The baby died due to septicemia after 48 hours. Described complications of sepsis during pregnancy are increased rates of premature births, fetal infection, hypoxia and acidosis, higher fetal mortality, and increased probability for cesarean section. In the obstetric context, the assessment of fetal vitality has particular relevance, as the balance between fetal oxygen supply and consumption might be severely altered. No study has yet analyzed the best approach for fetal vitality assessment under this circumstance [18]. The best approach to ensure fetal vitality is to stabilize the mother's condition. The base treatment, which also applies to pregnant women with sepsis, is provided by the therapeutic guidelines based on the Surviving Sepsis Campaign [19]. The aim of initial hemodynamic resuscitation is to restore tissue perfusion to an adequate level and to ensure that cell metabolism and oxygen supply return to normal levels to avoid acidosis and consequent multiorgan dysfunction. In pregnancy, one further aim of initial hemodynamic resuscitation is to improve fetal vitality [18, 19].

Empirically selected antibiotics must be initiated immediately. A wide variety of pathogens has been reported to be responsible for NSTI. The recent clinical classification

distinguishes the following four types: type I (70–80%, polymicrobial/synergistic) as in this case, type II (20% of cases; usually monomicrobial), type III (Gram-negative monomicrobial, including marine-related organisms), and type IV (fungal) [16].

After massive debridement and repeated surgery like in the case presented here, the patient is left with defect. When primary closure is not possible, soft tissue reconstruction can be considered, after the stabilization of the patient. Usually, it's been performed using skin grafts and myocutaneous flaps, as in burn reconstructions. In cases with excessively large amounts of soft tissue involvement (> 25% body surface area), autograft reconstruction may be restricted by the limited donor-site availability [20].

REFERENCES

1. Khwaja HA, Zakaria R, Wilde JM. Necrotising fasciitis of the lower limb due to diverticular disease of the sigmoid colon. *Int J Colorectal Dis.* 2010; 25(9):1145–46.
2. Shiroff AM, Herlitz GN, Gracias VH. Necrotising soft tissue infection. *J Intensive Care Med.* 2014; 29(3):138–44.
3. Endorf FJW, Klein MB, Mack CD, Jurkovich GJ, Rivara FP. Necrotizing soft-tissue infections: differences in patients treated at burn centers and non-burn centers. *J Burn Care Res.* 2008; 29(6):933–8.
4. Headley AJ. Necrotizing soft tissue infections: a primary care review. *Am Fam Physician.* 2003; 68(2):323–8.
5. Oud L, Watkins P. Necrotizing fasciitis associated with pregnancy: a population-based cohort study. *Infect Dis Ther.* 2014; 3(2):307–20.
6. Martinschek A, Evers B, Lampl L, Gerngroß Hb, Schmidt R, Sparwasser C. Prognostic aspects, survival rate, and predisposing risk factors in patients with Fournier's gangrene and necrotizing soft tissue infections: evaluation of clinical outcome of 55 patients. *Urol Int.* 2012; 89(2):173–9.
7. Cheung JPY, Fung B, Tang WM, Ip WY. A review of necrotising fasciitis in the extremities. *Hong Kong Med J.* 2009; 15(1):44–52.
8. Cheng NC, Yu YC, Tai HC, Hsueh PR, Chang SC, Lai SY, et al. Recent trend of necrotizing fasciitis in Taiwan: Focus on monomicrobial *Klebsiella pneumoniae* necrotizing fasciitis. *Clin Infect Dis.* 2012; 55(7):930–9.
9. Angoules AG, Kontakis G, Drakoulakis E, Vrentzos G, Granick MS, Giannoudis PV. Necrotising fasciitis of upper and lower limb: A systematic review. *Injury.* 2007; 38:S18–S25.
10. Nikolaou M, Zampakis P, Vervita V, Almaloglou K, Adonakis G, Marangos M, et al. Necrotizing fasciitis complicating pregnancy: a case report and literature review. *Case Rep Obstet Gynecol.* 2014; 2014:505410.
11. Adar T, Grisaru-Granovsky S, Ben Ya'acov A, Goldin E, Bar-Gil Shitrit A. Pregnancy and the immune system: general overview and the gastroenterological perspective. *Dig Dis Sci.* 2015; 60(9):2581–9.
12. Hady HR, Mikucka A, Golaszewski P, Trochimowicz L, Puchalski Z, Dadan J. Fatal necrotizing fasciitis following two suicide attempts with petroleum oil injection. *Langenbecks Arch Surg.* 2011; 396(3):407–13.
13. Goh T, Goh LG, Ang CH, Wong CH. Early diagnosis of necrotizing fasciitis. *Br J Surg.* 2014; 101(1):e119–e125.
14. Wronski M, Slodkowski M, Cebulski W, Karkocha D, Krasnodebski IW. Necrotizing fasciitis: early sonographic diagnosis. *J Clin Ultrasound.* 2011; 39(4):236–9.
15. Mishra SP, Singh S, Gupta SK. Necrotizing Soft tissue infections: Surgeon's prospective. *Int J Inflam.* 2013. 2013:609628.
16. Morgan MS. Diagnosis and management of necrotizing fasciitis: a multiparametric approach. *J Hosp Infect.* 2010; 75(4):249–57.
17. Gallup DG, Freedman MA, Meguiar RV, Freedman SN, Nolan TE. Necrotizing fasciitis in gynecologic and obstetric patients: a surgical emergency. *Am J Obstet Gynecol.* 2002; 187(2):305–10.
18. Cordioli RL, Cordioli E, Negrini R, Silva E. Sepsis and pregnancy: do we know how to treat this situation? *Rev Bras Ter Intensiva.* 2013; 25(4):334–44.
19. Dellinger RP, Levy MM, Rhodes A, Annane D, Gerlach H, Opal SM, et al. Surviving Sepsis Campaign: international guidelines for management of severe sepsis and septic shock, 2012. *Crit Care Med.* 2013; 39(2):165–228.
20. Bernal NP, Latenser BA, Born JM, Liao J. Trends in 393 necrotizing acute soft tissue infection patients 2000–2008. *Burns.* 2012; 38(2):252–60.

CONCLUSION

Necrotizing soft tissue infection is a rapidly progressive, life-threatening condition that requires early aggressive treatment. Clinical findings on presentation are crucial for diagnosis. It should be suspected in pregnancy and postpartum period in cases with unusually intensive pain, local edema, and systemic signs of infection. Postponing treatment leads to septic shock with high mortality. The treatment is based on “source control” principle with aggressive surgical debridement, broad spectrum antibiotics, and resuscitation. In cases such as described above, the assessment of fetal vitality is relevant, demanding joint efforts of surgeon, obstetrician, and intensive care specialists.

Некротизирајућа инфекција меких ткива код труднице

Милица Несторовић¹, Горан Станојевић^{1,2}, Вања Печић¹, Бранко Бранковић^{1,2}, Милан Радојковић^{1,2}, Љиљана Јеремић¹, Горан Стевановић^{2,3}

¹Клинички центар Ниш, Клиника за општу хирургију, Ниш, Србија;

²Универзитет у Нишу, Медицински факултет, Ниш, Србија;

³Клинички центар Ниш, Клиника за пластичну и реконструктивну хирургију, Ниш, Србија

САЖЕТАК

Увод Некротизирајућа инфекција меких ткива (НИМТ) јесте по живот опасно стање које карактерише опсежна некроза коже, поткожног масног ткива, фасције и мишића. Лечење је хируршко уз антибиотике широког спектра. Морталитет је висок услед касног постављања дијагнозе. НИМТ је ретка у општој популацији и још ређа код трудница. На НИМТ се мора посумњати код перианалних инфекција, нарочито у трудноћи, као имunosупресивном стању.

Приказ болесника Приказан је случај двадесетједногодишње труднице са НИМТ која полази од перианалне регије. Примљена је у болницу у 31. недељи некомплицоване близначке трудноће, дан након инцизије перианалног абсцеса. На пријему је стабилних виталних параметара прегледана и од гинеколога. Лабораторијски налази указивали су на присуство инфекције. Урађена је још једна хируршка интервенција и укључени су антибиотици широког спектра. Следећег јутра болесница се жалила на јак бол у трбуху. Клинички на-

лаз је показао дискретно црвенило коже и њену повећану осетљивост, уз присуство крепитација. Индикувана је хитна операција и интраоперативно је нађена масивна инфекција меких ткива која се пружа до зида грудног коша. Изведене су широке инцизије уз дебридман. Болесница је развила септични шок и после иницијалне ресусцитације гинеколог је ехосонографски утврдио интраутерину смрт оба плода и индуковао порођај. Током наредних дана опште стање болеснице се поправило. У неколико наврата рађен је агресивни дебридман у условима опште анестезије, што је довело до великог дефекта предњег трбушног зида. Двадесет три дана после иницијалне операције дефект је реконструисан коришћењем кожног графта са задовољавајућим резултатом.

Закључак Дијагноза и преживљавање НИМТ зависе од времена постављања дијагнозе и почетка третмана, јер је ток болести брз и скривен.

Кључне речи: некротизирајућа инфекција; некротизирајући фасциитис; трудноћа