

## ORIGINAL ARTICLE / ОРИГИНАЛНИ РАД

# Oral complications in irradiated head and neck cancer patients – 3D conformal radiotherapy planning vs. 3D conformal radiotherapy planning with magnetic resonance fusion

Miroslav Latinović<sup>1</sup>, Milana Mitrić-Asković<sup>1</sup>, Olivera Ivanov<sup>1,2</sup>, Mićo Novaković<sup>1</sup>, Jelena Ličina<sup>1</sup><sup>1</sup>Oncology Institute of Vojvodina, Clinic for Radiotherapy, Sremska Kamenica, Serbia;<sup>2</sup>University of Novi Sad, Faculty of Medicine, Novi Sad, Serbia**SUMMARY**

**Introduction/Objective** The incidence of radiation-induced side effects in patients with head and neck (H&N) cancer depends on the planning technique and the irradiation dose, as well as primary tumor location within the H&N region.

The aim of our research is to establish the incidence of side effects in patients with H&N cancer treated with conformal radiotherapy planning with computed tomography (CT) or computed tomography fusion with magnetic resonance imaging (CT-MRI fusion).

**Methods** Prospective analysis was performed on 40 patients with oropharynx carcinoma and on 40 patients with larynx carcinoma prospectively followed after radiotherapy. Forty patients with H&N cancer were irradiated by using 3D conformal radiotherapy planning with CT, while other 40 patients were treated using 3D conformal radiotherapy planning with CT-MRI fusion. In all cases standard fractionation was used at 2 Gy per day, five days a week.

**Results** Of the total of 80 patients treated, 52 patients (52/80; 65%) reported a side effect and the incidence of complications was higher in patients irradiated with 3D technique planning with CT (31/52; 60% for 3D CT vs. 21/52; 40% for 3D CT-MRI;  $p = 0.02$ ). There were more complications in chemoradiotherapy group of patients than observed when only radiotherapy was used – 35/52 RT + HT vs. 17/52 RT (67%: 33% and  $p = 0.004$ ).

**Conclusion** 3D radiotherapy technique planned solely on the basis of CT is related to high incidence of toxicity, which significantly affects the quality of life of irradiated patients. 3D conformal radiotherapy planned with CT-MRI fusion reduces the incidence of oral complications. Following the example of developed countries, this technique should be considered as a standard method for irradiating patients with H&N cancer. Planning technique with fusion technique using MR imaging is more suitable for delivering higher doses to the tumor with fewer side effects.

**Keyword:** radiotherapy; head and neck; oral complications; CT-MRI fusion in radiotherapy planning

**INTRODUCTION**

The treatment of tumors in head and neck (H&N) region most commonly combines the use of surgery, radiotherapy and chemotherapy with radiotherapy being applied in more than 50% of cases [1].

According to the data of Cancer Registry of the Oncology Institute of Vojvodina in Sremska Kamenica, a total of 500 people suffered from H&N cancer in 2010 in the province of Vojvodina in Serbia, which makes around 4–5% of all malignant tumors registered that year [2].

This data fits well with the data of the International Agency for Research on Cancer (IARC), where H&N cancers make up 5% of all malignant tumors [3].

The frequency of oral complications during radiotherapy is high and studies show the frequency to be up to 40% [3].

Radiation-induced changes can be divided into two groups, based on the usual time of their occurrence: early or acute side effects that

are noted during or immediately after treatment, and late or chronic side effects, which develop months or years after the end of radiation therapy [4].

Xerostomia is the most frequent complication of irradiation in patients treated with conformal (3D) radiotherapy. About 64% of patients developed permanent xerostomia of a moderate to severe degree. The most pronounced changes are found in patients with laryngeal and oropharyngeal carcinoma due to its close proximity to major salivary glands. Irradiation changes the composition of saliva, leads to difficulties in maintaining oral hygiene and affects intake of cariogenic food and drinks [5, 6].

In addition to these, mucosal atrophy and fibrotic changes, radiation-related caries and bone necrosis occur as side effects of the treatment but are less frequent [7, 8].

With conventionally fractionated radical doses of radiotherapy, the first signs of mucositis usually appear already during the second week

**Примљено • Received:**  
June 1, 2016

**Ревизија • Revised:**  
December 28, 2016

**Прихваћено • Accepted:**  
January 12, 2017

**Online first:** March 3, 2017

**Correspondence to:**

Miroslav LATINOVIĆ  
Oncology Institute of Vojvodina  
Put doktora Goldmana 4  
21204 Sremska Kamenica  
Serbia  
[miroslavlatinovic@gmail.com](mailto:miroslavlatinovic@gmail.com)

of the treatment and advance towards the end of the treatment from the enanths to confluent forms of pseudo-membranous mucositis [9]. The recovery starts within 2.5–3 weeks after the end of radiotherapy, and within one month the mucosa is healed in about 90–95% of patients [10].

In addition, xerostomia predisposes infections and development of dental caries and it affects speaking and swallowing [11].

Because of the lack of saliva, the probability for development of radiotherapy-related complications is increased. In the first two weeks following the beginning of radiotherapy and received cumulative radiation tumor dose even at 20 Gy, around 80% of salivary function is changed [12].

The increase in acidogenic and cariogenic bacteria in the mouth (*Streptococcus mutans*, *Lactobacillus* and *Candida* species) together with the decrease in non-cariogenic microorganisms (such as *Streptococcus sanguis*, *Neisseria* and *Fusobacterium*) increase the risk of development of oral complications [12].

Significant weight loss and deterioration of the patient's nutrition status tend to aggravate because of the pain while chewing and swallowing. Radiotherapy also incurs loss of appetite, nausea, and physical discomfort. Loss of taste occurs and progressively increases at the received radiation tumor dose of about 30 Gy [13].

The characteristics of modern radiotherapy planning are increasingly used fusion techniques such as positron emission tomography – computed tomography (PET CT) and magnetic resonance imaging (MRI) fusion. The adequate soft-tissue contrast of MRI allows the technique to have an increasing role in contouring the gross tumor volume, organs at risk, which leads to the decreasing incidence of treatment complications [14].

Frequency of complications of radiotherapy in patients with H&N cancer is about 35% [15, 16].

The aim of this research is to perceive the possibilities of lowering the radiotherapy-induced toxicity in patients with H&N carcinoma in a setting of a developing country. This aim can be reached by using the transition between three-dimensional (3D) conformal radiotherapy planning with computed tomography (3D CT) and 3D conformal radiotherapy planning with CT fusion MRI (3D CT-MRI). Acute side effects that are analyzed were xerostomia, mucositis, and dermatitis. On the other hand, dental caries was observed as a chronic complication of radiotherapy. Those side effects (acute and chronic) were monitored three times during radiotherapy:

- (1) In the fifth week of radiotherapy, after the completion of the 25th fraction;
- (2) 30 days following the completion of radiotherapy, and
- (3) 90 days following the completion of radiotherapy.

Minimum two weeks prior to radiotherapy, initial (baseline) dental treatment (IDT) was performed, while medical examinations with documentation of complications and dental evaluation were done at every check-up. Radiotherapy complications were not monitored 90 days after the completion of radiotherapy.

## METHODS

This investigation was carried out at the Oncology Institute of Vojvodina in Sremska Kamenica, Province of Vojvodina, Serbia in the period between January 2013 and October 2014. The study included patients with diagnosed H&N cancer treated with radiotherapy. Eighty prospective patients participated in the study, 40 of whom were diagnosed with laryngeal carcinoma and 40 with oropharynx carcinoma. The main aim of the study was to compare the two most commonly applied methods of radiotherapy planning, 3D with CT and 3D conformal with fusion CT-MRI, in relation to the incidence of the appearance of complications.

The study included patients over the age of 18 years for whose treatment radiotherapy was indicated by the oncology consultant team. All the patients had good general status, Eastern Cooperative Oncology Group (ECOG) Scale of Performance Status 0 or 1.

Patients who for any reason failed to complete the prescribed radiotherapy, as well as those whose general status was poor, such as ECOG 2 or more, were excluded from consideration.

Prior to the radiotherapy, the participants had IDT performed. It was performed at least two weeks prior to radiotherapy and all the tooth lesions were identified and repaired. Teeth that could not be repaired had to be extracted. Clinical examination and dental evaluation was performed five weeks into the radiotherapy (i.e. after the completion of the 25th fraction). The second examination was performed 30 days and the third 90 days following the completion of radiotherapy.

## Radiation treatment

The patients were irradiated using two techniques: 3D conformal radiotherapy with CT and 3D conformal radiotherapy with fusion CT-MRI. The participants in the study were irradiated with a daily dose of 2 Gy, five days a week, with a curative radiotherapy tumor dose from 60 Gy to 70 Gy. Each patient was provided with a thermoplastic mask in order to immobilize the treated region and to deliver the radiation tumor dose more precisely.

3D conformal radiotherapy technique for oropharyngeal cancer includes tumor / tumor bed with margins of 2 cm and lymph node: N0 include levels II–IV and retropharyngeal lymph nodes (RPN), N1 include levels Ib–IV and RPN, N2–3 include Ib–V and RPN [17]. Radiation dose for adjuvant 3D radiotherapy for oropharyngeal cancer is 60 Gy (60 Gy to the preoperative tumor bed and 50 Gy to the lymph nodes with 2 Gy per day, five days a week).

For inoperable oropharyngeal cancer tumor radiation dose was 70 Gy (70 Gy on the tumor and involves lymph nodes and 50 Gy on elective lymph nodes with 2 Gy per day, five days a week) [18].

Curative 3D conformal radiotherapy technique for laryngeal cancer included primary tumor and any involved lymph nodes. Irradiation depended on laryngeal localization of the primary tumor. The levels that are included are

**Table 1.** Patient and tumor characteristics

Characteristics	3D-CT RT (total 40)	3D CT-MRI RT (total 40)	p
Age range (median)	54.7	52.9	
Gender (male:female)	31:9	28:12	0.61
ECOG (0:1)	26:14	24:16	0.82
Oropharynx	20	20	1
Supraglottic larynx	10	12	0.81
Glottic larynx	6	7	0.99
Subglottic larynx	4	1	0.36
T stage 1/2/3/4	3/8/17/12	8/12/15/5	0.11
N stage 0/1/2/3	7/13/16/4	12/20/7/1	0.04
RT	11	20	0.07
Concurrent RT + HT	29	20	0.07
Early stage T1–T2	3 + 8 = 11	8 + 12 = 20	0.07
Advanced stage T3–T4	17 + 12 = 29	15 + 5 = 20	0.07
Total dose 60 Gy	24	21	0.49
Total dose 70 Gy	16	19	0.49

ECOG – Eastern Cooperative Oncology Group; RT – radiotherapy; HT – chemotherapy

**Table 2.** Treatment-related toxicity

Toxicity	3D-CT RT (40 in total)	3D CT-MRI RT (40 in total)	p
Complications in total	31	21	0.02
<b>Acute complications (1, 2, 3)</b>	31	21	0.02
Acute complications RT vs. RT + HT	RT 10 RT + HT 21	RT 7; total = 17 RT + HT 14; total = 35	0.004
1. Xerostomia	27	13	0.002
Xerostomia (oropharyngeal/laryngeal)	16/11	8/5	
2. Mucositis	24	12	0.006
Mucositis (oropharyngeal/laryngeal)	17/7	8/4	
3. Dermatitis	10	14	0.46
Dermatitis (oropharyngeal/laryngeal)	4/6	7/7	
Grade 0–2 RTOG scoring criteria	17	15	0.64
Grade 3–4 RTOG scoring criteria	14	6	0.03
<b>Chronic complications (DC)</b>	15	7	0.04
DC (larynx)	4	1	0.16
DC (oropharynx)	11	6	0.14
Total dose 60 Gy	17	15	0.64
Total dose 70 Gy	14	7	0.07
Corticosteroid therapy	35	17	0.004

RT – radiotherapy; HT – chemotherapy; RTOG – Radiation Therapy Oncology Group; DC – dental caries

II–IV, level VI with subglottic tumors, and level V if > 1 node is involved in that side of the neck.

Curative dose for oropharyngeal and laryngeal cancer was 60 Gy. For locally advanced tumor the radiation dose was escalated up to 70 Gy.

Indication for chemoradiotherapy included advanced stage of the disease (T3, T4) and positive surgical margin and extranodal capsular extension.

Every day, the patients themselves made notes of subjective difficulties with skin, oral pain and the sense of (insufficient)

saliva. During the radiotherapy course, analgesic therapy was optionally included, as well as corticosteroid therapy when stronger pain appeared, and was left at the discretion of involved radiation oncologist.

A modified scale recommended by the Radiation Therapy Oncology Group (RTOG) was used for monitoring acute complications (xerostomia, mucositis, and dermatitis), specifically the part which relates to monitoring the complications of H&N region (RTOG acute radiation morbidity scoring criteria). In this classification, the acute complications are divided into a four-point scale [19]:

- 0 – no change;
- 1 – mild changes which demand no therapy;
- 2 – changes which demand symptomatic therapy and necessary analgesics;
- 3 – suffering which demands opioid analgesics, and
- 4 – changes which demand the termination of radiotherapy.

## RESULTS

Results were statistically analyzed using  $\chi^2$  and Fischer exact probability tests. There were 80 participants in the study – 59 men and 21 women. The ratio 3:1 in favor of men fits into the general trend of the incidence of this disease,  $p = 0.61$ . Age ranged 18–65 years, with the median age at presentation of 54.7 years in 3D CT and 52.9 in 3D CT-MRI radiotherapy. All the patients had ECOG 0–1,  $p = 0.82$  (Table 1).

The study involved 40 patients diagnosed with primary laryngeal carcinoma (22 patients with supraglottic localization tumor, 13 glottic, and 5 subglottic) and 40 with oropharynx carcinoma. The number of patients irradiated with 60 Gy and 70 Gy in both groups was nearly the same,  $p = 0.49$  (Table 1). According to  $p > 0.05$ , we concluded that the groups were homogeneous concerning the age, gender, ECOG performance, and tumor dose.

Fewer patients had early stages of the disease ( $n = 31$ ) while advanced stage disease was present in 49 patients. In advanced stages of the disease (T3 and T4), as well as with postoperative high risk (positive surgical margins and extranodal extension), concomitant radiotherapy and chemotherapy was used with 5-fluorouracil plus cisplatin (5FU/CDDP). Forty-nine patients with advanced stage of the disease were treated with chemoradiotherapy.

Twenty patients with laryngeal or oropharynx carcinoma were irradiated with 3D CT, the other group of 20 patients of both tumor localizations were treated with 3D CT-MRI conformal radiotherapy (2 Gy per fraction, 5 fractions a week, from 60 Gy to 70 Gy),  $p > 0.05$  (Table 1).

Of the total number of 80 irradiated patients, 52 of them (65%) reported a side effect of radiation therapy. Thirty-one patient was irradiated by using 3D CT, while 21 patient were irradiated by using 3D CT-MRI,  $p = 0.02$  (Table 2.). In this study  $p$  was  $< 0.05$ , which suggested that incidence of side effects in these groups was statistically significantly different.

Oropharyngeal mucositis developed in 36 out of 52 patients, being observed in 24 and 12 patients for the 3D

CT and 3D CT-MRI technique, respectively ( $p = 0.006$ ). Xerostomia was present in 40/52 irradiated patients, in oropharyngeal cancer 3D CT vs. 3D CT-MRI = 16:8, in laryngeal cancer 11/5 ( $p = 0.002$ ). According to the  $p$ , which was  $< 0.05$ , the incidence of complications was statistically higher in the group where radiotherapy was planned without fusion with MRI.

Skin changes on the face and neck during radiotherapy in the form of radiation dermatitis manifested in 24 patients, being observed in 10 and 14 patients for the 3D CT and 3D CT-MRI technique, respectively ( $p = 0.46$ ) (Table 2). Based on the results of the  $p$ , there was no statistical difference in incidence of the radiation dermatitis (3D vs. 3D-MRI). The reason could be the number of the radiation fields which in conformal technique was 4–10 [20].

Dental caries (DC) was identified in 22 out of 80 patients who were irradiated (Figure 1). It was identified in three patients during the radiotherapy, in eight patients 30 days following the completion of radiotherapy, and in 11 patients 90 days after radiotherapy (Figure 2).

It was observed that radiation-related caries appeared in 17 patients treated for primary oropharynx carcinoma, and in only five patients treated for primary laryngeal carcinoma (Table 2). According to the dose volume histogram, the coverage of the planning target volume was homogeneous with 95% tumor dose.

Caries was identified in 15 patients treated with conventional 3D CT radiotherapy and in seven patients treated with 3D CT-MRI conformal radiotherapy,  $p = 0.04$  (Table 2). Results in our study showed that incidence of dental caries was statistically more frequent if radiotherapy is planned only according to CT.

Regardless of the used treatment technique, acute complications were more common in chemoradiotherapy regi-

men (35/52 pts.) than in the application of radiotherapy alone (17/52 pts.), ( $p = 0.004$ ). This implies that in chemoradiation the incidence of side effects was statistically significantly higher than in radiotherapy without concomitant chemotherapy.

Fifty-two patients out of the total number of 80 examined and irradiated patients received some form of corticosteroid therapy during the period of radiation, 35 (67%) for 3D CT vs. 17 (33%) for 3D CT-MRI,  $p = 0.004$  (Table 2). The use of corticosteroid therapy in 3D conformal radiotherapy has been correlated with increased incidence of side effects.

Corticosteroid therapy was included as a symptomatic therapy with irradiated patients when non-steroidal analgesics could not eliminate the pain. Dexamethasone was usually used in the form of tablets with total daily dose of 1.5–3 mg per 24 hours or parenteral 4–12 mg per 24 hours.

Complications of radiation treatment grade 0, 1, and 2 which do not require interruption of radiotherapy or analgesics have the same incidence in both techniques,  $p = 0.64$ . Grades 3 and 4 have been statistically more frequent in patients treated with 3D CT technique,  $p = 0.03$ . There was no difference in incidence of side effects in either technique when the tumor dose was 60 Gy, while we noticed an increase in the 3D CT technique when the dose was 70 Gy,  $p = 0.07$ .

## DISCUSSION

Our study involved 80 patients of both genders. According to the results of the study the incidence of H&N cancer is higher in men than in women (59 M:21 W). The approximate ratio of 3:1 in favor of men corresponds to the general trend of incidence of this disease as shown in medical literature [21].

Complications of radiotherapy were observed in 65% of patients (52/80). In the literature, this percentage goes around 40%, and in our study it is higher, which can be explained by infrequent usage of planning radiotherapy based on computerized tomography with MRI fusion as well as fusion methods with PET-CT and intensity-modulated radiation therapy (IMRT) techniques [22].

Complications in the mucous membrane of the oral cavity in the form of radiation-related mucositis was registered in 36 out of 80 participants in the study, and approximately one half of the patients reported some kind of a problem. Although this complication was the most common, the manifestation of mucositis was mild (Grade 0–2: 32/52) and did not cause the interruption of radiotherapy [23]. Assessing our results we can conclude that there is statistically significant difference in the incidence of side effects if radiotherapy is planned using CT rather than using MRI fusion. This especially applies to the delivery of higher tumor dose of 70 Gy (3D CT : 3D CT-MR = 14:7;  $p = 0.07$ ).

Xerostomia appeared in 40 patients, which is one half of the irradiated patients. Xerostomia is one of the most common symptoms in cancer patients [24]. Based on the results we concluded that for delivery of higher tumor dose

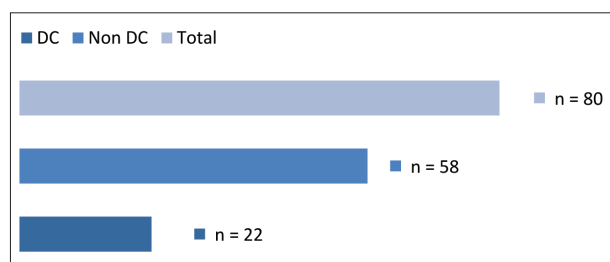


Figure 1. Distribution of dental caries (DC) in irradiated patients

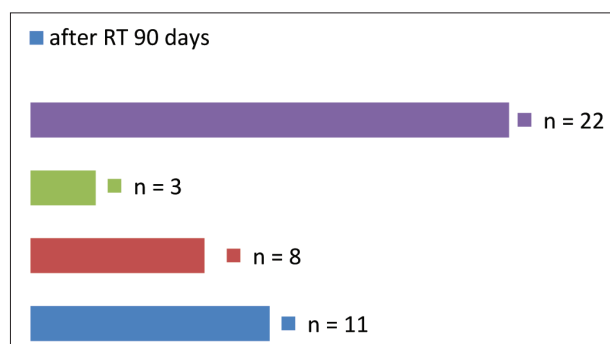


Figure 2. Distribution of dental caries at the first, second, and third patient medical examination and dental evaluation



with fewer side effects, the optimal radiation technique is planning with fusion MRI.

These patients often suffered from skin changes and complications. These changes were seen in 24 patients and are mainly manifested in the form of Grade 0–1 with the presence of skin erythema. Dermatitis more often occurred in the 3D CT-MRI technique because there was a larger number of fields (3D CT : 3D CT-MRI = 10:14) (Table 2). The level of manifestation of acute radiation complications (Acute Radiation Morbidity Scoring Criteria) in the form of radiation-related dermatitis was classified into four categories [19].

All 49 patients with negative prognostic factors (RT:RT + HT = 31:49) received radiotherapy concomitant with chemotherapy. Side effects were reported by 35 patients (35/49;  $p = 0.004$ ). According to this, the frequency of complications increase when chemotherapy is applied concomitant with radiotherapy.

In 22 out of a total of 80 patients dental caries was identified. As expected, radiation-related caries had higher incidence in patients treated for oropharyngeal (O) than in those treated for laryngeal (L) carcinoma (17:5 = O:L,  $p = 0.14$ ). Participation of supraglottic localization was the most frequent of all laryngeal carcinoma in our study (22/40; 55%). The likely reason for this could be the size of irradiated area and localization which encompasses large salivary glands. It was also found that 15 patients irradiated with 3D CT technique developed radiation-related caries. Such high incidence (15/40; 37.5%) of dental caries can be linked to the use of 3D CT planning and execution technique, which is in many centers already proven as inferior and, hence, outdated. Different studies explain the impact of irradiation on the composition of teeth in a different way. Some claim that the immediate effect of irradiation is demineralization and damage of the prismatic structure of tooth, while others argue that the exposure to radiotherapy does not change tooth structure and composition [25, 26].

Data regarding this topic is scarce in literature. The phase III study which compared side effects of 2D, 3D radiotherapy techniques and IMRT, did not give any detail on dental management and complications [27]. Using newer radiation techniques, 3D CT-MRI fusion and IMRT, protection of critical organs became possible and decreased the incidence of early and late complications of the irradiated areas of H&N.

In their study, Walker et al. [17] have proven that doses above 60 Gy cause irreversible changes in the structure of the teeth and induced dental caries development. Dose of 30–60 Gy is likely related to salivary gland damage. Critical threshold seems to be at the  $\geq 60$  Gy level, and these findings suggest that 3D treatment planning process should be carefully done respecting this dose level. All the patients in the present study received radiation doses of 60 Gy or 70 Gy, depending on the type of radiotherapy – adjuvant vs. primary treatment in locally advanced H&N cancer.

Caries risk was reduced in patients receiving parotid-sparing radiotherapy, where salivary output is largely maintained [17].

Late radiotherapy-related complications, such as post irradiation caries that were analyzed 90 days after radiation treatment, occurred in about 27.5% of cases as mentioned earlier (22/80; 27.5%). Some studies have shown higher incidence of radiation-related caries (around 35%), mostly in patients which were irradiated for nasopharyngeal carcinoma [16]. The favorable results of this study can be explained by a small number of patients and localization of irradiated areas, as well as by avoidance of irradiation of large salivary glands. It is obvious that direct effect of irradiation may not be solely responsible for the occurrence of dental caries, and that other factors such as hyposalivation, xerostomia, mucositis, loss of taste, and diet change may be present. This clearly confirms multifactorial genesis of radiation-related caries [28].

New radiotherapy techniques make possible for the radiation dose to be localized to a smaller volume of mandible, which will certainly result in lower incidence of oral complications and radiation-related caries [29]. However, despite the expectations of lower incidence of oral complications, some authors claim that there is no great benefit to this. Ben-David et al. [30] claim that the daily intake of fluoride supplements up to 18 months following the completion of radiotherapy has a greater effect on reduction of oral complications.

Around 65% (52/80) of our patients received some form of corticosteroid therapy during radiation (Table 2). The combination of radiation-related complications with simultaneous application of corticosteroid therapy is very high in our patients and it is about 75%. Application of corticosteroid therapy during radiation and its impact on the increase of incidence of complication is not well understood in the literature [31]. Unreasonably frequent application of corticosteroid therapy is present and it can certainly affect the patient's immune system and the composition of saliva. It can also be related to a higher rate of oral complications during radiotherapy.

The pain is certainly not an absolute indication for the use of these medications, and the therapy should be directed to analgesic therapy and cancer pain therapy in the form of non-opioid and opioid analgesics as well as coanalgesics. Further recommendations for research would certainly include the effect of corticosteroid systematic therapy on the development of radiation-related complications.

Finally, it is worth saying that direct effect of radiation is not the sole factor in occurrence of oral complications and radiation-related caries. The complications that have been researched have a multifactorial genesis and depend on composition and quantity of saliva, bacterial colonization, age, dental hygiene and fluoride intake [32]. Minimizing the use of corticosteroid therapy has also been associated with the decrease in incidence of oral complications. Studies involving patients who were not irradiated also document the occurrence of secondary caries, which supports the finding that direct effect of radiotherapy is not the only causal factor in the occurrence of dental caries [21]. The use of IMRT can certainly reduce the incidence of radiotherapy complications in H&N cancer [32, 33].

## CONCLUSION

3D radiotherapy planning techniques with computed tomography are associated with a high rate of toxicity, which affects patients' quality of life. In our study, 3D CT-MRI radiotherapy reduced the incidence of radiation-related oral complications. The experience of institutions of developed countries, based on fusion techniques in radio-

therapy planning, shows successful decrease of side effect incidence. This benefit should be included in the clinical practice of radiotherapy planning in institutions of developing countries. Curative radiotherapy treatment methods should be planned with best available imaging techniques in the form of conformal techniques based on computerized tomography fusion with MRI alone or, whenever possible, using fusion with PET CT and/or IMRT.

## REFERENCES

- Thariat J, Ramus L, Darcourt V, Marcy PY, Guevara N, Odin G, et al. Compliance with fluoride custom trays in irradiated head and neck cancer patients. *Supp Care Cancer*. 2012; 20(8):1811–4.
- Cancer Registry of Vojvodina, Oncology Institute of Vojvodina, Sremska Kamenica, Serbia, (unpublished material), 2011.
- IARC-International Agency for research on cancer. (Accessed: July 22, 2013) Available from: <http://www.iarc.fr/>.
- Otmani N. Oral and maxillofacial side effects of radiation therapy on children. *J Can Dent Assoc*. 2007; 73(3):257–61.
- Silva AR, Alves FA, Antunes A, Goes MF, Lopes MA. Patterns of demineralization and dentin reactions in radiation-related caries. *Caries Res*. 2009; 43(1):43–9.
- Jham BC, da Silva Freire AR. Oral complications of radiotherapy in the head and neck. *Bras J Otorrinolaringol. (Engl Ed)*. 2006; 72(5):704–8.
- Sciubba JJ, Goldenberg D. Oral complications of radiotherapy. *Lancet Oncol*. 2006; 7(2):175–83.
- Lyons A, Ghazali N. Osteoradionecrosis of the jaws: current understanding of its pathophysiology and treatment. *Br J Oral Maxillofac Surg*. 2008; 46(8):653–60.
- Satheesh Kumar PS, Anita B, Arun S, Tinky B. Radiation Induced Oral Mucositis. *Indian J Palliat Care*. 2009; 15(2):95–102.
- Popa E, Pauna M, Stratul S-I, Ionita S. Cancer Therapy-Induced Oral Mucositis. A Review of Epidemiology, Patophysiology and Treatment. *Timisoara Med J*. 2008; 58(1–2):104–7.
- Citak E, Tulek Z. Longitudinal quality of life in Turkish patient with head and neck cancer undergoing radiotherapy. *Supp Care Cancer*. 2013; 21(8):2171–83.
- Livia BM, Fatima RNS, Helio MT, Alvimar LC, Elerson GJJ. Influence of preventive dental treatment on mutans streptococci counts in patients undergoing head and neck radiotherapy. *J Appl Oral Sci*. 2009; 17 Suppl:5–12.
- Cheng SCH, Wu VW, Kwong DL, Ying MT. Assessment of post-radiotherapy salivary glands. *Br J Radiol*. 2011; 84(1001):393–402.
- Metcalfe P, Liney GP, Holloway L, Walker A, Barton M, Delaney GP, et al. The potential for an enhanced role for MRI in radiation-therapy treatment planning. 2013; 12(5):429–46.
- Thariat J, de Mones E, Darcourt V, Poissonnet G, Marcy PY, Guevara N, et al. Teeth and irradiation: dental care and treatment of osteoradionecrosis after irradiation in head and neck cancer. *Cancer Radiother*. 2010; 14(2):137–44.
- Wicem S, Wafa M, Fatma E, Abdelmonnem G, Jammeleddine M, Mounir F, et al. Clinical studies, Late Toxicities after Conventional Radiotherapy for Nasopharyngeal Carcinoma: Incidence and Risk Factors. *J Radiother*. 2014; 8.
- Walker MP, Wichman B, Cheng AL, Coster J, Williams KB. Impact of Radiotherapy Dose on Dentition Breakdown in Head and Neck cancer Patients. *Pract Radiat Oncol*. 2011; 1(3):142–8.
- Eric KH, Mack R. *Handbook of Evidence-based radiation*. 2nd ed. Portland (Oregon, USA): Springer; 2010.
- Cox JD, Stetz J, Pajak TF. Toxicity criteria of the Radiation Therapy Oncology Group (RTOG) and the European Organization for Research and Treatment of Cancer (EORTC). *Int J Radiat Oncol Biol Phys*. 1995; 31(5):1341–6.
- Ahmad N, Attia G, El-Ghoneimy E, Radwan A, El-Badawy S. Conventional (2D) vs. conformal (3D) technique in radiotherapy for malignant pediatric tumors: dosimetric perspectives. *J Egypt Natl Canc Inst*. 2009; 21(3):309–14.
- Ferlay J, Shin HR, Bray F, Forman D, Mathers C, Parkin DM, eds. *Cancer Incidence and Mortality Worldwide: IARC Cancer base No 10 (internet)*. Lyon: International Agency for Research on Cancer. GLOBOCAN 2008. 2010. Available from: <http://globocan.iarc.fr>
- Moonkyoo K, Seong EH, Jinhun C, Youngkyong K. Comparison of survival rates between patients treated with conventional radiotherapy and helical tomotherapy for head and neck cancer. *Radiat Oncol J*. 2013; 31(1):1–11.
- Dheeraj K, Namrata R. Oral Complications and Its Management during Radiotherapy. *Int J Head Neck Surg*. 2011; 2(2):109–13.
- Hanchanale S, Adkinson L, Daniel S, Fleming M, Oxberry SG. Systematic literature review: Xerostomia in advanced cancer patients. *Supp Care Cancer*. 2015; 23(3):881–8.
- Silva AR, Alves FA, Berger SB, Giannini M, Goes MF, Lopes MA. Radiation-related caries and early restoration failure in head and neck cancer patients. A polarized light microscopy and scanning electron microscopy study. *Supp Care Cancer*. 2010; 18(1):83–7.
- Kielbassa AM, Hinkelbein W, Hellwig E, Meyer-Lückel H. Radiation-related damage to dentition. *Lancet Oncol*. 2006; 7(4):326–35.
- Nutting CM, Morden JP, Harrington KJ, Urbano TG, Bhide SA, Clark C, et al. Parotid-sparing intensity modulated versus conventional radiotherapy in head and neck cancer (PARSPORT): a phase 3 multicentre randomised controlled trial. *Lancet Oncol*. 2011; 12(2):127–36.
- Ozdemir S, Akin M, Coban Y, Yildirim C, Uzel O. Acute toxicity in nasopharyngeal carcinoma patients treated with IMRT/VMAT. *Asian Pac J Cancer Prev*. 2015; 16(5):1897–900.
- Pow EH, Kwong DL, McMillan AS, Wong MC, Sham JS, Leung LH, et al. Xerostomia and quality of life after intensity-modulated radiotherapy vs. conventional radiotherapy for early-stage nasopharyngeal carcinoma: initial report on a randomized controlled clinical trial. *Int Journal Radiat Oncol Biol Phys*. 2006; 66(4):981–91.
- Ben-David MA, Diamante M, Radawski JD, Vineberg KA, Stroup C, Murdoch-Kinch CA, et al. Lack of osteoradionecrosis of the mandible after intensity-modulated radiotherapy for head and neck cancer: likely contributions of both dental care and improved dose distributions. *Int J Radiat Oncol Biol Phys*. 2007; 68(2):396–402.
- Marcus N, Kristina M, Oliver B, Jochen F, Henrik H, Wolfgang JS, et al. Dental status, dental treatment procedures and radiotherapy as risk factors for infected osteoradionecrosis (IORN) in patients with oral cancer – a comparison of two 10 years' observation periods. *Springerplus*. 2014; 3:263.
- Jawad H, Hodson NA, Nixon PJ. A review of dental treatment of head and neck cancer patients, before, during and after radiotherapy: part 1. *Br Dent J*. 2015; 218(2):65–8.
- Kouloulis V, Antypas C, Liakouli Z, Armpia C, Zygogianni A, Floros I, et al. The first implementation of IMRT technique for head and neck and prostate cancer patients in public sector in Greece: feasibility, treatment planning and dose delivery verification using the delta (4 pt) Pre-Treatment volumetric quality assurance system. *J BUON*. 2015; 20(1):196–205.

## Оралне компликације радиолошке терапије код болесника са карциномом главе и врата – 3Д конформална радотерапија и 3Д конформална радиотерапија са МР фузијом

Мирослав Латинковић<sup>1</sup>, Милана Митрић-Асковић<sup>1</sup>, Оливера Иванов<sup>1,2</sup>, Мићо Новаковић<sup>1</sup>, Јелена Личина<sup>1</sup>

<sup>1</sup>Институт за онкологију Војводине, Клиника за радиотерапију, Сремска Каменица, Србија

<sup>2</sup>Универзитет у Новом Саду, Медицински факултет, Нови Сад, Србија

### САЖЕТАК

**Увод/Циљ** Учесталост нежељених ефеката зрачења код болесника са карциномом главе и врата зависи од технике планирања, спровођења радиотерапије и примарне локализације тумора.

Циљ нашег истраживања је да се утврди учесталост нежељених ефеката зрачне терапије код болесника са тумором главе и врата лечених 3Д конформалном радиотерапијом планираном само на основу КТ и 3Д конформалном терапијом планираном на основу фузије КТ са МР (КТ-МР).

**Методe** Проспективно је анализирано 40 болесника са карциномом орофаринкса и 40 болесника са карциномом ларинкса код којих је спроведена зрачна терапија. Двадесет болесника са карциномом орофаринкса и 20 болесника са карциномом ларинкса је зрачено 3Д конформалном техником на основу КТ, а још по 20 са карциномом орофаринкса и ларинкса фузијом КТ-МР. Код свих је примењена стандардна фракционација са 2 Гу дневно, пет дана седмично.

**Резултати** Од укупно 80 болесника лечених зрачењем, код 52 (52/80; 65%) забележени су нежељени ефекти зрачне терапије, а учесталост компликација је већа код примене 3Д КТ технике зрачења (31/52; 60% код 3Д КТ насупрот 21/52; 40% код 3Д КТ-МР;  $p = 0,02$ ). Било је више компликација у групи болесника код којих је примењена хемоирадијација него код болесника лечених само радиотерапијом – 35/52 РТ+ХТ, а 17/52 РТ (67% : 33%;  $p = 0,004$ ).

**Закључак** 3Д техника радиотерапије планирана само на основу КТ је повезана са високом стопом токсичности, које знатно утичу на квалитет живота зрачених болесника. 3Д конформална техника радиотерапије планирана фузијом КТ-МР смањује појаву оралних компликација. За примену виших туморских доза уз мању учесталост компликација је подеснија техника планирања са фузионисаном техником помоћу МР.

**Кључне речи:** радиотерапија; тумори главе и врата; оралне компликације; КТ-МР фузија у планирању радиотерапије