

CASE REPORT / ПРИКАЗ БОЛЕСНИКА

Gastric sarcoidosis

Svetlana Kašiković-Lečić^{1,2}, Violeta Vučinić^{3,4}, Milana Panjković^{1,2}, Biljana Kukić^{2,5}¹Institute for Pulmonary Diseases of Vojvodina, Sremska Kamenica, Serbia;²University of Novi Sad, School of Medicine, Novi Sad, Serbia;³Clinical Centre of Serbia, Clinic of Pulmonology, Belgrade, Serbia;⁴University of Belgrade, School of Medicine, Belgrade, Serbia;⁵Oncology Institute of Vojvodina, Sremska Kamenica, Serbia

SUMMARY

Introduction Sarcoidosis is a systemic disease with a 90% predilection for the lungs, but any organ can be involved. Gastric sarcoidosis may be a component of a generalized process, while isolated gastric sarcoidosis is very rare.

Case Outline We describe a rare case of biopsy-proven gastric sarcoidosis in a 45-year-old woman with pulmonary sarcoidosis in remission, and highlight the importance of gastroscopy and biopsy to confirm the diagnosis. Her optimal response to anti-acid therapy required no alternate (glucocorticoid) therapy. We briefly review the clinical, diagnostic, and therapeutic aspects of gastric sarcoidosis.

Conclusion Glucocorticoids remain the cornerstone of the sarcoidosis treatment, although it has been insufficiently documented by clinical trials. The decision to treat sarcoid patients with systemic glucocorticoids is largely based upon the severity of symptoms. The anti-acid therapy may be an alternative in milder cases, as demonstrated in our patient.

Keywords: sarcoidosis; stomach diseases; granuloma



INTRODUCTION

Sarcoidosis is a systemic disorder of uncertain etiology, characterized by accumulation of mononuclear inflammatory cells, followed by the formation of non-caseating epithelioid granulomas at the site of involvement. Sarcoidosis is localized in the lungs in more than 90% of cases [1]. Gastrointestinal manifestations excluding liver involvement (which occur in 40–70% of cases) are a rare form of extrapulmonary sarcoidosis [2]. The stomach is the most commonly affected organ in gastrointestinal sarcoidosis. It is estimated that gastric sarcoidosis with the associated symptomatology is observed in less than 1% of patients with sarcoidosis [2]. However, it has been suggested that sarcoid granulomas may be observed in the stomach of as many as 10% of patients with pulmonary manifestation of this disease without causing any significant gastrointestinal complaints [3]. Only 1% of the cases of a systemic disease have symptomatic gastric involvement [3]. An autopsy study of patients with sarcoidosis, however, reported gastro-duodenal involvement in 4–10% of the cases [2, 3].

CASE REPORT

A 45-year-old woman with pulmonary sarcoidosis in remission developed epigastric pain. The diagnosis of pulmonary sarcoidosis (stage II) without extrapulmonary disease manifestations had been established ten years previously, when

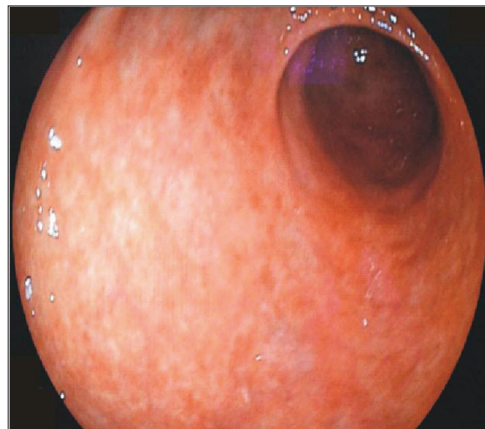

Figure 1. Upper gastrointestinal endoscopy showing mucosal erythema

she, complaining on exertional dyspnea, underwent pulmonary and hilar lymph node biopsy revealing non-caseating granulomas. Her symptoms resolved with a six-month course of systemic glucocorticoids. Over the last five-month period, 10 years after the initial diagnosis of sarcoidosis, she developed intermittent abdominal pain exacerbated by food and associated with nausea, early satiety, anorexia, and a slight weight loss. She had been examined by a gastroenterologist. The physical examination was remarkable for mild tenderness in the epigastric region. Esophagogastroduodenoscopy was performed, revealing a mucosal erythema (Figure 1). Random biopsies were taken from different sections of the stomach.

The histological examination of the biopsy specimens from the gastric fundus and antrum

Примљено • Received:
March 3, 2016

Ревизија • Revised:
April 22, 2016

Прихваћено • Accepted:
May 6, 2016

Online first: March 3, 2017

Correspondence to:
Svetlana KAŠIKOVIĆ-LEČIĆ
Pasterova 22
21000 Novi Sad, Serbia
sklecic@sbb.rs

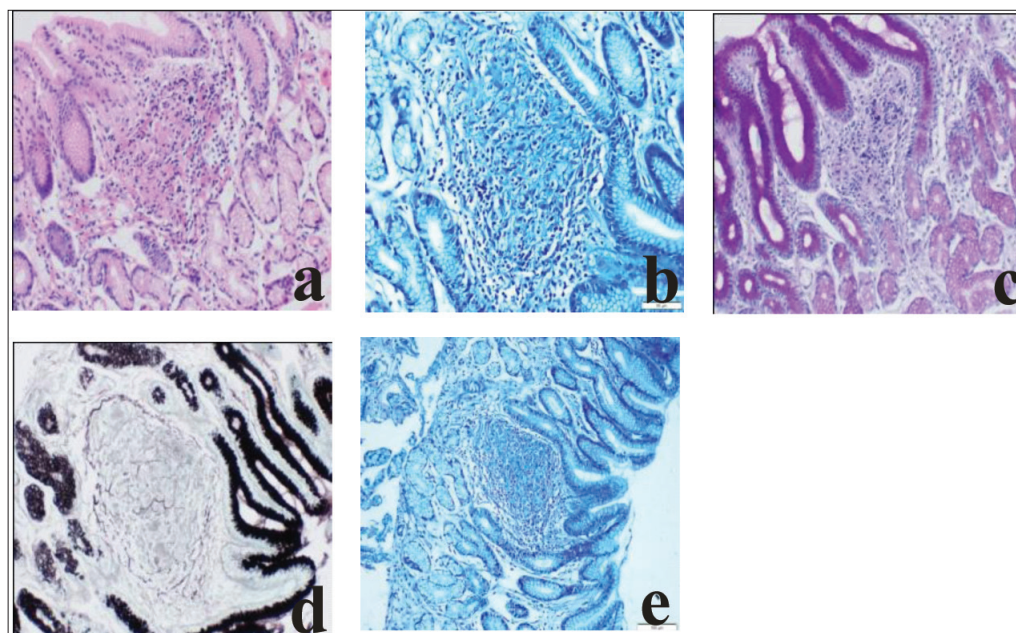


Figure 2. Sarcoid granuloma in the gastric mucosa: a) H&E, × 20; b) Ziehl–Neelsen, × 20; c) PAS, × 20; d) Grocott, × 20; e) Giemsa, × 10

showed non-necrotizing granulomas composed of epithelioid cells and lymphocytes (Figure 2). Biopsy samples were stained for *Helicobacter pylori* (Giemsa staining), acid-fast bacilli (Ziehl–Neelsen staining), and fungi (PAS and Grocott staining), and were all negative (Figure 2). The acid-fast staining and culture of the gastric aspirate were negative, as well as the serologic testing for *Treponema*. Other laboratory analyses in the differential diagnosis were negative as well.

After that, a total colonoscopy was performed providing normal findings. Ultrasound of the upper abdomen and abdominal computed tomography findings were also normal. The chest X-ray finding demonstrated no evidence of hilar lymphadenopathy or lung lesions. Laboratory studies at that time showed a normal complete blood count and no elevation in either the erythrocyte sedimentation rate, or the C-reactive protein (CRP) level. The serum and 24-hour urine calcium levels, as well as the serum angiotensin-converting enzyme (ACE) level were within reference ranges. The ophthalmologic evaluation did not reveal any changes characteristic of granulomatous inflammation.

With the former history of sarcoidosis, on the basis of the clinical history, physical examination, and histological findings, the diagnosis of gastric sarcoidosis was established.

A proton pump inhibitor was introduced and the patient had an alleviation of the symptoms in a few days. On controls, the patient was free of symptoms. She had routine follow-up gastroscopies and gastric mucosa biopsy sampling regularly performed in six-month intervals. Biopsy samples histopathology revealed persisting non-caseating epithelioid cell granulomas. After one year, histopathological analysis did not reveal any changes in the gastric mucosa (spontaneous or treatment-induced remission), and medicamentous therapy was suspended. No recurrence of symptoms occurred in two years of monitoring.

DISCUSSION

Among patients with sarcoidosis, the disease course is highly variable, and thus patients may present with a wide array of clinical manifestations and multiple non-specific symptoms. Fatigue is an integral part of the clinical picture of sarcoidosis [4]. Sarcoidosis can involve any organ, with pulmonary involvement being the most common one. Gastric sarcoidosis may be a component of a generalized process, while isolated gastric sarcoidosis is very rare. It mainly affects the antrum of the stomach [5, 6].

Gastric sarcoidosis may not cause any significant symptoms. The clinical manifestation of gastric sarcoidosis varies greatly and is obviously rather non-specific. Symptoms of gastric sarcoidosis are due to granulomatous inflammation and associated fibrosis of the gastric wall. Epigastric pain, emerging most commonly after meals, is the most common symptom. Other symptoms are nausea, vomiting, early satiety, anorexia, and weight loss [6, 7]. Complications are also various, and include a delayed gastric emptying, pyloric or duodenal obstruction, vitamin B12 deficiency, hematemesis and melena. Rarely, massive gastrointestinal bleeding occurs. The clinical symptoms of gastric sarcoidosis often lead to misdiagnoses of malignant or peptic disease [8].

Our case report is a warning that individuals with sarcoidosis in remission are still at risk of other, unrelated organ manifestations of the disease. In patients with a history of sarcoidosis, either active or in remission, presenting with gastrointestinal symptoms, the possibility of gastric sarcoidosis should be considered.

Gastroscopy, along with biopsy sampling, is essential in establishing the diagnosis of gastric sarcoidosis. In asymptomatic patients, the gastric mucosa may be normal and therefore unjustifiably disregarded during endoscopy

[3, 7]. The upper endoscopy with biopsy sampling is pivotal to establish the definitive diagnosis, even with the normal-looking mucosa. Mucosal ulcers with or without erythema, thickened mucosa, polypoid/nodular lesions (due to granulomas), diffuse infiltration of the mucosa (appearing as linitis plastica) and fibrosis may be seen as well. In gastric sarcoidosis, the following four principal categories of lesions have been distinguished: subclinical (usually asymptomatic and the most common), ulcerative, infiltrative, and polypous [9].

The diagnosis of gastric sarcoidosis may be established on the basis of the histopathological evaluation of biopsies collected during endoscopy. It should be remembered that endoscopic biopsies sometimes fail to identify sarcoid lesions, as the granulomas may be localized in the submucosa and deeper layers of the gastric wall, not just in the mucous membrane [9]. The diagnosis of gastric sarcoidosis is difficult without evidence of involvement of other organs. Gastric sarcoidosis can mimic other gastrointestinal diseases in presentation and its diagnosis requires a proper interpretation of the obtained biopsy samples as many other etiologies can present with non-caseating granulomas. In the differential diagnosis, other granulomatous gastritis should be considered, including Crohn's disease, Whipple's disease, tuberculosis, syphilis, reaction to malignancy (sarcoid reactions in cancer) or foreign body, peptic ulcer disease, gastric cancer, hypertrophic gastritis, histoplasmosis, lymphoma, Langerhans cell histiocytosis, and Ménétrier disease [9, 10]. Idiopathic granulomatous gastritis is diagnosed when none of the aforementioned conditions are identified [11]. However, the clinical relevance of this entity is questionable [11].

Hilar lymphadenopathy with/without lesions in the lungs may co-exist with, or precede the development of sarcoid lesions in the gastrointestinal tract [12, 13, 14]. This was the case in our patient. Isolated gastric sarcoidosis is very rare [9, 10].

Imaging studies are less useful, but barium studies are sometimes used to document ulcerations, stenosis, mucosal thickening, and loss of normal distensibility of the stomach. Abdominal computed tomography scan can be useful to assess the presence of hepatosplenomegaly or regional and retroperitoneal lymph nodes in the case of concomitant extragastric sarcoidosis [5]. Functional imaging with 8-F-fluorodeoxyglucose positron-emission tomography and computed tomography (FDG-PET-CT) have proved very sensitive to assess the inflammatory activity in sarcoidosis. Imaging studies are useful initially to assess the extent of the disease and guide the biopsy, or later to follow the response to the treatment. In gastric sarcoidosis, however, FDG-PET scan is limited by the variable physiologic uptake of the gastric mucosa [5]. Our patient refused FDG-PET-CT.

There are no specific laboratory features in gastric sarcoidosis. Inflammatory markers such as CRP, erythrocyte sedimentation rate, and gammaglobulins can be found elevated. The serum ACE elevation is neither sensitive nor specific for extrapulmonary sarcoidosis. Other laboratory tests are used only to assist in ruling out alternative diagnoses [6].

There are no available clinical trials on the therapeutic management of gastric sarcoidosis, which is therefore mostly derived from the experience in pulmonary sarcoidosis [5]. The treatment of gastric sarcoidosis depends on symptoms – that is on both the severity and the extent of the disease [5, 15, 16]. Asymptomatic patients do not need any specific therapy [16]. In a mild disease, the anti-acid therapy with proton pump inhibitors can be attempted, since a response has been reported in some cases [3]. The optimal duration of the treatment with proton pump inhibitors is unknown [5, 10, 12]. The treatment with proton pump inhibitors relieved digestive symptoms, although a control biopsy of the gastric mucosa revealed persistence of non-caseating granulomas. The role of glucocorticoids in the treatment of gastric sarcoidosis is unclear. Systemic glucocorticoids ameliorated symptoms and induced the clinical disease remission, demonstrating the usefulness of the drug in treating two thirds (66%) of patients with gastric sarcoidosis [17]. Clinical improvement is not always aligned with the resolution of pathological lesions [6]. Oral prednisolone 20–40 mg per day is recommended with a gradual tapering regimen [9]. The optimal duration is unknown, but a minimum of 6–12 months seems reasonable [7, 17]. Glucocorticoids have been used alone, or in combination with proton pump inhibitors [3]. Still, further studies aimed at assessing the efficacy of glucocorticoids and proton pump inhibitors in treating patients with gastric sarcoidosis are needed. Our patient, who had moderate symptoms and mild changes in the gastric mucosa and no significant other organ involvement, did not receive glucocorticoids because she achieved an optimal response to anti-acid therapy.

In cases of contraindicated corticosteroid treatment, corticosteroid-resistant symptoms or need for a corticosteroid-sparing therapy, alternative agents (such as methotrexate, azathioprine, infliximab, hydroxychloroquine or chlorambucil) have been used, alone or in combination with corticosteroids [5, 17].

A surgery might be useful in rare cases when there is a severe gastric lumen narrowing, pyloric or duodenal obstruction, or massive hemorrhage [18].

Patients with longstanding gastric sarcoidosis may involve various degrees of fibrosis of the gastric wall. Other patients recover spontaneously. Gastric cancer associated with gastric sarcoidosis has hardly been reported [18]. This is why repeated gastroscopies and biopsies of the gastric mucosa were performed in our patient.

REFERENCES

1. Statement on sarcoidosis. Joint Statement of the American Thoracic Society (ATS), the European Respiratory Society (ERS) and the World Association of Sarcoidosis and Other Granulomatous Disorders (WASOG) adopted by the ATS Board of Directors and by the ERS Executive Committee, 1999. *Am J Respir Crit Care Med.* 1999; 160(2):736–55.
2. Afshar K, BoydKing A, Sharma OP, Shigemitsu H. Gastric sarcoidosis and review of the literature. *J Natl Med Assoc.* 2010; 102(5):419–22.
3. Ungprasert P, Kue-A-Pai P, Srivali N, Cheungpasitporn W, Griger DT. A rare case of symptomatic gastric sarcoidosis. *Q J Med.* 2013; 106(6):569–70.
4. Vučinić V, Stojković M, Milenković B, Videnović-Ivanov J, Škodić-Trifunović V, Žugić V, et al. Fatigue in Sarcoidosis: Detection and Treatment. *Srp Arh Celok Lek.* 2012; 140(1-2):104–10.
5. Vanderhulst J. Gastric sarcoidosis: rare presentation of a rare disease. *Acta Clin Belg.* 2015; 70(1):58–60.
6. Chinitz MA, Brandt LJ, Frank MS, Frager D, Sablay L. Symptomatic sarcoidosis of the stomach. *Dig Dis Sci.* 1985; 30(7):682–8.
7. Ziora D, Trzepióra B, Kozielski J. Gastric sarcoidosis – a case report. *Pneumonol Alergol Pol.* 2010; 78(5):374–8.
8. Vahid B, Spodik M, Braun KN, Ghazi LJ, Esmaili A. Sarcoidosis of gastrointestinal tract: a rare disease. *Dig Dis Sci.* 2007; 52(12):3316–20.
9. Vahid B, Lin T. Surgical aspects of abdominal sarcoidosis. *Surg J.* 2007; 2:5–13.
10. Adler M, Burroughs A, Beynon H. Gastrointestinal sarcoidosis. A review. *Sarc Vasc Diffuse Lung Dis.* 2007; 24(1):3–11.
11. Sandmeier D, Bouzourene H. Does idiopathic granulomatous gastritis exist? *Histopathology.* 2005; 46(3):352–3.
12. Akinoyemi E, Rohewal U, Tangorra M, Matin A, Abdullah M. Gastric sarcoidosis. *J National Med Assoc.* 2006; 98(6):948–9.
13. Farman J, Ramirez G, Rybak B, Lebowitz O, Semrad C, Rotterdam H. Gastric sarcoidosis. *Abdom Imaging.* 1997; 22(3):248–52.
14. Kawaura K, Takahashi T, Kusaka K, Yamakawa J, Itoh T, Kanda T. Spontaneously identified gastric sarcoidosis: a report of three cases. *J Int Med Res.* 2003; 31(3):239–43.
15. Shkolnik LE, Shin RD, Brabeck DM, Rothman RD. Symptomatic gastric sarcoidosis in a patient with pulmonary sarcoidosis in remission. *BMJ Case Rep.* 2012; 2012.
16. Tokala H, Polsani K, Kalavakunta JK. Gastric Sarcoidosis: A Rare Clinical Presentation. *Case Rep Gastrointest Med.* 2013; 2013:260704.
17. Ebert EC, Kierson M, Hagspiel KD. Gastrointestinal and hepatic manifestations of sarcoidosis. *Am J Gastroenterol.* 2008; 103(12):3184–92.
18. Matsubara T, Hirahara N, Hyakudomi R, Fujii Y, Kaji S, Taniura T, et al. Early gastric cancer associated with gastric sarcoidosis. *Int Surg.* 2015; 100(5):949–53.

Саркоидоза желуца

Светлана Кашиковић-Лечић^{1,2}, Виолета Вучинић^{3,4}, Милана Пањковић^{1,2}, Биљана Кукић^{2,5}

¹Институт за плућне болести Војводине, Сремска Каменица, Србија;

²Универзитет у Новом Саду, Медицински факултет, Нови Сад, Србија;

³Клинички центар Србије, Клиника за пулмологију, Београд, Србија;

⁴Универзитет у Београду, Медицински факултет, Београд, Србија;

⁵Институт за онкологију Војводине, Сремска Каменица, Србија

САЖЕТАК

Увод Саркоидоза је системско обољење које код 90% болесника захвата плућа, мада било који орган може бити захваћен овом болешћу. Саркоидоза желуца може бити саставни део генерализоване болести, а изолована саркоидоза желуца је врло ретка.

Приказ болесника Описали смо редак случај саркоидозе желуца потврђен биопсијом код болеснице старе 45 година са саркоидозом плућа у ремисији. Указали смо на значај гастроскопије и биопсије за потврду дијагнозе. Оптималан одговор на антацидну терапију није захтевао примену ал-

тернативне (гликокортикоидне) терапије. Изнет је кратак преглед клиничких, дијагностичких и терапијских аспеката саркоидозе желуца.

Закључак Гликокортикоиди су основа терапије саркоидозе, што, међутим, није у потпуности доказано клиничким испитивањима. Одлука о лечењу саркоидозе применом системских гликокортикоида углавном се заснива на тежини симптома. Антацидна терапија може бити алтернатива код благе саркоидозе желуца, као што је приказано у нашем случају.

Кључне речи: саркоидоза; болести желуца; гранулом