

Synchronous advanced pulmonary tuberculosis and acute virus myocarditis mimicked Wegener granulomatosis in a 26-year-old man – A case report

Dragica P. Pešut^{1,2}, Milan Ž. Petrović^{1,3}, Nada R. Vasić², Ruža S. Stević^{1,4}

¹University of Belgrade, School of Medicine, Belgrade, Serbia;

²Clinical Center of Serbia, Hospital for Pulmonology, Belgrade, Serbia;

³Clinical Center of Serbia, Hospital for Cardiology, Belgrade, Serbia;

⁴Clinical Center of Serbia, Center for Radiology and Magnetic Resonance, Belgrade, Serbia

SUMMARY

Introduction Tuberculosis patients are rarely asymptomatic. Acute virus myocarditis presents with a wide range of symptoms, from mild dyspnea or chest pain to cardiogenic shock and death.

Case Outline A 26-year-old Caucasian man non-smoker presented with one-week history of lower extremities' swelling. The patient's medical history also revealed a two-day episode of subfebrile temperature with scanty hemoptysis three weeks prior to admission. The episode had not provoked him to seek medical care. Physical examination revealed generalized oedema, and laboratory analysis showed signs of acute renal insufficiency. Enlarged heart and hilar shadows, bilateral massive cavitory pulmonary opacities and pleural effusion were found at chest radiography. Sputum smears were *Mycobacteria* negative on direct microscopy. Electrocardiogram changes and echocardiography were suggestive of acute myocarditis with dilated cardiomyopathy. IgM titer to adenovirus was positive. Under diuretics, angiotensin-converting-enzyme inhibitor, beta-blocker, antibiotics and bed rest, fast heart compensation and renal function repair were achieved. Radiographic pulmonary changes promptly regressed except for a cavity in the right upper lobe. Bronchial aspirate from the affected lobe was *Mycobacteria* positive on direct microscopy and culture positive for *Mycobacterium tuberculosis*. Standard anti-tuberculosis drug regimen led to recovery.

Conclusion In the unusual common existence of two diseases whose presentation initially mimicked Wegener's granulomatosis, acute dilated cardiomyopathy contributed to pulmonary tuberculosis detection. To prevent diagnostic delay in tuberculosis, further efforts in population education are necessary together with continual medical education.

Keywords: tuberculosis, pulmonary; myocarditis, viral; cardiomyopathy; diagnostics; oedema; renal insufficiency

INTRODUCTION

Tuberculosis (TB), declared global emergency by the World Health Organization, is an infectious disease caused by *Mycobacterium tuberculosis complex*. A total of 9.6 million people worldwide developed active TB and 1.5 million people died from the curable disease in 2014 [1]. Although TB may affect any organ, in 96% of the cases it starts in the lungs [2]. TB prevalence in a community influences the risk of being infected and the risk of developing TB in infected patients depends on many factors that determine human immunity [3]. Bacteriologic confirmation is the gold diagnostic standard.

Myocarditis is inflammation of the myocardium accompanied by myocellular necrosis, usually caused by infectious agents [4]. It represents a significant cause of death especially in young patients [5]. Viral myocarditis is most frequently caused by parvovirus B19, human herpes virus 6, coxsackievirus, and adenovirus [6]. Acute myocarditis should be considered in patients who present with recent onset of cardiac failure and/or arrhythmia [6]. Although endomyocardial biopsy with viral genome detection is considered the gold stan-

dard in the diagnostics of viral myocarditis, it is not routinely used in all suspected cases [7, 8]. Presence of viral genome in the myocardium of patients with acute dilated cardiomyopathy has no functional and prognostic relevance [9].

We aimed to describe a rare condition: synchronous existence of two atypically presented diseases that initially mimicked Wegener's granulomatosis. The Ethics Board of the Clinical Centre of Serbia in Belgrade has approved the case report to be published in a medical journal.

CASE REPORT

A previously healthy 26-year-old non-smoker Caucasian man presented to emergency room with one-week history of rapidly progressive low extremities' swelling without other complaints. The patient's medical history revealed a two-day episode of subfebrile temperature and scanty hemoptysis three weeks prior to admission. He never went to see a doctor for that and denied history of alcohol abuse, toxic exposure or sick contact. He was a guest to his relatives, coming from a high TB prevalence and a post-war country.

Correspondence to:

Dragica PEŠUT
Teaching Hospital of Pulmonology
Clinical Center of Serbia
Dr Koste Todorovića 26
11000 Belgrade
Serbia
dragica.pesut@mub.bg.ac.rs

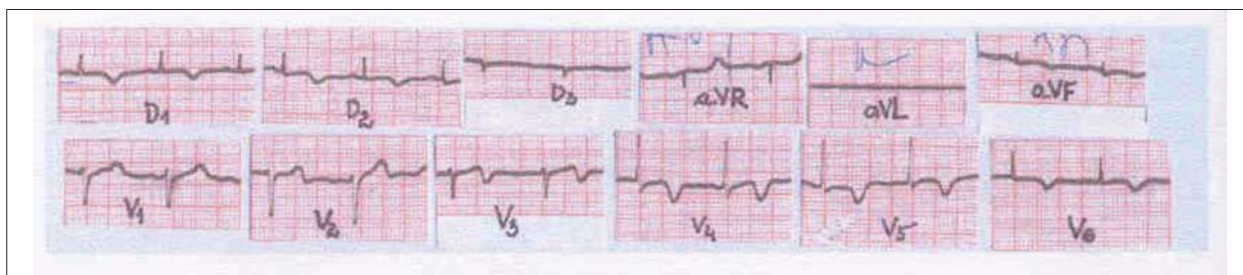


Figure 1. Electrocardiography on admission: low QRS complex voltage, depressed and inverted T wave in the standard and left precordial leads

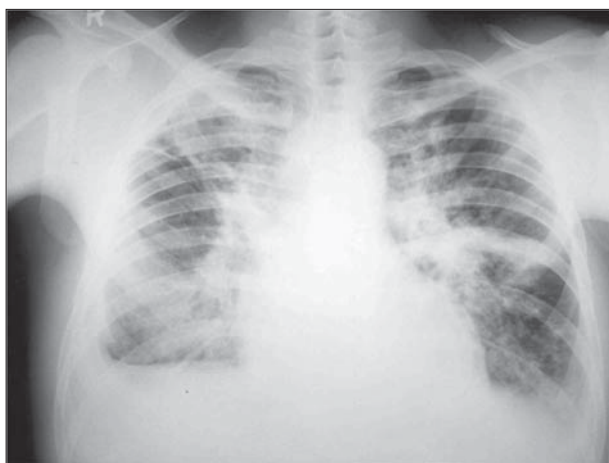


Figure 2. Posteroanterior chest radiography on admission: enlarged heart and hilar shadows, diffuse pulmonary parenchymal opacities, partially excavated, especially expressed in the right infraclavicular and left perihilar fields with bilateral obliteration of costophrenic sinus

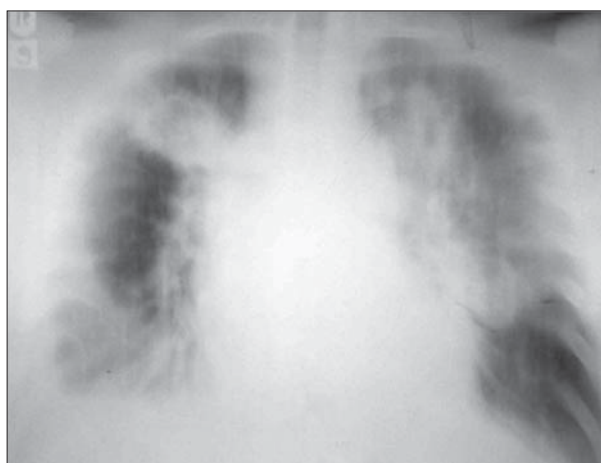


Figure 3. Frontal chest radio tomography on admission (9 cm): bilateral massive lung patchy infiltrates, partly excavated, together with renal insufficiency, might suggest Wegener's granulomatosis

Inspection showed heavy generalized edema especially expressed in lower extremities. The patient's vital signs were as follows: 1) blood pressure: 105/70 mmHg; 2) body temperature: 36.4°C; 3) respiratory rate: 16 breaths/min.; 4) heart and pulse rate: 88 beats/min.; and 5) oxygen saturation 95% while breathing room air. Auscultation revealed decreased pulmonary sound and crackles over pulmonary bases. Results of peripheral blood laboratory tests were within normal limits, including complete blood count, except for signs of renal insufficiency [urea: 12.2 mmol/L (range: 2.5–7.5), creatinine: 193 μ mol/L (range: 53–124), sK⁺: 5.6 mmol/L (range: 3.5–5.1)]. Electrocardiogram (ECG) changes are shown in Figure 1 and standard posteroanterior chest radiography in Figure 2. Apart from pulmonary and pleural changes, radiographic findings suggested that cardiomegaly was possible by the ratio of the heart diameter to that of the chest. The findings were completed with chest tomography (Figure 3), which was suggestive of granulomatosis Wegener. Negative vasculitis serology made the diagnosis of vasculitis less likely.

Echocardiography revealed signs of acute myocarditis: significant enlargement of the left ventricle following dilative cardiomyopathy pattern with significantly reduced its systolic function (ejection fraction: 37%); changed hypoechogenic myocardial structure with thicker wall and septum that correlated with myocardial oedema during acute myocarditis; low degree mitral regurgitation due to dilatation of the left ventricle and pericardial dissociation with minimal pericardial effusion as signs of cardiac

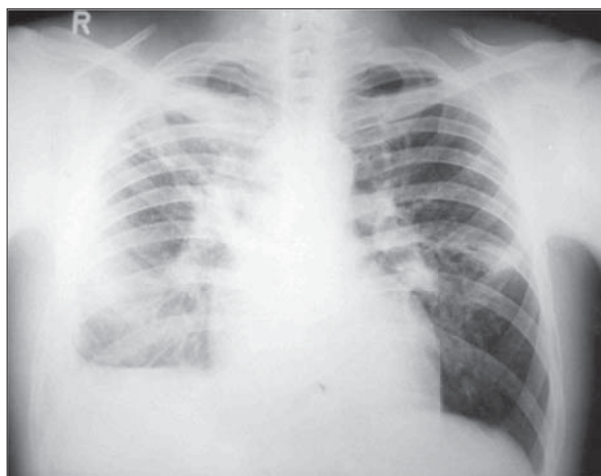


Figure 4. Chest radiography seven days after admission; under diuretic (and antibiotic) treatment, left-sided pleural effusion disappeared (clearly shaped left diaphragm and costophrenic sinus) together with majority of pulmonary shadows that belonged to hydrostatic pulmonary oedema

failure. Immuno-serologic examination was negative for systemic disease and IgM titer to adenovirus was positive.

The patient responded well to furosemide, angiotensin-converting-enzyme inhibitor, calcium channel blocker, bed rest, and antibiotic. Generalized oedema promptly diminished and disappeared in several days and radiographic changes regressed significantly (Figure 4). Cardiac compensation was achieved and renal function normalized. ECG and echocardiography findings suggested re-

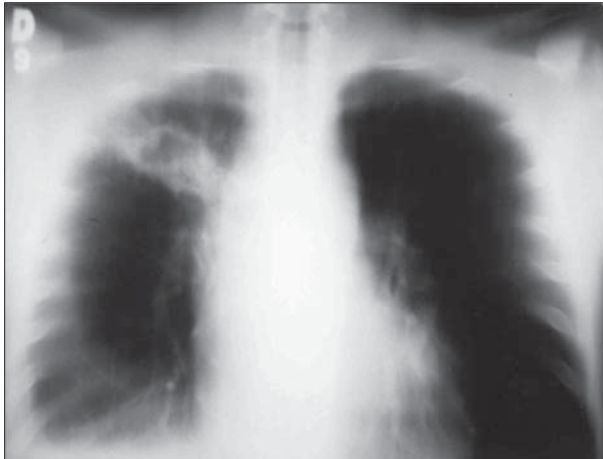

Figure 5. Chest tomography six weeks later showed irregularly shaped excavated thickened wall shadow 3 × 4 cm in size in the right upper pulmonary lobe

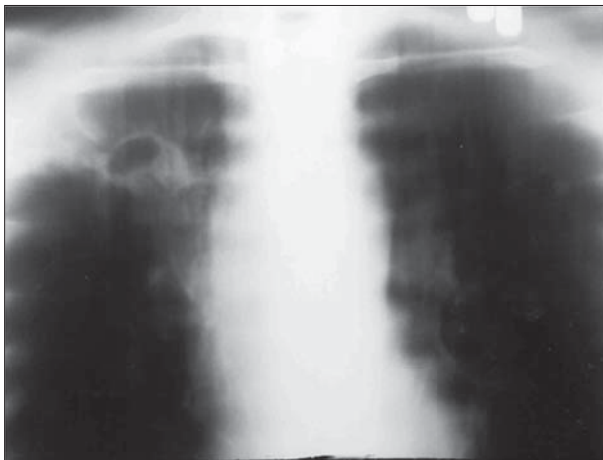


Figure 6. Frontal chest radio tomography (9 cm): typical slow regression of the right upper lobe cavity (Figure 5) two months after the commencement of the anti-tuberculosis treatment

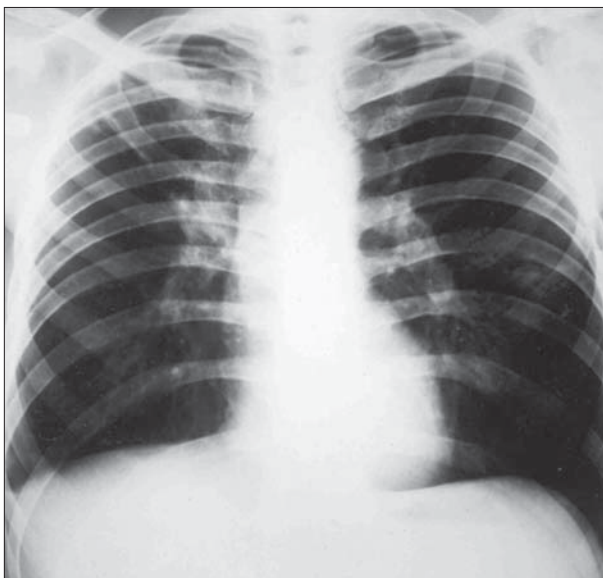


Figure 7. Standard chest radiography one year later: normally sized heart shadow; sequelae tuberculosis in the right upper lobe (second intercostal space) and obtuse right costophrenic sinus due to pleural adhesion

gression of myocarditis and left ventricle function recovery. Six weeks later, all radiographic pulmonary changes regressed except for one in the right upper lobe (Figure 5). Asymptomatic patient's stable cardiac condition allowed continuation of the necessary diagnostic procedure. Bronchoscopy showed normal bronchial tree, and aspirate from the area of radiographic changes was acid fast bacilli positive on direct microscopy. Culture was positive for *Mycobacterium tuberculosis*.

Anti-tuberculosis treatment started following standardized short course regimen. Regression was evident on chest tomography two months later, at the end of the initial phase of treatment (Figure 6). The therapy was continued for the next four months until the end of the regimen.

The patient came for a medical examination one year later, having no respiratory complaints, at which time chest radiography was performed (Figure 7). Transient ventricular premature beats (bigeminy) were registered and further cardiologic follow-up and treatment were recommended.

DISCUSSION

We presented a case of acute adenovirus myocarditis, which happened to be helpful in detection of advanced pulmonary TB. Atypically, our patient presented without fatigue, appetite or weight loss, sweating and cough. Cough is the most common symptom, and hemoptysis appears in about 20% of patients with pulmonary TB [2, 10]. Together with sneezing, singing or loud speaking, cough is considered crucial in the production of infectious droplet nuclei and spreading of the airborne infection [3]. Thus, absence of cough in patients with cavitary TB is especially important from the public health point of view. Moreover, on admission, the patient was acid-fast bacilli sputum smear negative on direct microscopy, which additionally diminished his presence as a serious source of infection.

Diagnosis of acute myocarditis is based on symptoms/signs, electrocardiography and echocardiography [11, 12]. The clinical picture may vary, ranging from asymptomatic courses to severe illness and the necessity of intensive care therapy [13]. Our patient had no symptoms related to an infectious disease or cardiac failure until rapidly growing low extremities' oedema appeared. These were the only reason of his concern and coming to see a doctor. We could not but to mention fulminant myocarditis as a distinct entity characterized by sudden onset of severe congestive heart failure or cardiogenic shock. Adenovirus is among its known causes. It usually develops following a flu-like illness, which missed in our patient, who had a stable hemodynamic state during the course of the disease, absence of symptoms such as dyspnea, chest pain, fever, cough or palpitations, and relatively fast recovery under diuretics, angiotensin-converting-enzyme inhibitors and bed rest.

Biopsy for diagnosis of myocarditis in patients who present clinically with congestive heart failure can be useful [14]. Although it remained the gold standard in diagno-

sis of viral myocarditis, it is used infrequently due to perceived risks and the lack of a widely accepted and sensitive histological standard [7, 15]. Serologic test alone is not considered valid for diagnosis, but together with clinical presentation, ECG, radiographic and echocardiographic findings it was adequate to suggest etiology of acute myocarditis and dilated cardiomyopathy in the presented case. The role of many viruses detected in cardiac tissue in causing myocarditis is controversial and even in forensic studies the issue remains challenging. One of the recent studies showed that adenovirus, enterovirus, and parvovirus B19 were found to be rare causes of myocarditis-related death [16]. It is suggested that noninvasive cardiac magnetic resonance imaging might provide an alternative method for diagnosis and its use is recommended as early as possible at onset of the disease when its validity is the highest. Recent research on patients in whom acute myocarditis was clinically suspected for the first time confirmed association of left ventricle transmural myocardial oedema evidenced by contrast-enhanced cardiac magnetic resonance and T wave inversion [17]. The latter has been registered in our patient's ECG (Figure 1) and also associated with myocardial oedema in the presence of minimal pericardial effusion on echocardiography. The pathophysiologic mechanisms of electrocardiographic T-wave inversion occurring in patients with acute myocarditis remain to be elucidated.

Causative differential diagnosis of myocarditis could include the other microbial or toxic agents. Although extrapulmonary TB is on the increase worldwide and in Serbia [1, 18], TB myocardial affection, usually detected on autopsy, was least possible in our patient due to prompt recovery, which is not a characteristic of the TB process [2]. History taking excluded possibility of alcohol-induced or other toxic heart disease.

Myocarditis may cause arrhythmias in its acute phase due to inflammatory infiltration and myocyte necrosis.

Transient bigeminy, detected in our patient a year later in the chronic phase, could be attributed to an immune reaction, fibrosis, and resulting electric remodeling [19]. Patient follow-up is of crucial importance to abort complications such as sudden cardiac death [11, 20]. If antiarrhythmic drugs are not effective enough in patients with hemodynamically unstable ventricular tachycardia, an implantable cardioverter-defibrillator is taken into consideration [21].

While it is clear that high TB prevalence in our patient's country of origin might put him into higher risk of TB infection, we hardly succeeded to define any of risk factors for developing TB as an active disease except for one – prolonged emotional stress [3]. The young man had come from a post-war setting, familiar with some horrible local events that had happened.

Diagnostic delay is an important problem in TB control. It consists of patients' delay to seek medical care and the delay of the healthcare system [22]. Population education on TB usually results in better understanding of TB symptoms and earlier presentation of symptoms to a doctor, earlier detection and treatment with stopping the spread of the disease within a community. Moreover, continual medical education could strengthen the idea that patients and groups at higher risk for developing TB exist. The idea should always be present in physicians' minds to initiate an active approach in TB detection [23]. In the times of TB as global emergency, "Think TB!" principle should be a premise in both primary health care and differently profiled specialized institutions.

ACKNOWLEDGMENT

The paper was supported by the Ministry of Education, Science and Technological Development of the Republic of Serbia through grant No. 175095, 2011–2014.

REFERENCES

- World Health Organization [Internet] Geneva: Global tuberculosis report 2015 [cited 2015 Dec 10] Available from: http://www.who.int/tb/publications/global_report/en/.
- Crofton J, Horne N, Miller F. *Clinical Tuberculosis*. 3rd ed. London: Macmillan Education; 2009.
- Rieder HL. *Epidemiologic Basis of Tuberculosis Control*. Paris: International Union against Tuberculosis and Lung Disease; 1999.
- Mahrholdt H, Wagner A, Deluigi CC, Kispert E, Hager S, Meinhardt G, et al. Presentation, patterns of myocardial damage, and clinical course of viral myocarditis. *Circulation*. 2006; 114(15):1581–90. [DOI: 10.1161/CIRCULATIONAHA.105.606509] [PMID: 17015795]
- Rose NR. Viral myocarditis. *Curr Opin Rheumatol*. 2016; 28(4):383–9. [DOI: 10.1097/BOR.0000000000000303] [PMID: 27166925]
- Combes A. Acute myocarditis. *Presse Med*. 2012; 41(6 Pt 1):621–7. [DOI: 10.1016/S0755-4982(04)98709-X] [PMID: 22515999]
- Mahfoud F, Gärtner B, Kindermann M, Ukena C, Gadomski K, Klingel K, et al. Virus serology in patients with suspected myocarditis: utility or futility? *Eur Heart J*. 2011; 32(7):897–903. [DOI: 10.1093/eurheartj/ehq493] [PMID: 21217143]
- Chimenti C, Frustaci A. Contribution and risks of left ventricular endomyocardial biopsy in patients with cardiomyopathies: a retrospective study over a 28-year period. *Circulation*. 2013; 128(14):1531–41. [DOI: 10.1161/CIRCULATIONAHA.13.001414] [PMID: 24004501]
- Kueth F, Sigusch HH, Hilbig K, Tresselt C, Gluck B, Egerer R, et al. Detection of viral genome in the myocardium: lack of prognostic and functional relevance in patients with acute dilated cardiomyopathy. *Am Heart J*. 2007; 153(5):850–8. [DOI: 10.1016/j.ahj.2007.02.03] [PMID: 17452164]
- Wejse C, Gustafson P, Nielsen J, Gomes VF, Aaby P, Andersen PL, et al. TBscore: signs and symptoms from tuberculosis patients in a low-resource setting have predictive value and may be used to assess clinical course. *Scand J Infect Dis*. 2008; 40(2):111–20. [DOI: 10.1080/00365540701558698] [PMID: 17852907]
- JCS Joint Working Group. Guidelines for diagnosis and treatment of myocarditis (JCS 2009): digest version. *Circ J*. 2011; 75(3):734–43. [DOI: 10.1253/circj.CJ-88-0008] [PMID: 21304213]
- Løgstrup BB, Nielsen JM, Kim WY, Poulsen SH. Myocardial oedema in acute myocarditis detected by echocardiographic 2D myocardial deformation analysis. *Eur Heart J Cardiovasc Imaging*. 2016; 17(9):1018–26. [DOI: 10.1093/ehjci/jev302] [PMID: 26588987]
- D'Ambrosio A, Patti G, Manzoli A, Sinagra G, Di Lenarda A, Silvestri F, et al. The fate of acute myocarditis between spontaneous improvement and evolution to dilated cardiomyopathy: a review. *Heart*. 2001; 85(5):499–504. [DOI: 10.1136/heart.85.5.499] [PMID: 11302994]
- Vasiljević JD, Kanjuh V, Seferović P, Šesto M, Stojić D, Olsen EG. The incidence of myocarditis in endomyocardial biopsy samples from

- patients with congestive heart failure. *Am Heart J.* 1990; 120(6 Pt 1):1370–7. [DOI: 10.1016/0002-8703(90)90250-2] [PMID: 2174202]
15. Cooper LT. Myocarditis. *N Engl J Med.* 2009; 360(15):1526–38. [DOI: 10.1056/NEJMra0800028] [PMID: 19357408]
 16. Nielsen TS, Hansen J, Nielsen LP, Baandrup UT, Banner J. The presence of enterovirus, adenovirus, and parvovirus B19 in myocardial tissue samples from autopsies: an evaluation of their frequencies in deceased individuals with myocarditis and in non-inflamed control hearts. *Forensic Sci Med Pathol.* 2014; 10(3):344–50. [DOI: 10.1007/s12024-014-9570-7] [PMID: 24781135]
 17. De Lazzari M, Zorzi A, Baritussio A, Siciliano M, Migliore F, Susana A, et al. Relationship between T-wave inversion and transmural myocardial edema as evidenced by cardiac magnetic resonance in patients with clinically suspected acute myocarditis: clinical and prognostic implications. *J Electrocardiol.* 2016; 49(4):587–95. [DOI: 10.1016/j.jelectrocard.2016.04.002] [PMID: 27178316]
 18. Pešut DP, Bulajić MV, Lešić AR. Time trend and clinical pattern of extrapulmonary tuberculosis in Serbia, 1993–2007. *Vojnosanit Pregl.* 2012; 69(3):227–30. [DOI: 10.2298/VSP1203227P] [PMID: 22624407]
 19. Dello Russo A, Casella M, Pieroni M, Pelargonio G, Bartoletti S, Santangeli P, et al. Drug-refractory ventricular tachycardias after myocarditis: endocardial and epicardial radiofrequency catheter ablation. *Circ Arrhythm Electrophysiol.* 2012; 5(3):492–8. [DOI: 10.1161/CIRCEP.111.965012] [PMID: 22294614]
 20. Howlett JG, McKelvie RS, Arnold JM, Costigan J, Dorian P, Ducharme A, et al. Canadian Cardiovascular Society Consensus Conference guidelines on heart failure, update 2009: diagnosis and management of right-sided heart failure, myocarditis, device therapy and recent important clinical trials. *Can J Cardiol.* 2009; 25(2):85–105. [DOI: 10.1016/S0828-282X(09)70477-5] [PMID: 19214293]
 21. ACC/AHA/ESC 2006 guidelines for management of patients with ventricular arrhythmias and the prevention of sudden cardiac death – executive summary: a report of the American College of Cardiology/American Heart Association Task Force and the European Society of Cardiology Committee for practice guidelines (writing committee to develop guidelines for management of patients with ventricular arrhythmias and the prevention of sudden cardiac death): developed in collaboration with the European Heart Rhythm Association and the Heart Rhythm Society. *Eur Heart J.* 2006; 27(17):2099–140. [DOI: 10.1093/eurheartj/ehl199] [PMID: 16923744]
 22. Malbasa M, Pesut D. Is there delay in diagnosis of pulmonary tuberculosis in an intermediate-to-low TB incidence setting. *Pneumologia.* 2011; 60(3):138–42. [PMID: 22097435]
 23. Bothamley GH, Ditiu L, Migliori GB, Lange C, TBNET contributors. Active case finding of tuberculosis in Europe: a Tuberculosis Network European Trials Group (TBNET) survey. *Eur Respir J.* 2008; 32(4):1023–30. [DOI: 10.1183/09031936.00011708] [PMID: 18550615]

Истовремено присуство кавернозне плућне туберкулозе и акутног вирусног миокардитиса имитирало је Вегенерову грануломатозу код 26-годишњег болесника – приказ случаја

Драгица П. Пешут^{1,2}, Милан Ж. Петровић^{1,3}, Нада Р. Васић², Ружа С. Стевић^{1,4}

¹Универзитет у Београду, Медицински факултет, Београд, Србија;

²Клинички центар Србије, Клиника за пулмологију, Београд, Србија;

³Клинички центар Србије, Клиника за кардиологију, Београд, Србија;

⁴Клинички центар Србије, Центар за радиологију и магнетну резонанцу, Београд, Србија

КРАТАК САДРЖАЈ

Увод Туберкулоза ретко протиче асимптоматски. Акутни вирусни миокардитис може да се испољи широком палетом тежоба од благе диспнеје или бола у грудима до кардиогеног шока и смрти.

Приказ болесника Непушач стар 26 година јавио се на преглед због брзог отицања ногу у последњих недељу дана. Три недеље раније имао је дводневну епизоду оскудних хемоптизија и субфебрилне температуре, због које се није обраћао лекару. Физикалним прегледом је нађен генерализован едем, а лабораторијским анализама знаци акутне реналне инсуфицијенције. Радиограм грудног коша показао је увећану силуету срца и хилуса плућа и обостране масивне промене у плућима, на томографији делом екскавиране, и плеурални излив. Микобактерије нису нађене у спутуму директном микроскопијом. ЕКГ и ехокардиографија су указивали на знаке акутног миокардитиса, тј. дилатативне кардиомиопатије као његове последице. Титар *IgM* на аденовирусе био је позитиван. Диуретици уз *ACE* инхибитор,

блокатор калцијумових канала, мировање и антибиотик, довели су до брзог повлачења едема и компензације срца уз нормализовање реналне функције. Брзо се повукао и највећи део плућних промена, које су одговарале стази, али је заостала неправилна екскавација у десном горњем режњу. У бронхоаспирату из места рендгенски видљиве лезије микобактерије су нађене директном микроскопијом, а културом *M. tuberculosis*. И култура иницијалног узорка спутума била је позитивна. Примена антитуберкулотика према стандардном режиму довела је до излечења.

Закључак У реткој истовременој појави две болести, која је у почетку личила на Вегенерову грануломатозу, акутни вирусни миокардитис са дилатативном кардиомиопатијом допринео је откривању туберкулозе плућа. Да би се спречило кашњење у дијагнози туберкулозе, неопходни су додатни напори у просвећивању становништва и континуирана медицинска едукација.

Кључне речи: туберкулоза, плућна; миокардитис, вирусни; кардиомиопатија; дијагноза; едем; ренална инсуфицијенција

Примљен • Received: 23/10/2015

Ревизија • Revision: 13/01/2016

Прихваћен • Accepted: 26/01/2016