

The role of the color Doppler ultrasonography and computed tomography in estimation of portal hypertension

Dijana Nićiforović¹, Viktor Till¹, Viktorija Vučaj-Ćirilović², Kosta Petrović¹, Mirela Juković¹, Darka Hadnađev-Šimonji¹, Željka Savić³, Edita Stokić⁴, Katarina Šarčev⁵

¹Clinical Center of Vojvodina, Center for Radiology, Novi Sad, Serbia;

²Oncology Institute of Vojvodina, Diagnostic Imaging Center, Sremska Kamenica, Serbia;

³Clinical Center of Vojvodina, Gastroenterology and Hepatology Clinic, Novi Sad, Serbia;

⁴Clinical Center of Vojvodina, Endocrinology, Diabetes and Metabolic Diseases Clinic, Novi Sad, Serbia;

⁵Clinical Center of Vojvodina, Abdominal, Endocrine Surgery and Transplantation Clinic, Novi Sad, Serbia

SUMMARY

Introduction Liver diseases with disturbances of hepatic and splanchnic circulation lead to the portal hypertension, with or without a portal vein thrombosis.

Objective This study was based on the testing of hypothesis that more data and more precise diagnosis in patients with disorders of portal circulation can be obtained by using color Doppler ultrasonography (CDU) and computed tomography (CT) with contrast.

Methods The study was conducted from February 2011 to May 2014 and it comprised 120 patients who were suspected to have portal hypertension or already had clinical confirmation of the portal hypertension, patients with hepatitis, and some patients with hematological diseases. The first group of 40 patients was examined by conventional ultrasonography and CDU, the second group by contrast CT, and the third group of patients was examined by both methods (CDU and contrast CT). After six months of adequate therapy, the patients had control examinations with the same diagnostic technique used during their first examination.

Results Retrospective analysis showed that CDU is more sensitive than CT in the assessment of presence and age of thrombi (CDU 93.9%; CT 86.1%). CT gives precise data in detection of portosystemic collaterals. Sensitivity of CT is 100% and its specificity is 67%. Cumulative sensitivity and specificity for most parameters were increased in patients with portal hypertension when both methods were applied.

Conclusion This study emphasizes the possibility of early and more accurate diagnosis achieved when combining two radiological techniques (CDU and contrast CT scan), which is not the case when these methods are used separately.

Keywords: color Doppler ultrasonography; portal hypertension; portal thrombosis; computed tomography

INTRODUCTION

A hepatic circulation supplies blood to the liver parenchyma through the portal vein and the hepatic artery. The blood-supplying hepatic vessels are separated and independent. Only at the level of the liver acinus, as the functional unit, there is communication with hepatic veins and drain circulation system. In terms of understanding hemodynamic changes in portal-portal and portal-systemic circulation, it is very important to know this anatomical characteristic and its varieties. [1]. Portal hypertension occurs as a result of morphological changes at the level of parenchyma, which leads to increased resistance and pressure in the portal venous system. The most common causes of portal hypertension are diffused histopathological changes in liver parenchyma, vascular processes of the hepatic vein, decompensation of the right heart, etc. The specific etiological entities that cause portal hypertension include Budd-Chiari and Cruveilhier-Baumgarten syndrome. Increased vascular resistance in the

portal circulation may occur at prehepatic, intrahepatic, and posthepatic levels [1–3]. Clinical diagnosis of portal hypertension is based on anamnesis, laboratory analysis, and endoscopy [4]. In daily practice it is necessary to introduce radiological non-invasive diagnostic techniques [ultrasonography (US), color Doppler ultrasonography (CDU), computed tomography (CT) with contrast administration, or magnetic resonance imaging (MRI)]. Invasive diagnostic techniques such as conventional or digital angiography with direct or indirect presentation of the portal vein are also used. Invasive diagnostic techniques have been suppressed by the development of non-invasive diagnostic techniques, i.e. CDU, CT, and MRI, which are now used for definitive determination of pathological changes of the liver and the portal circulation. The main advantage of CDU is its possibility to determine the morphologic and hemodynamic parameters which are classified as qualitative, quantitative, and semi quantitative [5]. These parameters allow us to determine the presence and direction of

Correspondence to:

Dijana NIĆIFOROVIĆ
Centre for Radiology
Clinical Center of Vojvodina
Hajduk Veljkova 1–4
21000 Novi Sad
Serbia
dijananiciforovic@sbb.rs

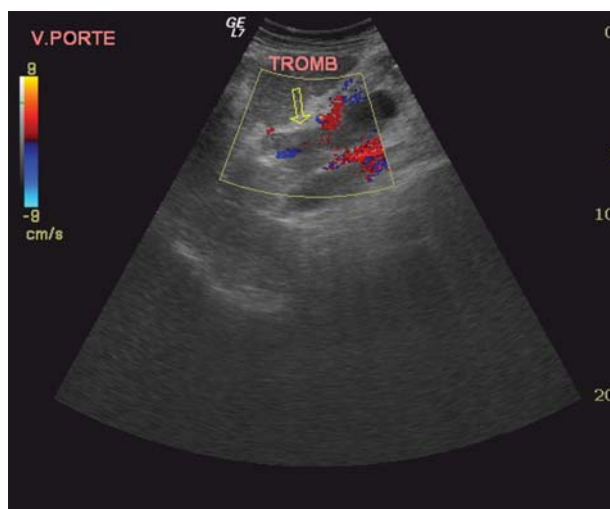


Figure 1. Color Doppler ultrasonography – obstructed lumen by thrombus of dilated portal vein

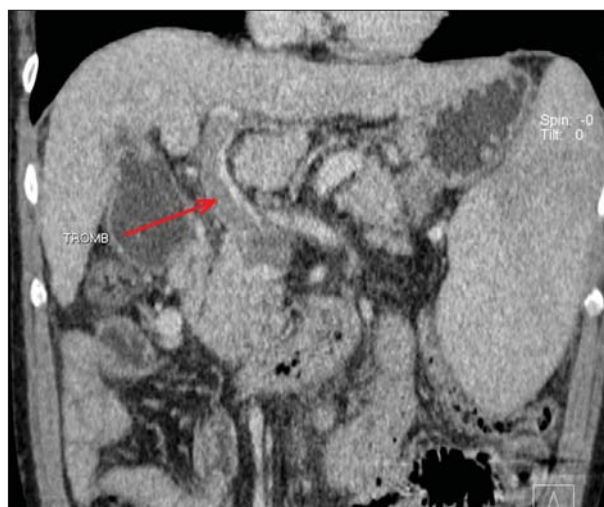

Figure 2. Contrast CT scan – portal thrombosis

flow in it and in its feeding branches, as well as in collaterals developed due to the portal hypertension.

Some of the signs of portal hypertension are the following: increased portal vein diameter (more than 13 mm), portal vein thrombosis (Figures 1 and 2), the presence and the detection of portosystemic collaterals. Increased diameter of the perigastric collaterals that exceeds 6–7 mm is a highly sensitive sign of portal hypertension; however, it is very rare and is seen in approximately 26% of patients with liver cirrhosis [6–10]. CT with contrast administration is a highly sophisticated diagnostic technique for displaying portal circulation. The advantage of CT scan compared with CDU is its high sensitivity and specificity in showing morphologic changes – both distal and proximal from location of the portal vein thrombosis, as well as existence of collaterals. X-ray radiation, iodine contrast agent and inability to determine the speed and direction of flow through blood vessels make CT inferior to CDU. MRI is used in situations when radiologist estimates that CDU and contrast CT scan data are insufficient for evaluation, or when there is a discrepancy in the findings of the previously mentioned techniques.

This study provides original contribution to the field of radiology in our region as it points to the possibility of early and accurate diagnosis when using combined radiological techniques (CDU and contrast CT scan), which is not the case when using these techniques separately.

OBJECTIVE

This study was based on the testing of hypothesis that more data and more precise diagnosis in patients with disorders of portal circulation can be obtained by using CDU and CT with contrast. CDU was used as it shows hemodynamic parameters for early detection of portal hypertension, while CT with contrast was used as it is a technique that provides accurate data on morphological changes, especially in the detection of collateral network and any obstruction caused by thrombosis. With adequate

selection of diagnostic and therapeutic algorithm, and with sophisticated choice of patients, what is achieved by combining CDU and contrast CT is that patients are not exposed to the unnecessary radiation. It has been found that the cumulative sensitivity and specificity of the tested parameters is greater, which justifies the combination of these diagnostic techniques. A relatively small number of articles have been published regarding this topic.

METHODS

The study was designed as a prospective study that comprised 120 patients with liver disease and with high suspicion of portal hypertension. The study included patients who had a clinical diagnosis of liver cirrhosis, hepatitis, portal vein thrombosis, liver tumor, and/or splenomegaly caused by liver disease. The most frequent complications of portal hypertension were bleeding from gastroesophageal varices and ascites in patients with cirrhosis. Patients were divided into three equal groups comprising 40 patients each:

Group 1 – patients examined only by US and CDU;

Group 2 – patients examined only by contrast CT scan, and

Group 3 – patients examined using both CDU and CT.

All three groups had control examinations after six months of therapy and were examined by the same diagnostic technique used during their initial examination. The main inclusion criterion was clinical diagnosis of portal hypertension. The main exclusion criteria were low level of suspicion of portal hypertension, patients with renal insufficiency, and patients under the age of 30.

For statistical analysis we used Statistical Package for Social Sciences software – SPSS 21 for Windows (IBM Corp., Armonk, NY, USA). The analysis used standard methods of descriptive and differential statistics. Numerical characteristics are shown by mean values (arithmetic mean) and a measure of variability (range of values, standard deviation) and attributive characteristics by using frequencies and percentages.

Comparison of numerical values of characteristics between the groups was performed using Student's t-test; statistically significant values are considered to be at the level of $p < 0.05$. The results are presented in tables.

RESULTS

At the Center of Radiology, Clinical Center of Vojvodina, Novi Sad, Serbia, during a period of three years patients with symptoms of gastrointestinal disease and/or biliary tract disease and patients with hematological symptoms were examined using conventional ultrasonography with CDU on Logiq 7 (GE Healthcare, Chicago, IL, USA) machine with a 3.5 MHz probe, and with multislice computed tomography using SOMATOM Sensation Cardiac 64 (Siemens Healthcare GmbH, Erlangen, Germany). A greater number of males were included in the study, i.e. there were 86 (71.7%) males and 34 (28.3%) females. The age of the patients is presented in Table 1. Percentage of patients with the diagnosis of liver cirrhosis amounted to 63.3%, of which 95% was of alcoholic etiology, while the remaining 5% of patients were with biliary, cryptogenic, and immunogenic cirrhosis (Table 2).

At the first examination, in the first group of patients diagnosed using CDU, the average value of the diameter of the portal vein was 12.73 mm, and at the control examination after six months the average lumen width was 12.05 mm. There was a statistically significant difference in the values of measurements ($t = 2.859$, $p < 0.01$). The results of CDU parameters are presented in Table 1. At the first examination, the average flow rate through the portal vein was 0.18 m/s, and at the control examination after six months it was 0.21 m/s. There was a statistically significant difference in the values of measurements ($t = -3.269$, $p < 0.01$). An important parameter in the assessment of portal hypertension is certainly a "congestion index" (CI) of the portal vein. The "congestion index" is used to mean the ratio between the cross-sectional area (cm^2) and the blood flow velocity (cm/s) of the portal vein, as determined by a CDU [11]. It is used for identification of the

initial state of portal hypertension. CI values ($\text{cm} \times \text{s}$) at the first examination and at the control examination after six months were displayed as increased CI (Table 3).

At the first examination, in the second group of patients examined only by contrast CT scan, the average value of the diameter of the portal vein was 14.21 mm, and at the control examination after six months the average lumen width was 12.75 mm. There was a statistically significant difference in the values of measurements ($t = 3.121$, $p < 0.01$). The parameters in surveying by contrast CT scan are presented in Table 3.

The third group of patients was examined by using both techniques, i.e. CDU and contrast CT, and the parameters are presented in Table 4. The average value of the diameter of the portal vein at the first examination was 12.65 mm when done by CDU and 13.42 mm when done by CT. At the control examination after six months the average lumen width was 12.57 mm when done by CDU and 13.17 mm when done by CT. There was a statistically significant difference in the measurement of the average diameter of the portal vein at the first examination between the values determined by the CDU and CT ($t = -2.215$, $p < 0.05$).

Table 1. Age distribution of patients

Age groups (years)	Number of patients
16–25	1
26–35	3
36–45	6
46–55	29
56–65	61
66–75	20

Table 2. Percentage of patients with referred diagnosis

Referred diagnosis	%
Liver cirrhosis	63.3
Thrombosis of the portal vein	10.0
Hepatitis B and C	9.2
Portal hypertension	7.5
Thrombosis in the mesocaval shunt	3.3
Cavernous transformation	3.3
Preparation for transplantation	3.3

Table 3. The results of values obtained by color Doppler ultrasonography (CDU) and by multi-slice computer tomography (MSCT) separately

Parameter	Values obtained by CDU				Values obtained by MSCT			
	First exam		Follow-up at 6 months		First exam		Follow-up at 6 months	
	N	%	N	%	N	%	N	%
Increased diameter of the portal vein	11	27.5	7	17.5	23	57.5	9	22.5
Thrombosis of the portal vein	1	2.5	2	5.0	12	30.0	5	12.5
PV flow – reduced	32	80.0	25	62.5	-	-	-	-
Congestion index – increased	12	30.0	4	10.0	-	-	-	-
Hepatopetal flow	37	92.5	37	92.5	-	-	-	-
Hepatofugal flow	2	5.0	2	5.0	-	-	-	-
Flow not respiratory-dependent	31	77.5	29	72.5	-	-	-	-
Presence of portosystemic collaterals	2	5.0	2	5.0	28	70.0	28	70.0
Absence of portosystemic collaterals	38	95.0	38	95.0	12	30.0	12	30.0
Increased diameter of the splenic vein	28	70.0	14	35.0	10	25.0	5	12.5
Increased AP diameter of the liver	18	45.0	13	32.5	30	75.0	24	60.0
Increased AP diameter of the spleen	25	62.5	21	52.5	25	62.5	15	37.5

N – number of patients; PV – portal vein; AP – anterior-posterior diameter

Table 4. The results of values receive by using color Doppler ultrasonography (CDU) and contrast multi-slice computer tomography (MSCT) together

Parameter	CDU + MSCT			
	First exam		Follow-up at 6 months	
	N	%	N	%
Increased diameter of the portal vein	13	32.5	9	22.5
Thrombosis of the portal vein	6	15.0	4	10.0
Presence of portosystemic collaterals	3	7.5	3	7.5
Increased diameter of the splenic vein	5	12.5	5	12.5
Increased AP diameter of the spleen	24	60.0	24	60.0
Increased AP diameter of the liver	28	70.0	25	62.5

N – number of patients; AP – anterior-posterior diameter

No significant difference in diameter measured by CDU and CT ($t = -1.220$, $p > 0.05$) was observed at the control examination (Table 4).

DISCUSSION

Lumen width of the portal vein was checked in patients who underwent only the CDU examination. The results from this study are consistent with the results of Haag et al. [12]. In a group of 375 patients with liver cirrhosis, who were examined by CDU, Haag et al. [12] found that 112 (30%) patients had expanded lumen of the portal vein, as was found to be the case in our study as well. Our research showed that the sensitivity of CDU in the measurement of the width of the lumen was 85.7% and specificity 97.1%. Lim et al. [13] found that portal vein thrombosis is the most common cause of portal prehepatic hypertension. The authors state that idiopathic thrombosis is rare, but that it is always a complication of other diseases and syndromes. The three causes of thrombosis of the portal vein identified in our study, ordered in their frequency of occurrence, are as follows: liver cirrhosis, hepatocellular carcinoma, and Budd–Chiari syndrome. Since the mid-80s of the 20th century, several studies have been published regarding the functional measurement of portal flow velocity [14–16]. In our study, after the first CDU examination, 32 (80%) patients were found to have decreased flow due to portal hypertension determined by standardized clinical protocols according to Child–Pugh classification [17]. At the control examination after six months, a reduced flow rate was found in 25 (62.5%) patients. This improvement of the flow rate (80% vs. 62.5%) can be explained by a good therapeutic response of the patients to the treatment. Similar data in the literature have not been found. An inverse or hepatofugal flow is one of the indicators of the portal hypertension, which may be registered in some or all of the segmental veins. Our research showed that at the first and at the control CDU examination hepatofugal flow was diagnosed in 2 (5%) patients. Survey data are approximate to the results of the study conducted by Gaiani et al. [18], where out of 228 patients, 68 (3%) had hepatofugal flow. Portosystemic shunt can be seen in 80–90% of patients with portal hypertension [19–21]. Most often, the CDU could register flow in dilated umbilical vein, in

gastroesophageal and splenorenal collaterals, as well as in mesenteric collaterals, which are very rare [22–26]. In our study, in both examinations, CDU showed low sensitivity of 6.7%, while specificity was 100%. The sensitivity of CDU was low, as most of the patients were inadequately prepared, i.e. they were meteoristic and/or had large ascites, which made visualization of organs difficult, particularly the presence of portosystemic collaterals. The duration of the hemodynamic disturbances affects the value of the CI as the pathological changes in vein progress, unless the adequate therapeutic treatment is applied [27]. In a study of 64 liver cirrhosis patients conducted by Moriyasu et al. [27] sensitivity was 55%. Sensitivity recorded in our study was 47.1%, which is slightly lower when compared to the results of Moriyasu et al. [11]. This difference is most likely due to the fact that the patients had varying degrees of damage of the liver parenchyma and variously developed portosystemic collaterals, which could affect differences in flow rate and thus the CI. In portal hypertension the flow is slow and complete loss of oscillation is observed, the curve is not respiratory dependent [28]. Results from our study correlate with the research of Safak et al. [29], which showed that 70% of patients did not have the respiratory-dependent flow. This stipulated fact indicates that ultrasound is a primary diagnostic technique in determination of the diameter of lienal vein in patients with portal hypertension. Sensitivity of this study was 80% and specificity was 93.3%. Splenomegaly is a common finding in patients with portal hypertension. Ultrasonography has high sensitivity (92%) and specificity (100%) in case of splenomegaly, as determined in our research, which correlates with the literature, which quotes similar results, i.e. sensitivity 95% and specificity 98% [30]. A combination of the two diagnostic techniques (CDU and contrast CT scan) gives more precise information on the morphology and hemodynamic changes in patients with portal hypertension, which is not the case when these techniques are used separately. In Group 3, in patients examined by CDU and CT, the diameter of the portal vein showed that the cumulative sensitivity was 93.3% and the specificity was 100%. Furthermore, sensitivity and specificity for the presence of thrombus in the portal vein and splenomegaly was 100%. In measuring the width of lienal vein lumen, the cumulative sensitivity was 71.5% and specificity was 100%. The study previously mentioned intra- and extrahepatic portosystemic collateral in patients with portal hypertension [31, 32]. In determination of portosystemic collaterals, we found that cumulative sensitivity of CDU and CT was 41.9% and specificity was 100%. Low cumulative sensitivity of both techniques in the diagnosis of portosystemic collaterals can be explained by low sensitivity of CDU, which directly affects cumulative value and is caused by the previously mentioned reasons regarding difficult visualization by CDU (due to presence of gas, ascites, etc.). Similar data was stated by Nelson et al. [33] in their study of 64 patients, where they had a good correlation in diagnosing esophageal varices found in 68% of the patients, while the percentage of patients with splenic and spleno-renal varices was significantly lower and was found in 22% of the patients.

CONCLUSION

The advantage of CDU is possibility to determine the morphologic and hemodynamic parameters. These parameters allow us to determine the presence and direction of flow. CT with contrast administration is highly sophisticated diagnostic technique in the detection of morphologic changes like collateral network and any obstruction caused by thrombosis. X-ray radiation, iodine contrast agent, and inability to determine the speed and direction of flow through the blood vessels make CT inferior to CDU. A cumulative sensitivity and specificity in

most parameters (diameter of the portal vein, the presence of thrombus in the portal vein, lienal vein diameter, anterior–posterior diameter of the liver and spleen) was higher than when these techniques are used separately, except for determination of portosystemic collaterals (sensitivity of CDU and contrast CT scan was 41.9%, and specificity of both techniques was 100%) in patients with portal hypertension.

This study emphasizes the possibility of early and accurate diagnosis when combining two radiological methods (CDU and contrast CT scan), which is not the case when these methods are used separately.

REFERENCES

- Rossi P, Nardo Di, Zolovkins A, Marcelli G, Coniglio M. Angiography and Radiologic Anatomy of the Portal System. In: Rossi P, Ricci P, Broglia P, editors. Portal Hypertension: Diagnostic Imaging and Imaging – Guided Therapy. Berlin, Heidelberg, New York: Springer Verlag; 2000. p. 35–49.
- Lafortune M, Patriquin H, Lepanto L. Color Doppler of Portal Hypertension: A Pictorial Essay. In: Rossi P, Ricci P, Broglia P, editors. Portal Hypertension: Diagnostic Imaging and Imaging – Guided Therapy. Berlin, Heidelberg, New York: Springer Verlag; 2000. p. 83–4.
- Manzano-Robleda Mdel C, Barranco-Fragoso B, Uribe M, Mendez-Sanchez N. Portal vein thrombosis: What is new? *Ann Hepatol.* 2015; 14(1):20–7. [PMID: 25536638]
- Mekaroonkamol P, Cohen R, Chawla S. Portal hypertensive enteropathy. *World J Hepatol.* 2015; 7(2):127–38. [DOI: 10.4254/wjh.v7.i2.127] [PMID: 25729469]
- Bolondi L, Piscaglia F, Valimigli M, Gaiani S. Doppler ultrasound in portal hypertension. In: Rossi P, Ricci P, Broglia P, editors. Portal Hypertension: Diagnostic Imaging and Imaging – Guided Therapy. Berlin, Heidelberg, New York: Springer Verlag; 2000. p. 57–73.
- Vilgrain V, Lebrec D, Menu Y, Scherrer A, Nahum H. Comparison between ultrasonographic signs and the degree of portal hypertension in patients with cirrhosis. *Gastrointest Radiol.* 1990; 15(3):218–22. [PMID: 2187730]
- Nićiforović D, Till V, Hadnađev D, Govorčin M, Lučić Z, Lovrenski J. Duplex Doppler sonography in portal hypertension. *Med Pregl.* 2007; 60(3-4):161–7. [DOI: 10.2298/MPNS0704161N] [PMID: 17853729]
- Subramany BR, Balthazar EJ, Madamba MR, Raghavendrab N, Horii SC, Lefleur RS. Sonography of portosystemic venous collaterals in portal hypertension. *Radiology.* 1983; 146(1):161–6. [DOI: 10.1148/radiology.146.1.6849040] [PMID: 6849040]
- Wachsberg RH, Simmons MZ. Coronary vein diameter and flow direction in patients with portal hypertension: evaluation with duplex sonography and correlation with variceal bleeding. *AJR Am J Roentgenol.* 1994; 162(3):637–41. [DOI: 10.2214/ajr.162.3.8109512] [PMID: 8109512]
- Chawa YK, Bodh V. Portal Vein thrombosis. *J Clin Exp Hepatol.* 2015; 5(1):22–40. [DOI: 10.1016/j.jceh.2014.12.008] [PMID: 25941431]
- Moriyasu F, Nishida O, Ban N, Nakamura T, Sakai M, Miyake T, et al. „Congestion index“ of the portal vein. *AJR Am J Roentgenol.* 1985; 146(4):735–9. [DOI: 10.2214/ajr.146.4.735] [PMID: 3485345]
- Haag K, Roessle M, Ochs A, Huber M, Siegerstetter V, Olschewski M, et al. Correlation of duplex Doppler sonography findings and portal pressure in 375 patients with portal hypertension. *AJR Am J Roentgenol.* 1998; 172(3):631–5. [DOI: 10.2214/ajr.172.3.10063849] [PMID: 10063849]
- Lim JH, Park JH, Auh YH. Membranous obstruction of the inferior vena cava: comparison of findings at sonography, CT and venography. *AJR Am J Roentgenol.* 1992; 159(3):515–20. [DOI: 10.2214/ajr.159.3.1503015] [PMID: 1503015]
- Ohnishi K, Saito M, Pugliese D, Tsunoda T, Saito M, Okuda K. Changes of splanchnic circulations with progression of chronic liver disease studied by echo-Doppler flowmetry. *Am J Gastroenterology.* 1987; 82(6):507–11. [PMID: 2953238]
- Brown HS, Halliwell M, Qamar M, Read AE, Evans JM, Wells PN. Measurement of normal portal venous blood flow by Doppler ultrasound. *Gut.* 1989; 30(4):503–9. [DOI: 10.1136/gut.30.4.503] [PMID: 2653973]
- Mostbeck GH, Wittich GR, Herold C, Vergesslich KA, Walter RM, Frotz S, et al. Hemodynamic significance of the paraumbilical vein in portal hypertension: assessment with duplex US. *Radiology.* 1989; 170(2):339–42. [DOI: 10.1148/radiology.170.2.2643137] [PMID: 2643137]
- Pugh RN, Murray-Lyon IM, Dawson JL, Pietroni MC, Williams R. Transection of the oesophagus for bleeding oesophageal varices. *Brit J Surg.* 1973; 60(80):646–9. [DOI: 10.1002/bjs.1800600817] [PMID: 4541913]
- Gaiani S, Bolondi L, Li Bassi S, Zironi G, Barbara L. Prevalence of spontaneous hepatofugal portal flow in liver cirrhosis. Clinical and endoscopic correlation in 228 patients. *Gastroenterology.* 1991; 100(1):160–7. [PMID: 1983817]
- Morin C, Lafortune M, Pomier G, Robin M, Breton G. Patent paraumbilical vein: anatomic and hemodynamic variants and their clinical importance. *Radiology.* 1992; 185(1):253–6. [DOI: 10.1148/radiology.185.1.1523319] [PMID: 1523319]
- Lebrec D, Sogni P, Vilgrain V. Evaluation of patients with portal hypertension. *Baillieres Clin Gastroenterol.* 1997; 11(2):221–41. [DOI: 10.1016/S0950-3528(97)90037-3] [PMID: 9395745]
- Lin ZY, Chen SC, Hsieh MY, Wang CW, Chuang WL, Wang LY. Incidence and clinical significance of spontaneous intrahepatic portosystemic venous shunts detected by sonography in adults without potential cause. *J Clin Ultrasound.* 2006; 34(1):22–6. [DOI: 10.1002/jcu.20176] [PMID: 16353230]
- Saccerdoti D, Bolognesi M, Bombato G, Gatta A. Paraumbilical vein patency in cirrhosis: effect on hepatic hemodynamics evaluated by Doppler sonography. *Hepatology.* 1995; 22(6):1689–94. [DOI: 10.1002/hep.1840220612] [PMID: 7489975]
- Golli M, Kriaa S, Said M, Belguith M, Zbidi M, Saad J, et al. Intrahepatic spontaneous portosystemic venous shunt: value of color and power Doppler sonography. *J Clin Ultrasound.* 2000; 28(1):47–50. [DOI: 10.1002/(SICI)1097-0096(200001)28:1<47::AID-JCU8>3.0.CO;2-V] [PMID: 10602106]
- Li FH, Hao J, Xia JG, Li HL, Fang H. Hemodynamic analysis of esophageal varices in patients with liver cirrhosis using color Doppler ultrasound. *World J Gastroenterol.* 2005; 11:4560–5. [DOI: 10.3748/wjg.v11.i29.4560] [PMID: 16052688]
- Alempijević T, Sokic-Milutinovic A, Milicic B, Jescic R, Balovic A, Popovic D, et al. Noninvasive assessment of portal hypertension in patients with alcoholic cirrhosis. *Turk J Gastroenterol.* 2012; 23(3):239–46. [DOI: 10.4318/tjg.2012.0463] [PMID: 22798113]
- Al-Nakshabandi NA. The role of ultrasonography in portal hypertension. *Saudi J Gastroenterol.* 2006; 12(3):111–7. [PMID: 19858596]
- Kim G, Cho YZ, Baik SK, Kim MY, Hong WK, Kwon SO. The accuracy of ultrasonography for the evaluation of portal hypertension in patients with cirrhosis: a systematic review. *Korean J Radiol.* 2015; 16(2):314–24. [DOI: 10.3348/kjr.2015.16.2.314] [PMID: 25741193]
- Bolondi L, Li Bassi S, Gaiani S, Zironi G, Benzi G, Santi V, et al. Liver cirrhosis: changes of Doppler waveform of hepatic veins. *Radiology.* 1991; 178(2):513–6. [DOI: 10.1148/radiology.178.2.1987617] [PMID: 1987617]
- Safak AA, Simsek E, Bahcebasi T. Sonographic assessment of the normal limits and percentile curves of liver, spleen, and kidney

- dimensions in healthy school-aged children. *J Ultrasound Med.* 2005; 24(10):1359–64. [PMID: 16179618]
30. Hagg K, Weimann A, Zeller O, Spamer C, Srollinger M, Rossle M. Splenic size and duplex sonography determination of blood flow in the vena lienalis and vena portae in liver cirrhosis. *Bildgebung.* 1992; 59(2):80–3. [PMID: 1511215]
31. Zardi EM, Uwechie V, Caccavo D, Pellegrino NM, Cacciapaglia F, Di Matteo F, et al. Portosystemic shunts in a large cohort of patients with liver cirrhosis: detection rate and clinical relevance. *J Gastroenterol.* 2009; 44(1):76–83. [DOI: 10.1007/s00535-008-2279-1] [PMID: 19159076]
32. Adaletli I, Baris S, Gulsen G, Kurugoglu S, Kantarci F, Mihmanli I, et al. Comparison of color doppler US and CT portography in evaluating portal hypertension in children. *South Med J.* 2012; 105(1):6–10. [DOI: 10.1097/SMJ.0b013e31823cfae2] [PMID: 22189660]
33. Nelson RC, Sherbourne GM, Spencer HB, Chezmar JL. Splenic venous flow exceeding portal venous flow at Doppler sonography: relationship to portosystemic varices. *AJR. Am J Roentgenol.* 1993; 161(3):563–7. [DOI: 10.2214/ajr.161.3.8352105] [PMID: 8352105]

Улога колор доплер ултрасонографије и компјутеризоване томографије у процени портне хипертензије

Дијана Ниђифоровић¹, Виктор Тил¹, Викторија Вучај-Ђириловић², Коста Петровић¹, Мирела Јуковић¹, Дарка Хаднађев-Шимоњи¹, Жељка Савић³, Едита Стокић⁴, Катарина Шарчев⁵

¹Клинички центар Војводине, Центар за радиологију, Нови Сад, Србија;

²Институт за онкологију Војводине, Центар за имџинг дијагностику, Сремска Каменица, Србија;

³Клинички центар Војводине, Клиника за гастроентерологију и хепатологију, Нови Сад, Србија;

⁴Клинички центар Војводине, Клиника за ендокринологију, дијабетес и болести метаболизма, Нови Сад, Србија;

⁵Клинички центар Војводине, Клиника за абдоминалну, ендокрину и трансплантациону хирургију, Нови Сад, Србија

КРАТАК САДРЖАЈ

Увод Обољења јетре праћена поремећајем јетрене и спланхичне циркулације изазивају портну хипертензију, са тромбозом вене порте или без ње.

Циљ рада Ово испитивање је засновано на провери хипотезе о добијању већег броја података и прецизнијег постављања дијагнозе код болесника са поремећајем портне циркулације коришћењем колор доплер ултрасонографије (КДУ) и контрастне компјутеризоване томографије (КТ).

Методе рада Истраживање је обухватило 120 болесника, од фебруара 2011. до маја 2014. године, са сумњом или већ клинички потврђеном портном хипертензијом, болеснике са хепатитисом и неколико болесника са хематолошким обољењима. Прва група од 40 болесника је прегледана конвенционалном ултрасонографијом и КДУ, друга група контрастним КТ и трећа група болесника је прегледана уз

помоћ обе методе (КДУ и контрастним КТ). Шест месеци након примењене адекватне терапије начињени су контролни прегледи.

Резултати Ретроспективна анализа је показала да је КДУ осетљивија од КТ у процени постојања и старости тромба (КДУ 93,9%, КТ 86,1%). КТ даје прецизне податке у откривању портосистемских колатерала. Осетљивост КТ је 100%, а специфичност 67%. Кумулативна осетљивост и специфичност у већини параметара су повећане у односу на методе понаособ.

Закључак Ова студија истиче могућност постављања ране и прецизније дијагнозе комбиновањем две дијагностичке методе (КДУ и КТ са интравенским контрастом), што није случај када се те методе примењују појединачно.

Кључне речи: колор доплер ултрасонографија; портна хипертензија; портна тромбоза; компјутеризована томографија

Примљен • Received: 02/11/2015

Ревизија • Revision: 01/04/2016

Прихваћен • Accepted: 27/04/2016