

Vojislav Arnovljević described “Sézary syndrome” ten years before Sézary and Bouvrain

Nataša Čolović^{1,3}, Marko Janković², Danijela Leković^{1,3}, Mirjana Gotić^{1,3}

¹University of Belgrade, School of Medicine, Belgrade, Serbia;

²School of Medicine, Institute of Microbiology, Belgrade, Serbia;

³Clinical Center of Serbia, Clinic of Haematology, Belgrade, Serbia

SUMMARY

In 1938 Sézary and Bouvrain reported on a patient with a set of symptoms which later began to carry an eponymous designation “Sézary syndrome.” Ten years previously, Vojislav Arnovljević had described a patient with exactly the same set of symptoms, as well as physical, laboratory, autopsy, and histopathology findings. Unfortunately, his contribution remained unnoticed, not only by the international but Serbian audience as well.

In 1928, in the *Serbian Archives of Medicine*, in Serbian, Vojislav Arnovljević published an article titled “The chronic lymphoid leukaemia with skin lymphomatosis,” in which he described a 43-year-old man with a two-year history of progressive development of a diffuse erythroderma with itching and hair loss over the entire torso, leukemia of 240,000/mm³, 91% of which lymphocytes and 5% eosinophils, who soon after admission developed a bronchopulmonary infection and died. The autopsy showed a pronounced lymphadenopathy in axillae, chest, and abdomen, enlarged liver and spleen with multiple infiltrates and thick skin. The histology confirmed a profound lymphocyte infiltration of axillar, mediastinal and abdominal lymph nodes, as well as liver, spleen and skin, while “the reaction of the other parts of the lymph and blood systems was relatively weak.”

There is more than enough clinical, laboratory, autopsy and histological evidence to support that the patient Arnovljević described in 1928 had a syndrome that ten years later was described by Sézary and Bouvrain, which now bears the eponymous designation of Sézary syndrome.

Keywords: erythroderma; itching; lymphadenopathy; lymphoid leukemia; eosinophilia; hepatosplenomegaly

INTRODUCTION

In 1938 Sézary and Bouvrain described a triad of symptoms consisting of erythroderma, leukemia with circulating mononuclear cells containing large atypical mononuclear cells with a large, convoluted, single cerebriform nucleus, and enlarged lymph nodes infiltrated by these cells [1]. They were later named Sézary cells, which further turned out to be T-lymphocytes. At present, apart from the aforementioned triad, in order to establish a diagnosis of Sézary syndrome, one of the following criteria is required: an absolute Sézary cells count of at least 1,000 mm³; an expanded CD4+ T-cell population resulting in a CD4+/CD8+ ratio of more than 10 and/or loss of one or more T-cells or more antigens [2]. Eosinophilia and increased levels of immunoglobulin E may also be present as a consequence of possible Sézary cell-induced heightened secretion of IL-4 and IL-5 [3], which could lead to terminal organ insufficiency [4, 5].

The aim of the report is to show that Arnovljević had described exactly the same syndrome ten years before Sézary and Bouvrain.

ARNOVLJEVIĆ’S REPORT OF A PATIENT

Dr. Vojislav Arnovljević was a clinical assistant to Professor Radenko Stanković, head of the

Internal Propedeutic Clinic of the School of Medicine of Belgrade, Serbia (Figure 1).

Arnovljević’s description of “Chronic lymphoid leukaemia with skin lymphomatosis” was published in the *Serbian archives of Medicine* in 1928 [6]. Two years prior to admission, a 43-year-old male exhibited initial symptoms of a burning sensation and itching, as well as a minor red and glossy skin lesion on his right lumbar area. The redness and edema gradually spread from the lesion over the waist, then to the back, towards the left shoulder, lastly upwards and downwards, until it enveloped the entire torso. Hair loss from the head (scalp and moustache), armpits, and pubic region followed. The abdomen was getting progressively enlarged and the patient tired quickly. He reported no pain.

On examination, the skin of the face, neck, shoulders, arms, and legs was atrophic, thin, glossy, tense, and pale, while the skin on the thorax, abdomen, scrotum, and the upper half of the thighs was livid-red, dry, very hard and thickened, with creases, folds, and cuts as deep as seen in elephantiasis, particularly conspicuous on the side, under the armpits and in the groin (Figure 2). On the transition from the infiltrated towards the atrophic part of the skin, especially on the thorax, lesser infiltrative nodes in the form of larger and smaller papules could be observed. Hair was missing from under the armpits and the pubic area. Hair on

Correspondence to:

Nataša ČOLOVIĆ
Clinic of Hematology
Clinical Center of Serbia
Dr Koste Todorovića 2
11010 Belgrade
Serbia
natasacolovic73@gmail.com



Figure 1. Dr. Vojislav Arnovljević, first on the left; Professor Radenko Stanković in the middle; picture taken approximately at the time of presentation

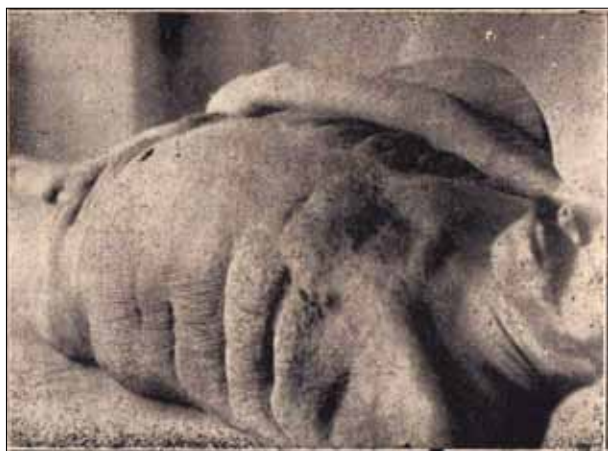

Figure 2. The skin of the thorax, abdomen, scrotum, and the upper half of the thighs was livid-red, dry, very hard and thickened, with creases, folds and cuts as deep as seen in elephantiasis, particularly conspicuous on the side, under the armpits and in the groin [6] (reproduced with permission of the *Serbian Archives of Medicine (Srpski arhiv za celokupno lekarstvo)*)

the scalp was very thin, hairs small and "moustache very sparse and falling off." Submandibular and neck lymph nodes were not enlarged, while the axillar and inguinal ones could not be palpated because of the thickened skin. The tonsils were of normal size. The infiltrated and thick skin allowed no palpation or percussion of liver or spleen.

The blood analyses were as follows: hemoglobin 50%; erythrocytes 3,000,000 mm^3 ; leukocytes 280,000 mm^3 . The leukocyte formula showed 91% lymphocytes

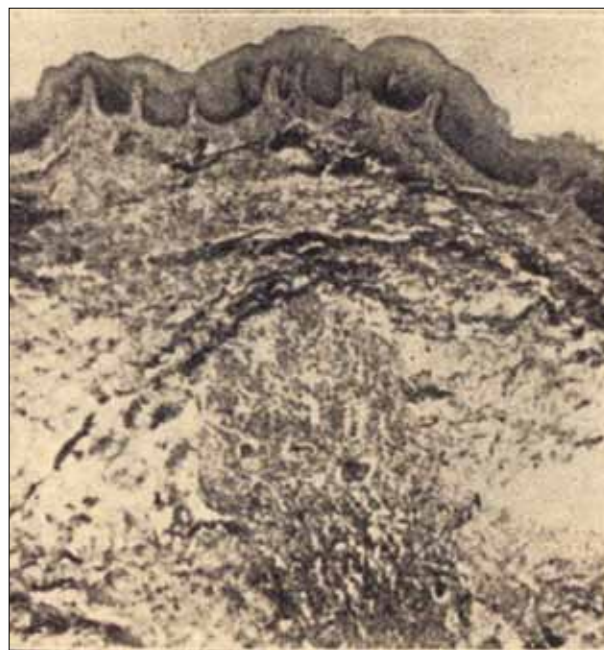


Figure 3. Histology of the skin showing thickness which was "due to deposits of small, round cells, most prevalent in the lower parts of the dermis, around the papillary bodies, where they are particularly grouped around and along blood vessels, forming the proper follicles" [6] (reproduced with permission of the *Serbian Archives of Medicine (Srpski arhiv za celokupno lekarstvo)*)

(254,800 mm^3), 5% eosinophilic leukocytes (14,000 mm^3), and 4% polymorphonuclear neutrophilic leukocytes (11,206 mm^3). Erythrocyte sedimentation rate after one

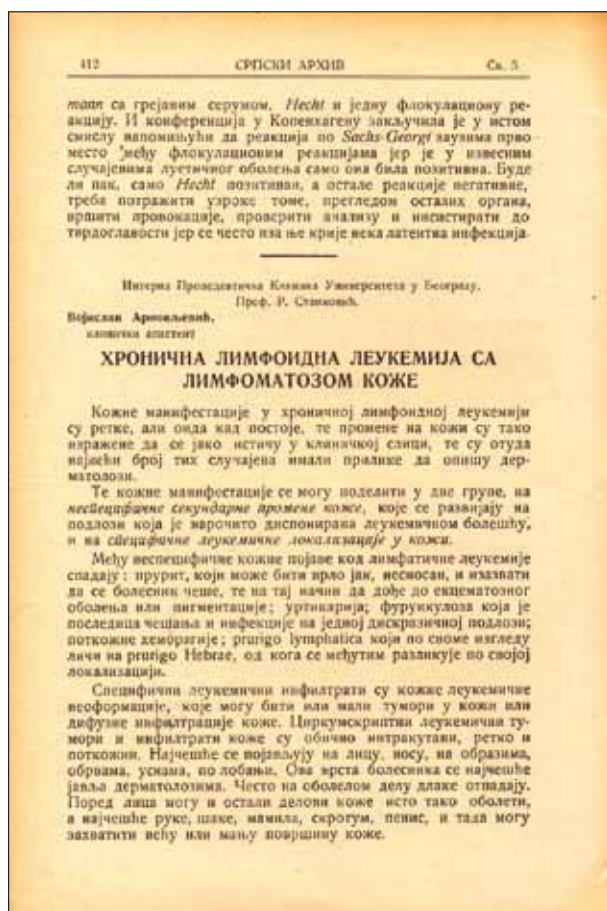


Figure 4. The first page of Arnovljević's paper [6] (reproduced with permission of the *Serbian Archives of Medicine (Srpski arhiv za celokupno lekarstvo)*).

hour was 40 (Westergren). The Bordet–Wassermann reaction was negative.

On the third day after admission, the patient developed a fever of up to 39.5°C and started coughing, initially without sputum. In the following days, he manifested signs of bronchitis and the sputum became purulent. The fever lowered to 38°C, but a state of “cardiac adynamia occurred” and the patient died on the sixth day after admission.

The autopsy findings are as follows: the skin on the thorax and abdomen was hypertrophic, an average thickness of 1–1.5 centimeters. About 1 liter of clear fluid was found in the abdominal cavity. The liver and spleen were enlarged, the liver weighing 2,700 g, and the spleen weighing 2,040 g, with 28 × 17 × 7 cm in size. On the spleen transection “numerous diffusely scattered focal sites paler in hue were found, ranging in size from a grain of millet to a grain of corn.” “On section, the lungs were reddish and hyperemic, a purulent-foamy liquid exited the bronchi and the alveoli were dilated.”

“The thoracic and mesenteric lymph nodes were much enlarged, hard in consistency, yellowish-red in color on the section with a much hypertrophied lymphatic tissue. The reaction of the other parts of the lymph and blood systems was relatively weak.”

Histopathology of the skin showed thickness which was “due to deposits of small, round cells, most prevalent in

the lower parts of the dermis, around the papillary bodies, where they are particularly grouped around and along blood vessels, forming proper follicles” (Figure 3).

Arnovljević states that “both the clinical and the pathological features in this case are characteristic of chronic lymphoid leukemia”, but that “the pronounced leukemic skin lesions stand out so much that in the majority of similar cases they were described under the joint term of skin leukemia (leukemia cutis, lymphadenosis cutis, or lymphodermia)”. Arnovljević rather disputes this terminology “because according to these designations one might assume that the skin condition was the basis of the disease. These manifestations are, however, only an additional sign of an illness that at its foundation has typical changes in the hematopoietic system that underlie all other disease related pathology. Therefore, it is much more accurate to emphasize in the name of the disease its most important feature, and that is leukemia. Besides this defining element, it is also important to note its particular clinical aspect, and that is the lymphocytic infiltration of the skin. Having all this in mind, we have named this specific case chronic lymphoid leukemia with skin lymphomatosis.”

The author states that “it is very rare that a skin leukemic infiltration spreads across the whole of the torso, abdomen, back, hips and upper part of the thighs, all the while being of such intensity that it creates skin folds seen only in elephantiasis.” He further notes that the leukemic infiltrates, or leukemic lymphomas, were most prominent on the skin, followed by changes in the spleen, liver and several axillary and mesenteric lymph nodes. These pathological findings were considerably less expressed on the other parts of the lymph and blood systems. Finally, the author calls to attention the striking peripheral blood eosinophilia amounting to 5% of total leukocyte count, which “has not been described in any of the cases of lymphoid leukemia so far.” For this finding Arnovljević had no clear explanation.

DISCUSSION

Sézary syndrome is a very rare disease comprising less than 5% of all cutaneous T-cell lymphomas [7]. It is predominant in men, more often those older than 60 years [2]. Being a leukemia, in its advanced phase, Sézary syndrome could affect all organs, while bone marrow stays preserved the longest [2].

The most frequent symptoms inciting patients to seek medical help are erythroderma and generalized lymphadenopathy. Less often there are itching, alopecia, plantar or palmar hyperkeratosis, onychodystrophy, and ectropion [2].

An increased frequency of cutaneous and systemic malignancies seen in these patients is attributed to reduced immunity caused by the loss of normal circulating CD4+ T-cells [8].

The disease has a poor prognosis. Even with modern therapy, only 10–20% of patients survive more than five years [7].

The main causes of death are opportunistic infections [2]. Prognosis tends to be worse with the larger numbers of Sézary cells in the peripheral blood and with larger lymphadenopathy [9, 10].

When comparing the original and modern descriptions of Sézary syndrome with the one from Arnovljević, what is obvious is an almost complete match of accounts. Arnovljević's male patient had a characteristic triad (erythroderma with itching, leukemia with circulating mononuclear lymphocytes and axillar, thoracic, and abdominal lymph node enlargement with leukemic cell infiltration) while the infiltration of other parts was „considerably less expressed on the other parts of the lymph and blood systems.“ The description of skin changes is also characteristic of the disease. Disseminated erythroderma and hair loss from almost the entire body, including hair from the scalp and moustache, are typical as well.

Peripheral blood findings unequivocally indicated leukemia with 91% of lymphocytes, as well as elevated counts of eosinophils of 5%, which is also frequent in Sézary syndrome. Unfortunately, we lack a more detailed account of the appearance of lymphocytes in peripheral blood. As the symptoms developed for two years, there was more than enough time for the pathologic changes to occur within the liver and the spleen, which were undoubtedly infiltrated with abnormal lymphocytes, today known as Sézary cells.

Patients with Sézary syndrome have a marked tendency towards developing opportunistic infections, which are the leading cause of death in this population. This was indeed the case with Arnovljević's patient, who died of

lung infection on the third day since the symptoms first appeared (coughing soon followed by expectoration and high grade fever). The rapidity of the unfavorable outcome was not only due to lack of antibiotic therapy at the time, but also as a consequence of reduced immunity, a typical occurrence in these patients. It is a possibility that eosinophilia could have also contributed to the speed at which death occurred as well. It was possible that the pronounced eosinophilia had contributed to the rapid death outcome.

Although the detailed description of pathologic lymphocytes in peripheral blood is lacking, the account provided by the author offers such an abundance of information that it could be said with certainty that the disease was, in fact, Sézary syndrome. Arnovljević correctly understood that the pathologic changes in the skin are a secondary manifestation of a generalized illness, which he described as chronic lymphoid leukemia.

CONCLUSION

Notwithstanding a deficient depiction of the aforementioned lymphocytes, especially of their nuclei, all of the other information strongly advocates in favor of Sézary syndrome. It is unfortunate that this case, reported ten years prior to that of Sézary and Bouvrain, was published in Serbian and not in international scientific literature, because it would have certainly not been unnoticed. Surprisingly, it has not been recognized even by the Serbian hematologists so far.

REFERENCES

1. Sézary A, Bouvrain Y. Erythrodermia avec presence de cellules monstreuses dans le derme et le sang circulant. *Bull Soc Fr Dermatol Syphil.* 1938; 45:254–60.
2. Ralfkiaer E, Willemze R, Whittaker SJ. Sézary syndrome. In: Swerdlow SH, Campo E, Harris NL, et al., eds. *WHO Classification of Tumours of Haematopoietic and Lymphoid Tissues.* Lyon: IARC Press; 2006. p. 299.
3. Borish L, Dishuch J, Cox L, Mascali JJ, Williams J, Rosenwasser LJ. Sezary syndrome with elevated serum IgE and hypereosinophilia: role of dysregulated cytokine production. *J Allergy Clin Immunol.* 1993; 92:123–31. [PMID: 8335848]
4. Davarifar A, Julian R, Vipul P, Yilmaz E, Verma A. Profound hypereosinophilia secondary to Sezary syndrome. *Blood.* 2015; 126(23):50–3.
5. Mišćević N, Suvajdžić N, Jovanović V, Janković G, Radošević N, Čolović M. Sezarijev sindrom (prikaz bolesnika). *Srp Arh Celok Lek.* 1995; 123(3–4):102–4. [PMID: 16296236]
6. Arnovljević V. Hronična limfoidna leukemija sa limfomatozom kože. *Srp Arh Celok Lek.* 1928; 30(5):412–7.
7. Willemze R, Jaffe ES, Burg G, Cerroni L, Berti E, Swerdlow SH, et al. WHO-EORTC classification for cutaneous lymphomas. *Blood.* 2005; 105:3768–85. [DOI: 10.1182/blood-2004-09-3502] [PMID: 15692063]
8. Huang KP, Weinstock MA, Clarkee CA, McMillan A, Hoppe RT, Kim YH. Second lymphomas after malignant neoplasm in patients with mycosis fungoides and Sezary syndrome: evidence from population-based and clinical cohorts. *Arch Dermatol.* 2007; 143:45–50. [DOI: 10.1001/archderm.143.1.45] [PMID: 17224541]
9. Klemke CD, Mansmann U, Poenitz N, Dippel E, Goerdts S. Prognostic factors and prediction of prognosis by the CTCL. Severity index in mycosis fungoides and Sezary syndrome. *Br J Dermatol.* 2005; 153:118–24. [DOI: 10.1111/j.1365-2133.2005.06676.x] [PMID: 16029336]
10. Vonderheid EC, Pena J, Nowell P. Sezary cell counts in erythrodermic cutaneous T-cell lymphoma: implication for prognosis and staging. *Leuk Lymphoma.* 2006; 47:1841–56. [DOI: 10.1080/10428190600709655] [PMID: 17064997]

Војислав Арновљевић је описао Сезаријев синдром десет година пре Сезарија и Буврена

Наташа Чоловић^{1,3}, Марко Јанковић², Данијела Лековић^{1,3}, Мирјана Готић^{1,3}

¹Универзитет у Београду, Медицински факултет, Београд, Србија;

²Медицински факултет, Институт за микробиологију, Београд, Србија;

³Клинички центар Србије, Клиника за хематологију, Београд, Србија

Сезари и Буврен су 1938. године описали болесника са групом симптома која је по Сезарију касније добила име. Десет година раније, Војислав Арновљевић је описао болесника са потпуно истом клиничком сликом, али је тај рад у литератури остао незапажен.

У Српском архиву за целокупно лекарство од 1928. године, Војислав Арновљевић је објавио чланак под називом „Хронична лимфоидна леукемија са лимфоматозом коже“, приказавши 43 године старог болесника са две године дугом анамнезом болести, који је имао еритродермију коже целог трупа, праћену сврабом, опадањем длака скоро са целог тела, леукемију са 240.000 леукоцита у mm^3 , од чега су 91% били лимфоцити и 5% еозинофили, увећане лимфне жлезде у пазушним јамама, грудном кошу и абдомену, увећану јетру и нарочито слезину са макроскопски видљивим инфил-

тратима, који је трећег дана по пријему на клинику постао високофебрилан, почео да кашље и искашљава и који је после два дана летално завршио од плућне инфекције, што је потврђено обдукционим налазом, при којој је хистолошки нађена масивна инфилтрација лимфоидним ћелијама коже и лимфних жлезда пазушних јама, грудног коша и абдомена, јетре и слезине, док је остали део лимфног и крвног система био углавном сачуван.

Иако има неких малих мањкавости, има више него довољно клиничких, лабораторијских, аутопсијских и хистолошких доказа да је Арновљевић описао болесника са синдромом који су десет година касније описали Сезари и Буврен, а који је по Сезарију добио име.

Кључне речи: еритродермија; пруритус; лимфаденопатија; лимфоидна леукемија; еозинофилија; хепатоспленомегалија

Примљен • Received: 25/05/2016

Ревизија • Revision: 16/08/2016

Прихваћен • Accepted: 19/08/2016