

Benign cystic teratoma of the mesosigmoid – Report of a case

Berislav Vekić¹, Rastko Živić¹, Marko Kalezić¹, Predrag Matić²

¹Clinical Center "Dr Dragiša Mišović – Dedinje", Surgical Clinic, Belgrade, Serbia;

²Institute for Cardiovascular Diseases "Dedinje", Clinic for Vascular Surgery, Belgrade, Serbia

SUMMARY

Introduction Extragenadal intraperitoneal teratomas are very rare, especially those arising from mesentery and mesocolon. In the contemporary literature only 22 cases of such tumors have been published and described.

Case Outline We report a case of a 52-year-old woman with a benign cystic teratoma of the mesosigmoid. The patient presented with mild clinical signs of intestinal obstruction. Computerized tomography of the pelvis and abdomen showed a large 9.7 × 8.9 × 9.4 cm calcified tumor in the lower part of the left hemiabdomen. Extraluminal obstruction was verified by colonoscopy at 35 cm from the anal verge. Intraoperatively, a cystic calcified tumor of the mesosigmoid was found causing extraluminal obstruction of the left colon. The tumor was extirpated and a partial resection of the adherent great omentum was performed. The histopathological examination revealed a benign cystic teratoma.

Conclusion Considering the fact that mesenteric teratomas are extremely rare tumors, it is difficult to designate a general conclusion for an adequate treatment of patients suffering from them. Complete surgical excision is indicated in order to establish a correct histopathological diagnosis and to relieve the patients of symptoms.

Keywords: mesosigmoid benign cystic teratoma; intestinal obstruction; colonic surgery

INTRODUCTION

Teratomas are tumors composed of a mixture of tissues derived from the three embryonic germinal layers and are, consequently, considered to be neoplastic counterparts of embryonic tissues. As in gonadal and extragonadal examples, there are two variants identified – mature and immature teratomas. The histologic appearance and malignant potential of teratomas is determined by the degree of immaturity of the tissue components [1]. Mature teratomas are generally multicystic and composed of a mixture of recognizable mature elements including keratin balls, hair, cartilage and bone. Most benign teratomas are composed of mature cells; however, 20–25% of these also contain immature elements, mostly the neuroepithelium [1]. The most common site of extragonadal teratoma is the sacrococcygeal region followed by neck, mediastinum, central nervous system, paranasal sinuses, liver, uterine cervix, stomach, abdominal wall, omentum and peritoneum [2]. Extragenadal intraperitoneal teratomas, especially those arising from mesentery and mesocolon, are very rare – only 22 cases of such tumors have been published and described in the contemporary literature [3].

CASE REPORT

A 52-year-old woman presented to the emergency room with clinical signs of mild intestinal obstruction, which were associated with

irregular stool, abdominal discomfort and distension. On the manual abdominal examination, she was found to have a slightly distended abdomen and a palpable nontender mass in the left hemiabdomen, with no signs of peritonism. She had no previous abdominal operations. Rectal examination was unremarkable. Common laboratory tests were in normal ranges, including tumor markers: CEA = 1.7 ng/ml, CA19-9 = 4.0 U/ml, CA125 = 41 U/ml and *Echinococcus* IgG At = 11.4 U/ml. Computerized tomography of the pelvis and abdomen showed a large calcified tumor in the lower part of the left hemiabdomen with smooth walls and 9.7 × 8.9 × 9.4 cm in size (Figures 1 and 2). Extraluminal obstruction with intact mucosa was verified at 35 cm from the anal verge by colonoscopy.

Considering the clinical symptoms, computerized tomography scan, and endoscopic findings, elective laparotomy was performed. Intraoperative findings revealed a cystic tumor of the mesosigmoid, causing extraluminal obstruction of the left colon, with no interference with blood vessels of the mesosigmoid. The tumor was enucleated and a partial resection of the adherent mesosigmoid and the great omentum was performed (Figures 3 and 4).

Macroscopic examination of the resected specimen showed a solid, calcified tumor mass with hair and cartilage inside its capsule. The histopathological examination revealed benign cystic teratoma. The postoperative course was uneventful and the patient was discharged on postoperative day seven. The patient was free of symptoms during a 12-month follow-up period.

Correspondence to:

Rastko ŽIVIĆ
Clinical Center "Dr Dragiša Mišović
– Dedinje"
Heroja Milana Tepića 1
11000 Belgrade
Serbia
rale.zivic@gmail.com

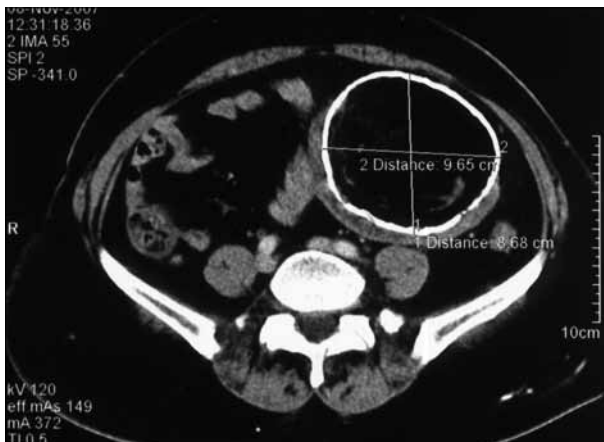


Figure 1. CT scan of the abdomen and pelvis – axial view

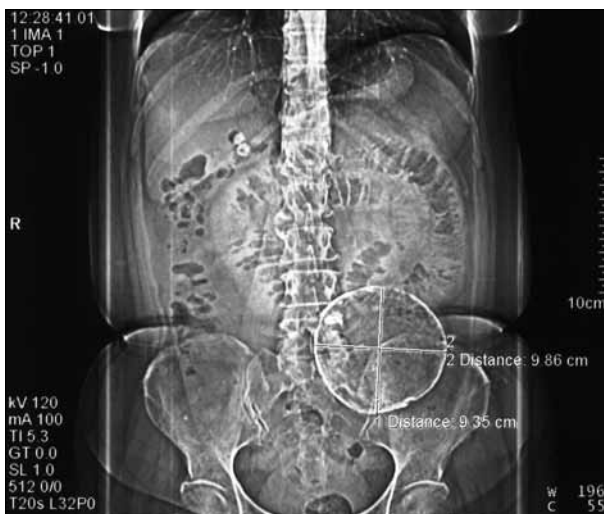

Figure 2. CT scan of the abdomen and pelvis – coronal view

DISCUSSION

Teratoma is the most commonly encountered germ cell tumor [4]. Extragenital intraperitoneal teratomas are extremely rare, although there are almost 40 reports of teratomas arising from the greater and lesser omentum [4, 5, 6], and only 22 cases arising from mesentery and mesocolon [3]. The occurrence of mesenteric teratoma in males is less common than in females [3, 4]. These tumors more frequently occur in children than in adults, but rare cases of geriatric patients have also been reported [7–18]. Although cases with multiple masses have been described [14], mesenteric teratomas are usually solitary tumors with a diameter ranging 3–18 cm [12, 14, 17], located more often in the mesentery than in the mesocolon [3].

Mesenteric teratomas may present with a variety of symptoms. These patients can be completely asymptomatic and just present with a nontender abdominal mass [8, 16, 17, 19], while on the other hand they can also show signs of intestinal obstruction [10, 12, 14, 15, 20], and cause abdominal pain [7, 14, 15, 18, 20–23].

Whereas these tumors are very rare, it is very difficult to establish a correct preoperative diagnosis with all available diagnostic imaging tools. The differential diagnosis of

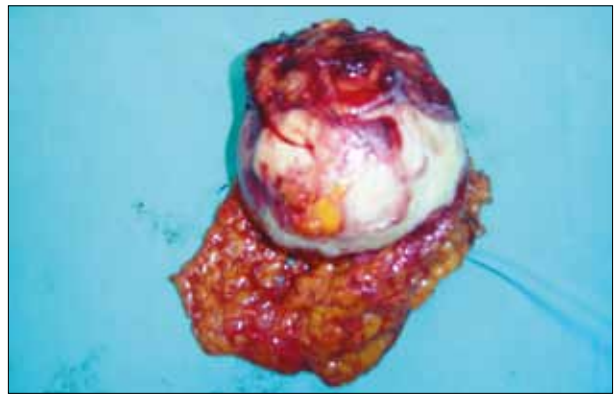

Figure 3. Gross finding of teratoma of the mesosigmoid with resected part of the great omentum

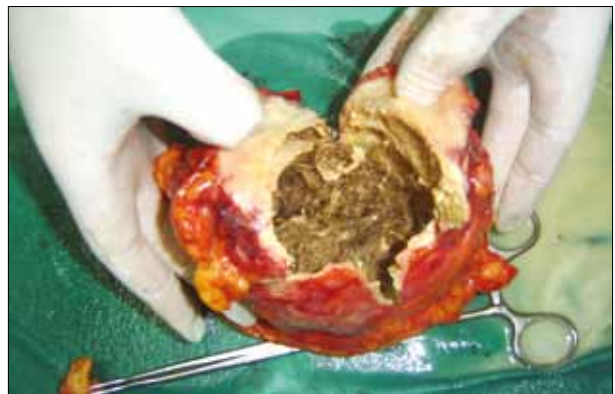

Figure 4. Gross finding of bisected teratoma of the mesosigmoid

intra-abdominal cystic masses includes mesenteric cysts, cystic teratoma, and cystic mesothelioma [24]. Since the definitive diagnosis can be made only on the basis of histopathological examination, complete surgical removal of the cyst is the only way in the treatment of these patients. Although laparoscopic surgery has been used in some cases [3, 19], the majority of authors, including our group, gave preference to a standard laparotomy approach [7–18, 20–23]. We chose laparotomy over laparoscopy for several reasons: the size of the tumor, intestinal obstruction with consecutive bowel distension and a possible interference of the tumor with adjacent blood vessels and organs.

It is recommended that teratomas should be classified as "mature" and "immature," replacing the terms "benign" and "malignant" [25]. While it is generally stated that an immature teratoma has a greater potential to metastasize than a mature one, increasing evidence indicates that other factors such as location of the tumor, patient's age and sex are also important factors in determining the potential of malignant behavior of these tumors [2]. Mesenteric teratomas are mostly benign [3, 7–14, 16–23], and for these patients surgery is a sufficient treatment option, whereas adjuvant chemotherapy for malignant mesenteric teratomas is required [15], as in gonadal and other extragenital sites [2, 26].

Considering the fact that mesenteric teratomas are extremely rare tumors it is difficult to designate a general conclusion for an adequate treatment of these patients. Complete surgical excision is indicated in order to establish a correct histopathological diagnosis and to relieve the patients of symptoms.

REFERENCES

- Norris HJ, Zirkin HJ, Benson WL. Immature (malignant) teratoma of the ovary: a clinical and pathologic study of 58 cases. *Cancer*. 1976; 37(5):2359–72. [DOI: 10.1002/1097-0142(197605)37:5<2359::AID-CNCR2820370528>3.0.CO;2-Q] [PMID: 1260722]
- Ordóñez NG, Manning JT Jr, Ayala AG. Teratoma of the omentum. *Cancer*. 1983; 51:955–8. [DOI: 0008-543X/83/0301/0955] [PMID: 6821860]
- Tanaka Y, Koyama S, Shiki Y. Hand-assisted laparoscopic surgery for a mesenteric teratoma. *JSLs*. 2014; 18(1):160–4. [DOI: 10.4293/108680813X13693422520567] [PMID: 24680163]
- Baviskar BP, Dongre SD, Karle RR, Sewlikar VN. Teratoma of lesser omentum in a male infant. *J Postgrad Med*. 2006; 52(4):304–5. [PMID: 17102555]
- Hegde P. Extragonadal omental teratoma: a case report. *J Obstet Gynaecol Res*. 2014; 40(2):618–21. [DOI: 10.1111/jog.12198] [PMID: 24147579]
- Sforza M, Andjelković K, Ivanov D, Marčić Z, Krstić S. A rare case of benign omentum teratoma. *Srp Arh Celok Lek*. 2012; 140(5-6):362–4. [DOI: 10.2298/SARH1206362S] [PMID: 22826993]
- Buonanno G, Gonnella F, Pettinato G, Castaldo C. Autoimmune hemolytic anemia and dermoid cyst of the mesentery: a case report. *Cancer*. 1984; 54(11):2533–6. [DOI: 10.1002/1097-0142(19841201)54:11<2533::AID-CNCR2820541137>3.0.CO;2-4] [PMID: 6498743]
- Prieto ML, Casanova A, Delgado J, Zabalza R. Cystic teratoma of the mesentery. *Pediatr Radiol*. 1989; 19(6-7):439. [DOI: 10.1007/BF02387647] [PMID: 2671899]
- Naik R, Raghuvver CV. Benign cystic teratoma of mesentery. *Indian J Pathol Microbiol*. 1993; 36(2):151–3. [PMID: 8276479]
- Chiba T, Iwami D, Kikuchi Y. Mesenteric teratoma in an 8-month-old girl. *J Pediatr Surg*. 1995; 30(1):120. [DOI: 10.1016/0022-3468(95)90627-4] [PMID: 7722815]
- Marcolongo A, Divirgilio G, Bettilli G, Saverio Camoglio F, Fasoli L, Marradi P, et al. Immature mesenteric teratoma in a male newborn infant: prenatal ultrasonographic diagnosis and surgical treatment. *Prenat Diagn*. 1997; 17(7):686–8. [PMID: 9249872]
- Ratan SK, Ratan J, Kalra R. Large benign cystic teratoma of the mesosigmoid causing intestinal obstruction: report of a case. *Surg Today*. 2002; 32(10):922–4. [DOI: 10.1007/s005950200183] [PMID: 12376796]
- Al-Arfaj AA, El-Shawarby MA, Al-Mulhim FA, Lardhi AA. Mesenteric cystic teratoma in children. *Saudi Med J*. 2003; 24(12):1388–90. [PMID: 14710290]
- Okada T, Sasaki F, Onodera Y, Oonishi S, Ichikawa N, Itoh T, et al. Multiple mesenteric teratomas: usefulness of spiral computed tomography with 3-dimensional reconstruction. *J Pediatr Surg*. 2006; 41(4):868–71. [DOI: 10.1016/j.jpedsurg.2005.12.040] [PMID: 16567213]
- Rattan KN, Ratan SK, Jhanwar A, Kaushik V, Magu S. Immature mesenteric teratoma causing intestinal obstruction. *Indian J Pediatr*. 2007; 74(2):207–8. [PMID: 17337839]
- Punguyire D, Iserson KV. Mesenteric dermoid cyst in a child. *Pan Afr Med J*. 2011; 10:41. [PMID: 22384287]
- Kulinna C, Eibel R, Bruning R, Reiser M. Mesenteric regressive epidermoid cyst. *Eur Radiol*. 2003; 13(8):2051–2. [DOI: 10.1007/s00330-002-1796-1] [PMID: 12942308]
- Papakonstantinou E, Iavazzo C, Hasiakos D, Kleanthis CK, Fotiou S, Kondi-Pafiti A. Extraovarian mature cystic teratoma of the mesentery: a case report and literature review. *Clin Exp Obstet Gynecol*. 2011; 38(3):291–3. [PMID: 21995170]
- Knudson JJ, Saba A. Laparoscopic enucleation of a dermoid cyst of the cecal mesentery. *Am Surg*. 2010; 76(8):E139–41. [PMID: 21513637]
- Torreggiani WC, Brenner C, Micallef M, O'Laoidhe R. Case report: caecal volvulus in association with a mesenteric dermoid. *Clin Radiol*. 2001; 56(5):430–2. [DOI: 10.1053/crad.1999.0174] [PMID: 11384147]
- Milea AC. Hemorrhagic dermoid cyst of the mesentery; report of a case. *Obstet Gynecol*. 1959; 14(1):107–10. [PMID: 13667189]
- Verswijvel G, Janssens F, Vanboven H, Palmers Y. Spontaneous rupture of mesenteric dermoid cyst: a rare cause of abdominal pain. *Eur Radiol*. 2004; 14(8):1517–8. [DOI: 10.1007/s00330-003-2114-2] [PMID: 14586549]
- Siraz F, Jain D. Mesenteric teratoma in an adult: report of a very rare association. *ANZ J Surg*. 2011; 81(5):393–4. [DOI: 10.1111/j.1445-2197.2011.05715.x] [PMID: 21518201]
- Stoupis C, Ros PR, Abbitt PL, Burton SS, Gauger J. Bubbles in the belly: imaging of cystic mesenteric or omental masses. *Radiographics*. 1994; 14(4):729–37. [DOI: 10.1148/radiographics.14.4.7938764] [PMID: 7938764]
- Mostofi FK, Price EB. Tumors of the male genital system. In: *Atlas of Tumor Pathology, Fascicle 6*. Washington, DC: Armed Forces Institute of Pathology; 1973. p. 59–68.
- Pashankar F, Hale JP, Dang H, Krailo M, Brady WE, Rodriguez-Galindo C, et al. Is adjuvant chemotherapy indicated in ovarian immature teratomas? A combined data analysis from the Malignant Germ Cell Tumor International Collaborative. *Cancer*. 2016; 122(2):230–7. [DOI: 10.1002/cncr.29732] [PMID: 26485622]

Бенигни цистични тератом сигмоидног мезоколона – приказ болесника

Берислав Векић¹, Растко Живић¹, Марко Калезић¹, Предраг Матић²

¹Клиничко-болнички центар „Др Драгиша Мишовић – Дедиње“, Клиника за хирургију, Београд, Србија;

²Институт за кардиоваскуларне болести „Дедиње“, Клиника за васкуларну хирургију, Београд, Србија

КРАТАК САДРЖАЈ

Увод Екстрагонадални интраперитонеални тератоми су изузетно ретки, поготово они који су смештени у мезентеријуму или мезоколону. У савременој литератури објављено је и описано свега око 22 оваква случаја.

Приказ болесника Приказујемо случај болеснице у старосној доби од 52 године са бенигним цистичним тератомом сигмоидног мезоколона. Пацијенткиња је примљена на одељење хирургије са клиничким знацима цревне субоклузије. Компјутеризованом томографијом мале карлице и трбуха виђен је велики калцификовани тумор у доњем делу левог хемиабдомена величине 9,7 × 8,9 × 9,4 cm. Колоноскопијом је верификована екстралуминална опструкција на 35 cm од ануса. Као узрок екстралуминалне опструкције

левог колона интраоперативно је нађен цистични калцификовани тумор сигмоидног мезоколона. Тумор је екстипиран уз парцијалну ресекцију прираслог великог оментума. Дефинитивним патохистолошким прегледом препарата постављена је дијагноза бенигног цистичног тератома.

Закључак С обзиром на чињеницу да су тератоми мезентеријума изузетно ретки тумори, врло је тешко донети опште закључке и поставити смернице за адекватан третман ових пацијената. Комплетна хируршка ексцизија је индикована у циљу постављања дефинитивне патохистолошке дијагнозе и ради отклањања последичних клиничких симптома.

Кључне речи: бенигни цистични тератом; сигмоидни мезоколон; цревна опструкција; хирургија дебелог црева