

Glomus tumor – A case report

Momčilo Stošić, Igor Stojanović, Marija Lalić

General Hospital, Department of Surgery, Vranje, Serbia

SUMMARY

Introduction Glomus tumor is a neuromyoarterial tumor. It is a rare tumor which accounts for about 2% of all hand tumors. The diagnosis is based on the triad of symptoms, clinical examination which includes three tests, magnetic resonance imaging, and ultrasound imaging. The most common treatment is surgical excision, using transungual or lateral subperiosteal approach. Sclerotherapy and radiotherapy may be the treatments of choice, but they are less effective. The recurrence rate is high – from 5% to 50%.

Case Outline We diagnosed a glomus tumor of 1 cm in diameter in the distal phalanx of the fourth finger of the right hand in a 30-year-old woman. She had been visiting different physicians for more than two years and had been variously diagnosed. We performed a biopsy of the tumor, which was bleeding profusely during the procedure. Upon biopsy results, the tumor was excised with transungual approach. Two and a half months after the procedure the patient was feeling well.

Conclusion There should be higher awareness of this tumor in order to diagnose it more easily and treat it accordingly, and thus alleviate the severe pain which the tumor causes. When it is considered as the possible cause of the lesion, the diagnosing is easier and treatment is immediate.

Keywords: glomus tumor; excision, transungual; soft-tissue

INTRODUCTION

A glomus tumor is a rare benign neuromyoarterial tumor. Seventy percent of glomus tumors are located in digital, i.e. subungual region [1]. The tumor arises from the glomus body, which controls blood pressure and temperature (thermoregulatory shunt) by regulating blood flow through cutaneous vasculature [2]. Glomus tumors account for 1–4.5% of all hand tumors [3]. The tumor was first described by Wood in 1812, while histopathological description and terminology was given by Masson in 1824 [4]. The triad of glomus tumor symptoms includes severe pain, pinpoint pain, and cold sensitivity [5]. The patient is diagnosed with glomus tumor after physical examination and magnetic resonance (MR) imaging and ultrasound (US) scanning. Clinical examination includes Love's pin test, Hildreth's test and cold sensitivity test. Love's pin test means that the patient is experiencing severe pain when the skin over the suspected area is pressed with a pinhead. In Hildreth's test, transient ischemia along the arm is induced by tying a tourniquet, which leads to pain in the affected area, which can be outlined. Cold water or ice cubes can be applied to the affected area while performing the

cold sensitivity test. The test is positive when increased pain is elicited during the procedure [6]. US and MR imaging scans are also used to support clinical diagnosis.

CASE REPORT

A 30-year-old female was referred from dermatology department, with a three-year history of pain in the fourth finger of the right hand. She had numerous visits to different healthcare providers in the past. Exposure to the cold or temperature changes provoked occasional pain. Even a minor trauma used to provoke a severe bout of pain. A soft mass with no skin impairment appeared at the tip of the finger in the last several months. No discoloration either of the nail plate or of the proximal nail fold was observed. The mass felt mucous when palpated. Meanwhile, the pain grew constant. Routine laboratory results were within normal limits. The radiographic testing did not reveal any abnormalities. A biopsy specimen of skin tissue was taken under local anesthesia. The wound was bleeding profusely, which immediately indicated the vascular origin of the lesion (Figures 1a and 1b). The bleeding occurred at each

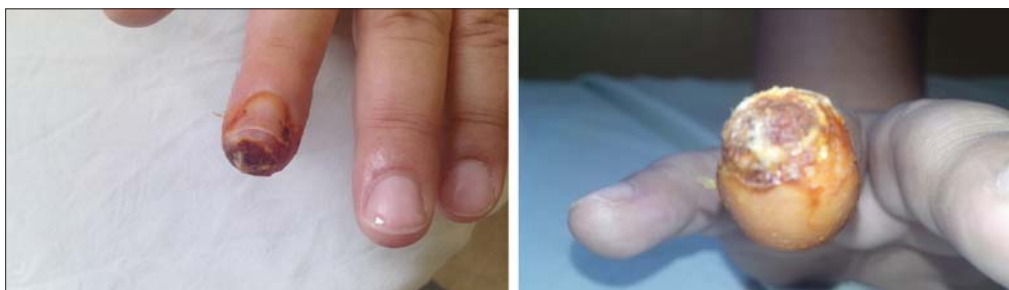

Figure 1. Glomus tumor: a) before biopsy; b) after biopsy

Correspondence to:

Momčilo STOŠIĆ
Department of Surgery
Vranje General Hospital
J. J. Lunge 1
17500 Vranje
Serbia

momcilostosic@gmail.com

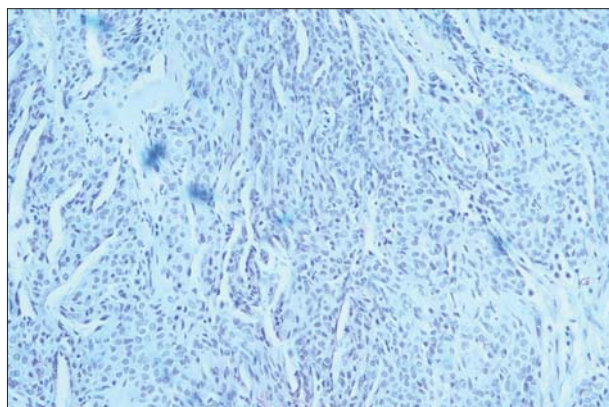


Figure 2. Glomus tumor composed of branching vascular spaces, overlaid with normal endothelial cells, separated by stroma which contains glomus cells nest-like aggregates

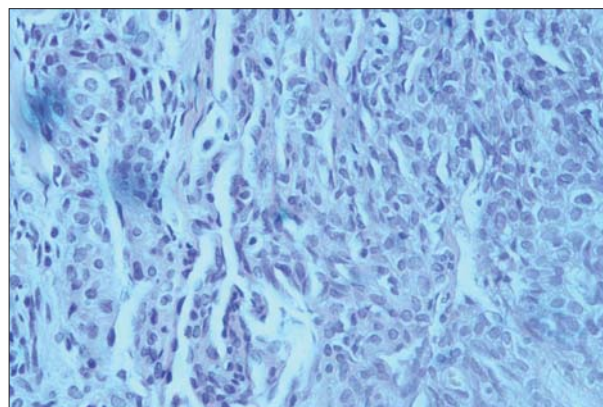
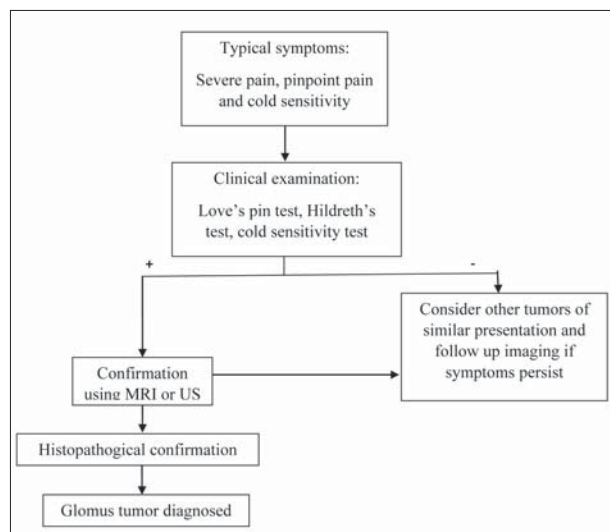


Figure 3. Glomus cells arrayed around vascular space; the cells are epithelioid and they have small, regular, round nuclei and very low mitotic activity



Scheme 1. Original algorithm of the glomus tumor diagnosis (on Tang's idea [7])

dressing change. Histopathological examination revealed a “glomus tumor.” The tumor was excised, and biopsy results were confirmed (Figures 2 and 3). Two and a half months after the procedure the patient was feeling no pain, while occasional numbness at the incision site occurred.

DISCUSSION

Algorithm in Scheme 1 shows simple diagnostic steps when glomus tumor is suspected as a possible condition. Sometimes it takes several years and various differential diagnoses before accurate diagnosis is made and the tumor excised [3, 7]. Furthermore, the nomenclature is confusing – the term “glomus tumor” refers to tumors in the head and neck (glomus caroticum, glomus jugularae), while it also refers to tumors mainly located in digital and subungual regions. The peripheral glomus tumor is called ganglioma. The tumor can be composed of prominent glomus cells (solid glomus tumors, 25%), or prominent vascular components (ganglioma, 60%), or prominent smooth muscle components (glomangiomyoma, 15%) [8]. Paraganglioma of the peripheral nerves (not located

in the head or neck), which originates from sympathetic or parasympathetic ganglia, are also classified as glomus tumors. The last group of tumors also includes pheochromocytoma [9]. A few cases of glomus tumor of digital nerve have been reported [10].

Our patient presented with a lesion the size of a half a distal phalanx, about 10 mm in diameter. Some of the common symptoms were present (pain and hypersensitivity in the tumor area). The first and the working diagnosis was the benign tumor of the distal phalanx extensor tendon. Routine examination and X-ray scanning were done, while MR imaging and US scanning were not performed. It is thought that the latter types of scanning are not necessarily needed in practice. There are two reasons for this: the surgical excision is urgent, and the mentioned scans are costly. [11]. In case of erosion of the lateral part of the bone, evident on an X-ray scan, glomus tumor can be suspected [12]. MR imaging and US are used to delineate the size and precise location of the tumor.

A tissue sample from the fingertip was taken and sent for evaluation. The histopathological findings confirmed “glomus tumor.” It was an indication for excision in local or general anesthesia. After consulting a plastic surgeon in a tertiary institution, the excision was done with transungual approach, which is most frequently performed [13]. According to Vasišć, surgical excision using lateral subperiosteal approach can be done as well [14]. The use of low power lens proved to be useful. Sclerotherapy and argon cryotherapy were found to be ineffective.

Follow-up examinations are quick and they are done every three to six months. Two and a half months after the procedure the patient was feeling well. There was mild paresthesia, but the patient felt no pain. The recurrence of the tumor is frequent (5–40%) and is caused by the tumor growth *de-novo* or the incomplete excision [13, 15].

Glomus tumor is a rare disease, as such it is frequently misdiagnosed, and it is necessary to suspect it when presented with the triad of symptoms, MR imaging and US scans, or biopsy results. Early diagnosis is also important from the aspect of pain relief. The treatment is surgical. Relevant scientific studies report a high incidence of recurrence.

REFERENCES

- Maxwell GP, Curtis RM, Wilgis EF. Multiple digital glomus tumors. *J Hand Surg.* 1979; 4:363–7. [DOI: 10.1016/S0363-5023(79)80076-3] [PMID: 224090]
- Shin DK, Kim MS, Kim SW, Kim SH. A painful glomus tumor on the pulp of the distal phalanx. *J Korean Neurosurg Soc.* 2010; 48:185–7. [DOI: 10.3340/jkns.2010.48.2.185] [PMID: 20856673]
- Kim DH. Glomus tumor of the finger tip and MRI appearance. *Iowa Orthop J.* 1999; 19:136–8. [PMID: 10847529]
- Nebreda CL, Urban BJ, Taylor AE. Upper extremity pain of 10 years duration caused by a glomus tumor. *Reg Anesth Pain Med.* 2000; 25:69–71. [DOI: 10.1016/S1098-7339(00)80014-0] [PMID: 10660244]
- Carroll RE, Berman AT. Glomus tumors of the hand: review of the literature and report on twenty-eight cases. *J Bone Joint Surg Am.* 1972; 54:691–703. [PMID: 4341268]
- Takemura N, Fujii N, Tanaka T. Subungual glomus tumor diagnosis based on imaging. *J Dermatol.* 2006; 33:389–93. [DOI: 10.1111/j.1346-8138.2006.00092.x] [PMID: 16700827]
- Tang CYK, Tipoe T, Fung B. Where is the lesion? Glomus tumours of the hand. *Arch Plast Surg.* 2013; 40:492–5. [DOI: 10.5999/aps.2013.40.5.492] [PMID: 24086799]
- Rao AG, Indira D, Kamal J. Extra digital glomangioma. *Indian J Dermatol.* 2010; 55(4):397–8. [DOI: 10.4103/0019-5154.74570] [PMID: 21430901]
- US National Library of Medicine (service Genetics Home Referencies). Nonsyndromic paraganglioma. Available at: <http://ghr.nlm.nih.gov/condition/nonsyndromic-paraganglioma>. Accessed on August 8, 2015.
- Srinivasan D, Rajappa S. Glomus tumor of digital nerve – a case report. *J Hand Microsurg.* 2014; 6(2):106–7. [DOI: 10.1007/s12593-014-0136-4] [PMID: 25414562]
- Rao S, Raya DA. Three cases of subungual glomus tumours of the fingers – a case series. *J Clin Diagn Res.* 2014; 8(10):ND05–ND06. [DOI: 10.7860/JCDR/2014/8977.4939] [PMID: 25478395]
- Polo C, Borda D, Poggio D, Asuncion J, Peidro L. Glomus tumor of the hallux. Review of the literature and report of two cases. *Foot Ankle Surg.* 2012; 18:89–93. [DOI: 10.1016/j.fas.2011.05.005] [PMID: 22443993]
- Grover C, Khurana A, Jain R, Rathi V. Transungual surgical excision of subungual glomus tumor. *J Cutan Aesthet Surg.* 2013; 6(4):196–203. [DOI: 10.4103/0974-2077.123401] [PMID: 24470715]
- Muramatsu K, Ihara K, Hashimoto T, Tominaga Y, Taguchi T. Subungual glomus tumours: diagnosis and microsurgical excision through a lateral subperiosteal approach. *J Plast Reconstr Aesthet Surg.* 2014; 67:373–6. [DOI: 10.1016/j.bjps.2013.11.006] [PMID: 24411667]
- Lee SH, Roh MR, Chung KY. Subungual glomus tumors: surgical approach and outcome based on tumor location. *Dermatol Surg.* 2013; 39:1017–22. [DOI: 10.1111/dsu.12181] [PMID: 23463908]

Гломус тумор – приказ болесника

Момчило Стошић, Игор Стојановић, Марија Лалић
Општа болница, Хируршко одељење, Врање, Србија

КРАТАК САДРЖАЈ

Увод Гломус тумор је неуромиоартеријални тумор. Спада у групу ретких тумора. Од свих тумора шаке чини око 2%. Дијагностика се базира на тријасу симптома, клиничком прегледу (три теста), магнетној резонанци и ултразвуку. Терапијски стандард је хируршка ексцизија, која може бити трансунгуална и латерално субпериостална. Спроводи се и склеротерапија, као и радиотерапија, али са мање успеха. Процент рецидива је висок – од 5 до 50%.

Приказ болесника Дијагностиковали смо гломус тумор величине око 1 cm у пречнику на дисталној фаланги десног 4.

прста, код жене у тридесетим годинама. Више од две године је посећивала различите лекаре и имала више различитих дијагноза. Ми смо урадили биопсију тумора, који је доста крварио при томе. По добијању резултата урађена је трансунгуална ексцизија. После два и по месеца осећа се добро. **Закључак** Потребно је мислити на овај тумор да би лакше био дијагностикован и лечен, а самим тим и уклоњени јаки болови које изазива. Када се мисли на њега као узроку тегоба, дијагноза се поставља лакше и терапија је промптна. **Кључне речи:** гломус тумор; ексцизија, трансунгуална; мекоткивени