

Anorectal melanoma and seborrheic dermatitis – A case report

Berislav Vekić^{1,2}, Rastko Živić^{1,2}, Marko Kalezić², Suzana Otašević^{3,4}, Valentina Arsić-Arsenijević^{1,5}

¹University of Belgrade, School of Medicine, Belgrade, Serbia;

²Clinical Hospital Center „Dr Dragiša Mišović“, Clinic for Surgery, Belgrade, Serbia;

³University of Niš, Faculty of Medicine, Institute of Microbiology, Niš, Serbia;

⁴Center of Microbiology and Parasitology, Public Health Institute, Niš, Serbia;

⁵University of Belgrade, School of Medicine, Institute of Microbiology and Immunology, National Reference Medical Mycology Laboratory, Belgrade, Serbia

SUMMARY

Introduction Anorectal melanoma (ARM) is a rare and aggressive neoplasm with predisposition for early infiltration, distant spread, and unfavorable prognosis. It has been speculated that *Malassezia* yeasts could possibly have an impact on skin carcinogenesis and development of melanoma, especially in patients with seborrheic dermatitis (SD), due to production of aryl hydrocarbon receptor (AhR) agonists.

Case Outline A 52-year-old man with intensive SD complained of a four-month-long rectal bleeding, tenesmus, pain, and difficulty during defecation. On examination, a rectal tumor was detected and histopathology of tumor tissue revealed ARM with positive protein S100, melanoma antigen HMB45 and melan-A expression. After the diagnosis was established, abdominoperineal resection of the anus and rectum was performed, since the tumor was large, obstructive, and the anal sphincter was invaded.

Conclusion Because of the possible impact of intensive SD to the cross-link between *Malassezia* yeasts AhR agonists and skin carcinogenesis, we discussed on this matter and reviewed the literature data regarding ARM. In addition to “pathogenic” and “non-pathogenic” *Malassezia* subtypes based on AhR agonist production, future studies on *Malassezia* metabolites, their carcinogenic effect in the skin and development of melanoma are needed. If the cross-link between *Malassezia* AhR agonists and skin carcinogenesis exists, timely prevention of ARM could be done with *Malassezia* eradication, especially in patients with severe SD.

Keywords: anorectal melanoma; cancerogenesis; *Malassezia*; aryl hydrocarbon receptor; seborrheic dermatitis

INTRODUCTION

Anorectal melanoma (ARM) is a rare and aggressive neoplasm with predisposition for early infiltration, distant spread, and unfavorable prognosis, which represents 0.05–4.6% of all anal malignancies [1, 2]. Although being behind cutaneous and retinal, ARM, the third most common melanoma, accounts for 0.4–1.6% of all melanomas [2, 3]. ARM originates from melanocytes, the carcinogenic changed pigmented dendritic-like cells, which are present in all three mucosal zones of the anal canal [4]. Although solar ultraviolet radiation (UVR) is the most important carcinogen for melanocytes, not all melanomas can be attributed to ambient UVR, since some tumors arise on sun protected localizations, such as colon and anal region [5].

The literature data indicate possible link between melanoma, specific products of *Malassezia* yeasts, and aryl hydrocarbon receptors (AhR) [6, 7, 8]. *Malassezia* (*Pityrosporum*) species are lipophilic yeasts that are recognized as skin commensals capable of producing an extensive array of bioactive indolic compounds, such as malassezin, indolo[3,2-b]carbazole (ICZ), and indirubin, especially in pathogenic condition, e.g. seborrheic dermatitis (SD) [7]. Recent data show that the presence of different

Malassezia species, the yeast density, and different enzyme production, could be important for *Malassezia* role in pathogenesis of different conditions and in different patient groups, especially those mediated by activation of AhR [7–10]. AhR are widely expressed in humans and are involved in various signaling pathways critical to normal cell homeostasis. Dysregulation of these physiological processes is known to contribute to skin tumor induction, by ‘initiation,’ ‘promotion,’ and ‘progression,’ which represent different stages of the carcinogenic process. AhR are expressed in multiple tumor types, suggesting their pro-oncogenic role. It has been proposed that compounds produced by *Malassezia* yeasts are responsible for alterations in melanocytic function [7, 11]. *Malassezia* yeasts may produce enzymes important for melanoma progression making melanoma more sensitive to AhR-activation simultaneously. Therefore, AhR could play a central role in the ecological ‘cross-talk’ between *Malassezia* yeasts and development of melanoma in the upper part of the epithelium/epidermis.

CASE REPORT

A 52-year-old man with a four-month history of rectal bleeding, bowel obstruction symp-

Correspondence to:

Valentina ARSIĆ-ARSENJEVIĆ
National Reference Medical
Mycology Laboratory
Institute of Microbiology and
Immunology
School of Medicine
University of Belgrade
Dr. Subotića 1, 11000 Belgrade
Serbia
mikomedlab@yahoo.com

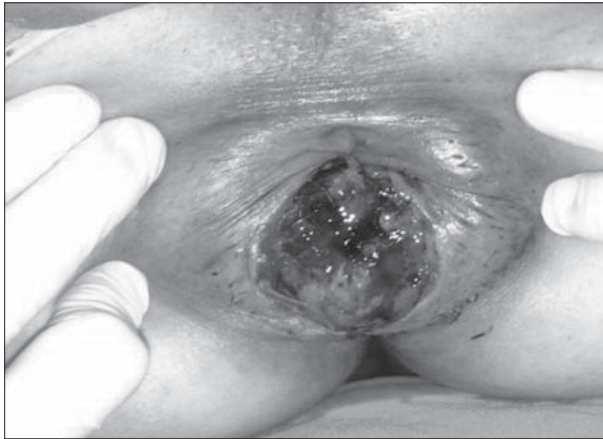

Figure 1. Anorectal melanoma (ARM) located above and below the dentate line with obstruction of the lumen of the rectum

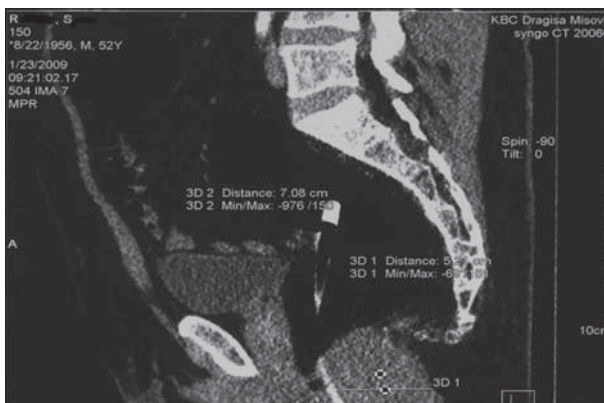


Figure 2. Computed tomography scanning of the small pelvis revealed circumferential rectal thickening (7.2 cm in length and 1.8 cm thickness) located 3.2 cm from the anus, leading to the narrowing of the rectal lumen with several enlarged perirectal nodes

toms, and 10 kg weight loss was referred to our clinic. Anamnestic data revealed untreated extensive long-standing SD. A huge anorectal tumor in the region of the dentate line was detected by clinical inspection (Figure 1). Biopsies demonstrated that it was a malignant melanoma, as protein S100, melanoma antigen HMB-45, and Melan-A expression were found. On computed tomography (CT) scanning, a circumferential anorectal thickening 3.2 cm above the anus, 7.2 cm in length and 1.8 cm in thickness, narrowing the rectal lumen, was detected, associated with several adjacent enlarged perirectal lymph nodes (Figure 2). CT scans of the thorax and abdomen showed no signs of distant metastases. In the inguinal region, no enlarged lymph nodes were detected.

After the diagnosis was established, abdominoperineal resection of the rectum was performed, since the tumor was large, obstructive, and the anal sphincter was invaded (Figure 3). The patient recovered well from the operation and was dismissed on the ninth postoperative day.

Histology analysis confirmed malignant metastatic epithelioid melanoma. The tumor showed invasion into the muscular layer. Only one of 14 removed perirectal lymph nodes was histologically positive on paraffin embedded sections. Melanoma was classified as stage 3. No adjuvant therapy was prescribed by the oncologist.

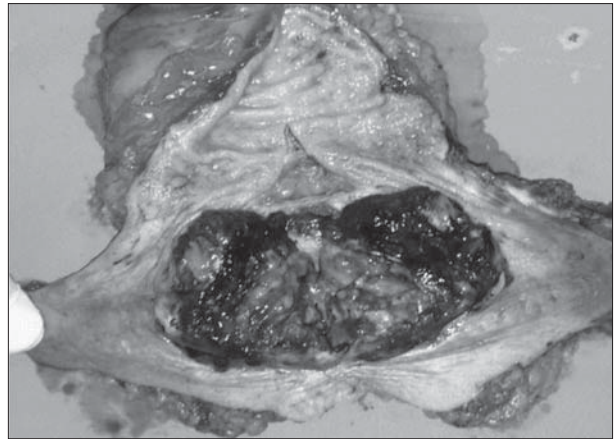


Figure 3. Gross finding of bisected anorectum with present ARM

Eleven months after the initial surgery treatment was performed, the patient began to feel pain in the perineal region. Clinical examination showed palpable tumor mass in the perineal area. The 7.5 × 6.2 cm tumor was confirmed by magnetic resonance imaging and associated with enlarged lymph nodes in the inguinal region. The abdominal magnetic resonance imaging showed no signs of distant metastases. A second surgical procedure was carried out, showing recurrence of ARM in the small pelvis, with no infiltration of the prostate, urinary bladder or pelvic bones. The tumor was removed, the patient recovered well from the operation and was released on the tenth postoperative day and directly forwarded to a dermatologist to initiate treatment of SD and to an oncologist to initiate chemotherapy. Ten months after the second operation, the patient was disease-free, with SD in remission.

DISCUSSION

ARM is a rare disease with exceedingly poor prognosis, worse than cutaneous melanoma, with a median survival of one year and with five-year survival rate of 10% [12]. ARM could be located in the anal canal or at the anal verge (2/3), or in the distal rectum (1/3), and often presents with non-specific local symptoms such as rectal bleeding (55%), rectal masses (34%), anal pain (13%), and change in bowel habits (63%) [13, 14]. However, women are more likely than men to be diagnosed with ARM (male to female ratio is 0.75) [15], and lesions are usually non-specific, amelanotic, and commonly mistaken for benign conditions such as hemorrhoids or rectal polyposis, which prolongs the establishment of the diagnosis [16, 17].

Apart from UVR, the relevant impact of other factors on carcinogenesis in melanoma remains controversial. Exposure to solar UVR is the most important independent carcinogen for melanoma, but additional factors related to the host or local environment may contribute substantially to the pathogenesis of melanoma [18]. The host dependent factors and the polymorphisms of genes encoding for the biosynthesis of detoxifying enzymes are important for melanoma cases in different patient groups [19]. Therefore, UVR-independent anatomical distribution of

melanoma is in line with the current hypothesis that carcinogenic factors acting *in loco* independently or in addition to UVR, may play a distinctive role in the pathogenesis of ARM. In this setting, the important locally modifying factor in human skin carcinogenesis could be lipophilic yeasts of the genus *Malassezia*, previously known as *Pityrosporum*. The genus is characterized by the number of different species production of bioactive enzymes and production of certain metabolites [9, 18]. This is further in line with the observed coincidence of ARM and *Malassezia* colonization areas that are commonly found in some relatively UVR-protected areas, which are also locations of ARM [23]. Epidemiological observations that indirectly link *Malassezia* with melanoma come from the study of patients with Parkinson's disease in whom SD and skin carcinomas appeared in higher rates than expected by chance, despite the fact that the most of other malignancies are found with reduced prevalence in this group of patients [9, 19]. The core mechanism by which *Malassezia* yeasts could probably mediate the carcinogenesis acts through the production of locally acting potent indolic AhR ligands [7]. The AhR belong to orphan receptor group that in adults mediate metabolism of xenobiotics through induction of detoxifying enzymes [20]. AhR are members of the Per-Arnt-Sim superfamily of transcription factors and operate as a key mediators of diverse chemical and physical environmental damages to the cell, including UVR [21, 22]. Recent evidence indicates that AhR ligands are able to modify differentiation of keratinocytes *in vitro* and accelerate terminal skin development [23]. Moreover, AhR have pluripotent functions in adult human skin, e.g. they regulate many aspects of immune response, the cell cycle, and also part of the UVR induced cell alterations [21, 22]. The relationship of rapidly metabolized AhR ligands to carcinogenesis, including those naturally-occurring, like ICZ and indirubin, is more complex because they usually occur as mixtures affecting complex molecular interactions with potentially variable biological outcomes [7].

According to literature data, the presence of AhR ligands from *Malassezia* spp. in the skin could modify epidermal carcinogenesis and induce melanoma by (i) affecting the immune state of the skin; (ii) perturbing the homeostasis between cell cycle progression and apoptosis; (iii) increasing expression of matrix metalloproteinase-1 (MMP-1) in keratinocytes with consecutively enhanced tumor invasion; (iv) affecting survival of the initiated tumor cells; (v) modulating UVR induced carcinogenesis of the epidermis [7, 8]. Within the above framework, a key component of the proposed association to be dissected in future studies will be the behavior of *Malassezia* yeasts under UVR. The increased prevalence of SD among patients with parkinsonism also highlights the impact of the patients' genetic profile, which is important in SD pathogenesis [9, 24].

Although there are various treatment strategies for ARM, surgical treatment remains the main therapeutic modality, with radical abdominoperineal resection (APR) and conservative wide local excision (WLE) as the most common [25]. The necessity of APR in the treatment of ARM beyond WLE remains controversial. Because of the low incidence of this disease, treatment guidelines are based on small retrospective studies. Ross with colleagues showed a 29% recurrence rate in primary ARM after APR, and a 58% recurrence rate after WLE [26]. In a study by Thibault et al. [13], 37 patients had curative resection with no significant survival difference between WLE and APR when comparing disease stage and five-year survival. Before 1997, approximately 70% of all patients underwent APR, while after 1997 almost 90% of patients underwent WLE [14]. The benefits of WLE are obvious, and include fast recovery time from a significantly less invasive procedure, minimal impact on bowel function, and avoidance of permanent colostomy [13]. WLE with or without adjuvant therapy seems to offer good locoregional control without reducing the survival rate, and may be a therapeutic modality of choice for patients with small, superficial ARM [14, 27]. APR should be offered to patients with obstructive bowel symptoms, locally advanced and invasive ARM, or as a salvage therapy following recurrence [27]. Moreover, the role of adjuvant chemotherapy and immunotherapy in the treatment of ARM has not been established, particularly in cases involving metastatic disease. Some patients with metastatic melanomas have been shown to respond to therapy with interferon- α and interleukin-2, suggesting that metastatic melanoma is susceptible to immune assault [28]. However, ARM has always been considered to be a radioresistant tumor [27], as radiation therapy provides no benefit, except occasionally for palliative care in cases with unresectable tumors [28].

In conclusion, besides surgery, the optimal treatment strategy for ARM requires multidisciplinary approach, taking into consideration the possible link between *Malassezia* yeasts and skin carcinogenesis, especially in patients with severe SD. Based on AhR agonist production, future studies are needed to determinate a cross-link between ARM and *Malassezia* yeasts. If a cross-link between agonists (malassezin, ICZ, or indirubin) and carcinogenesis exists in patients with severe SD, timely prevention of melanoma and ARM could possibly be done with *Malassezia* eradication.

ACKNOWLEDGMENT

The study was supported by the Ministry of Education, Science and Technology of the Republic of Serbia, research grant No. OI 175034.

REFERENCES

- Falch C, Stojadinovic A, Hann-von-Weyhern C, Protic M, Nissan A, Faries MB, et al. Anorectal malignant melanoma: extensive 45-year review and proposal for a novel staging classification. *J Am Coll Surg*. 2013; 217:324-35. [DOI: 10.1016/j.jamcollsurg.2013.02.031] [PMID: 23697834]
- Ishizone S, Koide N, Karasawa F, Akita N, Muranaka F, Uhara H, et al. Surgical treatment for anorectal malignant melanoma: report of five cases and review of 79 Japanese cases. *Int J Colorectal Dis*. 2008; 23:1257-62. [DOI: 10.1007/s00384-008-0529-6] [PMID: 18633625]
- Goldman S, Glimelius B, Pahlman L. Anorectal malignant melanoma in Sweden. Report of 49 patients. *Dis Colon Rectum*. 1990; 33:874-7. [PMID: 1698595]
- Clemmensen OJ, Fengler C. Melanocytes in the anal canal epithelium. *Histopathology*. 1991; 18:237-41. [PMID: 2045074]
- Miller BJ, Rutherford LF, McLeod GR, Cohen JR. Where the sun never shines: anorectal melanoma. *Aust NZ J Surg*. 1997; 67:846-8. [PMID: 9451338]
- Mexia N, Gaitanis G, Velegraki A, Soshilov A, Denison MS, Magiatis P. Pityriazepin and other potent AhR ligands isolated from *Malassezia furfur* yeast. *Arch Biochem Biophys*. 2015; 571:16-20. [DOI: 10.1016/j.abb.2015.02.023] [PMID: 25721496]
- Gaitanis G, Velegraki A, Magiatis P, Pappas P, Bassukas ID. Could *Malassezia* yeasts be implicated in skin carcinogenesis through the production of aryl-hydrocarbon receptor ligands? *Medical Hypotheses*. 2011; 77:47-51. [DOI: 10.1016/j.mehy.2011.03.020] [PMID: 21444158]
- Gaitanis G, Magiatis P, Stathopoulou K, Bassukas ID, Alexopoulos EC, Velegraki A, et al. AhR ligands, malassezin, and indolo[3,2-b]carbazole are selectively produced by *Malassezia furfur* strains isolated from seborrheic dermatitis. *J Invest Dermatol*. 2008; 128(7):1620-5. [DOI: 10.1038/sj.jid.5701252] [PMID: 18219281]
- Arsic Arsenijevic VS, Milobratovic D, Barac AM, Vekic B, Marinkovic J, Kostic VS. A laboratory-based study on patients with Parkinson's disease and seborrheic dermatitis: the presence and density of *Malassezia* yeasts, their different species and enzymes production. *BMC Dermatol*. 2014; 14:5. [DOI: 10.1186/1471-5945-14-5] [PMID: 24628775]
- Knockaert M, Blondel M, Bach S, Leost M, Elbi C, Hager GL, et al. Independent actions on cyclin-dependent kinases and aryl hydrocarbon receptor mediate the antiproliferative effects of indirubins. *Oncogene*. 2004; 23(25):4400-12. [DOI: 10.1038/sj.onc.1207535] [PMID: 15077192]
- Krämer HJ, Kessler D, Hipler UC, Irlinger B, Hort W, Bödeker RH, et al. Pityriarubins, novel highly selective inhibitors of respiratory burst from cultures of the yeast *Malassezia furfur*: comparison with the bisindolylmaleimide arcyriarubin A. *Chembiochem*. 2005; 6(12):2290-7. [DOI: 10.1002/cbic.200500163] [PMID: 16252297]
- Solaz Moreno E, Vallalta Morales M, Silla Búrdalo G, Cervera Miguel JI, Díaz Beveridge R, Rayón Martín JM. Primary melanoma of the rectum: an infrequent neoplasia with an atypical presentation. *Clin Transl Oncol*. 2005; 7:171-3. [PMID: 15960927]
- Thibault C, Sagar P, Nivatvongs S, Ilstrup DM, Wolff BG. Anorectal melanoma—an incurable disease? *Dis Colon Rectum*. 1997; 40:661-8. [DOI: 10.4103/0019-509X.55561] [PMID: 9194459]
- Yeh JJ, Shia J, Hwu WJ, Busam KJ, Paty PB, Guillem JG. The role of abdominoperineal resection as surgical therapy for anorectal melanoma. *Ann Surg*. 2006; 244:1012-7. [DOI: 10.1097/01.sla.0000225114.56565.f9] [PMID: 17122627]
- McLaughlin CC, Wu XC, Jemal A, Martin HJ, Roche LM, Chen VW. Incidence of noncutaneous melanomas in the U.S. *Cancer*. 2005; 103(5):1000-7. [DOI: 10.1002/cncr.20866] [PMID: 15651058].
- Morlino A, La Torre G, Vitagliano G, Cammarota A. Malignant rectal melanoma. Case report. *Ann Ital Chir*. 2015; 86. [PMID: 25818193]
- Park JH, Lee JR, Yoon HS, Jung TY, Lee EJ, Lim JG, et al. Primary anorectal malignant melanoma treated with endoscopic mucosal resection. *Intest Res*. 2015; 13(2):170-4. [DOI: 10.5217/ir.2015.13.2.170] [PMID: 2593200]
- Epstein EH. Basal cell carcinomas: attack of the hedgehog. *Nat Rev Cancer*. 2008; 8(10):743-54. [DOI: 10.1038/nrc2503] [PMID: 18813320]
- Ferreira J, Silva JM, Freire R, Pignatelli J, Guedes LC, Feijó A, et al. Skin cancers and precancerous lesions in Parkinson's disease patients. *Mov Disord*. 2007; 22:1471-5. [DOI: 10.1002/mds.21575] [PMID: 17516496]
- Afaq F, Zaid MA, Pelle E, Khan N, Syed DN, Matsui MS, et al. Aryl hydrocarbon receptor is an ozone sensor in human skin. *J Invest Dermatol*. 2009; 129(10):2396-403. [DOI: 10.1038/jid.2009.85] [PMID: 19536146]
- Agostinis P, Garmyn M, Van Laethem A. The aryl hydrocarbon receptor: an illuminating effector of the UVB response. *Sci STKE*. 2007; (403):49. [DOI: 10.1126/stke.4032007pe49] [PMID: 17848686]
- Fritsche E, Schäfer C, Calles C, Bernsmann T, Bernshausen T, Wurm M, et al. Lightening up the UV response by identification of the aryl hydrocarbon receptor as a cytoplasmic target for ultraviolet B radiation. *Proc Natl Acad Sci USA*. 2007; 104(21):8851-6. [DOI: 10.1073/pnas.0701764104] [PMID: 17502624]
- Ray SS, Swanson HI. Alteration of keratinocyte differentiation and senescence by the tumor promoter dioxin. *Toxicol Appl Pharmacol*. 2003; 192(2):131-45. [DOI: 10.1016/S0041-008X(03)00277-1] [PMID: 14550747]
- Gupta AK, Bluhm R. Seborrheic dermatitis. *J Eur Acad Dermatol Venereol*. 2004; 18(1):13-26. [DOI: 10.1111/j.1468-3083.2004.00693.x] [PMID: 14678527]
- Malik A, Hull TL, Milsom J. Long-term survivor of anorectal melanoma: report of a case. *Dis Colon Rectum*. 2002; 45:1412-7. [PMID: 12394445]
- Ross M, Pezzi C, Pezzi T, Meurer D, Hickey R, Balch C. Patterns of failure in anorectal melanoma. A guide to surgical therapy. *Arch Surg*. 1990; 125:313-6. [DOI: 10.1001/archsurg.1990.01410150035007] [PMID: 2306178]
- Belli F, Gallino GF, Lo Vullo S, Mariani L, Poiasina E, Leo E. Melanoma of the anorectal region: the experience of the National Cancer Institute of Milano. *Eur J Surg Oncol*. 2009; 35:757-62. [DOI: 10.1016/j.ejso.2008.05.001] [PMID: 18602790]
- Stefanou A, Nalamati SP. Anorectal melanoma. *Clin Colon Rectal Surg*. 2011; 24(3):171-6. [DOI: 10.1055/s-0031-1286001] [PMID: 22942799]

Аноректални меланом и себореични дерматитис – приказ случаја

Берислав Векић^{1,2}, Растко Живић^{1,2}, Марко Калезић², Сузана Оташевић^{3,4}, Валентина Арсић-Арсенијевић^{1,5}

¹Клиничко-болнички центар „Др Драгиша Мишовић“, Дечја болница за плућне болести и туберкулозу, Београд, Србија;

²Универзитет „Привредна академија у Новом Саду“, Фармацеутски факултет, Нови Сад, Србија;

³Универзитет у Нишу, Медицински факултет, Ниш, Србија;

⁴Институт за јавно здравље, Ниш, Србија;

⁵Универзитет у Београду, Медицински факултет, Институт за микробиологију и имунологију, Национална референтна лабораторија за узрочнике микоза, Београд, Србија

КРАТАК САДРЖАЈ

Увод Аноректални меланом (АРМ) ретка је и агресивна неоплазма са израженом способношћу ране инфилтрације, удаљеног ширења и лоше прогнозе. Познато је да кваснице рода *Malassezia* имају способност продукције протеина, који представљају агонисте за *aryl hydrocarbon* рецепторе (*AhR*), што се доводи у везу са њиховим могућим карциногеним потенцијалом и способношћу да учествују у развоју меланома коже, посебно код пацијената са себореичним дерматитисом (СД).

Приказ болесника У раду је приказан пацијент стар 52 године, мушкарац са израженим СД и са симптомима аналног крварења, грчева, бола и отежане дефекације током четири месеца. Дијагностикован је тумор ануса, а патохистолошко испитивање је потврдило сумњу да се ради о АРМ са позитивним налазом протеина S100, меланома антигена *HMB45* и меланоцитног антигена *melan-A (MART1)*. По постављању

патохистолошке дијагнозе начињена је абдомино-перианална ресекција ануса и ректума с обзиром на величину тумора, његову опструктивну природу и инвазију аналног сфинктера.

Закључак Због могуће повезаности СД и продуката гљива рода *Malassezia* са процесом карциногенезе у кожи и последичним развојем АРМ, у раду је дискутован приказани случај уз преглед литературе. Подела на „патогене“ и „непатогене“ *Malassezia* врсте може да се доведе у везу са њиховим потенцијалом да продукују агонисте *AhR* рецептора, због чега су неопходна даља испитивања. Уколико се потврди веза између ових агониста и канцерогенезе коже код пацијената са израженим СД, могуће је развити стратегију превенције меланома правовременом ерадикацијом гљива рода *Malassezia*.

Кључне речи: аноректални меланом; канцерогенеза; *Malassezia*; *aryl hydrocarbon* рецептор; себореични дерматитис

Примљен • Received: 28/10/2015

Ревизија • Revision: 11/01/16

Прихваћен • Accepted: 09/03/2016