

Recurrent malignant otitis externa with multiple cranial nerve involvement: A case report

Dragoslava Djerić^{1,2}, Miljan Folić^{1,2}, Miloš Janićijević^{3,4}, Srbislav Blažić^{1,2}, Danka Popadić⁵

¹University of Belgrade, School of Medicine, Belgrade, Serbia;

²Clinical Center of Serbia, Clinic for Otorhinolaryngology and Maxillofacial Surgery, Belgrade, Serbia;

³University of Priština, Faculty of Medical Sciences, Kosovska Mitrovica, Serbia;

⁴Health Center, Department of Otorhinolaryngology, Kosovska Mitrovica, Serbia;

⁵Medical Center, Otorhinolaryngology Office, Vrnjačka Banja, Serbia

SUMMARY

Introduction Necrotizing otitis externa is a rare but conditionally fatal infection of external auditory canal with extension to deep soft tissue and bones, resulting in necrosis and osteomyelitis of the temporal bone and skull base. This condition is also known as malignant otitis due to an aggressive behavior and poor treatment response. Early diagnosis of malignant otitis is a difficult challenge. We present an illustrative case of necrotizing otitis externa and suggest some strategies to avoid diagnostic and treatment pitfalls.

Case Outline A 70-year-old patient presented with signs of malignant otitis externa, complicated by peripheral facial palsy. Adequate diagnostic and treatment procedures were performed with clinical signs of resolution. The recurrence of malignant infection had presented three months after previous infection with multiple cranial nerve neuropathies and signs of jugular vein and lateral sinus thrombosis. An aggressive antibiotic treatment and surgery were carried out, followed by substantial recovery of the patient and complete restoration of cranial nerves' functions.

Conclusion Necrotizing otitis externa is a serious condition with uncertain prognosis. The suspicion of malignant external otitis should be raised in cases of resistance to topical treatment, especially in patient with predisposing factors. Evidence-based guideline for necrotizing otitis externa still doesn't exist and treatment protocol should be adjusted to individual presentation of each patient.

Keywords: external ear; pseudomonas infection; facial paralysis; skull base; osteomyelitis

INTRODUCTION

Necrotizing otitis externa (NOE) is a rare but conditionally fatal infection of external auditory canal with extension to the deep soft tissue and bones, resulting in necrosis and osteomyelitis of the temporal bone and skull base. This condition is also known as malignant otitis due to aggressive behavior and poor treatment response.

It usually affects elderly individuals with a serious comorbidity, such as diabetes or immunocompromised patients. *Pseudomonas aeruginosa* is identified in the culture of external auditory canal in great majority of cases, although other microorganisms such as *Staphylococcus aureus*, *Klebsiella oxytoca*, *Proteus mirabilis* or *Aspergillus* species may cause a serious form of NOE [1]. Fungal infection should be suspected in all cases with no clinical signs of improvement after adequate anti-*Pseudomonas* treatment [2, 3].

Insidious course of the disease is responsible for the diagnostic difficulties that may be encountered in the early stages of the infection, further causing delay of appropriate treatment and occurrence of complications. Advanced stages of necrotizing otitis are associated with severe neurological disorders characterized by multiple cranial nerve neuropathies and intracranial extension [4]. Facial nerve paralysis is

the indicator of stylomastoid foramen involvement and is usually the first neurological sign of disease progression [5].

We present an interesting case of NOE and suggest some strategies to avoid diagnostic and treatment pitfalls.

CASE REPORT

A 70-year-old male patient presented with severe otalgia, ear canal suppuration and peripheral facial palsy that were treated for six weeks with systemic and local antibiotic therapy in another institution. The patient suffered from diabetes for years and had a good glucoregulation, optimized with therapy prescribed by endocrinologist.

By close inspection of the patient, signs of peripheral paralysis of facial nerve (House-Brackmann scale, grade III) and vaguely bordered tumefaction below auricle were noticed. Otomicroscopy revealed extensive skin edema of external ear canal that detained ear drum visualization. Granulation tissue was observed at the bottom of the canal, along with thick inflammatory secretion that showed the presence of *Candida* species during culturing. Pure tone audiometry depicted severe mixed hearing loss on the affected side and severe sensorineural hearing loss on the other side.

Correspondence to:

Miljan FOLIĆ
Clinic for Otorhinolaryngology
and Maxillofacial Surgery
Clinical Centre of Serbia
Pasterova 2, 11000 Belgrade
Serbia
mfolic@yahoo.com

The parameters of inflammation (erythrocyte sedimentation rate 140, C-reactive protein 110 mg/L) were greatly increased during laboratory testing and ultrasound examination of the neck revealed multiple reactive lymph nodes up to 10 mm in size. CT scan showed inflammatory changes and osteolysis of bony portion of external auditory canal and mastoid process (Figure 1).

The patient was treated with high-dose antibiotic therapy (combination of third-generation cephalosporins and clindamycin), followed by surgery. A cortical mastoidectomy was performed along with excision of the extremely hypertrophic and granulomatous skin of external hearing canal. Histological analysis of meatal skin, middle ear mucosa and bony septa revealed signs of chronic inflammation and bone necrosis and calcification. The patient was discharged from the hospital after six weeks of systemic antibiotic therapy with clinical signs of recovery. During a two-month follow-up, otomicroscopy finding was normal and general condition significantly improved.

However, three months after the discharge, the patient's condition worsened. Fever and weakness were followed by neurological disorders such as facial palsy, swallowing and speech difficulties, as well as taste disorders. The patient also had severe otalgia and purulent discharge from the external auditory canal; however, this time, swab analysis results came positive to ciprofloxacin-resistant strain of *Pseudomonas aeruginosa*. Neurological status revealed impaired function of VII, IX, and X cranial nerves.

CT scan and MR imaging showed devastating osteomyelitis of the petrous pyramid of the temporal bone, otomastoiditis and signs of jugular vein and lateral sinus thrombosis (Figure 2). Multidisciplinary treatment was carried out by an otorhinolaryngologist, neurologist, neurosurgeon, vascular surgeon, and infectologist. Intensive antibiotic therapy with vancomycin, ceftazidime, and metronidazole combined with antimycotics gave positive results on the condition of the patient, decreasing the levels of inflammatory parameters after seven weeks of treatment. Histological analysis and findings during revision surgery of the middle ear and mastoid cavity showed no signs of active inflammation. The patient presented substantial postoperative recovery that was verified on CT scan. During a six-month follow-up the patient's hearing improved and cranial nerves functions were completely restored.

DISCUSSION

Early diagnosis of NOE is a difficult challenge. Various authors suggest diagnostic criteria and treatment recommendations, although evidence-based guideline for necrotizing otitis externa still doesn't exist. The set of criteria for diagnosis of NOE established by Levenson et al. [6] is frequently cited in literature and is based on characteristic clinical findings, the isolation of *Pseudomonas aeruginosa* in aural secretion and clinical settings of diabetes. More than two thirds of authors agree that presentation of otitis externa refractory to treatment is a major diagnostic crite-

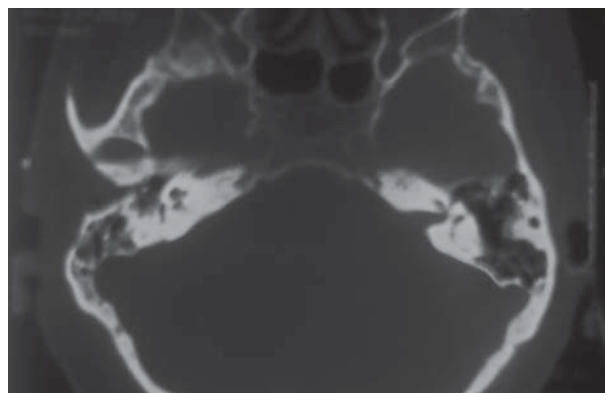


Figure 1. CT scan: Inflammatory changes involving osseous portion of external auditory canal and mastoid process

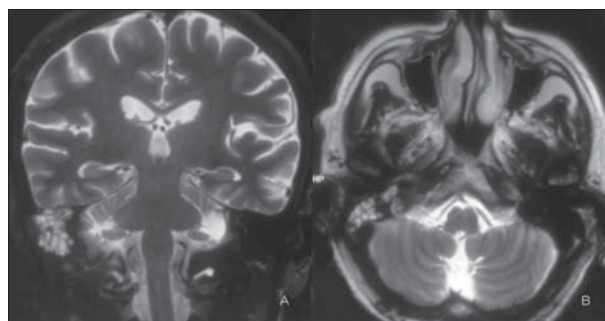


Figure 2. MR imaging: purulent collection involving skull base (A – coronal view; B – axial view)

ron [7]. Jacobsen and Antonelli [8] reported 6.9 months as the mean time necessary to make a diagnosis of NOE, and history or clinical presentation overlapping with benign otitis externa were identified as primary reasons for diagnostic delay.

Pseudomonas aeruginosa is isolated from aural drainage in about 95% of NOE cases [9]. Necrotizing otitis requires an intensive and prolonged antimicrobial therapy, although role of topical antipseudomonal therapy is controversial. Recurrent topical use of quinolones repels local signs of infection, but also it increases the risk of negative cultures or development of resistant strains. Our patient was formerly treated with ciprofloxacin ear drops in another institution, and during the first hospitalization at our clinic we were unable to isolate *Pseudomonas aeruginosa* in ear canal secretion. On the other hand, ciprofloxacin-resistant strain of *Pseudomonas aeruginosa* was identified as the causative agent during the second hospitalization. This resistance may be explained by prolonged antibiotic treatment and local use of ciprofloxacin ear drops. Le Clerc et al. [10] reported that 25% of *Pseudomonas aeruginosa* strains isolated in NOE patients are resistant to ciprofloxacin. Also, an increasingly implicated organism in NOE is methicillin-resistant *Staphylococcus aureus*, which may be found in 15% of cases [11]. In addition, topical antibiotic therapy may affect the incidence of mycotic infections by accelerating fungus growth. Mycotic infection should be suspected in all cases of malignant otitis externa with no signs of improvement after intensive antibiotic therapy and requires multiple deep tissue biopsies and isolation from blood cultures or fistula exudates [1, 12].

Imaging studies have an irreplaceable role in determining the extent of the disease and the response to therapy. CT scan and MR imaging are both used in assessment of NOE; CT scan is superior in visualization of bone erosion, while MRI has an advantage in evaluating intracranial and neurological complications. However, their utilization in determining disease resolution after treatment is limited due to inability of differentiation between active inflammation and tissue remodeling. According to a study by Al-Noury and Lotfy [13], all patients had cortical bone changes on CT scan and about two thirds of patients had soft tissue changes on MR imaging, a year after disease resolution. On the other hand, some nuclear medicine studies, such as ^{67}Ga scanning or ^{111}In -labeled leukocyte scintigraphy combined with SPECT/CT are powerful tools that can differentiate between healing tissue and active inflammation and therefore are used to document resolution of infection [14].

Advanced stages of NOE have been associated with multiple cranial nerve neuropathies. Facial nerve paralysis is usually the first neurological disorder in NOE and it is reported in about 25% of cases [15]. It represents a sign of disease progression, but it doesn't seem to be an indicator of adverse prognosis [16]. Decompression is not treatment of choice in such cases since it will not restore neural function due to damaging of nerve integrity and replacing it with granulation tissue. Fortunately, thanks to newer powerful therapy, the great majority of patients experience improvement or total recovery of facial nerve function.

Involvement of cranial nerves IX, X, XI, and XII is typically in that order and represents a sign of infection spreading to jugular foramen, presenting with symptoms such as dysphonia or dysphagia. Further spread of the disease, involving petrous apex, may affect cranial nerves V and VI with signs of Gradenigo's syndrome. Skull base osteomyelitis secondary to malignant otitis externa is associated with multiple cranial nerve palsies in about 40% of patients. Also, the recurrence of necrotizing infection affects the severity of neurological presentation. It is reported that four fifths of patients with recurrent NOE suffered from facial nerve paralysis, which was twice as often as glossopharyngeal and vagus nerves' paralysis concurrently, while all lower cranial nerves were involved in 20% of patients [17]. Lower cranial nerve palsies are significantly more likely to have a good treatment response compared with facial nerve palsy [18]. Our patient suffering from recurrent necrotizing otitis complicated with skull base osteomyelitis had a complete resolution of all neurological deficits. Facial nerve had the longest period of complete functional recovery, in comparison with other cranial nerve involved by infection.

Treatment of NOE comprises control of glycemia level, improvement of general condition, local debridement of granulation tissue, cleansing of external auditory canal and aggressive antimicrobial treatment for at least six weeks. Great effort must be taken to make accurate diagnosis and begin with adequate treatment in early stages of the disease in order to minimize complication rate. Verim et al. [19] found that time period of more than 30 days elapsed

between the onset of symptoms for NOE and admission to hospital has a significant impact on patient outcome and affects the duration of recovery.

Accurate timing of treatment suspension represents a difficult challenge for clinicians due to possibility of residual disease in spite of clinical resolution. ^{67}Ga or ^{111}In -labeled leukocyte scintigraphy combined with SPECT/CT should be repeated every two to four weeks during the treatment until normalization [14]. Factors that contribute to recurrent necrotizing otitis are still to be determined, although insufficient duration of treatment may play a significant role.

In fungal NOE, continued treatment for more than 12 weeks with amphotericin B is recommended, but its toxic profile has to be taken into consideration, especially in patients with serious comorbidities [1]. It is reported that voriconazole may be very effective agent for management of NOE caused by *Aspergillus* species but its precise role in therapeutic protocol had not still been documented [20]. Fungal infections are more invasive than bacterial forms of the disease and require surgical intervention four times as often, as reported by Hamzani et al. [2].

Surgical treatment has been ceded a leading role to an aggressive antimicrobial therapy and today it is used for local debridement, bony sequestrum removal, or incision of abscess. In some cases, tumors of temporal bone may have a clinical presentation similar to NOE and histopathological analysis is mandatory to exclude the malignancy [21].

Extensive surgical approach is not usually used due to its inability to prevent the spread of necrotizing infection; on the contrary, it brings the risk of further progression of the disease. On the other hand, there is a standpoint that radical mastoidectomy should be carried out in the majority of cases, especially if the fungi are involved as causative factors [1]. Hyperbaric oxygen is also used as an adjuvant treatment for malignant otitis externa, but there is no clear evidence regarding efficiency of this kind of treatment compared with combination of antibiotics and surgery [22].

Despite the fact that, nowadays, clinicians are provided with very potent antimicrobial agents and powerful diagnostic tools, the recurrence of malignant infection is common and mortality rate remains about 20% [17]. Study by Soudry et al. [23] showed that five-year survival is 44% in patients older than 70 years of age. The factors found to be associated with high mortality are multiple cranial nerve involvement, intracranial or skull base extension, and poor initial treatment response.

In conclusion, necrotizing otitis externa is a dangerous disease with high mortality rate in immunocompromised patients. Successful recovery of patients requires early diagnosis and aggressive antimicrobial treatment. In our case, the disease was persistent and aggressive despite prolonged and extensive treatment. The estimation was based on general condition of the patient, presenting symptoms, blood analysis, imaging findings (CT, MR) and swab analysis. However, our experience with conservative therapy in combination with surgery achieved a positive final outcome for the patient.

REFERENCES

1. Bovo R, Benatti A, Ciorba A, Libanore M, Borrelli M, Martini A. Pseudomonas and Aspergillus interaction in malignant external otitis: risk of treatment failure. *Acta Otorhinolaryngol Ital.* 2012; 32(6):416–9. [PMID: 23349563]
2. Hamzany Y, Soudry E, Preis M, Hadar T, Hilly O, Bishara J, et al. Fungal malignant external otitis. *J Infect.* 2011; 62(3):226–31. [DOI: 10.1016/j.jinf.2011.01.001] [PMID: 21237200]
3. Chen CN, Chen YS, Yeh TH, Hsu CJ, Tseng FY. Outcomes of malignant external otitis: survival vs. mortality. *Acta Otolaryngol.* 2010; 130:89–94. [DOI: 10.3109/00016480902971247] [PMID: 19466617]
4. Patmore H, Jebreel A, Uppal S, Raine CH, McWhinney P. Skull base infection presenting multiple lower cranial nerve palsies. *Am J Otolaryngol.* 2010; 31(5):376–50. [DOI: 10.1016/j.amjoto.2009.04.001] [PMID: 20015773]
5. Mehrotra P, Elbadawey MR, Zammit-Maempel I. Spectrum of radiological appearances of necrotizing external otitis: a pictorial review. *J Laryngol Otol.* 2011; 125(11):1109–15. [DOI: 10.1017/S0022215111001691] [PMID: 21846417]
6. Levenson MJ, Parisier SC, Dolitskz J, Bindra G. Ciprofloxacin: drug of choice in the treatment of malignant external otitis (MEO). *Laryngoscope.* 1991; 101(8):821–4. [DOI: 10.1288/00005537-199108000-00004] [PMID: 1865729]
7. Guevara N, Mahdyoun P, Pulcini C, Raffaelli C, Gahide I, Castillo L. Initial management of necrotizing external otitis: errors to avoid. *Eur Ann Otorhinolaryngol Head Neck Dis.* 2013; 130(3):115–21. [DOI: 10.1016/j.anorl.2012.04.011] [PMID: 23276814]
8. Jacobsen LM, Antonelli PJ. Errors in the diagnosis and management of necrotizing otitis externa. *Otolaryngol Head Neck Surg.* 2010; 143(4):506–9. [DOI: 10.1016/j.otohns.2010.06.924] [PMID: 21225805]
9. Bhandary S, Karki P, Sinha BK. Malignant otitis externa: a review. *Pac Health Dialog.* 2002; 9(1):64–7. [PMID: 12737420]
10. Le Clerc N, Verillaud B, Duet M, Guichard JP, Herman P, Kania R. Skull base osteomyelitis: incidence of resistance, morbidity and treatment strategy. *Laryngoscope.* 2014; 124(9):2013–6. [DOI: 10.1002/lary.24726] [PMID: 24752664]
11. Hobson CE, Moy JD, Byers KE, Raz Y, Hirsch BE, McCall AA. Malignant Otitis Externa: Evolving Pathogens and Implications for Diagnosis and Treatment. *Otolaryngol Head Neck Surg.* 2014; 151(1):112–6. [DOI: 10.1177/0194599814528301] [PMID: 24675790]
12. Vourexakis Z, Kos MI, Guyot JP. Atypical presentations of malignant otitis externa. *J Laryngol Otol.* 2010; 124:1205–8. [DOI: 10.1017/S0022215110000307] [PMID: 20193102]
13. Al-Noury K, Lotfy A. Computed tomography and magnetic resonance imaging before and after treatment of patients with malignant external otitis. *Eur Arch Otorhinolaryngol.* 2011; 268:1727–34. [DOI: 10.1007/s00405-011-1552-8] [PMID: 21400256]
14. Courson AM, Vikram HR, Barrs DM. What are the criteria for terminating treatment for necrotizing (malignant) otitis externa? *Laryngoscope.* 2014; 124(2):361–2. [DOI: 10.1002/lary.24093] [PMID: 24105671]
15. Carfrae MJ, Kesser BW. Malignant otitis externa. *Otolaryngol Clin North Am.* 2008; 41(3):537–49. [DOI: 10.1016/j.otc.2008.01.004] [PMID: 18435997]
16. Ali T, Meade K, Anari S, El Badawey MR, Zammit-Maempel I. Malignant otitis externa: case series. *J Laryngol Otol.* 2010; 124(8):846–51. [DOI: 10.1017/S0022215110000691] [PMID: 20388240]
17. Omran AA, El Gareem HF, Al Alem RK. Recurrent malignant otitis externa: management and outcome. *Eur Arch Otorhinolaryngol.* 2012; 269(3):807–11. [DOI: 10.1007/s00405-011-1736-2] [PMID: 21833561]
18. Nawas MT, Daruwalla VJ, Spierer D, Micco AG, Nemeth AJ. Complicated necrotizing otitis externa. *Am J Otolaryngol.* 2013; 34(6):706–9. [DOI: 10.1016/j.amjoto.2013.07.003] [PMID: 23927998]
19. Verim A, Naiboglu B, Karaca C, Seneldir L, Kulekci S, Oysu C. Clinical outcome parameters for necrotizing otitis externa. *Otol Neurotol.* 2014; 35(2):371–6. [DOI: 10.1097/MAO.0000000000000249] [PMID: 24448298]
20. Parize P, Chandeseris MO, Lanternier F, Poiree S, Viard JP, Bienvenu B, et al. Antifungal therapy of Aspergillus invasive otitis externa: efficacy of voriconazole and review. *Antimicrob Agents Chemother.* 2009; 53(3):1048–53. [DOI: 10.1128/AAC.01220-08] [PMID: 19104029]
21. Crestani S, Vellini JF, Nohra O, Gabrillargues J, Kemeny JL, Gilain L, et al. Adenoid cystic carcinoma of the external auditory canal. *Ann Otolaryngol Chir Cervicofac.* 2007; 124(6):314–7. [DOI: 10.1016/j.aorl.2007.03.003] [PMID: 17521599]
22. Philips JS, Jones SE. Hyperbaric oxygen as an adjuvant treatment for malignant otitis externa. *Cochrane Database Syst Rev.* 2013; 5:CD004617. [DOI: 10.1002/14651858.CD004617.pub3] [PMID: 23728650]
23. Soudry E, Hamzany Y, Preis M, Joshua B, Hadar T, Nageris BI. Malignant external otitis: analysis of severe cases. *Otolaryngol Head Neck Surg.* 2011; 144(5):758–62. [DOI: 10.1177/0194599810396132] [PMID: 21493363]

Понављајуће малигно запаљење спољашњег ува са захватањем више кранијалних нерава: приказ болесника

Драгослава Ђерић^{1,2}, Миљан Фолић^{1,2}, Милош Јанићијевић^{3,4}, Србислав Блажић^{1,2}, Данка Попадић⁵

¹Универзитет у Београду, Медицински факултет, Београд, Србија;

²Клинички центар Србије, Клиника за оториноларингологију и максилороцијалну хирургију, Београд, Србија;

³Универзитет у Приштини, Факултет медицинских наука, Косовска Митровица, Србија;

⁴Здравствени центар, Одељење оториноларингологије, Косовска Митровица, Србија;

⁵Дом здравља, Служба оториноларингологије, Врњачка Бања, Србија

КРАТАК САДРЖАЈ

Увод Некротизирајуће запаљење спољашњег ува је ретка, мада условно летална инфекција спољашњег слушног ходника са ширењем на дубока мека ткива и кост, која може да доведе до некрозе и остеомијелитиса темпоралне кости и базе лобање. Ово обољење је такође познато као малигни отитис због својих агресивних карактеристика и слабог терапијског одговора. Рана дијагноза представља тежак изазов. Приказујемо интересантан случај некротизирајућег запаљења спољашњег ува и дајемо предлоге како избећи дијагностичке и терапијске замке.

Приказ болесника Седамдесетогодишњи болесник је испољио знакове малигног отитиса, компликованог парализом фацијалног живца. Спровођење адекватног дијагностичког и терапијског протокола довело је до резолуције обољења. Релапс малигне инфекције се јавио три месеца

након претходне инфекције, изазивајући функционални испад више кранијалних живаца и показујући знакове тромбозе југуларне вене и сигмоидног синуса. Спроведена је агресивна антибиотска терапија и хируршко лечење, што је довело до изузетног опоравка болесника и комплетног опоравка функције кранијалних нерава.

Закључак Малигни отитис представља озбиљну инфекцију са неизвесном прогнозом. Сумња на ово обољење требало би да постоји у случајевима слабог одговора на топикалну терапију, посебно код пацијената са предиспонирајућим факторима. Смернице за некротизирајући отитис спољашњег ува засноване на доказима и даље не постоје; стога би протокол лечења требало прилагодити сваком пацијенту индивидуално.

Кључне речи: спољашње уво; инфекција псеудомонасом; фацијална парализа; база лобање; остеомијелитис

Примљен • Received: 03/09/2015

Прихваћен • Accepted: 21/12/2015