

Surgical treatment of intramural hematoma of the ascending aorta

Stamenko Šušak^{1,2}, Aleksandar Redžek^{1,2}, Vladimir Torbica², Jovan Rajič², Mirko Todić²

¹University of Novi Sad, Faculty of Medicine, Novi Sad, Serbia;

²Clinic for Cardiovascular Surgery, Institute for Cardiovascular Diseases of Vojvodina, Sremska Kamenica, Serbia

SUMMARY

Introduction Intramural hematoma of the aorta presents potentially fatal condition developing as a result of a vasa vasorum rupture. It is a major risk factor for developing a frank aortic dissection.

Case Outline A 65-year-old woman was admitted to our clinic for the second time, after her symptoms of chest pain and vertigo (with no electrocardiographic signs of myocardial infarction) hadn't disappeared after several months of medicament treatment (indicated in the first hospitalization). Computed tomography arteriography of the aorta showed no sign of acute aortic dissection, but revealed a contrast depo in the aortic wall of 8 × 14 mm dimensions, with no extravasation of contrast. Also, massive pericardial effusion was observed (10–30 mm in thickness). Transesophageal echocardiography confirmed these findings completely. The patient underwent surgery, in which plaque exulceration was detected on the convex side of the ascending aorta, 3 cm above the aortic valve, 1 cm in diameter, with no signs of intimal tear. A resection of the ascending aorta was performed, and the aorta was reconstructed with a 30 mm Dacron tube graft. The patient was discharged on the 14th postoperative day with satisfactory results.

Conclusion Intramural hematoma is not a common event, but it is potentially a fatal one. Open surgery in patients with an intramural hematoma is an effective treatment strategy, although percutaneous endovascular treatment options are being described.

Keywords: ascending aorta; aortic dissection; intramural hematoma; cardiovascular surgical procedures

INTRODUCTION

Cardiovascular diseases are the major cause of death in most of developed countries, and in many developing countries as well [1]. Aortic diseases play a big role in their mortality rate. New imaging modalities, developed over the last few decades, such as transesophageal echocardiography (TEE), magnetic resonance imaging (MRI) and computed tomography angiography (CTA) have brought a great improvement in diagnosis and decision-making in such conditions [2]. Prior to introducing these imaging modalities, this, as well as some other aortic diseases, could only be diagnosed during necropsy [3].

All mechanisms that weaken the aortic wall, lamina media in particular, lead to higher wall stress, which can induce aortic dilatation and aneurysm formation, eventually resulting in aortic dissection or rupture [4, 5, 6].

An intramural hematoma (IMH) leads to aortic dissection in which the intimal tear seems to be secondary to preceding intramural dissection [7, 8]. It is a result of rupture of vasa vasorum [7, 9], and can extend along the aorta, as a dissection. The weakened inner wall is subjected to the elongating force of the diastolic recoil, which can result in intimal tears.

The prevalence of intramural hemorrhage in patients with suspected aortic dissection, as observed by various new imaging techniques, seems to be in the range of 10–30% [8, 10, 11].

CASE REPORT

A 65-year-old woman, with a history of hypertension, higher cholesterol level, family history of heart disease and a history of smoking, four months prior to the operation started feeling symptoms in the form of a chest pain with propagation towards her back, hypertension (157/109 mmHg), followed by a strong headache and vertigo. She was immediately admitted to a local hospital, where she underwent CT diagnostics of the chest, which showed IMH of the ascending aorta, from sinotubular junction to the front half of aortic arch, 17 mm in thickness, and density of 65–70 HU. There was no evidence of myocardial ischemia on the electrocardiogram. With suspected aortic dissection she was transferred to our clinic, where CTA and TEE diagnostic confirmed presence of IMH and minimal pericardial effusion (5 mm), without signs of acute aortic dissection. After a short hospitalization she was discharged with further medical treatment indicated.

Three days before second hospitalization (four months after the first discharge) she felt a strong pain between her shoulder blades after mild physical activity, which intensified until urgent admission to our clinic. Her symptoms were followed by elevated body temperature (38.5°C), hypotension (left arm – 85/75 mmHg, right arm – 80/70 mmHg) and coughing (with thick white, and in one instance

Correspondence to:

Mirko TODIĆ
Institute of Cardiovascular
Diseases of Vojvodina
Clinic of Cardiovascular Surgery
Put dr Goldmana 4
21204 Sremska Kamenica
Serbia
todicmirko@yahoo.com

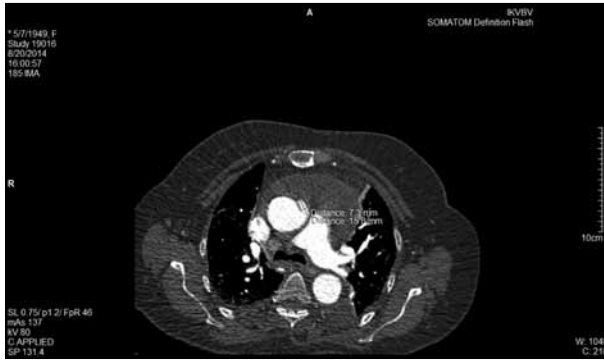

Figure 1. CTA of the aorta showing contrast depo in the aortic wall (marked by the authors)

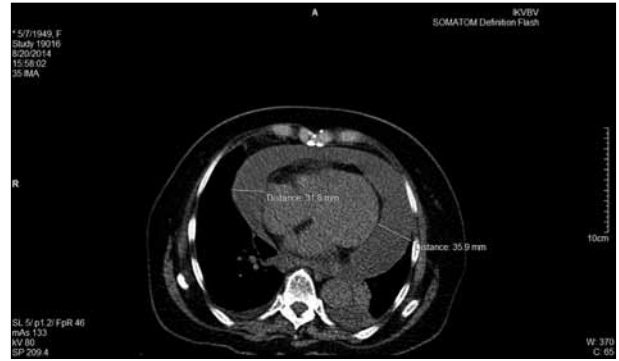


Figure 2. CT finding of a massive pericardial effusion (marked by the authors)

bloody sputum). Electrocardiogram showed arrhythmic heart function caused by ventricular extrasystoles. CTA of the aorta showed no signs of acute aortic dissection, but revealed an 8×14 mm contrast depo in the aortic wall, with no extravasation of contrast (Figure 1). The deformation in the aortic wall was described as bigger than the one obtained during CTA diagnostic examination conducted four months previously. Also, pericardial effusion was massive, spreading 10–30 mm in thickness (Figure 2). TEE confirmed these findings completely, and pointed suspicion at a discrete front aortic wall rupture. After the diagnoses of imminent heart tamponade and aortic wall rupture were established, the patient was urgently indicated with surgical treatment.

Total median sternotomy was performed to access mediastinum. Pericardiectomy was performed and revealed epicardial-pericardial adhesions due to serofibrinous pericarditis (Figure 3). A total of 800 ml of yellow-green fluid was aspirated out of pericardial cavity. Aspirating both pleural cavities resulted in evacuation of 700 ml of similar fluid in total. Aorta was in situs solitus and normal in size, with medial necrosis of its wall. Systemic heparinization was achieved by the patient's body mass. The operation was further conducted on partial extracorporeal circulation (ECC) with the ascending aorta and the inferior vena cava cannulation. Vent was placed in upper-right lung vein, to secure suction of the left atrium cavity. After activating the bypass, aortic clamping was performed on the ascending aorta, above the IMH level. Cardioplegic solution of potassium chloride was injected through the coronary ostia, and aspirated through the right atrium. After achieving cardiac arrest, longitudinal aortotomy was performed. On the convex side of the ascending aorta, 3 cm above the aortic valve, plaque exulceration of 1 cm in diameter was detected, but with no sign of dissection. This finding was described as a ruptured IMH (Figure 4), permeating entire circumference of the aorta (Figure 5). Resection of the ascending aorta was performed, and reconstructed with a 30 mm Dacron tube graft. Total cardiac arrest time was 50 minutes, and partial ECC time was 60 minutes.

After 14 days of postoperative hospitalization, the patient was discharged with optimal results of surgical treatment.

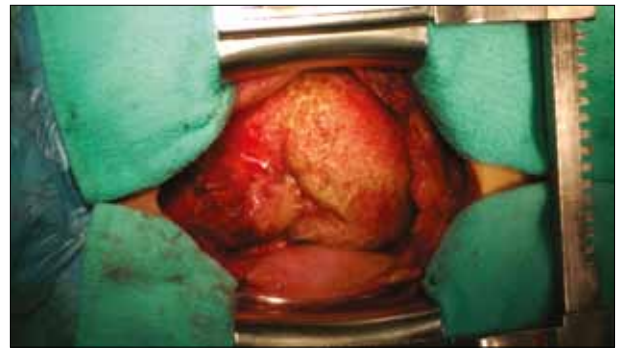


Figure 3. Deposits on the pericardium and epicardium found intraoperatively – serofibrinous pericarditis

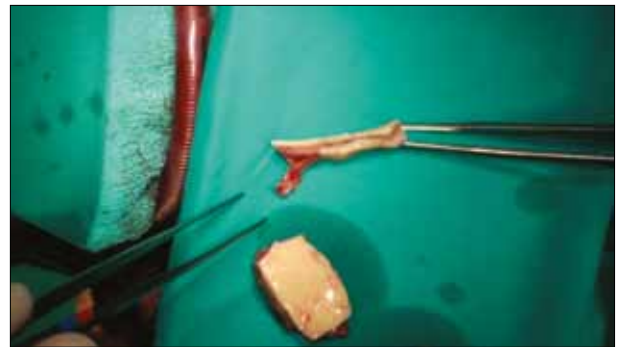


Figure 4. Fragment of aortic resection showing apparent layer of IMH

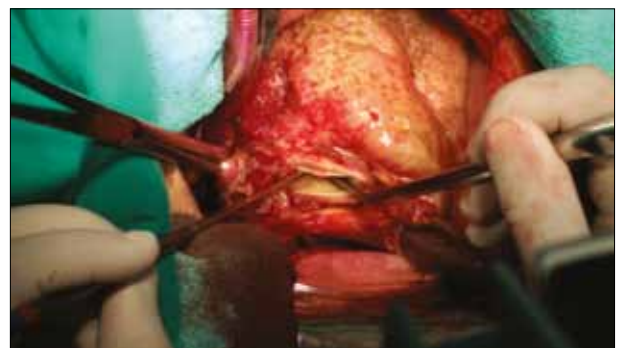


Figure 5. The ascending aorta removed. Layer of IMH permeating its entire circumference

DISCUSSION

The key to successful treatment of all classes of aortic dissection (including IMH) is the correct initial diagnosis, which allows immediate response. Despite this need for rapid decision making, overall agreement about the strategy for patient management has not been achieved until Task Force reported recommendations on diagnosis and management of aortic dissection [12].

There is a constant dilemma regarding the outcome of surgical versus medical treatment of ascending aorta IMH. Proponents of medical treatment emphasize the medical management with frequent follow-up imaging studies, which can lead to eventual surgical repair. In those opinions, it is recommended to use surgical treatment in cases where symptoms persist with the use of medical therapy, or if radiographic evidence shows enlargement of the IMH, or its progression to frank aortic dissection [13, 14, 15].

On the other hand, proponents of surgical management stand for early and aggressive surgery treatment of ascending aorta IMH (and aortic arch IMH), with medical management reserved for cases of descending aorta IMH [10, 16, 17]. A meta-analysis of 143 reported cases of IMH, performed by Maraj et al. [18], showed that the mortality rate of ascending aorta and aortic arch IMH group was

statistically significantly lower in cases in which surgical treatment was performed than in those who received medical treatment only. This statement on the role of surgical treatment of IMH was supported by Tittle et al. [19] landmark study in a series of 19 patients.

The study of Saborio et al. [20] described a case of a patient in whom a limited operation of ascending aorta IMH failed to treat the patient's condition, and required a major reoperation a few days later because of IMH appearing in the aortic arch. In their conclusion it is recommended to surgically treat patients with ascending aorta IMH by an ascending aorta and aortic arch replacement with the use of deep hypothermic circulatory arrest.

IMH is not a very frequent condition, but it is potentially fatal. It is usually seen in elderly individuals with hypertension and atherosclerosis, but may also develop as a result of blunt chest trauma with aortic wall injury or penetrating atherosclerotic ulcer. With an onset of acute chest pain with or without propagating to back, in a patient with no evidence of myocardial ischemia or signs of aortic dissection or rupture, IMH should be considered. In an emergency situation, CTA is the imaging modality of choice to identify IMH. Open surgery in patients with IMH is an effective treatment strategy, although percutaneous endovascular treatment options are being described.

REFERENCES

- Global status report on noncommunicable diseases 2010. Geneva, World Health Organization, 2011.
- Song JK. Diagnosis of aortic intramural haematoma. *Heart*. 2004; 90(4): 368–371. [DOI: 10.1136/hrt.2003.027607] [PMID: 15020502]
- Šušak S, Torbica V, Velicki L, Golubović M. Rare type of quadricuspid aortic valve requiring surgical replacement. *Thorac Cardiovasc Surg*. 2009; 57(6):364–6. [DOI: 10.1055/s-0029-1185563] [PMID: 19707981]
- Kovačević P, Velicki L, Popović D, Ivanović V, Mojašević R. Surgical treatment of penetrating atherosclerotic ulcer of the descending aorta. *Vojnosanit Pregl*. 2013; 70(9):874–7. [DOI: 10.2298/VSP1309874K] [PMID: 24266318]
- Kovačević P, Velicki L, Mojašević R, Kieffer E. Thromboexclusion of the complete aorta in the treatment of chronic type B aneurysm. *Ann Vasc Surg*. 2012; 26(2):278.e7–9. [DOI: 10.1016/j.avsg.2011.02.049] [PMID: 22079460]
- Filipović N, Nikolić D, Saveljić I, Đukić T, Adić O, Kovačević P, et al. Computer simulation of thromboexclusion of the complete aorta in the treatment of chronic type B aneurysm. *Comput Aided Surg*. 2013; 18(1–2):1–9. [DOI: 10.3109/10929088.2012.741145] [PMID: 23176116]
- Gore I. Pathogenesis of dissecting aneurysm of aorta. *Arch Path Lab Med*. 1952; 53:142–53. [PMID: 14884831]
- Shimizu H, Yohino H, Udagawa H, Watanuki A, Yano K, Ide H, et al. Prognosis of intramural hemorrhage compared with classic aortic dissection. *Am J Cardiol*. 2000; 85:792–5. [DOI: 10.1016/S0002-9149(99)00867-X] [PMID: 12000066]
- Stefanadis CI, Karayannacos PE, Boudoulas HK, Stratos CG, Vlachopoulos CV, Dontas IA, et al. Medial necrosis and acute alterations in aortic distensibility following removal of the vasa vasorum of canine ascending aorta. *Cardiovasc Res*. 1993; 27:951–6. [DOI: 10.1093/cvr/27.6.951] [PMID: 8221784]
- Nienaber CA, von Kodolitsch Y, Petersen B, Loose R, Helmchen U, Haverich A, et al. Intramural hemorrhage of the thoracic aorta. Diagnostic and therapeutic implications. *Circulation*. 1995; 92:1465–72. [DOI: 10.1161/01.cir.92.6.1465] [PMID: 7664428]
- Alfonso F, Goicolea J, Aragoncillo P, Hernandez R, Macaya C. Diagnosis of aortic intramural hematoma by intravascular ultrasound imaging. *Am J Cardiol*. 1995; 76:735–8. [DOI: 10.1016/s0002-9149(99)80213-6] [PMID: 7572641]
- Erbel R, Alfonso F, Boileau C, Dirsch O, Eber B, Haverich A, et al. Diagnosis and management of aortic dissection. *European Heart Journal*. 2001; 22:1642–1681. [DOI: 10.1053/euhj.2001.2782] [PMID: 11511117]
- Song JK, Kim HS, Kang DH, Lim TH, Song MG, Park SW, et al. Different clinical features of aortic intramural hematoma versus dissection involving the ascending aorta. *J Am Coll Cardiol*. 2001; 37:1604–10. [DOI: 10.1016/s0735-1097(01)01184-6] [PMID: 11345372]
- Moizumi Y, Komatsu T, Motoyoshi N, Tabayasi K. Management of patients with intramural hematoma involving the ascending aorta. *J Thorac Cardiovasc Surg*. 2002; 124:918–24. [DOI: 10.1067/mtc.2002.125637] [PMID: 12407374]
- Kaji S, Akasaka T, Horibata Y, Nishigami K, Shono H, Katayama M, et al. Long-term prognosis of patients with type A aortic intramural hematoma. *Circulation*. 2002; 106:1248–52. [DOI: 10.1016/s1062-1458(02)01001-2] [PMID: 12354741]
- Robbins RC, McManus RP, Mitchell RS, Latter DR, Moon MR, Olinger GN, et al. Management of patients with intramural hematoma of the thoracic aorta. *Circulation*. 1993; 88:111–10 [PMID: 8222144]
- Muluk SC, Kaufman JA, Torchiana DF, Gertler JP, Cambria RP. Diagnosis and treatment of thoracic aortic intramural hematoma. *J Vasc Surg*. 1996; 24:1022–9. [DOI: 10.1016/s0741-5214(96)70048-4] [PMID: 8976356]
- Maraj R, Rerkpattanapipat P, Jacobs LE, Makornwattana P, Kotler MN. Meta-analysis of 143 reported cases of aortic intramural hematoma. *Am J Cardiol*. 2000; 86:664–8. [DOI: 10.1016/s0002-9149(00)01049-3] [PMID: 10980220]
- Tittle SL, Lynch RJ, Cole PE, Singh SH, Rizzo JA, Kopf GS, et al. Midterm follow-up of penetrating ulcer and intramural hematoma of the aorta. *J Thorac Cardiovasc Surg*. 2002; 123:1051–9. [DOI: 10.1067/mtc.2002.121681] [PMID: 12063450]
- Saborio DV, Sadeghi A, Burack JK, Lowery RC, Genovesi MH, Brevetti GR. Management of intramural hematoma of the ascending aorta and aortic arch. *Tex Heart Inst J*. 2003; 30:325–327. [PMID: 14677748]

Хируршко збрињавање интрамуралног хематома асцендентне аорте

Стаменко Шушак^{1,2}, Александар Реџек^{1,2}, Владимир Торбица², Јован Рајић², Мирко Тодић²

¹Универзитет у Новом Саду, Медицински факултет, Нови Сад, Србија;

²Клиника за кардиоваскуларну хирургију, Институт за кардиоваскуларне болести Војводине, Сремска Каменица, Србија

КРАТАК САДРЖАЈ

Увод Интрамурални хематом (ИМХ) аорте представља стање са могућим смртним исходом и настаје као последица пуцања *vasa vasorum*-а. ИМХ је фактор високог ризика за развој праве дисекције аорте.

Приказ болесника Пацијенткиња старости 65 година је по други пут примљена на нашу клинику, након што се њени симптоми, у виду болова у грудима и вртоглавице (без електрокардиографских знакова инфаркта миокарда), нису повлачили после неколико месеци коришћења медикаментозне терапије (која јој је индикована у првој хоспитализацији). Налаз компјутеризоване томографије – артериографије (СТА) аорте није показао знаке акутне дисекције аорте, али је открио депо контраста у њеном зиду, димензија 8 × 14 mm, без екстравазације контраста. Такође је уочен масиван перикардни излив (дебљине 10–30 mm).

Налаз трансезофагеалне ехокардиографије (ТЕЕ) потпуно је потврдио налаз СТА. Пацијенткиња је подвргнута операцији, где је пронађена егзулцерација плака димензија 1×1 cm, на конвексној страни асцендентне аорте, 3 cm изнад аортног залиска, али без знакова интималног расцепа. Учињена је ресекција и реконструкција зида асцендентне аорте помоћу *Dacron tube* графта, пречника 30 mm. Пацијенткиња је отпуштена 14. постоперативног дана са задовољавајућим резултатима.

Закључак ИМХ је ретко, али стање са могућим смртним исходом. Операција пацијената са ИМХ представља ефикасну стратегију лечења, мада се описују и могућности перкутних ендоваскуларних захвата.

Кључне речи: асцендентна аорта; дисекција аорте; интрамурални хематом; кардиоваскуларне хируршке процедуре

Примљен • Received: 05/05/2015

Прихваћен • Accepted: 30/09/2015