

The Role of Rotational Thromboelastometry in Real Time Assessment of Haemostasis in Surgical Settings

Dragica Vučelić¹, Predrag Miljić², Nebojša Antonijević³, Miroslav Milićević¹

¹ Institute of Digestive System Diseases, Clinical Centre of Serbia, Belgrade, Serbia;

² Institute of Haematology, Clinical Centre of Serbia; School of Medicine, University of Belgrade, Belgrade, Serbia;

³ Institute of Cardiovascular Diseases, Clinical Centre of Serbia, Belgrade, Serbia

SUMMARY

Introduction In the settings of trauma, liver transplantation and major surgery multifactorial coagulopathies are frequently encountered. The treatment of acutely bleeding patients is critically compromised by monitoring with standard available routine coagulation tests. In contrast to conventional tests, rotational thromboelastometry (ROTEM) provides an automated measurement of interactive dynamic haemostatic processes in whole blood starting with initial haemostasis up to and including fibrinolysis at a given time point. Especially fibrinogen, platelet dysfunction and hyperfibrinolysis pose diagnostic gaps. The aim of this report was to highlight the usefulness of ROTEM in making the correct diagnosis and adoption of therapeutic approaches in a timely manner in liver transplantation and trauma. We describe the value of ROTEM in two haemostatically compromised patients.

Outline of Cases In the first case, we present the ROTEM-based dynamic assessment and goal-directed treatment of acute haemorrhage in a liver transplant recipient. In the second case, after operation a multitraumatised patient developed uncontrolled massive bleeding unresponsive to conventional treatment and recombinant activated factor VII (rFVIIa) administration. The cessation of bleeding was achieved after guided therapy according to ROTEM results.

Conclusion In orthotopic liver transplantation and severely injured trauma patients ROTEM enables rapid and accurate detection and the differential diagnosis of multifactorial coagulopathies. Also, it provides the basis of rational approach to the use of blood component therapy and pharmacological interventions.

Keywords: rotational thromboelastometry; liver transplantation; trauma

INTRODUCTION

Surgery or major trauma is the ultimate test of the haemostatic system [1]. Excessive perioperative bleeding remains a major complication following surgery and results in increased morbidity and mortality [2].

In the settings of major surgery, liver transplantation and trauma multifactorial coagulopathies are frequently encountered. Due to complex nature of haemorrhage in these settings, physicians require coagulation monitoring strategies sensitive to all major possible pathomechanisms [3].

Clinically, the treatment of acutely bleeding patients is critically compromised by monitoring with standard available routine coagulation tests that can take up to 45-60 minutes [3, 4]. In the clinical management of an acutely bleeding patient, it can be difficult to unravel the relative contribution of surgical haemostasis versus endothelial injury, platelet dysfunction, abnormalities of the coagulation proteases or their inhibitors and excessive fibrinolysis [5]. Thus, a false differential diagnosis may lead to therapeutic misadventures [3].

Today, rotational thromboelastometry (ROTEM), as a further development of the classical thromboelastography, is increasingly applied in perioperative setting and also performed outside specialised coagulation laboratories [6].

The purpose of this report was to show the utility of ROTEM in making correct diagnosis and adoption of therapeutic approaches in a timely manner in surgical settings.

METHODS

A ROTEM computerised analyser (Pentapharm GmbH, Munich, Germany) was used for coagulation profile monitoring. All analyses were performed in ROTEM pin and cups at 37°C on 300 µL citrated whole blood, according to the instructions of the manufacturer. Blood samples were tested immediately and up to 30 minutes after venepuncture.

The analysis was performed, in parallel, by four independent tests on the four channels of the ROTEM analyser (EXTEM, INTEM, FIBTEM and APTEM) and, depending on the therapeutic approaches, HEPTEM test was added.

ROTEM tests were started by recalcification and accelerated by adding an activator of extrinsic coagulation pathway (EXTEM) and intrinsic coagulation pathway (INTEM). For the differential diagnosis of haemostatic abnormalities FIBTEM (activation as in EXTEM with addition of platelet blocking substance cytochalasin D), APTEM (activation as in EXTEM with addition of antifibrinolytic aprotinin) and HEPTEM (activation as in INTEM with addition of heparinase) were added. Fibrin polymerisation disorder was detected with FIBTEM, hyperfibrinolysis was detected with APTEM, and heparin related coagulation disturbances were recorded with HEPTEM.

The parameters routinely measured provide as a reaction curve TEMogram (indicated in Figure 1), as well as numerical parameters derived from mathematical analysis of the curve by computer assisted operation procedure (Table 1; Figure 1).

This report includes two haemostatically compromised patients treated surgically.

CASE REPORTS

Patient 1

The patient was a 38-year-old female, 55 kg, who underwent cadaveric orthotopic liver transplantation (OLT) due to Willson disease. Immediately prior to transplantation

surgery, conventional haematological laboratory findings indicated only a moderate degree of thrombocytopenia: red blood cells (RBC) $5,12 \times 10^{12}/L$, haemoglobin (Hb) 152 g/L, platelet count (Plt) $91 \times 10^9/L$, activated partial thromboplastin time (APTT) 31.2 s, International Normalised Ratio (INR) 1.27, fibrinogen 2.6 g/L, antithrombin 80%, plasminogen 77%, D dimer 163 $\mu g/L$.

Initial ROTEM data at the start of surgery indicated the contribution of low platelet count and dysfibrinogenemia to reduced clot firmness as well as low grade hyperfibrinolysis (Table 2).

Table 1. ROTEM reference values

ROTEM parameter	CT (s)	CFT (s)	AA (°)	A10 (mm)	MCF (mm)	LI60 (%)
EXTEM	38-79	34-159	63-83	43-65	50-72	85-100
INTEM	100-240	30-110	70-83	44-66	50-72	85-100
FIBTEM ^a	-	-	-	7-23	9-25	-
APTEM ^b	38-79	34-159	63-83	43-65	50-72	
HEPTEM ^c	100-240	30-110	70-83		50-72	85-100

a) $MCF_{FIBTEM} < 8-9$ mm – fibrinogen deficiency or fibrinogen polymerization disorder. $MCF_{FIBTEM} > 24$ mm – elevated fibrinogen concentration. This can result in normal MCF_{FIBTEM} even in thrombocytopenic patients. A normal MCF_{FIBTEM} in the presence of low MCF_{EXTEM} indicating the need for platelet transfusion.

b) Shortening of CT or increase in MCF in APTEM compared to EXTEM can be a sign of hyperfibrinolysis.

c) Distinct shortening of CT in HEPTEM compared to INTEM indicates heparin effect [7].

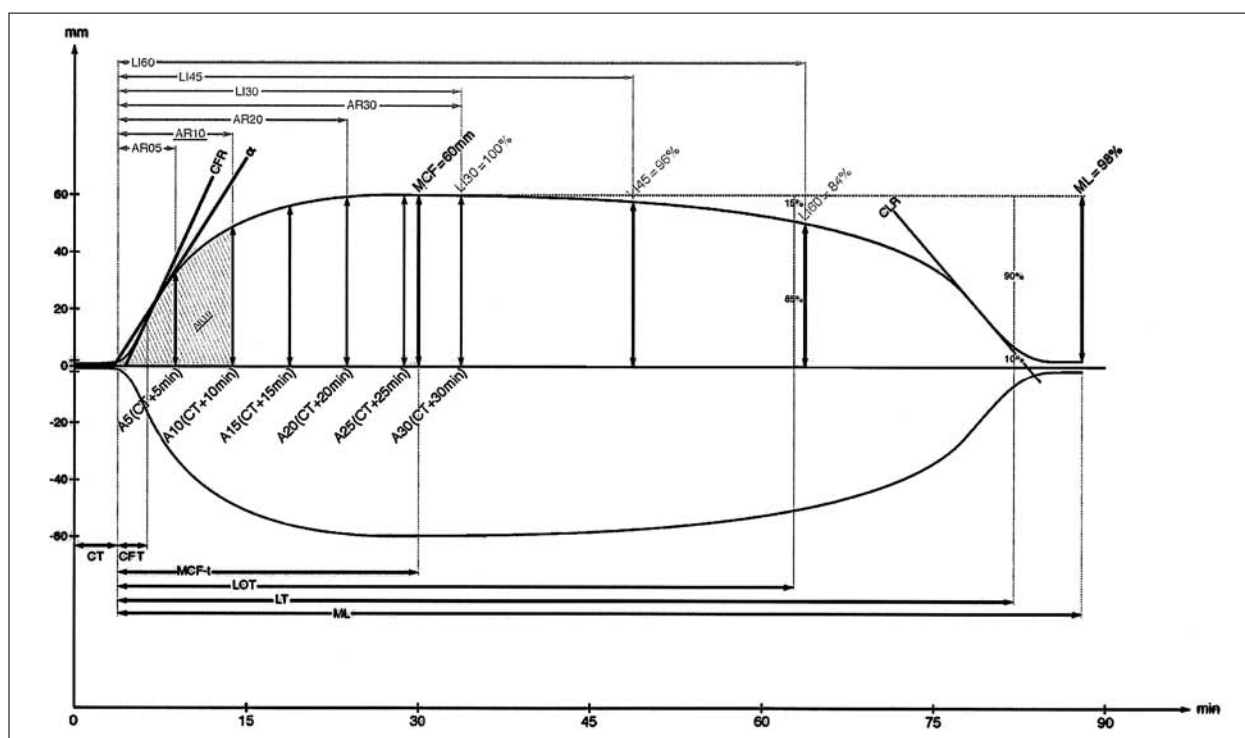


Figure 1. Diagrammatic representation of the ROTEM trace [3, 4, 7, 8]

ROTEM is a coagulation monitor that measures viscoelastic changes accompanying whole-blood coagulation generation and lysis. ROTEM system provides a reaction curve (TEMogram) and several numerical (kinetic) parameters (Table 1) which are derived from detailed mathematical analysis of the curve. The various phases of the curve represent different physiological events mediated by the interaction of platelets, coagulation factors and inhibitors, fibrinogen and fibrinolysis system. The clot strength is found on the y axis and time is found on the x axis.

In routine practice, several parameters are measured:

- **Clotting Time (CT)** is the time from initiation of clotting until the clot has gained strength of 2 mm. CT represents the rate of initial fibrin formation and is related functionally to plasma clotting factors and circulating inhibitor activity. Prolongation of CT may be the result of coagulation factor deficiencies, anti-coagulation or severe hypofibrinogenemia. A small CT value may be present in hypercoagulability syndrome.
- **Clot Formation Time (CFT)** is the time from clot strength 2 mm until clot strength 20 mm.
- **Alpha angle (AA)** is the angle measured between the horizontal midline and the line tangential to the graph at 2 mm clot strength. CFT and AA reflect the rate at which the clot is formed and polymerized and are related functionally to fibrinogen and platelet.
- **Maximum Clot Firmness (MCF)** is the maximum strength of the clot regardless of time. MCF is the greatest amplitude on the TEM trace and is the reflection of the absolute strength and stability of the fibrin clot. It is the direct function of fibrinogen level/fibrin polymerisation and platelets count/function. The MCF is taken to represent the ultimate strength of the clot, and subsequent reduction in amplitude indicating the efficacy of fibrinolysis.
- **Amplitude of clot** at 10, 15, 20 minutes (**A10, A15, A20**) is the clot firmness at the respective time point after CT. Clot firmness achieves its maximum normally after 20-30 minutes.
- **Lysis index (LI30-LI60)** describes the degree of fibrinolysis which has taken place until 30-60 minutes after CT. The result is calculated as the ratio of the amplitude and the MCF (% remaining clot firmness). To detect late hyperfibrinolysis, ROTEM tests have to be monitored for up to 60 minutes.

Table 2. Patient 1: ROTEM parameters during OLT

Parameter	Baseline	Anhepatic	Reperfusion after 1 hour	Reperfusion the end	The end of operation	4 th postoperative day
EXTEM-CT	88 s	150 s	117 s	472 s	56 s	74 s
EXTEM-CFT	169 s	329 s	386 s	undetectable	411 s	138 s
EXTEM-AA	61°	42°	37°	13°	44°	69°
EXTEM-A10	39 mm	28 mm	27 mm	10 mm	25 mm	43 mm
EXTEM-MCF	48 mm	39 mm	39 mm	12 mm	39 mm	50 mm
INTEM-CT	152 s	223 s	254 s	452 s	166 s	139 s
INTEM-CFT	171 s	309 s	448 s	-	440 s	120 s
INTEM-AA	63°	46°	33°	13°	57°	75°
INTEM-A10	37 mm	30 mm	24 mm	10 mm	24 mm	42 mm
INTEM-MCF	45 mm	42 mm	38 mm	13 mm	38 mm	49 mm
FIBTEM-MCF	5 mm	9 mm	5 mm	undetectable	7 mm	17 mm
APTEM-CT	72 s	87 s	-	478 s	69 s	85 s
HEPTEM-CT	-	-	188 s	-	-	-

At the induction of anaesthesia a regular prophylactic dose of tranexamic acid 1g was given intravenously over 20 minutes. At the beginning of operation transfusion of pooled platelet concentrate (PC) and cryoprecipitate (14 units) were administered.

The liver transplant surgery progressed uneventfully during exploration of the diseased liver. At the end of anhepatic phase ROTEM data indicated poor clot strength and hyperfibrinolysis (Table 2).

The patient was additionally treated with bolus dose of 2g tranexamic acid followed by continuous infusion of 15 mg/kg/hour, as well as pooled PC, cryoprecipitate (12 units) and 15 ml/kg of fresh frozen plasma (FFP).

One hour following reperfusion of the new graft ROTEM results demonstrated multifactorial coagulopathy due to fibrinogen and platelet deficiency, clotting factor deficiency, as well as heparin-like effect. The heparin-like effect was shown by the shortening of CT in HEPTEM compared to CT in INTEM (Table 2). ROTEM results suggested transfusion of blood products (cryoprecipitate, PC, FFP) and protamine sulphate in dose of 1 mg/kg.

Despite the therapy, at the end of reperfusion FIBTEM results demonstrated haemostasis disorder with pronounced hypofibrinogenemia (Table 2) complicated clinically with massive diffuse bleeding. Fibrinogen replacement in the form of cryoprecipitate (750 mg/kg) in combination with 2 pooled PC and complemented with 8 U of FFP and additional bolus dose of tranexamic acid were given immediately.

Table 3. Patient 2: ROTEM coagulation monitoring prior and after specific treatment

Parameter	After rFVIIa	First control	Second control
EXTEM-CT	241 s	72 s	70 s
EXTEM-CFT	1075 s	167 s	119 s
EXTEM-AA	37°	59°	66°
EXTEM-A10	15 mm	40 mm	50 mm
EXTEM-MCF	25 mm	53 mm	63 mm
INTEM-CT	447 s	227 s	181 s
INTEM-CFT	1332 s	174 s	100 s
INTEM-AA	29°	61°	71°
INTEM-A10	13 mm	39 mm	50 mm
INTEM-MCF	22 mm	50 mm	60 mm
FIBTEM-MCF	undetectable	6 mm	15 mm
APTEM-CT	211 s	56 s	92 s

A clinical response with successfully controlled non-surgical bleeding was achieved. At the end of operation ROTEM results showed marked correction in clotting profile (Table 2). Operation was successfully finished.

During the whole operation period cell saver for autologous blood salvage was used and the blood was transfused back into the patient. Additionally, the patient was transfused with allogeneous RBC aimed at keeping haematocrit between 25-30%. All RBCs and platelet units were leukodepleted.

On the 4th postoperative day ROTEM demonstrated a tracing consistent with near normal clot formation (Table 2).

Patient 2

A 24-year-old male was admitted to hospital after motor cycle accident. On admittance the patient was presented with multiple fractures of ribs and pelvic bones and rupture of the spleen. He was urgently operated on. The patient was treated with RBC, FFP and intravenous fluids, mainly by application of empirical rules. Monitoring was done by standard laboratory and coagulation tests.

After operation the patient developed uncontrolled massive bleeding. Attempts to control massive bleeding by vigorous resuscitation and blood products transfusion failed.

Despite the applied treatment, bleeding continued with the development of haemorrhagic shock. Recombinant activated FVII (rFVIIa) in a dose of 90 µg/kg of body mass was administered, but the reduction/cessation of bleeding was not achieved.

Afterwards, ROTEM investigations were performed which demonstrated a severe complex coagulopathy with pronounced fibrinogen polymerisation problem and disturbed platelet function, coagulation factor deficiency and hyperfibrinolysis (Table 3). These disorders were shown with a zero line (undetectable) in FIBTEM (no clotting), prolonged clot formation time (CFT) and diminished alpha angle (AA) in EXTEM and INTEM, prolonged CT in EXTEM and INTEM and by shortening CT in APTEM compared with EXTEM.

According to the registered ROTEM parameters, the patient was rapidly treated with fibrinogen in the form of cryoprecipitate (16 units) in conjunction with tranexamic

acid (20 mg/kg) as well as 2 pooled PC and FFP (20 mL/kg). Also, RBCs were given to achieve haemoglobin level above 100 g/L.

Control ROTEM measurement showed a significant improvement in coagulation status (Table 3) corresponding to marked slow-down bleeding and a gradual stabilisation of patient's vital parameters.

After additional therapy with cryoprecipitate (16 units), PC (2 pool) and a second dose of tranexamic acid (1 g) that was given 6h after the first dose, ROTEM demonstrated the normalisation of haemostasis (Table 3) corresponding to a complete haemorrhage control.

DISCUSSION

ROTEM is an additional analytical procedure employed for recognising overall disturbances in haemostasis [6]. There is a growing evidence that ROTEM is superior to routine laboratory tests in guiding intraoperative coagulation management. Point-of-care coagulation monitoring is likely to overcome several limitations of routine coagulation testing [3, 4, 5, 8, 9]. ROTEM is an optico-mechanical detection method that provides good protection against the impact of vibrations and mechanical shocks, with a lower susceptibility to movement. This allows the usage of the ROTEM system as a compact, portable instrument, which can be transported and housed in the operating room [4, 5, 7].

One important advantage of the ROTEM system is the possibility to estimate the efficiency of the coagulation process in whole blood, which most closely resembles *in vivo* conditions making it particularly useful for acute and intensive care medicine [6]. The results are available far more rapidly (within 10-30 min) than those from laboratory based conventional coagulation testing which have been criticized as too slow to be clinically useful perioperatively [5, 10]. The method allows the evaluation of the coagulation system as an holistic dynamic process and provides important global haemostatic information [5, 7].

The ROTEM system comes with four independent channels which enable the performance of four independent tests at the same time. The performance of four independent tests using the four channel operation of the ROTEM analyser at the same time provides a parallel representation of different essential parameters for diagnostic evaluation. The use of an automatic electronic pipette and computer-assisted operation procedure and analysis of the data make the ROTEM easy to use [7].

The addition of different coagulation-activating agents and inhibiting agents for platelets, fibrinolysis and heparin allows the reliable detection and quantification of specific coagulation defects, such as hypofibrinogenemia and fibrin polymerization disorder, coagulation factor deficiency, thrombocytopenia and platelet function disorders, heparin effect and hyperfibrinolysis [7, 11]. All these aspects of the coagulation scenario come into play when an individual is injured or undergoing surgery. Thus, ROTEM not only provides a global picture of the injured patient's haemostatic status, but also permits differential diagnosis of the major underlying pathomechanisms of coagulop-

athy. On the other hand, the most important limitation of routine coagulation tests is the fact that the predominant pathomechanism of bleeding in the complex scenario of trauma associated coagulopathy or massive intraoperative blood loss cannot be differentiated [3, 5].

ROTEM tests are started by recalcification and accelerated by adding an activator of extrinsic and intrinsic coagulation pathway. Thromboplastin (tissue factor) from the rabbit brain is used for activation of the extrinsic pathway in EXTEM, FIBTEM and APTEM. FIBTEM contains additional cytochalasin D, a strong inhibitor of the platelet cytoskeleton [7, 11]. APTEM is an EXTEM test which is performed in the presence of aprotinin in order to block hyperfibrinolysis. All extrinsic activated tests are heparin insensitive because they include a heparin inhibitor which is able to eliminate the effect of up to 6 IU heparin per mL of blood. Rabbit brain phospholipids and ellagic acid are used for the activation of intrinsic pathway in INTEM and HEPTEM. HEPTEM is an INTEM test with additional heparinase in order to eliminate the heparin effect [7].

Each test is specific for some portion of the haemostatic mechanism and none can stand alone. EXTEM and FIBTEM should be performed simultaneously as the first line ROTEM test in surgical patients [3]. Clot firmness (A10 or MCF – maximum clot firmness) in EXTEM has to be compared with MCF in FIBTEM to differentiate between fibrinogen deficiency/polymerization disorders and thrombocytopenia/platelet function disorders [7].

EXTEM allows for the visual diagnosis of hyperfibrinolysis, when a typical tapering trace is shown. [3]. Diagnosis of hyperfibrinolysis is very important. Any therapy with fibrinogen concentrate, cryoprecipitate, fresh frozen plasma, recombinant coagulation factors or platelet concentrates may fail as long as there is the presence of overshooting plasmin activity. Early intervention with antifibrinolytic drugs can stop hyperfibrinolysis rapidly and is therefore an effective step before starting other therapies [4, 8, 10].

APTEM permits the quantitative assessment of fibrinolysis and the estimation of the therapeutic benefit of antifibrinolytic agents. Any improvement in CT, CFT and MCF in APTEM compared to EXTEM demask hyperfibrinolysis and enables the diagnosis of enhanced fibrinolysis, as well as the contribution of hyperfibrinolysis to complex haemostasis disorder [3].

INTEM is an important screening reagent to discriminate between surgical bleeding and coagulopathy or effects of heparin treatment. INTEM and HEPTEM should be performed as the first line ROTEM tests in heparinized patients and as the second line ROTEM tests in all other surgical patients if (endogenous or exogenous) heparinization is suggested to complicate bleeding [3]. Heparin effects as well as a protamine overdosage can be detected or excluded by comparing the CTs of INTEM and HEPTEM [7].

The technique is also helpful in monitoring and guiding of therapeutic interventions in a haemostatically compromised patient [5, 7, 8, 10]. Although it has been reported that thromboelastography has been used successfully in the detection of increased risk for thromboembolic events [12, 13], the role of ROTEM in the diagnosis of hypercoagulable state is not yet established.

At the current time, there are no coagulation tests that strongly correlate with or predict surgical bleeding in OLT [5, 10, 14]. The global haemostatic information offered by viscoelastic monitors, and the speed with which this information is delivered, make their use preferable to conventional laboratory based coagulation tests [5]. Numerous general guidelines for optimal use of blood components in OLT do exist and deliver basically the same message. However, OLT surgery is often regarded as a unique situation that escapes the general rule and deserves a specific approach [15].

Haemostatic abnormalities during liver transplantation are divided according to surgical phases (pre-anhepatic, anhepatic, post reperfusion) and post operative period [16].

In our first patient, before starting surgery, it was shown that there was a poor agreement between fibrinogen concentration and ROTEM results suggesting fibrin polymerisation disorder. Also, it was shown the ability of ROTEM to diagnose hyperfibrinolysis which is the disadvantage of classical coagulation tests.

The first operative stage is characterized by extensive surgical trauma. Usually during this phase, mild coagulation abnormalities occur and blood losses are mainly correlated with surgical technique and the baseline hypocoagulable state. Enhanced fibrinolytic activity contributes to blood loss in only 10-20% of patients [16, 17].

During anhepatic phase no important surgical blood loss is seen, because appropriate vessels are clamped. However, hyperfibrinolysis has been demonstrated in many studies, due to net increase in tissue plasminogen activator (tPA) derived from endothelial cells that is not cleared due to the absence of the liver at this time. Additionally, simultaneous decrease of $\alpha 2$ antiplasmin and plasminogen activity and a concomitant increase in fibrin and fibrinogen degradation products do exist [16]. In our patient we observed a mild hyperfibrinolysis in this phase of OLT and poor clot strength which was in concordance with expected haemostatic abnormalities.

Reperfusion of the liver is the crucial point of the operation and leads to profound coagulation abnormalities. Within minutes after reperfusion, uncontrollable diffuse bleeding may occur in some patients [16]. In this phase of OLT, in our patient ROTEM test results indicated multifactorial haemostatic disturbances with a pronounced fibrinogen/fibrin problem and presence of heparin-like substances. Our observation is in accordance with reports in the literature which describe fibrinolysis as the most important and significant phenomenon responsible for bleeding during liver transplantation accompanied by trapping of platelets in the graft and effect of heparin or heparin-like substances released from the donor liver [16-19].

Routine laboratory screening tests provide essential information, but results are supplied too late to accurately reflect a fast changing situation [18]. Furthermore, dysfibrinogenemia, enhanced fibrinolysis and platelet dysfunction pose diagnostic gaps [3, 18]. On the other hand, ROTEM provides the basis for accurate real time assessment of haemostasis and offers a rational approach to the use of blood component therapy or pharmacologic intervention in OLT [10, 16]. In our patient, thanks to ROTEM

analyses the interventions by goal-directed therapy were rapid and accurate.

Blood loss and uncontrollable bleeding are major factors affecting survival in trauma patients and haemorrhage continues to be one of the leading causes of death after trauma [4, 20-22].

Haemorrhagic shock is the commonest cause of death in the early phase of hospital treatment [23]. Coagulopathy that is frequently encountered in haemorrhagic shock has been shown to be an independent risk factor for death after trauma [21]. Coagulopathy can be observed in almost 30% of trauma patients [4]. The development of coagulopathy associated with trauma involves a combination of many factors including overwhelming activation of tissue factor, consumption of coagulation factors and platelets, haemodilution, hyperfibrinolysis, hypothermia, metabolic acidosis, hypocalcemia, anticoagulant drugs for comorbid conditions, massive transfusion and disseminated intravascular coagulation [5, 22, 23, 24].

Ongoing bleeding and hypotension leads to inadequate tissue perfusion and the resulting lactic acidosis. Coagulopathy, acidosis and hypothermia are well described as the „lethal triad” for the trauma patient [23, 24].

The whole approach to the trauma patients has changed over the recent years with the acceptance that in major haemorrhage, excessive resuscitation may worsen the outcome [23]. The ability to detect and treat coagulopathy early appears to be a key component of the multifactorial approach to haemorrhage control in the trauma patients [22, 25].

Monitoring of a developing coagulopathy begins immediately upon arrival to hospital by regularly taking blood samples for analysis in the laboratory. Haemoglobin concentration, platelet count, PT, APTT and fibrinogen concentration, as well as blood grouping and cross-matching should be carried out as early as possible. The value of these tests in critically ill trauma patients is problematic in the massive transfusion situation where the results (available up to 45-60 minutes) lag behind clinical situation and are only therefore of limited utility in determining immediate or empiric therapy. The entire blood volume of the bleeding trauma patient may be exchanged several times during that time interval making the results of the laboratory tests obsolete [4].

It has been demonstrated that ROTEM can rapidly detect systemic changes in in vivo coagulation in trauma patients and may help to guide therapy as it gives real time analysis of clot formation [3, 4, 8].

In accordance with these reports, we observed the ability of ROTEM to accurately diagnose pronounced fibrinogen/fibrin problem in the context of coagulation factors and platelets depletion as well as hyperfibrinolysis in our multitrauma patient 2.

Also, therapeutic administration of rFVIIa was shown to be unsuccessful, despite blood transfusion support, in the light of undetectable true cause of the problem that was found by ROTEM and corrected with delay. After primary goal-directed substitution therapy with fibrinogen and antifibrinolytic drug administration, the cessation of bleeding,

as determined by observation and hemodynamic stabilization, was achieved.

In orthotopic liver transplantation and severely injured trauma patients where events may proceed at a fast and dramatic pace in perioperative period, ROTEM showed utility in rapid obtainance of relevant coagulation infor-

mation. It provided accurate differential diagnosis and specific treatment decisions. Especially, our cases demonstrate that haemostatic information with regard to dysfibrinogenemia and enhanced fibrinolysis make ROTEM use preferable to conventional laboratory based coagulation tests in surgical settings.

REFERENCES

1. Kitchens CS. Surgery and hemostasis. In: Kitchens CS, Barbara MA, Craig MK, editors. *Consultative Hemostasis and Thrombosis*. Philadelphia: Saunders Elsevier; 2007. p.613-634.
2. Koh MBC, Hunt BJ. The management of perioperative bleeding. *Blood Reviews*. 2003; 17:179-85.
3. Kozek-Langenecker S. Management of massive operative blood loss. *Minerva Anesthesiol*. 2007; 73:401-15.
4. Levrat A, Gros A, Rugeri L, Inaba K, Floccard B, Negrier C, et al. Evaluation of rotation thromboelastography for the diagnosis of hyperfibrinolysis in trauma patients. *Br J Anaesth*. 2008; 100(6):792-7.
5. Coakley M, Reddy K, Mackie I, Mallet S. Transfusion triggers in orthotopic liver transplantation: a comparison of the thromboelastometry analyzer, the thromboelastogram and conventional coagulation tests. *J Cardiovasc and Vasc Anaesth*. 2006; 20(4):548-53.
6. Hanecke P, Klouche M. Thromboelastography today: practicability and analytical power. *Transfus Med Hemother*. 2007; 34:421-8.
7. Gorlinger K, Jambor C, Hanke AA, Dirkmann D, Adamzik M, Hartmann M, et al. Perioperative coagulation management and control of platelet transfusion by point-of-care platelet function analysis. *Transf Med Hemother*. 2007; 34:396-411.
8. Engstrom M, Schott U, Reinstrup P. Ethanol impairs coagulation and fibrinolysis in whole blood: a study performed with rotational thromboelastometry. *Blood Coag Fibrinol*. 2008; 17:661-5.
9. Anderson L, Quasim I, Steven R, Soutar M, Macfie A, Korte W. An audit of red cell and blood product use after institution of thromboelastography in a cardiac intensive care unit. *Transf Med*. 2006; 16:31-9.
10. Salooja N, Perry DJ. Thromboelastography. *Blood Coag Fibr*. 2001; 12(5):327-37.
11. Lang T, Toller W, Gutl M, Mahia E, Metzler H, Rehak P, et al. Different effects of abciximab and cytochalasin D on cloth strength in thromboelastography. *J Thromb Haemost*. 2004; 2:147-53.
12. Ben-Ari Z, Panagou M, Patch D, Bates S, Osman E, Pasi J, et al. Hypercoagulability in patients with primary biliary cirrhosis and primary sclerosing cholangitis evaluated by thromboelastography. *J Hepatol*. 1997; 26:554-9.
13. McCrath DJ, Cerboni E, Frumento RJ, Hirsh AL, Bennett-Guerrero E. Thromboelastography maximum amplitude predicts postoperative thrombotic complications including myocardial infarction. *Anesth Analg*. 2005; 100:1576-83.
14. Massicotte L, Sassine MP, Lenis S, Roy A. Transfusion predictors in liver transplant. *Anesth Analg*. 2004; 98:1245-51.
15. Ozier Y, Pessione F, Samain E, Courtois F, for the French Study Group on Blood Transfusion in Liver Transplantation. Institutional variability in transfusion practice for liver transplantation. *Anesth Analg*. 2003; 97:671-9.
16. Senzolo M, Burra P, Cholongitas E, Burroughs AK. New insights into coagulopathy of liver disease and liver transplantation. *World J Gastroenterol*. 2006; 12(48):7725-36.
17. Kang Y. Coagulation and liver transplantation: current concepts. *Liver Transpl Surg*. 1997; 3:465-7.
18. Murakawa M. Coagulation monitoring and management during liver transplantation. *J Anesth*. 2003; 17:77-8.
19. Agarwal S, Senzolo M, Melikian C, Burroughs A, Mallett S. The prevalence of a heparin-like effect shown on the thromboelastograph in patients undergoing liver transplantation. *Liver Transpl*. 2008; 14:855-60.
20. Brahi K, Singh J, Heron M, Coats T. Acute traumatic coagulopathy. *J Trauma*. 2003; 54:1127-30.
21. McLeod JBA, Lynn M, McKenney MG, Cohn SM, Murtha M. Early coagulopathy predicts mortality in trauma. *J Trauma*. 2003; 55:39-44.
22. Spahn DR, Rossaint R. Coagulopathy and blood component transfusion in trauma. *Br J Anaesth*. 2005; 95:130-9.
23. Spivey M, Parr MJA. Therapeutic approaches in trauma-induced coagulopathy. *Minerva Anesthesiol*. 2005; 71:281-9.
24. Schreiber MA. Coagulopathy in the trauma patients. *Curr Opin Crit Care*. 2005; 11:590-7.
25. Tieu BH, Holcomb JB, Schreiber MA. Coagulopathy: its pathophysiology and treatment in the injured patient. *World J Surg*. 2007; 31:1055-64.

Улога ротационе тромбоеластометрије у правовременом дијагностиковању поремећаја хемостазе у хирургији

Драгица Вучелић¹, Предраг Миљић², Небојша Антонијевић³, Мирослав Милићевић¹

¹ Институт за болести дигестивног система, Клинички центар Србије, Београд, Србија;

² Институт за хематологију, Клинички центар Србије; Медицински факултет, Универзитет у Београду, Београд, Србија;

³ Институт за кардиоваскуларне болести, Клинички центар Србије, Београд, Србија

КРАТАК САДРЖАЈ

Увод Мултифакторски поремећаји хемостазе су као компликација трансплантације јетре, повреда и великих хируршких интервенција чести. Лечење акутног крварења на основу резултата добијених стандардним коагулационим тестовима може критично угрозити болесника. За разлику од конвенционалних тестова, ротациона тромбоеластометрија (РОТЕМ) омогућава аутоматизовано, правовремено праћење динамичних хемостатских процеса у целој крви, од стварања угрушка до почетка фибринолизе, укључујући њено даље праћење. Осим тога, утврђивање повишене фибринолизне активности, поремећаја полимеризације фибрина и поремећене функције тромбоцита није могуће стандардним тестовима хемостазе, који се рутински изводе у клиничкој пракси. Циљ рада је био да се укаже на корист РОТЕМ у правовременом постављању тачне дијагнозе поремећаја хемостазе и усмеравању терапијских приступа код трансплантације јетре и повре-

де. Значај РОТЕМ је дат кроз приказ два болесника код којих је хемостаза била поремећена.

Прикази болесника Код првог болесника динамички је праћен поремећај хемостазе током трансплантације јетре и усмерено лечење акутног крварења. Други болесник је доживео вишеструке повреде, након чега је дошло до незаустављивог обилног крварења с неодговарајућим одговором на стандардно лечење и примену активираног рекомбинантног фактора VII. Контрола крварења је постигнута усмереном терапијом на основу резултата РОТЕМ.

Закључак У ортотопичној трансплантацији јетре и трауми РОТЕМ омогућава брзо постављање тачне дијагнозе (или диференцијалне дијагнозе) мултифакторске коагулопатије. Такође обезбеђује основ за усмерену и рационалну примену крвних компонената и лекова за контролу крварења.

Кључне речи: ротациона тромбоеластометрија; трансплантација јетре; траума