

Intraoperative Air Testing of Colorectal Anastomoses

Dejan Ivanov¹, Radovan Cvijanović¹, Ljiljana Gvozdenović²

¹Hospital for Abdominal, Endocrine and Transplantation Surgery, Clinical Centre of Vojvodina, Novi Sad, Serbia;

²Hospital for Anaesthesia and Intensive Therapy, Clinical Centre of Vojvodina, Novi Sad, Serbia

SUMMARY

Introduction Intraoperative anastomotic air testing of stapled colorectal anastomosis is performed by filling the pelvis with saline solution and insufflating the rectum with air through a sigmoidoscope. The presence of air bubbles indicates anastomotic leaks which are resolved during surgery.

Objective The aim of this prospective, randomized study was to perform a comparative analysis regarding the number of anastomotic dehiscences in patients checked by air leak testing and in the control group without air testing.

Methods After stapled colorectal anastomosis was performed, patients were randomized into two groups of 30 patients. The first group patients underwent intraoperative anastomotic air testing, whereas in the control group this procedure was not performed. The two groups were matched for age, sex, diagnosis and surgical procedure.

Results Intraoperative air tests were positive in seven cases and anastomotic defects were repaired. After surgery, there were three clinical leaks in this group of patients. In the control group, there were six leaks (Unilateral Fischer's exact test, $p=0.24$). The incidence of colorectal anastomotic dehiscences in the study group was lower than in the control group by 50%. However, this finding was not statistically significant in our sample.

Conclusion In our opinion, intraoperative air testing of colorectal anastomosis is a good method for prevention of anastomotic dehiscence.

Keywords: rectal neoplasms; sigmoid neoplasms; surgical stapling; anastomosis, surgical; postoperative complications; surgical wound dehiscence

INTRODUCTION

Anastomotic dehiscence is the most severe complication in colorectal surgery, and it is the most frequent cause of postoperative mortality [1]. Among numerous causes of colorectal anastomotic dehiscence, surgical technique is the most significant one [2]. Several smaller clinical studies have shown that intraoperative air testing of colorectal anastomoses might reduce the postoperative leakage rate by detection and management of anastomotic leaks [3, 4, 5].

OBJECTIVE

This prospective, randomized study was designed to establish if intraoperative air testing may reduce the dehiscence rate of stapled colorectal anastomoses.

METHODS

The study included 71 patients undergoing colorectal anastomosis surgery using a stapler device. All patients who took part in the elective surgery program were operated at the Department of Abdominal, Endocrine and Transplantation Surgery of the Clinical Center of Vojvodina. Eleven patients were excluded during the

study. One patient did not agree to take part in the investigation. Out of the remaining ten patients, five were excluded from the study, and five from the control group. In the study group undergoing air testing, two patients were excluded due to peritoneal carcinosis, two due to technically inadequate surgical procedure, whereas one patient died of pulmonary thromboembolism in early postoperative period. In the control group, one patient was diagnosed with carcinosis, one presented with diffuse hepatic metastases, while two patients died of acute myocardial infarction during the postoperative period. The fifth patient from the control group was excluded due to anastomosis defect which could not be repaired, and he received a temporary sigmoidostomy. Findings of 60 patients in good general health (according to the criteria of the American Association of Anesthesiologists) with a confirmed diagnosis of adenocarcinoma of either sigmoid colon or in the proximal two thirds of the rectum were analyzed. The diagnosis was confirmed by findings of colonography, sigmoidoscopy and tumour biopsy. Ultrasonography of the upper abdomen and chest x-ray were performed in order to exclude metastatic changes in the liver and lungs. Laboratory blood analysis was performed in order to detect and manage signs of anaemia, hypoproteinemia and electrolyte imbalance. Patients with abnormal laboratory

Correspondence to:

Dejan IVANOV
Hospital for Abdominal, Endocrine
and Transplantation Surgery
Clinical Centre of Vojvodina
Hajduk Veljkova 1-3, 21000 Novi Sad
Serbia
dijnivanov@yahoo.com

findings were not included in the study. Exclusion criteria were as follows: patients under 18 years of age, patients with advanced stages of malignant diseases (metastatic changes established by US or x-ray) and patients with hand-sewn anastomoses. Patients who were preoperatively treated by either chemo- or radiotherapy were also excluded from the investigation.

All aspects of the clinical protocol were approved by the Ethical Committee of the School of Medicine of the University of Novi Sad. Each patient was required to read provided information, sign an informed consent and include his personal phone number.

Patients were admitted to the hospital a day before surgery. Mechanical preparation of the colon was performed by a nasogastric tube lavage [6], or with Fortrans[®]. Ceftriaxone, cephalosporin of the third generation, was administered prophylactically (1 g) during induction of anaesthesia. In cases of intraoperative peritoneal contamination, the administration of Ceftriaxone was continued postoperatively for seven days, and metronidazole (500 mg/8 h) was initiated. In order to prevent thromboembolic complications, the patients received 0.3 ml of Fraxiparine[®] in the morning before surgery. At the same time, elastic bandages were applied on the lower extremities.

The patients were randomized using computer software. They were divided into two groups: the study group underwent air testing following stapled anastomosis (hereinafter: air-testing group) and the control group without air testing following stapled anastomosis (hereinafter: control group). Each of the two groups included 30 patients.

Surgeries were performed in general endotracheal anaesthesia, while the length of surgical procedure was recorded. The procedure was initiated laparoscopically in five patients, out of which in three cases they were completed likewise. In two cases the laparoscopically initiated surgeries were attempted, but then conversion was necessary. The rest of surgeries (55 cases) were performed by median laparotomy, i.e. relaparotomy. Stapled colorectal anastomosis was preceded by the following procedures: sigmoid colon resection, low anterior resection of the rectum and restitution of sigmoidostomy following Hartmann's procedure. The number of performed surgeries in the air-testing and control groups is shown in Table 1.

After the creation of stapled anastomosis, the integrity of resected rings was inspected, and the tissue was sent for histopathology examination.

The study group underwent intraoperative stapled anastomotic air testing (Figure 1). The colon was clamped with a soft clamp on the proximal side of anastomosis. The small pelvis was filled with saline, to keep the anasto-

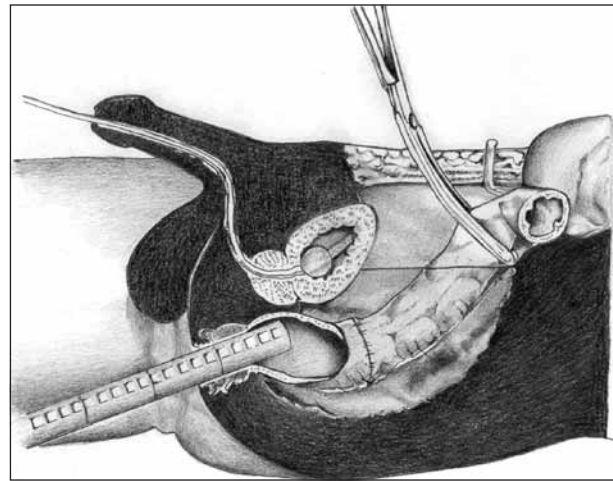


Figure 1. Illustration of air testing procedure using a sigmoidoscope

mosis under the fluid. Tissue particles which could have prevented observation of bubbles during the air testing were removed by aspiration. The sigmoidoscope was introduced through the anus and air was insufflated into the rectum. Insufflation was continued until the rectum was optimally distended. The whole length of anastomosis was examined. The appearance of bubbles indicated a defect in the anastomotic line and presented a positive air testing. If the bubbles were absent, the air testing was considered negative. The removal of the sigmoidoscope eyepiece was followed by desufflation of the rectum. The air testing procedure took about three minutes. In cases with positive air testing, the anastomotic defect was repaired by single-layer extramucosal sutures. After anastomotic reconstruction, air testing was repeated.

Based on intraoperative findings the surgeon makes the decision whether or not to introduce a nasogastric probe. In our study it was applied in 41 patients. At least one abdominal drain was placed in each patient.

After surgery, patients were transferred to the Intensive Care Unit or to the Department of Abdominal Surgery. They received infusion therapy until the intestinal peristalsis was restored, and they started receiving perioral meals; once the drains were removed, they were discharged from hospital. Hospital stay (in days) was also recorded for the purpose of comparison with the duration of postoperative period.

The outcome of a successfully created anastomosis means successful healing without dehiscence. Unsuccessful creation of anastomosis results in dehiscence with the following clinical symptoms [7, 8]: gas leakage, pus or faecal discharge from the drain, clinical picture of anastomotic dehiscence (increased body temperature, stomach painful at palpation, auscultatory evidence of absent peristalsis, signs of liquid-gas levels at abdominal x-ray, leukocytosis) with or without a confirmation by sigmoidoscope, and the presence of intra-abdominal abscess verified either by ultrasonography or CT of the abdomen.

Statistical data analysis was performed using the Statistica 7.0 software package.

Table 1. The number and type of surgical procedures in both examined groups

Surgical procedure	Study group	Control group	Total
Sigmoid colon resection	14	17	31
Low anterior rectal resection	5	4	9
Sigmoidostomy diversion after Hartmann's operation	11	9	20

RESULTS

The mean age of patients enrolled in the study was 60.3 years (range 47-87 years); there were 38 males (63.3%) and 22 females (36.7%). Patients undergoing colorectal anastomosis performed by automatic stapler device were randomized into two groups of 30 patients each. The study group comprised subjects in whom anastomosis was tested intraoperatively by air leak testing. In this group the mean age was 58.6 years (range 41-81 years) and there were 20 male patients (66.7%). The mean age of patients in the control group, without air leak testing, was 62.0 years (range 45-87 years) and it included 18 male patients (60%).

Mann-Whitney U-test was used to compare data regarding the age of the examined patients in both groups. The test showed p-value of 0.14, and the significance level of $\alpha=0.1$, so it can be concluded that the groups were homogenous by age. The homogeneity of the study and control group was also estimated regarding the patients' sex. The p-value of 0.79 was obtained by χ^2 -test and showed that the groups were uniform regarding gender as well.

Sixty patients received automatic stapled colorectal anastomosis. In both groups the proximal and distal rings were examined. They were complete in 55 performed anastomoses (91.7%), whereas in five cases one of the rings was incomplete (8.3%). There were no cases with both incomplete rings. These results are shown in Table 2. In both cases incomplete rings occurred in the air testing group and the air leak was positive. In all five cases with incomplete rings, the repair of anastomosis was performed with single layer extramucosal sutures. Dehiscences of anastomosis occurred in two patients, one in each group.

Out of the 30 tested colorectal anastomoses, air testing was positive in seven cases. In all cases the defect was repaired by single layer sutures. Anastomoses were once again tested by air leak testing. There were no patients who required reanastomosis, protective colostomy or ileostomy. Out of seven positive air tests, dehiscence of anastomosis occurred in two cases (28.6%). One patient with dehiscence of anastomosis required reoperation. Out of the remaining 23 patients with negative air tests, only one patient presented with dehiscence of anastomosis (4.3%).

Dehiscence of colorectal anastomoses was the main investigated parameter. Out of 60 colorectal anastomoses, dehiscence occurred in nine cases, with a dehiscence rate of 15%. There were three dehiscences of anastomoses in the group with air testing (10%) versus six (20%) in the control group. The correlation between the number of dehiscences in the study and control groups was estimated as well. The unilateral Fisher's exact test gave a p-value of 0.24, so that based on the tested sample, it cannot be concluded that there was a statistically significant difference between these two groups. The modalities of dehiscences of anastomoses and their correlations are presented in Table 3.

The occurrence of dehiscence required reoperation in one patient in each group. The patient in the air testing group, who presented with a missing proximal ring in the stapler following anastomosis and a positive air leak testing, underwent reoperation. The defect was repaired by

Table 2. The integrity of staple rings in both examined groups

Integrity	Study group	Control group	Total
Complete rings	28	27	55
Incomplete staple ring	2	3	5
Both staple rings are incomplete	0	0	0

Table 3. Number of anastomotic dehiscences in both examined groups, with clinical presentation of dehiscence

Anastomotic dehiscences	Study group	Control group
Fecal discharge through a drain	1	2
Clinical picture of dehiscence	1	3
Intraabdominal abscess	1	1

three single layer extramucosal sutures and the repeated air leak testing was negative. On the fourth postoperative day, the patient presented with clinically severe signs of dehiscence, associated with peritonitis, so he underwent another surgery forming a temporary sigmoidostomy. In one patient in the control group, sigmoid colon resection was initiated laparoscopically, but the surgery was completed by open method due to technical difficulties.

None of the patients died of dehiscence of stapled colorectal anastomosis. One subject died of a massive pulmonary thromboembolism, and two due to acute myocardial infarction in the early postoperative period; they were excluded from the study.

The relationship between the number of dehiscences and air leak testing outcomes (positive/negative) was tested by χ^2 -test, and the obtained p-value of 0.25 indicated that in the tested sample there was no statistically significant difference between the number of dehiscences and test outcomes.

In regard to the fact that the age of patients could have presented a risk factor for the development of dehiscences, the correlation between the number of dehiscences and the patients' age was also estimated. Mann-Whitney's U-test ($p=0.18$) showed that there was no statistically significant difference between the number of dehiscences and the patients' age. We also examined the correlation between the number of dehiscences and the patients' sex. Fisher's exact test gave a p-value of 0.43, suggesting that there was no statistically significant difference between the number of dehiscences and the patients' gender.

In the group of patients with air testing, the average duration of surgical procedures was 104.5 minutes (from 75 to 150), whereas the mean duration of surgeries in the control group was 101 minutes (from 75 to 150). No statistical significance was established (Mann-Whitney's test, $p=0.62$). The duration of surgeries in both groups is presented in Table 4.

The length of hospitalization (in days – only postoperative days were studied) in the group undergoing air testing was 8.63 days on average. In the control group it was longer by 0.57 days (9.2 days). Mann-Whitney's test showed that there was no statistically significant difference in the number of postoperative hospitalization days between the two investigated groups. The length of hospital stay in both groups is presented in Table 5.

Table 4. Length of surgery in both examined groups

Length of surgery	Study group	Control group
75 minutes	7	8
90 minutes	9	10
120 minutes	10	9
150 minutes	4	3
Mean length (minutes)	104.5	101

Table 5. Length of hospitalization in both examined groups

Length of hospitalization	Study group	Control group
6 days	8	7
8 days	12	13
10 days	7	4
15 days	3	6
Mean length (days)	8.63	9.2

DISCUSSION

Numerous factors influence the colorectal anastomotic failure. They can be divided into three basic groups: general or systemic, local and technical. General factors are associated with the patient himself and they depend on his general health (age, nourishment status, systemic diseases, use of medications, or radiation). Local factors are associated with the conditions of immediate surgical procedure on the colon and they comprise infection, local or distant trauma, presence of peritoneum, pathologic changes in the colon, and intraluminal pressure. Technical factors are most important and they are associated with the surgical performance and the surgeon's surgical knowledge and skills.

Colorectal anastomotic dehiscence depends on the vascularization of the colon, pressure on the suture line, strength of the performed anastomosis and on the applied surgical technique (technical factors). These factors are strictly under the control of the surgeon, and therefore Fielding has concluded that the surgeon is the most important individual factor influencing the integrity of anastomosis [2]. Methods used by the surgeon to control the procedure and corrections he makes during surgery are of utmost importance.

At our Department, testing tissue rings after stapled colorectal anastomosis has been a standard procedure for some time. If anastomosis is performed by using "purse string sutures", the integrity of proximal and distal rings is tested just after the removal of sutures. In this study, out of 60 performed anastomoses, in five cases (8.3%) one of the rings was incomplete. These results are in agreement with the literature data [9]. There were two incomplete rings in the study group, versus three in the control group. In all five cases, anastomoses were repaired by the addition of a single layer of extramucosal sutures.

Dehiscence, the last examined parameter in the control group, occurred in six cases (20%). Due to the fact that these were only clinically confirmed dehiscences, the dehiscence rate was moderately increased when compared with the literature data [3, 7, 9].

In one patient abdominal CT scan revealed an abscess along the posterior wall of the rectum. The abscess spontaneously drained through the anal canal. The patient received antibiotic therapy and was discharged from hospital. In cases with a small pelvic abscess after colorectal anastomosis, there is always the question of causes and consequences. Shorthouse et al. supposed that fluid collection in the free segment of the posterior rectum and abscess formation were the causes of dehiscences and not their consequence [10].

The only dehiscence of anastomosis requiring reoperation in the control group manifested on the third postoperative day by leakage of faecal matter through the drain. It occurred in a patient with initial laparoscopic approach with completion of surgery by open method due to technical problems. The control of rings did not reveal any defects. During the reoperation, the patient received a sigmoidostomy and was discharged from hospital after a longer postoperative period.

Bearing in mind that in the control group there were no lethal outcomes caused by dehiscences and taking into account that the results also comprised laparoscopic surgeries recently introduced at our Department [11], the dehiscence rate may be considered acceptable.

However, out of three cases with incomplete rings, dehiscences occurred in two. Although the anastomotic defect was repaired by additional sutures, the patients developed a clinical picture of dehiscence during the postoperative period. It was treated by conservative therapy, but nevertheless, there was still a question whether only control of tissue rings was sufficient to establish the defects of stapled anastomoses. On the other hand, dehiscences occurred in cases with complete rings as well.

In our opinion, control of tissue rings alone was insufficient for the estimation of stapled anastomotic integrity and therefore we decided to use air leak testing as a supplementary measure of control, assuming that its application may lead to dehiscence rate decrease. We decided to use this test for its simplicity of application and because there was no need for special education of surgeons. Besides, every operating room for colorectal surgery is supplied with equipment necessary for air leak testing. By the modification of air leak testing, using of distilled water instead of saline, the cytotoxic effect was achieved. At the same time, once sigmoidoscope was introduced in the rectum, if there was a need, anastomosis could have been immediately tested.

Having in mind that the first principle of medicine is to "do no harm", the question is whether this test may damage the recently performed stapled anastomosis. Our answer is negative. Based on the available literature data and our investigated sample, the safety of anastomoses was not impaired. Two patients were excluded from the study for technical problems. In both cases the surgeon carrying out the test was responsible for the surgical results. At the same time, theoretically, air testing is safe for patients. Namely, unlike water, air is compressible and therefore insertion of larger quantities does not lead to sudden pressure increase. Also, unlike using the Foley catheter, during insertion of the sigmoidoscope, at certain pressure level, the air goes

out the anal canal alongside the sigmoidoscope. Beard et al. [3] reported that in five patients the required increase of pressure above 35 mm Hg could not be achieved because the air came out alongside the sigmoidoscope. The safety of this method was definitely confirmed by final results of the study; the dehiscence rate in the study group was lower, not higher than in the control group.

Both investigated groups comprised 30 patients, matching for age and sex. All patients underwent equal preoperative treatment. Only patients in good general health were scheduled for surgical treatment and were included in the study. Also, only patients with rectosigmoid cancer were taken into account. In our opinion, at a certain moment cancer may become a systemic disease, but the doctors are not certain at which, and thus it cannot be compared with the diseases of one organ system, which is the case with diverticulosis. Besides, diverticulosis is a benign disease. On the other hand, some authors [3, 4, 9] compare results obtained treating carcinomas, adenomas, inflammatory diseases of the colon, and diverticulosis.

There were six dehiscences of anastomoses in the control group, versus three in the air testing group. Although the difference in the dehiscence rate was not statistically significant, considering absolute numbers, the number of dehiscences was less by half. In addition, knowing that there were no dehiscence-caused lethal outcomes, we can conclude that the results were good. Out of 30 performed air testings, the test was positive in seven cases. After the detection of anastomotic leakage, they were repaired by individual sutures. The repeated air testings were negative. Out of these seven cases, anastomotic dehiscences occurred in two. It may be supposed that dehiscences could have also occurred in the remaining five patients, if the defects had not been detected and repaired. However, the occur-

rence of these two dehiscences indicated that in certain cases addition of sutures only might not be sufficient to prevent dehiscences. In cases when dehiscences coincided with incomplete rings, positive air testing and the need for reoperation, we thought that the addition of individual sutures were not sufficient.

Under these circumstances, is it better to complete surgery by creating a protective surgical stoma, or by forming a new anastomosis? We believe that the creation of a new anastomosis is a better solution, because it was established that protective colostomy or ileostomy did not prevent occurrence of dehiscences, but only reduced the consequences [4], although there are different opinions [12].

Air testing was negative in a total of 23 cases. Out of these 23 stapled anastomoses, dehiscence occurred in one case. It was in an elderly patient with sigmoid colon carcinoma who underwent termino-terminal stapled anastomosis after resection. Dehiscence occurred on the seventh postoperative day, which meant that not only were technical factors responsible for the occurrence of dehiscence, but also some other factors, such as age and sex, were of certain significance.

CONCLUSION

Air testing of stapled colorectal anastomoses is a simple method to perform. It is used in the detection of stapled colorectal anastomotic defects, which can be repaired during surgery, and in this way the dehiscence rate is decreased. Air testing prolongs surgery by a few minutes, but at the same time shortens hospital stay.

REFERENCES

- Goligher JC, Graham NG, De Dombal FT. Anastomotic dehiscence after anterior resection of rectum and sigmoid. *Br J Surg.* 1970; 57:109-18.
- Fielding LP, Stewart-Brown S, Blesovsky L, Kearney G. Anastomotic integrity after operations for large-bowel cancer: a multicentre study. *Br Med J.* 1980; 281:411-4.
- Beard JD, Nicholson ML, Sayers RD, Lloyd D, Everson NW. Intraoperative air testing of colorectal anastomoses: a prospective, randomized trial. *Br J Surg.* 1990; 77:1095-7.
- Davies AH, Bartolo DCC, Richards AEM, Johnson CD, Mortensen NJMcC. Intra-operative air testing: an audit on rectal anastomosis. *Ann R Coll Surg Engl.* 1988; 70:345-7.
- Gilbert JM, Trapnell JE. Intraoperative testing of the integrity of left-sided colorectal anastomoses: a technique of value to the surgeon in training. *Ann R Coll Surg Engl.* 1988; 70:158-60.
- Cvijanović R. Ispitivanje primene intestinalne lavaže pomoću duodenalne sonde kod pripreme bolesnika za operaciju na debelom crevu [doktorska disertacija]. Novi Sad: Medicinski fakultet Univerziteta u Novom Sadu; 1990.
- Rullier E, Laurent C, Garrelon JL, Michel P, Saric J, Parneix M. Risk factors for anastomotic leakage after resection of rectal cancer. *Br J Surg.* 1998; 85:355-8.
- Krivokapić Z. Mere prevencije popuštanja anastomoze na debelom crevu. Beograd: Naučna knjiga; 1990.
- Lazorthes F, Chiotassol P. Stapled colorectal anastomoses: peroperative integrity of the anastomosis and risk of postoperative leakage. *Int J Colorect Dis.* 1986; 1:96-8.
- Shorthouse AJ, Bartram CI, Eyers AA, Thomson JPS. The water soluble contrast enema after rectal anastomosis. *Br J Surg.* 1982; 69:714-7.
- Cvijanović R, Korica M, Majdevac S, Ivanov D, Zoričić D, Farkas E. Laparoskopiska resekcija rektuma. *Acta Chir Iugosl.* 2001; 48(3):85-7.
- Schmidt O, Merkel S, Hohenberger W. Anastomotic leakage after low rectal stapler anastomosis: significance of intraoperative anastomotic testing. *Eur J Surg Oncol.* 2003; 29(3):239-43.

Интраоперативна водена проба колоректалних анастомоза

Дејан Иванов¹, Радован Цвијановић¹, Љиљана Гвозденовић²

¹Клиника за абдоминалну, ендокрину и трансплантациону хирургију, Клинички центар Војводине, Нови Сад, Србија;

²Клиника за анестезију и интензивну терапију, Клинички центар Војводине, Нови Сад, Србија

КРАТАК САДРЖАЈ

Увод Водена проба је интраоперативна метода провере стејплерске колоректалне анастомозе која се изводи тако што се мала карлица испуни водом, а у ректум уведе ваздух помоћу сигмоидоскопа. Појава мехурића указује на оштећење анастомозе, које се збрињава прешивањем.

Циљ рада Циљ овог проспективног истраживања био је да се упореди број дехисценција у групи испитаника код којих је водена проба изведена и у контролној групи болесника, код којих она није примењена.

Методе рада По завршетку испитивања стејплерске колоректалне анастомозе, одабрано је по 30 болесника из обе групе, које су биле уједначене по свим параметрима (старост и пол испитаника, дијагноза и хируршки поступак).

Резултати Интраоперативна водена проба је била позитив-

на код седам болесника, а оштећење на анастомози је ушивено. После операције, код три испитаника ове групе јавила се дехисценција. У контролној групи дехисценција је дијагностикована код шест испитаника (Фишеров унилатерални егзактни тест, $p=0,24$). Према је у испитиваној групи испитаника број дехисценција анастомоза био двоструко мањи него у контролној групи, у нашем узорку испитаника ова разлика није била статистички значајна.

Закључак Сматрамо да је интраоперативна провера стејплерских анастомоза воденом пробом добра метода за превенцију дехисценција.

Кључне речи: неоплазме ректума; неоплазме сигмоидног колона; хируршко аутоматско шивење; хируршка анастомоза; постоперационе компликације; дехисценција хируршке ране

Примљен • Received: 17/02/2010

Прихваћен • Accepted: 21/05/2010