

# Does Sclerotherapy of Remnant Little Oesophageal Varices after Endoscopic Ligation Have Impact on the Reduction of Recurrent Varices? Prospective Study

Saša Grgov, Perica Stamenković

Department of Gastroenterology and Hepatology, General Hospital, Leskovac, Serbia

## SUMMARY

**Introduction** Endoscopic band ligation (EBL) is superior to endoscopic injection sclerotherapy (EIS) of oesophageal varices, however, EBL is associated with a higher rate of variceal recurrences.

**Objective** To examine whether the reduction of recurrent varices can be achieved by additional sclerotherapy of remnant little varices after ligation.

**Methods** Forty-eight patients with liver cirrhosis who had previously bled from oesophageal varices were examined. Endoscopic therapy was performed in order to prevent recurrent variceal bleeding. I group: in 23 patients ligation of oesophageal varices with multi band ligation device was applied (EBL group). II group: in 25 patients sclerotherapy using polydocanol or absolute alcohol was applied after reducing the size of varices using ligation (EBL and EIS group).

**Results** There was no statistically significant difference between the examined groups of patients in relation to the number of sessions for variceal eradication, recurrence of variceal bleeding, deterioration of portal gastropathy and mortality in the observed period from 18.8±18.6 months (EBL group) and 22.2±26.2 months (EBL and EIS group). Variceal recurrence was verified in 21.7% of patients of the EBL group and 16% of the EBL and EIS group, but the difference was not statistically important. Several complications, such as dysphagia and chest pain, were statistically more frequent in the EBL and EIS group of patients.

**Conclusion** The combined method of ligation and extra sclerosing of remnant small oesophageal varices after ligation does not have advantage in relation to the ligation alone.

**Keywords:** oesophageal varices; endoscopic ligation; sclerotherapy; recurrent varices

## INTRODUCTION

Portal hypertension is the most common complication of cirrhosis accounting for significant morbidity and mortality mainly because of variceal hemorrhage, ascites, bacterial infections, hepatic encephalopathy and hepatorenal syndrome. In patients with cirrhosis the overall incidence of variceal bleeding is about 4% to 15% per year. Fatal outcome is above 30% in the first episode of bleeding. Patients surviving the first episode of variceal bleeding have a risk of over 60% of experiencing recurrent haemorrhage within two years from the index episode. Because of this, all patients surviving variceal bleeding should receive active treatment for the prevention of rebleeding. Available treatments for preventing variceal rebleeding include pharmacological therapy, endoscopic therapy, transjugular intrahepatic portosystemic shunt (TIPS) and surgical shunting [1, 2, 3].

Endoscopic treatment is a local treatment aimed at eradicating the varices. Since it does not decrease portal pressure, the varices may recur after endoscopic treatment, and patients need to receive a life-long endoscopic follow-up to detect variceal recurrence. Endoscopic band ligation (EBL) is clearly superior to endoscopic injection sclerotherapy (EIS) due to less frequent and severe complications, but EBL is associated with a higher rate of variceal recurrence [4, 5, 6].

The data in the literature about effects of sclerotherapy performed on remnant little varices after endoscopic ligation on reducing of recurrent varices are scarce.

## OBJECTIVE

The aim of this study was to examine whether recurrent varices reduction can be achieved by additional sclerotherapy of remnant little varices after ligation.

## METHODS

Forty-eight patients with liver cirrhosis who previously bled from oesophageal varices were examined. Endoscopic therapy was performed in order to prevent recurrent variceal bleeding. All patients gave their consent before endoscopic treatment was undertaken.

I group: in 23 patients the ligation of oesophageal varices with a multi band ligation device was applied (EBL group). II group: in 25 patients sclerotherapy was applied after reducing the size of varices using ligation (EBL and EIS group). The examined groups of patients did not differ significantly according to gender, age, cause of cirrhosis, varices size and Child-Pugh's class (Table 1). All examined patients had portal gastropathy. The exclusion criteria

## Correspondence to:

Saša GRGOV  
Department of Gastroenterology  
and Hepatology  
General Hospital  
Rade Končara 9, 16000 Leskovac  
Serbia  
grgov@open.telekom.rs

**Table 1.** Characteristics of examined groups of patients

Parameter	EBL group	EBL and EIS group
Number of patients (male/female)	23 (19/4)	25 (21/4)
Age (years), mean $\pm$ SD (min-max)	56.2 $\pm$ 8.02 (43-71)	57.6 $\pm$ 8.05 (41-75)
Alcoholic cirrhosis (n)	13 (56.5%)	13 (52%)
Postviral cirrhosis (n)	6 (26%)	6 (24%)
Alcoholic and postviral cirrhosis (n)	4 (17.3%)	6 (24%)
Varices grade II (n)	7 (30.4%)	8 (32%)
Varices grade III (n)	12 (52.1%)	13 (52%)
Varices grade IV (n)	4 (17.3%)	4 (16%)
Child-Pugh A (n)	11 (47.8%)	13 (52%)
Child-Pugh B (n)	10 (43.4%)	10 (40%)
Child-Pugh C (n)	2 (8.6%)	2 (8%)

p>0.05; n – number of patients

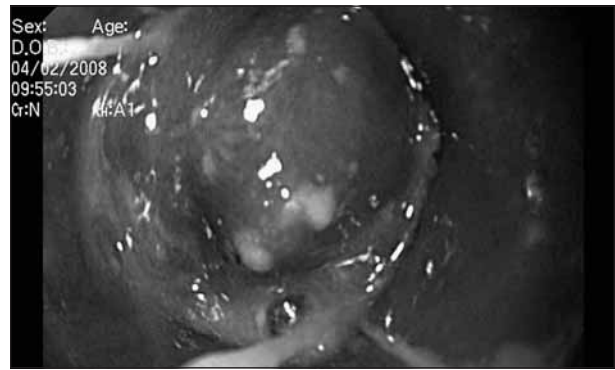
were: 1) association with gastric varices; 2) association with malignancy, uraemia, or other debilitating diseases; and 3) history of sclerotherapy or shunt operation. Beta-blockers were not administered during the study.

Endoscopy was carried out under topical oropharyngeal anaesthesia. Conscious sedation was provided with intravenous midazolam only in agitated patients.

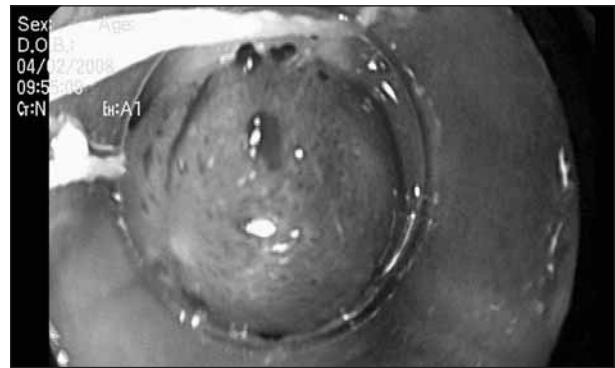
In the EBL group of patients banding started at the gastroesophageal junction, and then continued proximally for several centimetres. The treatment was repeated at two-week intervals until the varices completely disappeared or were significantly reduced to small residual varices gr I (Figures 1-4). In the EBL and EIS group of patients banding was also started at the gastroesophageal junction. The treatment was repeated at two-week intervals until the varices were significantly reduced to small residual varices grade I. After that, one session of sclerotherapy using polydocanol or absolute alcohol of 0.5 ml per injection until the total quantity of 10 ml, was applied. The sites of injections were confined to the distal oesophagus and intended for intravariceal injection.

Thereafter, in both groups of patients follow-up endoscopic examination was applied every three months to detect recurrence of oesophageal varices, deterioration of portal gastropathy or occurrence of gastric varices. Portal hypertensive gastropathy was assessed as macroscopic finding of a characteristic mosaic-like pattern of the gastric mucosa (mild portal hypertensive gastropathy), red-point lesions, cherry red spots, and/or black-brown spots (severe portal hypertensive gastropathy) [1, 7]. For patients with recurrent oesophageal varices, a repeated session of EBL was performed in both groups of patients. When rebleeding from the oesophageal varices was encountered, repeated sessions of EBL were performed in both groups until the varices were obliterated.

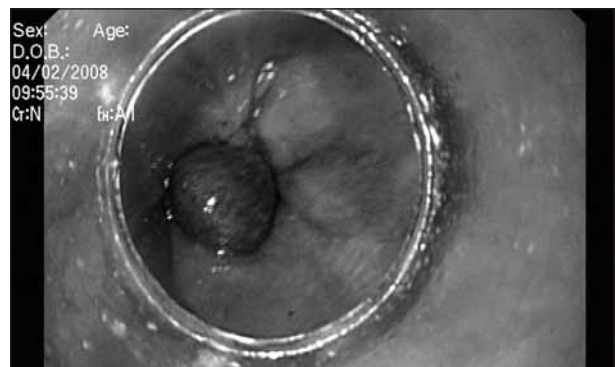
The descriptive statistical methods used included measures of central tendency (mean value –  $\bar{X}$ ) and a measure of dispersion (standard deviation – SD). The methods of statistical analysis used to assess the significance of differences included Student's t test, Mantel-Haenszel's  $\chi^2$  test with Yates corrections and Fisher's exact test. The level of significance was p<0.05.



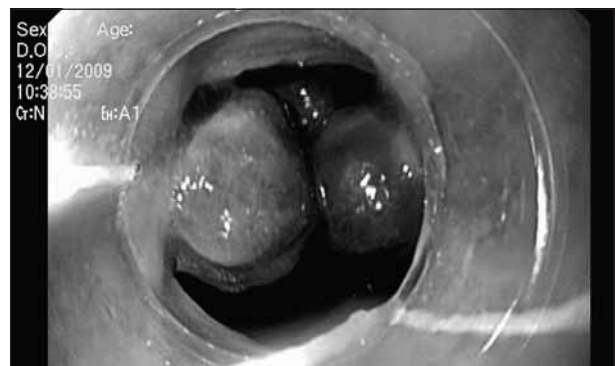**Figure 1.** Approximation of the endoscope tip mounted with the multi-band ligator until there is full contact with the varix



**Figure 2.** Suction of the oesophageal mucosa, submucosa, and the varix



**Figure 3.** Strangulation of the varix with the rubber band



**Figure 4.** Three ligated varices at the bottom of the oesophagus

## RESULTS

There was no statistically significant difference between the examined groups of patients in relation to the number

of sessions for variceal eradication ( $3.85 \pm 1.06$  in the EBL group vs.  $2.93 \pm 1.07$  in the EBL and EIS group).

Variceal recurrence was verified more frequently in the EBL group of patients (21.7%) than in the EBL and EIS group (16%), in the observed period from  $18.8 \pm 18.6$  months (EBL group) and  $22.2 \pm 26.2$  months (EBL and EIS group), but the difference was not statistically important ( $p > 0.05$ ).

Recurrence of variceal bleeding was verified only in one patient (4.3%) in the EBL group and also in one patient (4%) in the EBL and EIS group in the observed periods.

Deterioration of portal gastropathy occurred in two patients (8.6%) of the EBL group and in six patients (24%) of the EBL and EIS group, but the difference was not statistically important ( $p > 0.05$ ).

Gastric varices did not occur in any patient of the EBL groups and of the EBL and EIS group in the observed periods.

The same number of patients died in both of the examined groups. Mortality was related to the deterioration of liver function, but not to variceal bleeding (Table 2).

All complications in both groups of patients were not life depriving, but some, such as dysphagia and chest pain, were statistically more frequent in the EBL and EIS group of patients (44% vs. 13% respectively for dysphagia, and 40% vs. 8.6% respectively for chest pain). Fever was verified in one patient (4.3%) in the EBL group and three patients (12%) in the EBL and EIS group, but the difference was not statistically important. Oesophageal ulcer was verified only in the EBL and EIS group in two patients (8%) (Table 3). All complications in the EBL and EIS group of patients occurred after final session of sclerotherapy of remnant little varices after ligation.

## DISCUSSION

Despite the fact that much progress has been made in treatment and research over the recent decades, variceal hemorrhage is still one of the most severe complications of liver cirrhosis. All patients who survive an episode of acute variceal bleeding should undergo secondary prophylaxis. A number of trials have demonstrated that EBL is superior to EIS with regard to the time required to achieve variceal eradication, the rate of recurrent bleeding and treatment induced complications. Thus, EBL is at present the endoscopic treatment of choice. However, EBL is associated with a higher rate of recurrence of varices, because the obliteration of paraesophageal varices is not possible [8, 9, 10].

The effort to identify an optimal endoscopic technique for variceal eradication led to the combination of EBL and EIS. In combined endoscopic therapy sclerotherapy has been added to EBL either simultaneously or after the reduction of variceal size to small. Meta-analysis of the simultaneously performed EBL and EIS did not show any benefit to EBL alone, either for rebleeding or for mortality, and it also showed a trend towards an increasing complication rate with combined endoscopic therapy. Therefore, there

**Table 2.** Treatment results in the compared groups

Parameter	EBL group	EBL and EIS group
Treatment sessions to eradicate varices	$3.85 \pm 1.06$	$2.93 \pm 1.07$
Variceal recurrence (n)	5 (21.7%)	4 (16%)
Variceal rebleeding (n)	1 (4.3%)	1 (4%)
Deterioration of portal gastropathy (n)	2 (8.6%)	6 (24%)
Mortality (n)	3 (13%)	3 (12%)
Follow-up (months)	$18.8 \pm 18.6$	$22.2 \pm 26.2$

$p > 0.05$ ; n – number of patients

**Table 3.** Complications

Complication	EBL group	EBL and EIS group	p
Dysphagia	3 (13%)	11 (44%)	$< 0.05$
Chest pain	2 (8.6%)	10 (40%)	$< 0.05$
Fever	1 (4.3%)	3 (12%)	$> 0.05$
Oesophageal ulcer	0	2 (8%)	$> 0.05$

is no rationale to combine both endoscopic approaches simultaneously [11, 12, 13].

Few studies in the literature suggest that performing of a small amount of sclerosing agent on the varices after their reduction in size with EBL, result in less frequent variceal recurrence and rebleeding rate. Sclerotherapy of these little remnant varices after ligation is technically more accessible than ligation alone, because it is more difficult to achieve their aspiration by ligation. Also, it is possible that sclerotherapy may obliterate paraesophageal varices and achieve decrease of variceal recurrence. Thus, EIS can be useful in very small remnant varices after ligation [14, 15, 16]. There were also a small number of variceal recurrences in our group treated by the combination of ligation and sclerotherapy (16%) in relation to the group treated only by ligation (21.7%), but the difference was not statistically important. Rebleeding was verified in the same percentage in both groups of our patients. It should be kept in mind that the limiting factor in our study was the sample size, which probably prevented adequate statistical results.

After sclerotherapy, a higher number of patients develop portal gastropathy than after ligation, while the occurrence of gastric varices is similar. The reason for this is that deeper ulcers occur after sclerotherapy resulting in the development of fibrous tissue and that there is obliteration of perforated oesophageal veins, and thus an increase of portal pressure and redistribution in the portal vascular system [17, 18, 19]. These changes caused by sclerotherapy should be less frequent in a combined method of ligation and sclerotherapy of varices, because of the application of a small amount of sclerosing agent. Nevertheless, in our patients the deterioration of portal gastropathy was verified more often in the group of patients treated by ligation and additional sclerotherapy of varices (24%) in relation to the group of patients treated only by ligation of varices (8.6%), but the difference was not statistically important. In both groups of treated patients we did not verify the appearance of gastric varices in the observed periods.

The complications after the ligation of varices are rare and milder than after sclerotherapy. Chest pain and dysphagia are transitory. The complications of endoscopic

sclerotherapy are numerous: dysphagia, chest pain, febrility, small pleural effusions, ulcers and oesophageal stenoses. The most serious side effects of sclerotherapy are dysphagia, oesophageal stenosis and bleeding of oesophageal ulcers, which may account for as much as 14% of all rebleeding episodes [1]. We should expect fewer complications with the application of the combined method of ligation and additional variceal sclerotherapy for applying small amounts of sclerosing agents, which was shown by researches Lo et al. [14]. Nevertheless, in this study some complications, such as dysphagia and chest pain, were statistically more frequent after session of sclerotherapy in the group of patients on combined endoscopic therapy.

Some studies examined the effect of variceal ligation followed by mucosa-fibrosing with microwave on variceal recurrence. Recurrence of varices occurred in 60% of patients treated only by ligation and in 16% of patients treated by combined therapy ( $p=0.03$ ) [20]. Similar results were achieved with argon plasma coagulation after ligation [21, 22, 23]. A recent study by Monici et al. [24] showed that application of microwave coagulation to oesophageal varices after band ligation was safe. The post micro-

wave coagulation recurrence rate may be comparable to that observed following the combined treatment of EBL and EIS. The presence of gastric varices increases the risk of oesophageal variceal recurrence. However, long-term effects of different combined endoscopic methods on the reduction of variceal recurrence after ligation is not clear enough for now.

## CONCLUSION

In conclusion, the combined method of ligation and extra sclerosing of remnant small varices after ligation does not have advantages compared to the ligation alone, but more extensive studies are required.

## NOTE

The paper was presented at the 11<sup>th</sup> European Bridging Meeting in Gastroenterology in Belgrade, Serbia, on 31<sup>st</sup> October and 1<sup>st</sup> November 2009.

## REFERENCES

- Bosch J, Berzigotti A, Garcia-Pagan JC, Abraldes JG. The management of portal hypertension: rational basis, available treatments and future options. *J Hepatol.* 2008; 48 Suppl 1:S68-92.
- de Franchis R. Evolving consensus in portal hypertension. Report of the Baveno IV consensus workshop on methodology of diagnosis and therapy in portal hypertension. *J Hepatol.* 2005; 43:167-76.
- Cárdenas A, Ginès P. Portal hypertension. *Curr Opin Gastroenterol.* 2009; 25:195-201.
- Garcia-Pagan JC, Bosch J. Endoscopic band ligation in the treatment of portal hypertension. *Nat Clin Pract Gastroenterol Hepatol.* 2005; 2:526-35.
- Garcia-Tsao G, Sanyal AJ, Grace ND, Carey W. Prevention and management of gastroesophageal varices and variceal hemorrhage in cirrhosis. *Hepatology.* 2007; 46:922-38.
- Bai Yu, Li ZS. Management of variceal hemorrhage: current status. *Chin Med J (Engl).* 2009; 122(7):763-5.
- Primignani M, Carpinelli L, Preatoni P, Battaglia G, Carta A, Prada A, et al. Natural history of portal hypertensive gastropathy in patients with liver cirrhosis. The New Italian Endoscopic Club for the study and treatment of esophageal varices (NIEC). *Gastroenterology.* 2000; 119:181-7.
- Dong MH, Saab S. Complications of cirrhosis. *Dis Mon.* 2008; 54:445-56.
- Villanueva C, Piqueras M, Aracil C, Gómez C, López-Balaguer JM, Gonzalez B, et al. A randomized controlled trial comparing ligation and sclerotherapy as emergency endoscopic treatment added to somatostatin in acute variceal bleeding. *J Hepatol.* 2006; 45:560-7.
- Qureshi W, Adler DG, Davila R, Egan J, Hirota W, Leighton J, et al; Standards of Practice Committee. ASGE Guideline: the role of endoscopy in the management of variceal hemorrhage, updated July 2005. *Gastrointest Endosc.* 2005; 62:651-5.
- Karsan HA, Morton SC, Shekelle PG, Spiegel BM, Suttrop MJ, Edelstein MA, et al. Combination endoscopic band ligation and sclerotherapy compared with endoscopic band ligation alone for the secondary prophylaxis of esophageal variceal hemorrhage: a meta-analysis. *Dig Dis Sci.* 2005; 50:399-406.
- Djurđević D, Janošević S, Dapčević B, Vukčević V, Djorđević D, Svorcan P, et al. Combined ligation and sclerotherapy versus ligation alone for eradication of bleeding esophageal varices: a randomized and prospective trial. *Endoscopy.* 1999; 31(4):286-90.
- Singh P, Pooran N, Indaram A, Bank S. Combined ligation and sclerotherapy versus ligation alone for secondary prophylaxis of esophageal variceal bleeding: a meta-analysis. *Am J Gastroenterol.* 2002; 97(3):623-9.
- Lo GH, Lai KH, Cheng JS, Lin CK, Huang JS, Hsu PI, et al. The additive effect of sclerotherapy to patients receiving repeated endoscopic variceal ligation: a prospective, randomized trial. *Hepatology.* 1998; 28:391-5.
- Hou MC, Chen WC, Lin HC, Lee FY, Chang FY, Lee SD. A new „sandwich” method of combined endoscopic variceal ligation and sclerotherapy versus ligation alone in the treatment of esophageal variceal bleeding: a randomized trial. *Gastrointest Endosc.* 2001; 53:572-8.
- Cheng YS, Pan S, Lien GS, Suk FM, Wu MS, Chen JN, et al. Adjuvant sclerotherapy after ligation for the treatment of esophageal varices: a prospective, randomized long-term study. *Gastrointest Endosc.* 2001; 53:566-71.
- Avgerinos A, Armonis A, Stefanidis G, Mathou N, Vlachogiannakos J, Kougioumtzian A, et al. Sustained rise of portal pressure after sclerotherapy, but not band ligation, in acute variceal bleeding in cirrhosis. *Hepatology.* 2004; 39:1623-30.
- Sung JY. Treatment of variceal bleeding. *Curr Treat Options Gastroenterol.* 2003; 6:171-80.
- Sanyal AS. The value of EUS in the management of portal hypertension. *Gastrointest Endosc.* 2000; 52(4):575-9.
- Hokari K, Kato M, Katagiri M, Komatsu Y, Sato F, Sukegawa M, et al. A new combined therapeutic method for esophageal varices; endoscopic variceal ligation followed by mucosa-fibrosing with microwave. *Gastroenterology.* 1998; 114(Suppl 1):A1257.
- Nakamura S, Mitsunaga A, Murata Y, Suzuki S, Hayashi N. Endoscopic induction of mucosal fibrosis by argon plasma coagulation (APC) for esophageal varices: a prospective randomized trial of ligation plus APC vs. ligation alone. *Endoscopy.* 2001; 33:210-5.
- Cipolletta L, Bianco M, Rotondano G, Marmo R, Meucci C, Piscopo R. Argon plasma coagulation prevents variceal recurrence after band ligation of esophageal varices: Preliminary results of a prospective randomized trial. *Gastrointest Endosc.* 2002; 56:467-71.
- Furukawa K, Aoyagi Y, Harada T, Enomoto H. The usefulness of prevention consolidation therapy of esophageal varices using an argon plasma coagulation technique. *Hepatol Res.* 2002; 23(3):220-5.
- Monici LT, Meirelles-Santos JO, Soares EC, Mesquita MA, Zeitune JM, Montes CG, et al. Microwave coagulation versus sclerotherapy after band ligation to prevent recurrence of high risk of bleeding esophageal varices in Child-Pugh's A and B patients. *J Gastroenterol.* 2010; 45(2):204-10.

## Да ли склеротерапија заосталих малих варикса једњака након ендоскопског лигирања има утицаја на смањење рецидива варикса? Проспективна студија

Саша Гргов, Перица Стаменковић

Одељење за гастроентерологију и хепатологију, Општа болница, Лесковац, Србија

### КРАТАК САДРЖАЈ

**Увод** Ендоскопско банд-лигирање (ЕБЛ) варикса једњака је много боље од ендоскопске инјекционе склеротерапије (ЕИС), али је рецидив варикса већи након ЕБЛ.

**Циљ рада** Циљ рада је био да се испита може ли се постићи смањење рецидива варикса додатном склеротерапијом заосталих малих варикса након лигирања.

**Методе рада** У испитивање је укључено 48 особа са цирозом јетре код којих су установљена претходна крварења из варикса једњака. Ендоскопска терапија је примењена ради превенције рецидива крварења. Испитаници су сврстани у две групе: прву су чинила 23 болесника код којих је примењено лигирање варикса једњака мултибанд лигатором (ЕБЛ група), док је другу групу чинило 25 болесника код којих је примењена склеротерапија варикса полидоканолом или апсолутним алкохолом након смањења величине варикса лигирањем (ЕБЛ и ЕИС група).

**Резултати** Није било статистички значајне разлике између испитиваних група болесника у погледу броја сесија до искорењивања варикса, рецидива крварења, погоршања портне гастропатије и морталитета током периода клиничког праћења од  $18,8 \pm 18,6$  месеци (ЕБЛ група), односно  $22,2 \pm 26,2$  месеца (ЕБЛ и ЕИС група). Рецидив варикса је потврђен код 21,7% испитаника прве, односно 16% испитаника друге групе, али разлика није била статистички значајна. Неке од компликација, као што су дисфагија и бол у грудима, биле су статистички значајно чешће код болесника ЕБЛ и ЕИС групе.

**Закључак** Комбинована метода лигирања и додатне склерозације заосталих малих варикса једњака након лигирања нема предности у односу на само лигирање варикса.

**Кључне речи:** варикси једњака; ендоскопско лигирање; склеротерапија; рецидив варикса

Примљен • Received: 27/01/2010

Прихваћен • Accepted: 15/07/2010