

# Successful Retrieval of an Unexpanded Coronary Stent from the Left Main Coronary Artery during Primary Percutaneous Coronary Intervention

Sonja Šalinger-Martinović<sup>1</sup>, Siniša Stojković<sup>2</sup>, Milan Pavlović<sup>1</sup>, Zoran Perišić<sup>1</sup>, Slobodan Obradović<sup>3</sup>, Svetlana Apostolović<sup>1</sup>, Milan Živković<sup>1</sup>, Nenad Božinović<sup>1</sup>

<sup>1</sup>Clinic for Cardiovascular Diseases, Clinical Centre, Niš, Serbia;

<sup>2</sup>Department of Cardiology, Clinical Centre of Serbia, Belgrade, Serbia;

<sup>3</sup>Cardiology Department, Military Medical Academy, Belgrade, Serbia

## SUMMARY

**Introduction** Dislodgement and embolization of the new generation of coronary stents before their deployment are rare but could constitute a very serious complication.

**Case Outline** We report a case of a stent dislodgement into the left main coronary artery during the primary coronary intervention of infarct related left circumflex artery in a patient with acute myocardial infarction. The dislodged and unexpanded bare-metal stent FlexMaster 3.0x19 mm (Abbot Vascular) was stranded and bended in the left main coronary artery (LMCA), probably by the tip of the guiding catheter, but stayed over the guidewire. It was successfully retrieved using a low-profile Ryujiin 1.25x15 balloon catheter (Terumo) that was passed through the stent, inflated and then pulled back into the guiding catheter. After that, the whole system was withdrawn through the 6 F arterial sheath via the transfemoral approach. After repeated cannulation via the 6F arterial sheath, additional BMW and ATW guidewires were introduced into the posterolateral and obtuse marginal branches and a bare-metal stent Driver (Medtronic Cardiovascular Inc) 3.0x18 mm was implanted in the target lesion.

**Conclusion** Stent dislodgement is a rare but potentially life-threatening complication of the percutaneous coronary intervention. This incident occurring in the LMCA in particular during an acute myocardial infarction requires to be urgently resolved. The avoidance of rough manipulation with the guiding catheter and delivery system may help in preventing this kind of complications.

**Keywords:** STEMI; primary angioplasty; bare metal stent; dislodgement

## INTRODUCTION

Stent dislodgement or migration during coronary artery stenting is a rare complication and the incidence varies between 0.32-8.3% [1, 2]. Systemic and coronary embolizations are the consequences of stent dislodgement and can lead to serious complications such as the acute closure of the affected vessel, coronary thrombosis, and myocardial infarction. In the past, manual crimping of stents was associated with a significantly increased risk of the stent disengagement and embolization. Although manually crimped stents are seldom used, the problem of stent dislodgement and potential embolization has not been completely eliminated [3]. We present a case of a successful retrieval of an unexpanded and slightly bended coronary stent from the left main coronary artery (LMCA) via the transfemoral approach.

## CASE REPORT

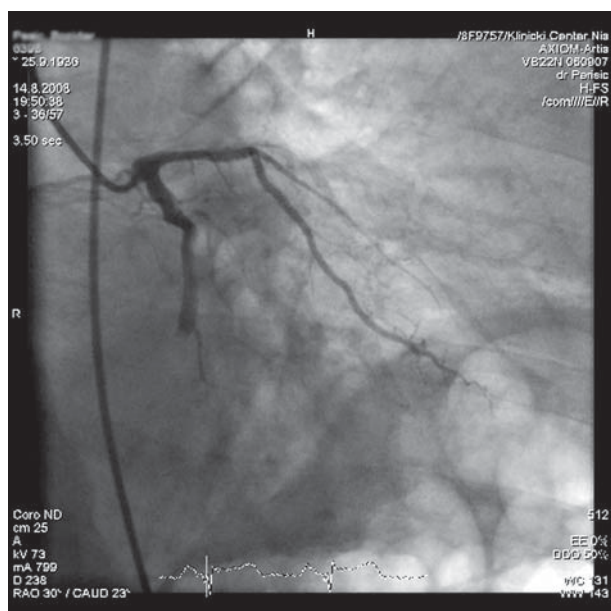
A 70-year-old man was admitted to our hospital with an inferior wall acute myocardial infarction with persistent ST segment elevation. Twelve hours after the onset of the symptoms, he was admitted to a local hospital and immediately transferred to our centre for primary

percutaneous coronary intervention (PCI). At the local hospital, the patient was treated with Aspirin 300 mg, Clopidogrel 300 mg, Enoxaparin 70 mg sc and analgesic agents. The electrocardiogram revealed the ST segment elevation in inferior leads (D2, D3, aVF) with an abnormal R wave in V1-V3 leads (R/S ratio >1 in V1). The values of the cardiac markers of myocardial necrosis were elevated: TnI 12 ng/ml, CKMB mass 300 ng/ml. The emergency echocardiographic examination showed inferoposterior akinesia, with a preserved global systolic function (EF 60%). The patient was sent to the catheterization laboratory and treated with additional Clopidogrel dose (300 mg), Enoxaparin 0.3 mg/kg (20.0 mg iv) and agent for gastroprotection (proton pump inhibitor).

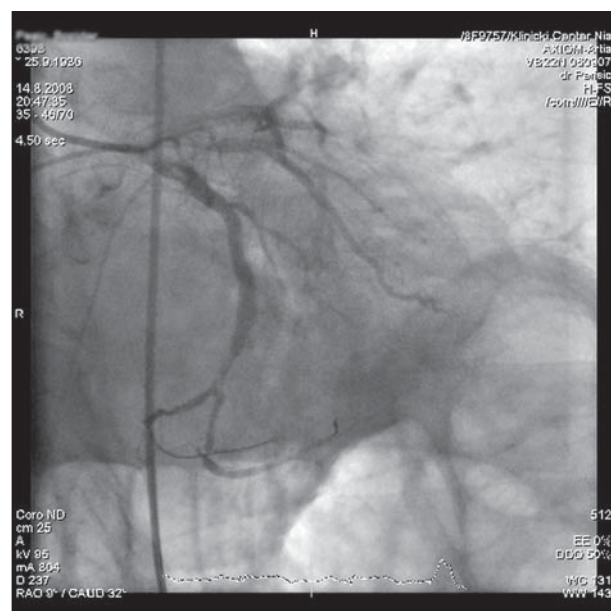
Using the right femoral approach (6 F arterial sheath), the coronary angiography revealed an occlusion in the mid-portion of the left circumflex artery (LCX) (Figure 1). After the implantation of a temporary pace-maker due to conduction disturbances, a 6 French (Fr) EBU 3.75 guiding catheter (Cordis Corporation, Miami Lakes, Florida) was used to engage the LMCA. The first attempt to cross the occluded segment of the LCX with a Zinger medium guidewire (Medtronic Cardiovascular Inc.) was unsuccessful. After this attempt, a Crosswire NT guidewire (TERUMO) was advanced across

## Correspondence to:

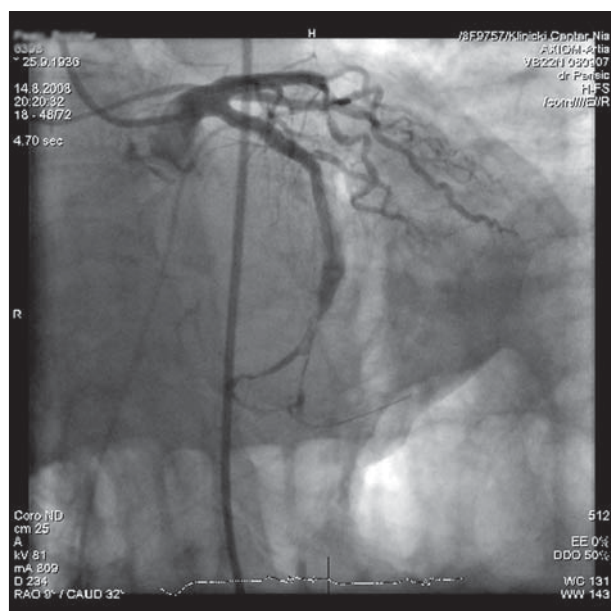
Sonja ŠALINGER-MARTINOVIĆ  
Durlan 23, 18000 Niš  
Serbia  
sonja.salinger@gmail.com



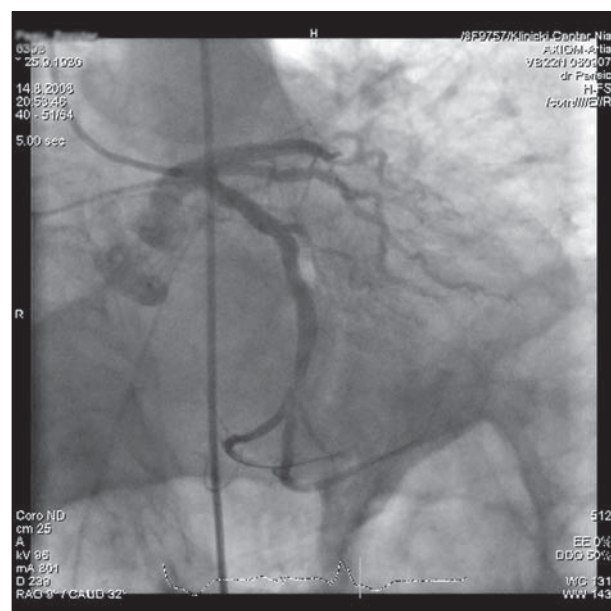**Figure 1.** Occlusion of the infarct related left circumflex artery



**Figure 3.** BMW guidewire advanced in the LCX posterolateral branch, and an ATW guidewire in the obtuse marginal branch



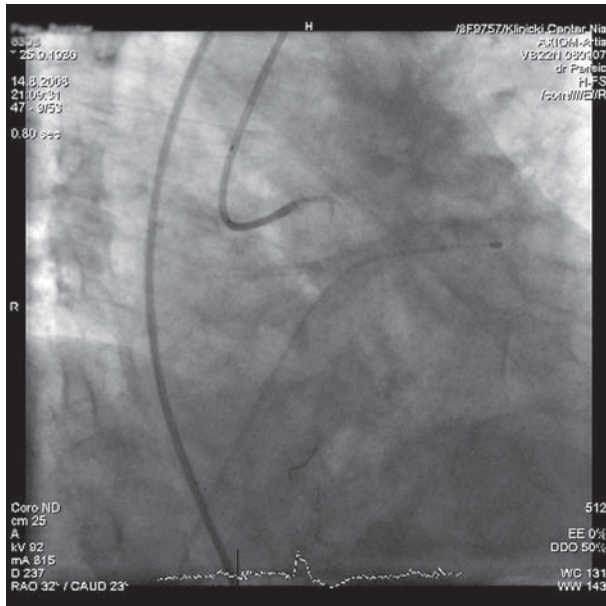
**Figure 2.** Advanced Crosswire NT guidewire across the lesion into the distal LCX



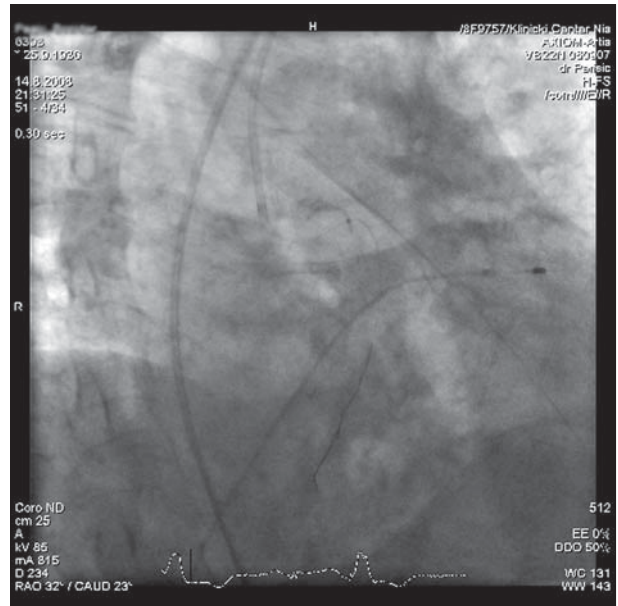
**Figure 4.** TIMI 3 flow after the predilatation of the lesion and of both side branches

the lesion without difficulty into the distal LCX (Figure 2). Following this, a Balance Middle Weight (BMW) guidewire (Guidant, Advanced Cardiovascular System Inc., CA, USA) was advanced in the LCX posterolateral branch, and an All Track Wire (ATW) (Cordis, USA) in the obtuse marginal branch (Figure 3). A Sprinter balloon catheters (Medtronic Cardiovascular) 1.5×20 mm and 20×20 mm were used to predilate the culprit lesion and both side branches at 16 atmospheres. After repeated intracoronary administration of nitro-glycerine (200 µg + 200 µg) a TIMI 3 flow was achieved (Figure 4). Then, the intention was to stent the lesion with a bare-metal stent FlexMaster 3.0×19 mm (Abbot Vascular), over the BMW guidewire in the posterolateral branch jailing the second guidewire in order to protect the obtuse marginal branch. While trying

to advance the stent across the guiding catheter, the guiding catheter got decannulated from the LMCA. In an attempt to recannulate the left coronary artery, the balloon catheter and stent were pulled back to advance the guiding catheter. The attempt was unsuccessful, the guidewire twisted inward making a loop, and the unexpanded stent peeled off from the balloon and slightly bended in the LMCA (Figure 5). The balloon was removed and a Ryujiin 1.25×15 balloon catheter (Terumo) was gently passed over the straightened guidewire through the stent (Figure 6). The balloon was inflated at 8 atm and carefully withdrawn inside the guiding catheter along with the dislodged stent. The whole system, including the guiding catheter, the balloon catheter, the dislodged stent and the guidewires were withdrawn through the femoral sheath. After repeated cannulation,



**Figure 5.** Dislodged and slightly bended stent in left main coronary artery



**Figure 6.** Ryujin 1.25x15 balloon catheter passed over the straightened guidewire through the stent

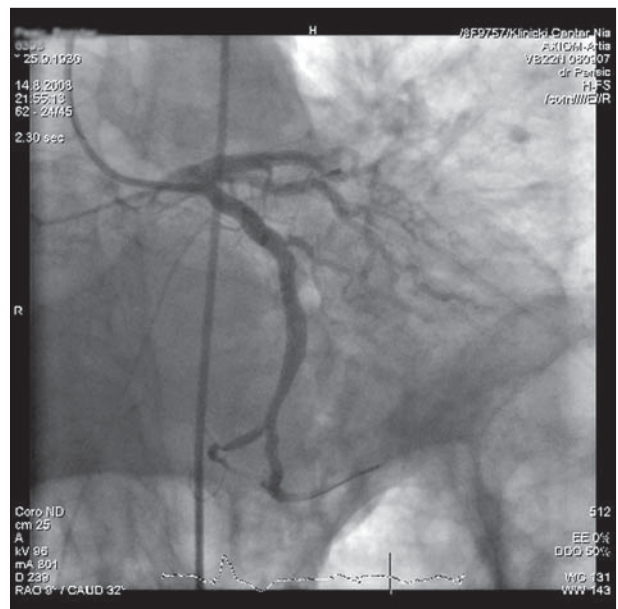
additional BMW and ATW guidewires were introduced into the posterolateral and obtuse marginal branches. A bare-metal stent Driver (Medtronic Cardiovascular Inc.) 3.0x18 mm was implanted in the target lesion at 12 atm. After that a post-dilatation of the proximal part of the stent was performed using a Maverick balloon catheter (Boston Scientific) 3.25x9 mm at 18 atm. Following this, the jailed guidewire was removed, and the TIMI 3 flow remained in both side branches (Figure 7).

## DISCUSSION

Dislodgement and embolization of new generation coronary stents before deployment is rare and may lead to challenging complications of intracoronary stenting. The incidence of stent dislodgement is uncommon and is lower now than at the time when stents were manually crimped, with reports varying between 0.32% and 8%. Dislodgement of a stent can be secondary to severe coronary angulation, calcified coronary arteries, inadequate coronary artery predilatation and direct stenting [4].

Despite the infrequent incidence of stent dislodgement, the consequences may be severe, sometimes fatal, and operators are generally not familiar with this kind of complication [5]. Adequate delivery and placement of coronary stents are dependent not only on proficient handling, but also on various properties [1]. Flexibility, structure, shape, and radial strength affect the durability and deliverability of stents. The stent visibility is also important in delivery and retrieval procedures [6].

The dislodging may occur at the guide tip when traversing the coronary artery proximal to the lesion, or in the lesion itself. If the guide choice and stability are not proper, the guide will be displaced from the coronary ostium as the stent exits the guide and meets resistance in the coronary artery [7]. The stent cannot be pushed on because there is



**Figure 7.** Final result: TIMI 3 flow after post dilatation of the bare-metal stent Driver 3.0x18 mm implanted in the target lesion

no backup. The guide can be advanced over the stent or the stent can be withdrawn into the guide until a better guide position is found. The above mentioned manoeuvres may both cause stent displacement and embolization. This complication may be avoided by choosing appropriate equipment; a low profile mounted stent that is well attached to the balloon, a guide catheter that will provide back-up and possibly a stiffer wire that helps to straighten bends in the coronary artery and reduce resistance. The most important means of avoiding this complication is to take care with the manipulations as the stent exits or re-enters the guide. Unnoticed proximal coronary lesions or calcification can cause stent displacement during the advancement of the delivery system [7, 8].

A complication such as undeployed stent in the LMCA can be life-threatening [2]. Such a complication may lead to emergency surgery, or may be treated percutaneously. The dislodged stent can be deployed locally, can be crushed to the arterial wall by a balloon or stent, or retrieved by a double guidewire technique. Other methods include usage of devices such as a biptome, a loop basket, a gooseneck snare, or an alligator forceps catheter [2, 3, 9]. The advent of IVUS imaging has played a significant role in enhancing visualization of stent deployment. The use of IVUS can perhaps improve percutaneous management of lost stents, further reducing the need for surgical retrieval [10].

In our case, the dislodged and unexpanded stent was stranded and bended in the LMCA, probably by the tip

of the guiding catheter, but stayed over the guidewire. It was removed from this location using a low profile delivery balloon and advancing it through the stent, inflating the balloon on low pressure and then pulling back into the guiding catheter. The guiding catheter, balloon and stent were removed via the femoral sheath.

Stent dislodgement is a rare but potentially life-threatening complication of the percutaneous coronary intervention. This incident occurring in the LMCA in particular during an acute myocardial infarction requires to be urgently resolved. The avoidance of rough manipulation with the guiding catheter and delivery system may help in preventing this kind of complications. This complication may, on occasion, be treated percutaneously preventing a more serious outcome.

## REFERENCES

- Colkesen Y, Baltali M, Acil T, Tekin G, Tekin A, Erol T, et al. Coronary and systemic stent embolization during percutaneous coronary interventions. A single center experience. *Int Heart J.* 2007; 48:129-36.
- Patel MT, Shah SC, Gupta AK, Ranjan A. Successful retrieval of transradially delivered unexpanded coronary stent from the left main coronary artery. *Indian Heart J.* 2002; 54:715-6.
- Goldberg A, Kemer A, Anne G, Gruberg L. Clinical images: one stent lost in two arteries. *J Invas Cardiol.* 2004; 16(3):163-4.
- Ahmar W, Malaipayan Y, Meredith IT. Transradial retrieval of a dislodged stent from the left main coronary artery. *J Invasive Cardiol.* 2008; 20:545-7.
- Brilakis ES, Best PJ, Elesber AA, Barsness GW, Lennon RJ, Holmes DR, et al. Incidence, retrieval methods, and outcomes of stent loss during percutaneous coronary intervention: a large single-center experience. *Catheter Cardiovasc Interv.* 2005; 66:333-40.
- Lohavanichbutr K, Webb JG, Carere RG, Solankhi N, Jarochoowski M, D'yachkova Y, et al. Mechanisms, management, and outcome of failure of delivery of coronary stents. *Am J Cardiol.* 1999; 83:779-81.
- Uyuan C, Gunduz H, Arinc H, Akademir R. Embolised stent into the circumflex coronary artery during percutaneous coronary intervention. *Int Heart J.* 2006; 47:125-9.
- Yimaz H, Belgi A, Demir I, Basarc I, Sancaktar O. Successful transcatheter retrieval of an embolized stent from the left ventricle. *J Invas Cardiol.* 2002; 14(8):466-468.
- Meisel SR, DiLeo J, Rajakaruna M, Pace B, Frankel R, Shani J, et al. A technique to retrieve stents dislodged in the coronary artery followed by fixation in the iliac artery by means of balloon angioplasty and peripheral stent deployment. *Catheter Cardiovasc Interv.* 2000; 49:77-81.
- George JC, Fiss D, Bashir R. Management of dislodged coronary stent using intravascular ultrasound. *Cath Lab Digest Archive.* 2009; 17(11):36-9.

## Успешно извлачење неекспандираног коронарног стента из главног стабла леве коронарне артерије током примарне перкутане коронарне интервенције

Соња Шалингер-Мартиновић<sup>1</sup>, Синиша Стојковић<sup>2</sup>, Милан Павловић<sup>1</sup>, Зоран Перишић<sup>1</sup>, Слободан Обрадовић<sup>3</sup>, Светлана Апостоловић<sup>1</sup>, Милан Живковић<sup>1</sup>, Ненад Божиновић<sup>1</sup>

<sup>1</sup>Клиника за кардиоваскуларне болести, Клинички центар, Ниш, Србија;

<sup>2</sup>Клиника за кардиологију, Клинички центар Србије, Београд, Србија;

<sup>3</sup>Клиника за кардиологију, Војномедицинска академија, Београд, Србија

### КРАТАК САДРЖАЈ

**Увод** Склизнуће са балона пре уградње и миграција стентова нове генерације веома су ретке, али потенцијално опасне, компликације перкутане коронарне ангиопластике.

**Приказ болесника** Приказујемо случај склизнућа стента у главно стабло леве коронарне артерије током примарне перкутане коронарне ангиопластике леве циркумфлексне артерије код болесника с акутним инфарктом миокарда. Стент од нерђајућег челика (*FlexMaster 3.0×19 mm, Abbott Vascular*) манипулацијом врха катетера склизнуо је са балона у главно стабло леве коронарне артерије, али је остао на коронарној жици. Извађен је помоћу нископрофилног балон-катетера (*Ryujiin 1.25×15 mm, Terumo*) који је постављен и инсуфлиран унутар стента, а затим увучен у катетер заједно

са стентом. После тога, читав систем, укључујући и катетер, извучен је кроз феморални шит од 6 F. Након поновне канулације преко артеријског уводника од 6 F коронарне жице *BMW* и *ATW* су пласиране у постеролатералну и оптузну маргиналну грану, а стент од нерђајућег челика (*Driver 3.0×18 mm, Medtronic Cardiovascular Inc.*) постављен је на место стенозе.

**Закључак** Склизнуће неуграђеног стента, премда ретка, може бити по живот опасна компликација. Склизнуће стента у главно стабло леве коронарне артерије током примарне перкутане коронарне ангиопластике захтева хитно решавање. Нежнијом манипулацијом катетером водичем и носачем стента може се спречити оваква врста проблема.

**Кључне речи:** STEMI; примарна ангиопластика; стент од нерђајућег челика; спадање стента