

# Histopathology of Urinary Bladder Carcinoma: Less Common Variants

Ivan Damjanov<sup>1</sup>, Mileta Golubović<sup>2</sup>

<sup>1</sup>Department of Pathology and Laboratory Medicine, The University of Kansas School of Medicine, Kansas City, Kansas, USA;

<sup>2</sup>Medical Faculty, University of Montenegro, Centre for Pathology, Clinical Centre of Montenegro, Podgorica, Montenegro

## SUMMARY

Bladder cancer is a common form of neoplasia which most often presents histologically as urothelial (transitional cell) carcinoma. In this article we review recent publications dealing with the less common variants of urothelial carcinoma such as tumours that show unusual forms of differentiation or the well known squamous, glandular, or sarcomatoid differentiation. Urothelial tumours may also show several distinct growth variants characterized by a nested, micropapillary, lymphoepithelioma-like, or plasmacytoid and giant cell growth pattern. The clinical course of bladder cancer varies depending on the histological type of neoplasia, grade and stage of the tumour. High-grade muscle-invasive urothelial cancers and tumours showing variant microscopic morphology have in general high mortality and poor prognosis.

**Keywords:** urinary bladder; urothelial carcinoma; pathology

## INTRODUCTION

Bladder cancer is the fourth most common cancer in men in the United States, after prostate, lung, and colorectal cancer and the 10th most common cancer in women [1]. From 1985-2000, the number of patients diagnosed annually with bladder cancer has increased by 33%. The recurrence rate for superficial transitional cell cancer of the bladder is high and as many as 80% of patients have at least one recurrence. Thus an annual cohort of 300,000–400,000 patients with bladder cancer has been reported yearly in the United States, representing a major public health problem. The median age at diagnosis is 68 years, and the incidence increases with age. Up to 90% of those affected are over the age of 55 years and many of the patients are elderly. Carcinoma of the urinary bladder was significantly more common in men (ratio of 2.5:1). Blood group A is prevalent blood group in both male and female patients [2].

Urothelial carcinomas in young people are low grade and noninvasive, but even in younger patient a regular follow-up is recommended after surgery since the tumour may recur or become more malignant [3]. Due to the prolongation of human life one may expect an increased incidence and prevalence of bladder cancer in all parts of the world.

Since bladder cancer detected in the early stages has a good chance of cure, awareness of the signs and symptoms of this malignancy are critical. Active search for bladder cancer in patients suspected of having this neoplasia is part of the preventive urinary tract medicine. Pathologist plays an important role in the

early diagnosis of bladder cancer, which may depend on the cytopathologic or histopathologic findings. The planning of therapy and the prognosis of these tumours also depend on pathology findings, and pathologic staging is of crucial significance in this respect [4]. Finally, pathologists play an important role in teaching the basics of microscopic diagnosis to medical students, clinical trainees and other allied health professions which all participate in the treatment of patients with urinary bladder cancer [5].

## Molecular biology

Current research in molecular pathology has contributed to the diagnostic of bladder cancer and the understanding of its pathogenesis, as presented in a recent review by Mitra and Cote [6]. The available data indicate that the low grade and noninvasive tumours result from one molecular pathway, whereas in the invasive high grade carcinomas the sequence of events involves completely different pathways. Namely, the low grade tumours show RAS-MAPK gene activation, whereas in the high grade tumours cancerogenesis depends on the changes or mutations of TP53 tumour suppressor gene and retinoblastoma (RB-1) gene pathway. The transition from the less aggressive tumour growth into a more anaplastic form of growth involves changes in the molecular pathways but such a switch occurs relatively rarely. Unfortunately the general consensus is that of the risk of recurrence and progression from noninvasive to invasive cancer still cannot be fully predicted on the basis of molecular biologic data, even

## Correspondence to:

Mileta GOLUBOVIĆ  
Medical Faculty  
University of Montenegro  
Centre for Pathology  
Clinical Centre of Montenegro  
Ljubljanska b.b., Settlement  
Kruševac  
81000 Podgorica  
Montenegro  
miletagol@t-com.me

though such data have contributed to our understanding of pathogenesis and biology of bladder cancer [7]. Additional data are obviously required and more work must be completed prior to a final major breakthrough that could help us prevent the development of bladder cancer.

## **PATHOLOGY**

Almost all bladder cancers are epithelial in origin, and more than 90% are classified as urothelial (transitional) carcinoma [7-12]. In Europe and North America only 5% of bladder cancers are squamous cell in origin, and 2% are adenocarcinomas. Squamous cell carcinoma is much more common in parts of Africa, like Egypt, and other areas infested with *Schistosoma haematobium*. Non-urothelial primary bladder tumours such as primary lymphoma and sarcoma are extremely rare [10], and will not be addressed here. All the common and uncommon forms of bladder cancer are included in the current histological classification of bladder cancers prepared by the experts of the World Health Organization (WHO) published in 2004 [11]. A slightly modified version of that classification is presented in Table 1. It is worth notice that the histological types of urinary bladder carcinoma are essentially the same in Balkan endemic nephropathy areas as well as in other parts of the world [8].

## **Grading**

The most significant prognostic factors for bladder cancer are grade, depth of invasion, and the presence of carcinoma in situ (CIS) [13]. Grading of invasive carcinomas is of limited clinical significance, because the prognosis of such tumours depends primarily on the extent of invasion, i.e. the stage of the tumour. On the other hand grading of papillary lesions has important implication for therapy and prognosis. The WHO classification of 1973 of papillary tumours of the bladder included three grades of urothelial carcinoma: grade 1, grade 2 and grade 3. This grad-

**Table 1.** Histological classification of tumours of the urinary bladder according to the World Health Organization 2004

Urothelial neoplasia	
Benign	Urothelial papilloma
	Inverted papilloma
Papillary urothelial neoplasm of low malignant potential	
Malignant papillary tumours	Papillary carcinoma, low grade
	Papillary carcinoma, high grade
	Papillary carcinoma with squamous or glandular differentiation
Malignant non-papillary tumours	
Flat carcinoma in situ	
Invasive carcinoma	Variants of invasive carcinoma (Nested pattern, micropapillary, plasmacytoid, etc)
Squamous cell carcinoma	
Adenocarcinoma	
Undifferentiated carcinomas	

Modified from Amin MB [10] and Eble JN et al. [11].

ing system has been replaced by a new system including only low grade and high grade carcinomas, plus a very low grade malignancy called papillary urothelial neoplasm of low malignant potential. Tumours are also classified by growth patterns: papillary (70%), sessile or mixed (20%), and nodular (10%). CIS is a flat, noninvasive, high-grade urothelial carcinoma. There is a higher incidence of atypical hyperplasia/dysplasia and CIS in patients with higher histological grade tumours and deeper infiltration of the urinary bladder wall, i.e. higher pathological stage [14].

## **Staging**

Several staging systems have been introduced over the last 50 years [9]. The most prevalent staging system currently used is the system adopted by the WHO and based on the TNM (tumour, lymph node, and metastasis). This staging system has been discussed in detail by Lopez-Beltran [8] and is presented in Table 2. It has been repeatedly shown that this staging system provides the best guidance for clinical treatment of urinary bladder tumours and correlates well with the prognosis of these tumours. It also offers a solid basis for comparison of various prospective and retrospective studies dealing with the new treatment modalities.

Even though staging provides the most important prognostic information for each individual urinary bladder cancer case, histopathologic data must be taken into consideration as well. The common forms of urothelial cancer will be presented in other papers and we will limit our presentation to some of the less common histological tumour variant and some recently identified forms of bladder cancer.

## **UNCOMMON VARIANTS OF UROTHELIAL CARCINOMA**

Most urinary bladder tumours belong to the groups of typical urothelial neoplasms which are usually papillary or flat [11]. These tumours will be discussed in greater detail in other papers, and thus we will not deal with them here. Suffice to say that these lesions have been studied in great detail and that the WHO has tried to introduce new systems of classifying urothelial lesion to enable more comparative international studies and better understanding between pathologists, urologists and oncologists. Furthermore several patterns of growth that have been recognized, point to the need of more precise diagnosis of these more aggressive variants [10]. Here we shall briefly describe some of these variants.

### **Micropapillary variant of urothelial carcinoma**

This uncommon histological variant of urothelial carcinoma accounts for 0.5% to 1% of all tumours, and shows a male predominance in excess to that noticed in classical urothelial carcinoma [10]. The tumour cells are arranged

**Table 2.** TNM Staging System of Urinary Bladder Cancers Recommended by the World Health Organization 2004

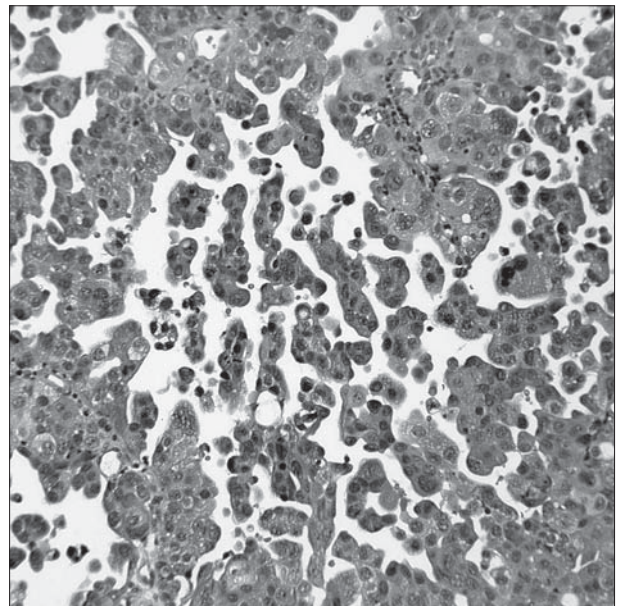
T (primary tumour)	T0	No evidence of primary tumour
	Ta	Papillary noninvasive carcinoma
	Tis	Carcinoma in situ (flat lesion)
	T1	Tumour invades the subepithelial connective tissue of the submucosa
	T2	Tumour invades the muscularis propria (muscle layer of the bladder)
	T2a	Tumour invades the muscle layer superficially (inner half)
	T2b	Tumour invades deeply into the muscle (outer half)
	T3	Tumour invades perivesical tissue
	T3a	Microscopically
	T3b	Macroscopically visible mass outside the bladder
	T4	Tumour has spread beyond the urinary bladder and invades any of the following: prostate, vagina, uterus, pelvic wall or abdominal wall
	T4a	Tumour invades prostate or uterus or vagina
	T4b	Tumour invades pelvic or abdominal wall
N (regional lymph nodes)	Nx	Lymph nodes cannot be assessed
	N0	No regional metastases
	N1	Metastases to a single lymph node 2 cm or less in diameter
	N2	Metastases in a single lymph node, more than 2 cm but not more than 5 cm in greatest dimension, or multiple lymph nodes none more than 5 cm in greatest diameter
	N3	Metastases in lymph node more than 5 cm in greatest diameter
M (distant metastase)	Mx	Distant metastases cannot be assessed
	M0	No distant metastases
	M1	Distant metastases

Modified from Lopez-Bertran A and Cheng L [8] and Eble JN et al. [11]

into small papillae that can be seen in the noninvasive as well as the invasive portion of the neoplasm and in the metastatic sites (Figure 1). The micropapillary component may be admixed to the typical urothelial carcinoma and its extent may vary from 10 to 90% of the entire tumour mass. For the pathologist it is important to quantify the extent of the micropapillary component, since it carries a worse prognosis than the usual urothelial growth pattern.

### Nested variant of urothelial carcinoma

This rare form of bladder cancer is often undiagnosed during routine pathology examination and thus it is difficult to assess its true incidence because it may occur in a pure form or be admixed to classical urothelial carcinoma [15]. Histologically, nested urothelial carcinoma has a deceptively bland appearance resembling von Brunn's nests. The nests may be discrete or focally confluent, cord-like, tubular or resembling cystitis cystica. The tumour must be distinguished from benign reactive bladder lesions. The diagnosis is made by recognizing the irregular epithelial-stromal interface indicative of the invasive nature of the tumour. The deceptively innocuous appearance of the epithelial nests is confounded by the fact that the adjacent stroma is only focally desmoplastic and myxoid. In the largest series of these tumours, reported so far by Wasco et al. [15], two thirds of studied tumours also contained foci of usual urothelial carcinoma. Hence the pure forms of nested urothelial carcinoma appear to be quite uncommon. These invasive tumours have the same clinical outcome as the common variants of invasive urothelial carcinoma.



**Figure 1.** Micropapillary carcinoma. The tumour cells form small papillae projecting into the lumen (Hematoxylin and eosin,  $\times 160$ ).

### Lymphoepithelioma-like urothelial carcinoma

These rare tumours resemble the undifferentiated nasopharyngeal carcinomas composed of epithelial cells intermixed with numerous lymphocytes. The epithelial cells arranged into syncytial-like sheets have large vesicular cells, prominent nucleoli and show brisk mitotic activity. Lymphoepithelioma-like carcinomas may be pure but in approximately 50% of reported cases also contain elements of classical urothelial carcinoma. Some tumours may contain foci of

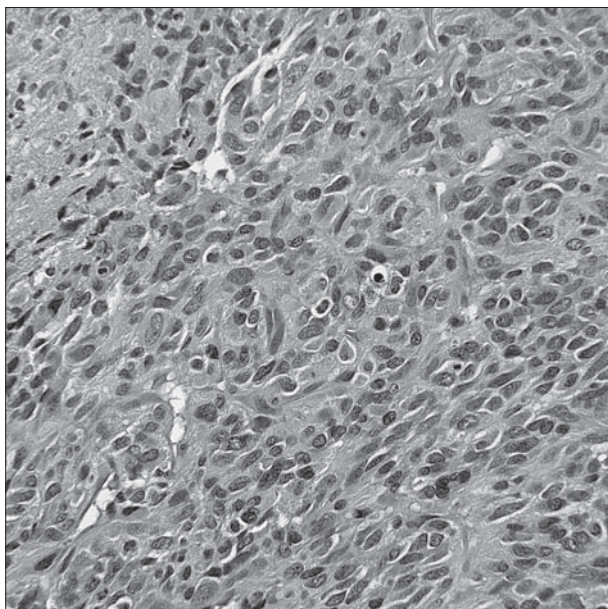
adenocarcinoma or flat carcinoma in situ [11]. It is important to be aware of this histological tumour type and not confuse it with chronic cystitis [10]. In contrast to lymphoepitheliomas of the upper aero-digestive tract, urothelial tumours of this type do not contain the Epstein-Barr virus [10]. These tumours have the same clinical prognosis as the classical invasive urothelial carcinomas.

### Sarcomatoid urothelial carcinoma

Sarcomatoid carcinomas account for approximately 0.6% of all bladder cancers [10, 11]. These tumours are composed of anaplastic spindle-shaped cells forming bundles (Figure 2). Most tumours contain carcinomatous and sarcomatous components and accordingly such tumours were previously called carcinosarcomas. However, the experts of the WHO have in 2004 recommended that these tumours be classified as sarcomatoid carcinomas, in which the sarcomatous component is nothing but the anaplastic spindle cell part of the tumour. Molecular biology data indicate that the carcinomatous and sarcomatous components are interrelated and derived from the same malignant clone. These tumours are highly malignant and have poor prognosis, and tend to metastasize widely [16].

### Plasmacytoid urothelial carcinoma

Urothelial carcinomas composed of dissociated cells resembling plasma cells have been recognized by the experts of the WHO as a well defined variant under the name of plasmacytoid carcinoma [10, 11]. These plasmacytoid tumor cells may be arranged into solid nests or alveoli, but most often they grow in form of cords of dissociated single cells invading the wall of the bladder (Figure 3). The tumour



**Figure 2.** Sarcomatoid carcinoma. The tumour is composed of anaplastic spindle cells densely compacted into bundles (Hematoxylin and eosin,  $\times 160$ ).

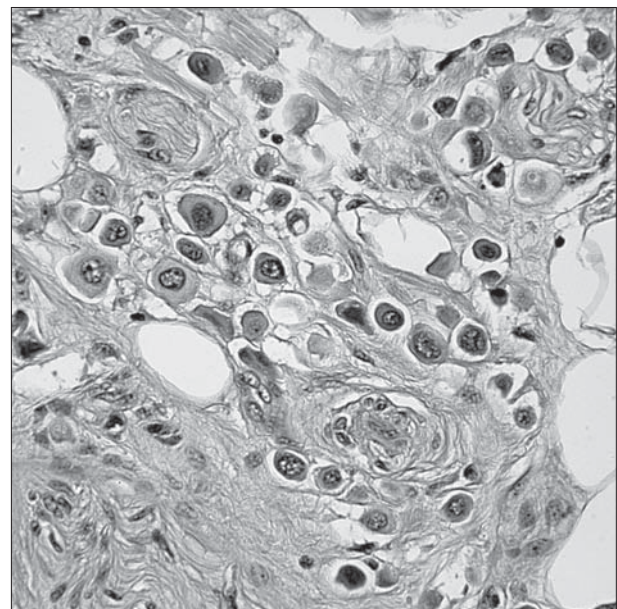
cells have an eccentrically placed nucleus round or irregularly shaped nucleus and eosinophilic cytoplasm thus resembling plasma cells. These cells are, however, epithelial as shown by their immunohistochemical reactivity with the antibodies to cytokeratins CK7 and CK20 [17]. The plasmacytoid component may predominate or form only a smaller part of the tumour. There are no generally accepted criteria for calling the tumour plasmacytoid urothelial carcinoma. In a recent study by Lopez-Beltran et al [17] some tumours contained as few as 30% of plasmacytoid cells, but some tumours were composed almost exclusively of plasmacytoid cells.

### Pleomorphic giant cell urothelial carcinoma

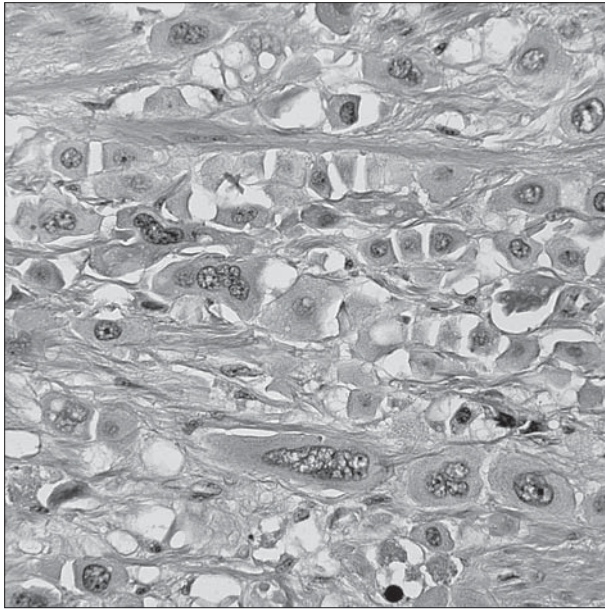
This very rare type of carcinoma is composed of giant, anaplastic and bizarre multinucleated cells (Figure 4). The giant cells account for 20% to 100% of all tumour cells [18]. These tumours form nests or infiltrate the muscle wall of the bladder in form of cords or individual cells. Conventional urothelial carcinoma or papillary carcinoma may be found adjacent to the giant cells. Most tumours have metastases at the time of diagnosis and overall these tumours have a very poor prognosis. Immunohistochemical and ultrastructural studies are of limited value in further characterizing these tumours [18, 19].

### Squamous cell carcinoma

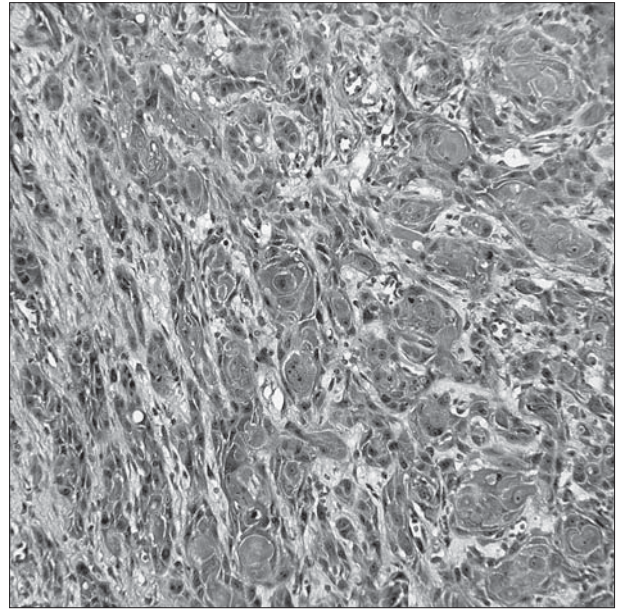
Squamous cell carcinomas (SCC) of the urinary bladder are usually poorly differentiated tumours resembling squamous cell carcinomas in other sites (Figure 5). In typical cases SCC forms after many years of chronic infection or irritation such as cystitis related to urinary stones [11].



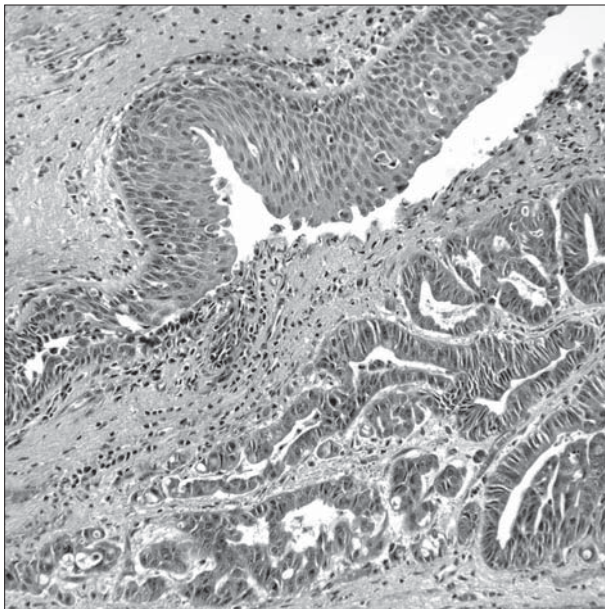
**Figure 3.** Plasmacytoid carcinoma. The tumour is composed of dispersed single cells that have round or oval nuclei surrounded with dense cytoplasm, resembling neoplastic plasma cells (Hematoxylin and eosin,  $\times 220$ ).



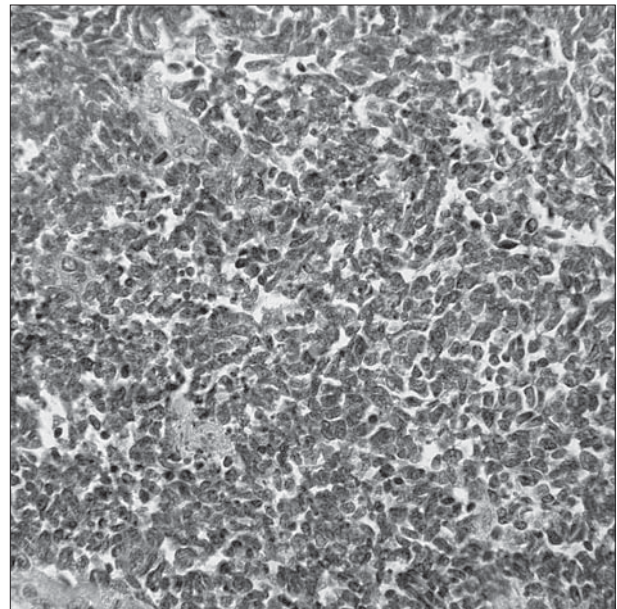
**Figure 4.** Giant cell carcinoma. The tumour is composed of anaplastic large cells many of which are multinucleated (Hematoxylin and eosin,  $\times 220$ ).



**Figure 5.** Squamous cell carcinoma. The tumour is composed of squamous cells interconnected one with another with intercellular bridges ( $\times 160$ ).



**Figure 6.** Adenocarcinoma. Adenocarcinoma, composed of atypical gland like structures in the lower part of the figure is juxtaposed to normal urothelium of the bladder in the upper part of the figure (Hematoxylin and eosin,  $\times 160$ ).



**Figure 7.** Small cell carcinoma. The tumour is composed of densely packed small cells with oval nuclei and scant cytoplasm (Hematoxylin and eosin,  $\times 220$ ).

By the time squamous cell bladder cancer is detected it is usually in an advanced stage. Although this is the second most common histopathological form of bladder cancer, it only accounts for less than 5% of all cases in industrialized countries. SCC bladder cancer is more often found in tropical climates and is mostly associated with bilharzial parasites primarily *Schistosoma haematobium* [19]. Bilharzial bladder cancer is the most common form of cancer found in adult males in Egypt, due to the prevalence of bilharzial infestation in the countryside. These tumours have a tendency to invade into muscle layer but in contrast to invasive tumours in the Western countries they less commonly metastasize to lymph nodes. Metasta-

ses to distant sites are also less common and among those bone metastases stand out.

Squamous metaplasia may be found in aggressive invasive urothelial carcinomas of the bladder in Europe and America. The term squamous cell carcinoma is reserved, however, for tumours composed exclusively of squamous cells. These non-bilharzial squamous cell carcinomas are rare, and a recent retrospective review of the material from MD Anderson Hospital in Houston Texas, revealed only 16 cases in a period of approximately 15 years [20]. Most cases (75%) presented as advanced stage cancers. Like bilharzial squamous cell carcinomas from Egypt, these squamous cell carcinomas were less often accompanied by metasta-

ses than usual urothelial carcinomas. Anecdotal evidence suggest that cystectomy might be beneficial, but the statistical stage-by-stage comparison of squamous and urothelial cancers in that Houston series did not reveal any significant differences in the patients' survival.

### Adenocarcinoma of the bladder

Approximately 2% of all bladder cancers are microscopically classified as adenocarcinomas [21-22]. These tumours are composed of cuboidal or columnar cells forming glands (Figure 6). Bladder adenocarcinomas can be grouped into one of three categories:

- Primary vesical tumours: these tumours originate from metaplastic glands formed from the invaginated urothelium and the nests of von Brunn in cystitis glandularis;
- Urachal tumours: these tumours originate from the epithelium lining remnants of the urachus at the bladder dome;
- Metastatic adenocarcinomas: these tumours can originate from primaries in many organs. The most common metastatic adenocarcinomas are derived from primaries in the prostate, ovary or colon.

The primary bladder adenocarcinomas form approximately two thirds of all glandular primary bladder tumours. Urachal adenocarcinomas account thus for 0.35% to 0.7% of all urinary bladder cancers [21]. Several subtypes of adenocarcinoma have been identified such as clear cell, villoglandular, or mucinous variants [20-23]. Despite the differences in the histology the stage of the tumour is the most powerful predictor of outcome.

Most glandular tumours of the bladder are highly malignant tumours but some urachal tumours may be

benign or show a borderline malignant phenotype. Likewise some adenocarcinomas originating in cystitis glandularis may be diagnosed in the preinvasive stage [24]. Adenocarcinomas should not be confused with urothelial carcinoma showing mucoid changes in the stroma [25], or benign glandular lesions that may present as exophytic polypoid tumors [26].

### Neuroendocrine tumours

Neuroendocrine tumours of the urinary bladder account for less than 1% of all bladder tumours. They can be classified as carcinoids, small cell carcinomas, or large cell neuroendocrine carcinomas [27-30]. Most of the reported cases belong to the category of small cell carcinomas, indistinguishable from the bronchial tumours of the same name (Figure 7). Metastases can be detected at the initial evaluation, although in some instances they occur later in the course of the disease.

### CONCLUSION

Even though urinary bladder cancers present in most instances as urothelial carcinoma several variants have been described lately. These histological variants have been reviewed here. The study of uncommon forms of bladder cancer could provide new data about the biology and pathogenesis of bladder cancer and advance our understanding of neoplasia in this organ. Furthermore it is important to be aware of these new clinical-pathological entities because with time one could expect that such tumours will require special treatment.

### REFERENCES

1. Jemal A, Siegel R, Ward E, Hao Y, Xu J, Thun MJ. Cancer statistics, 2009. *CA Cancer J Clin.* 2009; 59:225-49.
2. Todorov V, Maksimova S, Hristova V. Karcinom mokraćne bežike i krvne grupe. *Journal of the Anthropological Society of Serbia.* 2008; 43:72-4.
3. Živković S, Veličković Lj, Tasić-Dimov D, Rostov M, Stojanović N. Tumori mokraćne besike kod mladih ljudi. *Vojnosanit Pregl.* 2003; 60:621-4.
4. Cheng L, Montironi R, Davidson DD, Lopez-Beltran A. Staging and reporting of urothelial carcinoma of the urinary bladder. *Mod Pathol.* 2009; 22(Suppl 2):S70-95.
5. Damjanov I. Teaching of pathology at more than one level. *Hum Pathol.* 2005; 36:135-8.
6. Mitra AP, Cote RJ. Molecular pathogenesis and diagnostics of bladder cancer. *Annu Rev Pathol.* 2009; 4:251-85.
7. Lopez-Beltran A, Cheng L. Histologic variants of urothelial carcinoma: differential diagnosis and clinical implications. *Hum Pathol.* 2006; 37:1371-88.
8. Marković N, Ignjatović I, Cukuranović R, Petrović B, Kocić B, Stefanović V. Decreasing incidence of urothelial cancer in a Balkan endemic nephropathy region in Serbia. A surgery based study from 1969 to 1998. *Pathol Biol (Paris).* 2005; 53:26-9.
9. Tavora F, Epstein JI. Bladder cancer, pathological classification and staging. *BJU Int.* 2008; 102:1216-20.
10. Amin MB. Histological variants of urothelial carcinoma: diagnostic, therapeutic and prognostic implications. *Mod Pathol.* 2009; 22(Suppl 2):S96-118.
11. Eble JN, Sauter G, Epstein JI, Sesterhenn IAE. *World Health Organization classification of tumours: pathology and genetic of tumours of the urinary system and male genital organs.* Lyon: IARC Press; 2004.
12. Grignon DJ. The current classification of urothelial neoplasms. *Mod Pathol.* 2009; 22(Suppl 2):S60-69.
13. Damjanov I, Fan F, editors. *Cancer Grading Manual.* New York: Springer; 2007.
14. Veličković Lj, Dimov D, Kutlešić Č, Katić V, Tasić D, Marjanović D. Premalignant lesions of urinary bladder mucosae. *Facta universitatis, Series: Medicine and Biology.* 1998; 5(1):33-6.
15. Wasco MJ, Daignault S, Bradley D, Shah RB. Nested variant of urothelial carcinoma: a clinicopathologic and immunohistochemical study of 30 pure and mixed cases. *Hum Pathol.* 2009; 40:1382-9.
16. Langenstroer P, Romanas M, Damjanov I. Clitoromegaly caused by metastatic carcinosarcoma of the urinary bladder. *Arch Pathol Lab Med.* 2003; 127:505.
17. Lopez-Beltran A, Requena MJ, Montironi R, Blanca A, Cheng L. Plasmacytoid urothelial carcinoma of the bladder. *Hum Pathol.* 2009; 40:1023-8.
18. Lopez-Beltran A, Blanca A, Montironi R, Cheng L, Requero JC. Pleomorphic giant cell carcinoma of the urinary bladder. *Hum Pathol.* 2009; 40:1461-6.
19. Damjanov I, Tuma B, Dominis M. Electron microscopy of large cell undifferentiated and giant cell tumors. *Pathol Res Pract.* 1989; 184:137-60.
20. Guo CC, Gomez E, Tamboli O, Bondaruk JE, Kamat A, Bassett R, et al. Squamous cell carcinoma of the urinary bladder: a

- clinicopathologic and immunohistochemical study of 16 cases. *Hum Pathol.* 2009; 40:1448-52.
21. Grignon DJ, Ro JY, Ayala AG, Johnson DE, Ordóñez NG. Primary adenocarcinoma of the urinary bladder. A clinicopathologic analysis of 72 cases. *Cancer.* 1991; 67:2165-72.
  22. Lim M, Adsay NV, Grignon D, Osunkoya AO. Urothelial carcinoma with villoglandular differentiation: a study of 14 cases. *Mod Pathol.* 2009; 22:1280-6.
  23. Adeniran AJ, Tamboli P. Clear cell adenocarcinoma of the urinary bladder: a short review. *Arch Pathol Lab Med.* 2009; 133:987-91.
  24. Gopalan A, Sharp DS, Fine SW, Tickoo SK, Herr HW, Reuter VE, et al. Urachal carcinoma: a clinicopathologic analysis of 24 cases with outcome correlation. *Am J Surg Pathol.* 2009; 33:659-68.
  25. Miller JS, Epstein JI. Noninvasive urothelial carcinoma of the bladder with glandular differentiation: report of 24 cases. *Am J Surg Pathol.* 2009; 33:1241-8.
  26. Rubin J, Khanna OP, Damjanov I. Adenomatous polyp of the bladder: a rare cause of hematuria in young men. *J Urol.* 1981; 126:549-50.
  27. Akamatsu S, Kanamaru S, Ishihara M, Sano T, Soeda A, Hashimoto K. Primary large cell neuroendocrine carcinoma of the urinary bladder. *Int J Urol.* 2008; 15:1080-3.
  28. Ismaili N, Ghanem S, Mellas N, Afgir S, Taleb M, Amrani M, et al. Small cell carcinoma of the urinary bladder: a case report and review of the literature. *J Cancer Res Ther.* 2009; 5:133-6.
  29. Mukesh M, Cook N, Hollingdale AE, Ainsworth NL, Russell SG. Small cell carcinoma of the urinary bladder: a 15-year retrospective review of treatment and survival in the Anglian Cancer Network. *BJU Int.* 2009; 103:747-52.
  30. Mazzucchelli R, Morichetti D, Lopez-Beltran A, Cheng L, Scarpelli M, Kirkali Z, et al. Neuroendocrine tumours of the urinary system and male genital organs: clinical significance. *BJU Int.* 2009; 103:1464-70.

## Хистологија рака мокраћне бешике: мање чести облици

Иван Дамјанов<sup>1</sup>, Милета Голубовић<sup>2</sup>

<sup>1</sup>Одељење за патологију, Медицински факултет, Универзитет у Канзасу, Канзас Сити, Канзас, САД;

<sup>2</sup>Центар за патологију, Медицински факултет, Клинички центар Црне Горе, Подгорица, Црна Гора

### КРАТАК САДРЖАЈ

Карцином мокраћне бешике припада групи веома честих неоплазми. Хистолошки облик који се најчешћа јавља код овог тумора је уротелни (транзициоцелуларни) карцином. У овом раду разматрају се најновије публикације које обрађују ретке варијанте уротелног карцинома с необичним облицима диференцијације. Такође се бавимо туморима који показују познатије обрасце диференцијације, као што су: сквамозна, glandуларна и саркоматоидна. Уротелни тумори могу показивати различите видове раста: гнездаст, микропапи-

ларан, сличан лимфоепителиому или плазмоцитоидан, односно крупноћелијски. Клинички ток различитих карцинома мокраћне бешике зависи од хистолошког типа неоплазме, градуса и стадијума тумора. Уротелни карциноми високог градуса с инвазијом у мишићни слој и тумори променљиве микроскопске морфологије носе већи степен морталитета и лошу прогнозу.

**Кључне речи:** мокраћна бешика; уротелни карцином; патологија

Примљен • Received: 05/02/2010

Ревизија • Revision: 06/06/2011

Прихваћен • Accepted: 19/07/2011