

# Laparoscopic Body-Tail Pancreatic Resection for Insulinoma

Radovan Cvijanović<sup>1</sup>, Dejan Ivanov<sup>1</sup>, Milena Mitrović<sup>2</sup>, Matilda Djolai<sup>3</sup>, Dejan Petrović<sup>1</sup>, Olivera Tešić<sup>4</sup>

<sup>1</sup>Department of Abdominal, Endocrine and Transplantation Surgery, Clinical Centre of Vojvodina, Novi Sad, Serbia;

<sup>2</sup>Department of Endocrinology, Diabetes and Metabolism Diseases, Clinical Centre of Vojvodina, Novi Sad, Serbia;

<sup>3</sup>Department of Pathology and Histology, Clinical Centre of Vojvodina, Novi Sad, Serbia;

<sup>4</sup>Radiotherapy Department, Oncology Institute of Vojvodina, Novi Sad, Serbia

## SUMMARY

**Introduction** Insulinomas are the most common endocrine tumours of the pancreas. They are more frequent in females, and they are commonly less than 2 cm in diameter. If conservative treatment of typical clinical symptoms fails, detailed diagnostic procedures are necessary and surgical treatment is indicated. The aim of this report was to emphasize the need of pancreatic resection when insulinoma is poorly visualized during surgery and when it is not possible to perform intraoperative ultrasonography.

**Case Outline** A 27-year-old female patient suffered from hypoglycaemic episodes during physical efforts and fasting periods. After examination, diagnostic procedures and preoperative preparation, laparoscopic surgery was performed. The tumour was less than 10 mm in diameter, and it could not be visualized during laparoscopic exploration. The body and the tail of the pancreas were mobilized using ultrasound scissors and the resection was performed by two Endo GIA staplers. The surgical specimen was removed in an endo-bag. The postoperative course was without complications and the glycemic level was normalized. Macroscopic examination of the resected specimen showed a solitary, poorly demarcated, dark grey lesion, 0.8 cm in diameter, with a solid consistence in comparison with the surrounding gland tissue. Histological examination showed a poorly demarcated, subcapsular tissue in this area, consisting of uniform, irregular, cubic and short cylindrical cells, organized in clusters with pseudo-glandular and "zellballen" formations.

**Conclusion** In case when the insulinoma is so small in size that it cannot be visualized during operation, pancreas resection is a surgical procedure of choice. Laparoscopic surgery is preferred because of less postoperative complications and faster recovery.

**Keywords:** insulinoma; laparoscopic surgery; hypoglycaemic coma

## INTRODUCTION

Paul Langerhans, a pathologist, published his thesis in 1869 and described endocrine pancreas, while in 1926, Dr. W. J. Mayo performed the first surgery for insulinoma [1]. Insulinomas are the most common endocrine tumours of the pancreas, and they are more frequent in females. Usually they are small-sized, and in about 90% of cases they are under 2 cm in diameter, but they may be multiple, especially when they occur in the scope of multiple endocrine neoplasia type 1 syndrome (MEN 1). Large insulinomas are more likely to be malignant, while the presence of metastatic malignancy and infiltration into the surrounding tissue are evidence of their malignancy. The tumours are well-vascularized, whereas their hormonal activity is not proportional to their size [2, 3].

The diagnosis of insulinoma is based on clinical signs and development of hypoglycaemic episodes after fasting or physical activity. By using standard procedures, such as ultrasonography (US), computerized tomography

(CT), and magnetic resonance (MR), it is pre-operatively possible to localize about 85% of insulinomas [4, 5]. Selective angiography and endoscopic ultrasonography provide even better chances for localization. A very effective method for tumour localization is vein catheterization and assessment of hormone concentration within them, but the procedure is complex and generally used only in cases when the tumour has not been localized [6].

Indications for insulinoma surgery are made after detailed examination of clinical signs and symptoms, establishing the diagnosis, and failure of conservative treatment. The surgery may be done by enucleation, distal pancreatectomy, or by duodenopancreatectomy. Laparoscopic approach provides easy visualization of the pancreas and of large tumours [7]. The postoperative course is much easier and the recovery significantly shorter than in standard laparotomy.

Aim of this report was to emphasize the need of pancreatic resection when insulinoma is poorly visualized during surgery and when it is not possible to perform intraoperative ultrasonography.

## Correspondence to:

Radovan CVIJANOVIĆ  
Department of Abdominal,  
Endocrine and Transplantation  
Surgery  
Clinical Centre of Vojvodina  
Hajduk-Veljkova 1-3  
21000 Novi Sad, Serbia  
rcvijanovic@yahoo.com

## CASE REPORT

A 23-year-old female patient was admitted to the Clinic of Infectious Diseases in Novi Sad due to acute gastroenteritis and fever. During hospitalization, the patient presented with coma, hypoglycaemia (1.9 mmol/l), and an endocrinologist was consulted for further diagnosis. Anamnestic data revealed that the patient showed symptoms of hypoglycaemia in the last two years. On several occasions, the ambulance was called for emergency help, and after receiving concentrated carbohydrates or intravenous hypertonic glucose, the symptoms disappeared.

Further investigation was performed at the Endocrinology Clinic in Novi Sad. On several occasions fasting hypoglycaemia was registered, as well as episodes of hypoglycaemia during the day, with high values of insulinemia (IRI), C-peptides, and pathological values of the glycaemic index (IRI/glycaemic ratio). The patient underwent further examinations, and as other causes of the hypoglycaemic syndrome were excluded, the diagnosis of multiple endocrine neoplasia (MEN) was made. After toxicological analysis, oral hypoglycaemic agents, from the group of sulphonylurea were discontinued. A 72-hour fasting test was planned, but it was terminated after a few hours, due to clinical symptoms of hypoglycaemia, whereas the laboratory measured glycaemic value was 1.7 mmol/l. After the diagnosis was biochemically confirmed, morphological diagnosis was made using US, CT and MR of the abdomen. However, no clear localization of the lesion was obtained.

Considering a clear clinical picture and biochemical confirmation, our patient was referred for further morphological diagnosis to the Military Medical Academy in Belgrade. She underwent endoscopic US of the abdomen and a 7×10 mm pancreatic tail lesion was revealed. After that, arterial Ca stimulation venous sampling (ASVS) method was performed. Arterial stimulation was done using 0.021 mEq of Ca per kg of body weight through the proximal and distal splenic artery, gastroduodenal, and superior mesenteric arteries. After stimulation through the proximal and distal splenic arteries, maximum peaks of insulinemia were 8.42 and 2.7 folds, while stimulation through gastroduodenal and superior mesenteric arteries did not induce increase in the concentration of insulin higher than 2 fold. This finding showed that insulinoma was localized in the tail of the pancreas.

The laparoscopic surgery started by creating a pneumoperitoneum of 12 mm Hg through an incision of the skin above the umbilical level. An 11 mm optical trocar was placed into the abdomen for exploration, but no pathological changes were found. Additional 11 mm trocars were placed in the midclavicular line, subcostally to the right, and in the axillary line to the left at the umbilical level. One 5 mm trocar was placed in the anterior axillary line to the right at the umbilical level for aspiration. The hepatic flexure of the colon was mobilized and the gastro-colonic ligament was opened using ultrasonic scissors, which were further used for preparation. The anterior part of the pancreas was visualized, but the lesion could not be seen, due to its size of 7-10 mm. The anterior edge of the pancre-

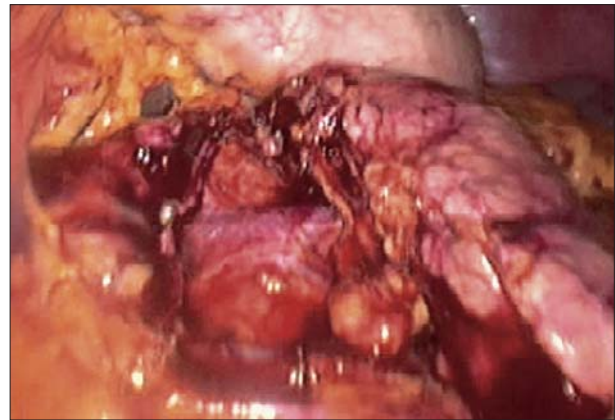

Figure 1. Transection of the pancreas

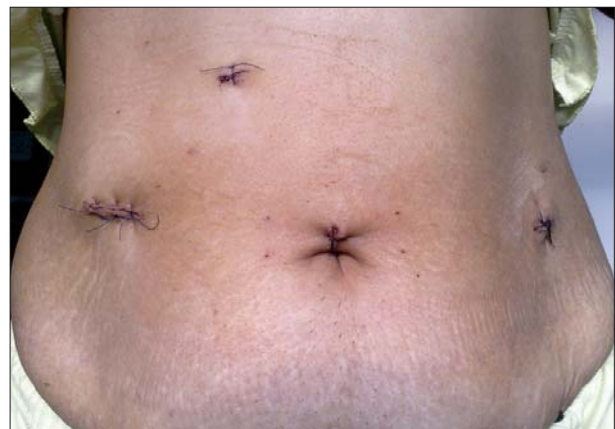

Figure 2. Drains removed

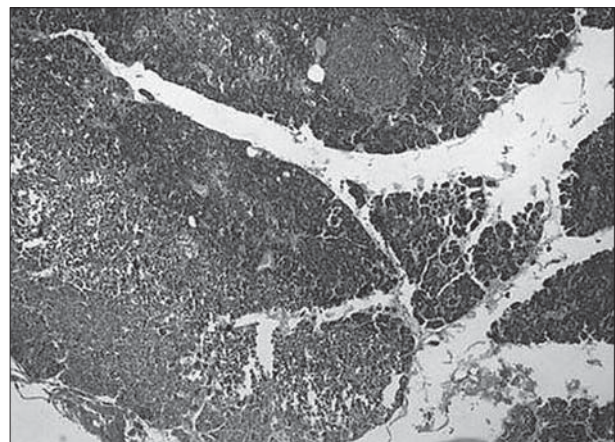


Figure 3. Tumorous tissue with the surrounding exocrine pancreas and enlarged islets of Langerhans (PAS, ×5)

atic tail and body were exposed and the inferior side was approached. Dissection of the hepatic vein was performed using US scissors, in order to move to the superior edge of the pancreas at the neck level. Then, dissection was continued to the spleen, which remained in situ. After the body and the tail were completely dissected (Figure 1), pancreatic resection was performed at the neck level using two Endo-GIA staplers. Minimal bleeding from the resection margin was controlled by US scissors. The resected segment was put into a plastic bag and pulled out through a small incision. Drains were placed locally and into the Douglas

creek. The postoperative course was uneventful and intestinal peristalsis was maintained. The patient started taking fluids the next day, and after that food as well. Drains were removed as well as the remaining sutures (Figure 2).

During the postoperative period, no hypoglycaemic episodes were noted, but expected hyperglycaemia was recorded. It was the consequence of contra-insulin hormones production, but also of long-term pancreatic beta-cells suppression by excessive tumour cells insulin production.

The removed tissue included pancreatic tissue with the surrounding fatty tissue and marked resection edge of 10×4×1.5 cm in size. On the junction of the anterior two thirds and the posterior third of the resected tissue, an unclearly marked dark-grey area was found, 0.8 cm in diameter, somewhat harder in consistency than the surrounding gland tissue (Figure 3).

Within the histopathologically analyzed section of the described area, a relatively unclearly marked, subcapsular tissue was found, consisting of uniform, irregular, cubic and low cylindrical cells arranged in stripes, of pseudo-glandular and "zellballen" pattern. Mitoses were not found in the examined cells. A fine, connective stroma was found among the cells. Between the described field and the exogenous pancreas, a border, consisting of degenerated cells of the exocrine pancreas, was identified.

## DISCUSSION

Treatment of rare benign pancreatic insulinomas is surgical. Good treatment outcome is achieved in 90% of patients [7]. Surgical procedures used in the treatment of pancreatic insulinomas include resection surgeries, whereas depending on the localization, size and morphological characteristics of the tumour, enucleation or pancreatic resection (for example distal pancreatectomy) are performed. Enucleation is performed for solitary insulinomas, well-encapsulated, under 4 mm in diameter, and distant from the main pancreatic duct [8].

Laparotomy provides good visualization of the pancreas, so most insulinomas are easily identified either directly, by inspection, as pinkish-brown areas, or indirectly, by palpation, being firmer in consistency than the surrounding tissue. Intraoperative US exploration provides 100% diagnosis of insulinomas. The sensitivity of intraoperative ultrasonography in localizing insulinomas is 88% [9]. Pancreatic ultrasonography during surgery identifies the distance between the insulinoma and the main pancreatic duct, and it is easier to decide whether to perform laparoscopic enucleation or pancreatic resection. However, ultrasonography is most important in laparoscopic surgery of pancreatic insulinomas, because in this surgical procedure palpation is not possible. This diagnostic method requires special equipment, and in cases when it is not at disposal, one should focus on precise preoperative localization of insulinomas within the pancreas.

When the diagnosis of hormonally active insulinoma is established based on clinical picture and biochemical tests,

the localization of insulinoma within the pancreatic tissue is performed by US, CT, MR, selective angiography, somatostatin receptor scintigraphy and trans-gastric endoscopic ultrasound [10]. If the localization of insulinoma is not identified by the above-mentioned techniques, Doppman, the arterial stimulation venous sampling (ASVS) method is used. ASVS is the most sensitive method in preoperative localization of insulinomas with accuracy of 88-100% [11, 12]. The test includes catheter positioning through the femoral artery into the gastroduodenal, superior mesenteric and splenic arteries. Calcium gluconate (0.025 mEq/kg) is injected directly into the branches, and venous blood samples are obtained from the right hepatic vein. Two-fold increase in the insulin level in the sample taken from the right hepatic vein represents a positive test finding [11].

Considering the fact that intraoperative ultrasonography in laparoscopic surgery, the most sensitive method in localization of insulinomas, is not available to us at this time, we are forced to perform ASVS preoperatively. A positive finding of this test, without accurate preoperative localization of insulinomas by other diagnostic techniques, is the only indication to perform "blind" resection of the pancreas, especially by laparoscopy [13]. Despite the fact that the tumour was under 4 cm in diameter, pancreatic resection was our surgical treatment of choice, because we had no data about its localization in regard to the main pancreatic duct [8].

Exact localization of the insulinoma in laparoscopic surgery is of great importance, not only because palpation is not possible, but also because of the surgical technique, that is positioning the patient for surgical procedure on the OR table and placement of trocars.

Better cosmetic results, less postoperative pain, shorter hospital stay, faster recovery and return to normal life activities, are advantages of all laparoscopic surgeries, which encouraged us to choose this surgical procedure [14, 15]. Pancreatic surgery belongs to the group of the most demanding operative procedures in abdominal surgery with numerous respiratory complications (atelectasis and pneumonia), so faster recovery and fewer respiratory disorders established in cholecystectomies [16] were among reasons to choose laparoscopic surgical approach in our patient.

In 1995, Gagner and associates performed distal pancreatectomies for insulinoma using an endoscopic linear stapler [17]. Distal laparoscopic pancreatectomies, with preservation of the spleen, last from 2.5 to 5 hours [8, 10, 17], and it was the time we needed to perform the surgery.

Morbidity of laparoscopic surgery is comparable to the open method [14], whereas pancreatic fistula is the most common and most important postoperative complication.

Histopathological analysis after surgery is of utmost importance, but uneventful postoperative course is much more important for patients, so that is why they stay in the hospital for some time under medical supervision of internists-endocrinologists.

In case when the insulinoma is so small in size that it cannot be visualized during operation, pancreas resection is a surgical procedure of choice. Laparoscopic surgery is preferred because of less postoperative complications and

faster recovery. Laparoscopic pancreatic resection for insulinoma is performed safely, with spleen and splenic blood

vessels preservation, whereas fast postoperative recovery is a great advantage of this surgical procedure.

## REFERENCES

- Janković R. Neuroendokrini tumori pankreasa i duodenuma. In: Čolović R. Hirurgija pankreasa. Beograd: Zavod za udžbenike i nastavna sredstva; 1998. p.221-45.
- Chetty R. Neuroendocrine tumours of the pancreas. In: Kahn A. Surgical Pathology of Endocrine and Neuroendocrine Tumours. 1st ed. New York: Human Press; 2009. p.143-53.
- Klimastra DS, Modlin IR, Copola D, Lloyd R, Suster S. Pathological classification of neuroendocrine tumours. *Pancreas*. 2010; 39:707-12.
- Ahrendt SA, Komorowski RA, Demeure MJ, Wilson SD, Pitt HA. Cystic pancreatic neuroendocrine tumours: Is preoperative diagnosis possible? *J Gastrointest Surg*. 2002; 6:66-74.
- Tamagno G, Maffei P, Pasquali C, De Carlo E, Martini C, Mioni R, et al. Clinical and diagnostic aspects of cystic insulinoma. *Scand J Gastroenterol*. 2005; 40:1497-501.
- Miller DL. Endocrine angiography and venous sampling. *Radiol Clin North Am*. 1993; 31:1051-67.
- Kaczirek K, Asari R, Scheuba C, Niederle B. Organic hyperinsulinism and endoscopic surgery. *Wien Klin Wochenschr*. 2005; 117(1-2):19-25.
- Edwin B, Mala T, Mathisen Ø, Gladhaug I, Buanes T, Lunde OC, et al. Laparoscopic resection of the pancreas: a feasibility study of the short-term outcome. *Surg Endosc*. 2004; 18(3):407-11.
- Norton JA, Cromack DT, Shawker TH, Doppman JL, Comi R, Gorden P, et al. Intraoperative ultrasonographic localization of islet cell tumours. A prospective comparison to palpation. *Ann Surg*. 1988; 207:160-8.
- Jun CC, Seong HC, Sung HJ, Jin SH, Dong WC, Yong IK. Localization and surgical treatment of the pancreatic insulinomas. *ANZ J Surg*. 2006; 76:1051-5.
- Doppman JL, Miller DL, Chang R, Shawker TH, Gorden P, Norton JA. Insulinomas: localization with selective intraarterial injection of calcium. *Radiology*. 1991; 178:237-41.
- Brown CK, Bartlett DL, Doppman JL, Gorden P, Libutti SK, Fraker DL, et al. Intraarterial calcium stimulation and intraoperative ultrasonography in the localization and resection of insulinomas. *Surgery*. 1997; 122:1189-94.
- Park BJ, Alexander HR, Libutti SK, Huang J, Royalty D, Skarulis MC, et al. Operative management of islet-cell tumours arising in the head of the pancreas. *Surgery*. 1998; 124:1056-61.
- Karaliotas C, Sgourakis G. Laparoscopic versus open enucleation for solitary insulinoma in the body and tail of the pancreas. *J Gastrointest Surg*. 2009; 13:1869.
- Ivanov D, Cvijanović R, Majdevac S, Korica M. Naša iskustva sa laparoskopskom adrenalektomijom. *Medicina danas*. 2003; (3-4):294-7.
- Ivanov D. Komparativne vrednosti respiratornih parametara nakon holecistektomija subkostalnom laparotomijom i laparoskopski [magistarski rad]. Novi Sad: Medicinski fakultet Univerziteta u Novom Sadu; 2001.
- Burpee S, Jossart G, Gagner M. The laparoscopic approach to gastroenteropancreatic tumours. *Acta Chir Austriaca*. 1999; 31:207-13.

## Лапароскопска ресекција корпорокаудалног панкреаса због инсулинома

Радован Цвијановић<sup>1</sup>, Дејан Иванов<sup>1</sup>, Милена Митровић<sup>2</sup>, Матилда Ђолаи<sup>3</sup>, Дејан Петровић<sup>1</sup>, Оливера Тешић<sup>4</sup>

<sup>1</sup>Клиника за абдоминалну, ендокрину и трансплантациону хирургију, Клинички центар Војводине, Нови Сад, Србија;

<sup>2</sup>Клиника за ендокринологију, дијабетес и болести метаболизма, Клинички центар Војводине, Нови Сад, Србија;

<sup>3</sup>Центар за патологију и хистологију, Клинички центар Војводине, Нови Сад, Србија;

<sup>4</sup>Одељење за радиотерапију, Институт за онкологију Војводине, Нови Сад, Србија

### КРАТАК САДРЖАЈ

**Увод** Инсулином је најчешћи ендокрини тумор панкреаса с већом учесталошћу код особа женског пола. У 90% случајева пречник инсулинома је мањи од 2 *cm*. Индикација за операцију се поставља након неуспешног конзервативног лечења, типичних клиничких симптома и детаљних дијагностичких прегледа. Овим приказом желела се истаћи неопходност ресекције панкреаса када је отежано препознавање инсулинома током операције, у условима када је интраоперациона сонографија недоступна.

**Приказ болесника** Жена стара 27 година је у анамнези навела појаву хипогликемијских криза након периода гладовања и током физичког напора. Обављено је детаљно испитивање и постављена дијагноза инсулинома. Хируршки захват је извршен лапароскопски. Експлорацијом се није могао потврдити тумор чији је пречник мањи од 10 *mm*, те су ултразвучним маказима мобилисани тело и реп панкреаса, а ресекција је изведена са две *endo-GIA*. Препарат је од-

страњен ендо-кесом. Постоперациони ток је протекао без компликација, а ниво гликемије се нормализовао. У ресекцираном делу панкреаса макроскопски је уочено солитарно, нејасно ограничено, мркосивкасто поље пречника 0,8 *cm*, нешто чвршће конзистенције у односу на околно жлездано ткиво. Хистолошким прегледом се у описаном пољу налазило нејасно ограничено субкапсуларно ткиво, саграђено од униформних, неправилних коцкастих и ниско цилиндричних ћелија распоређених у траке, псеудогландуларне и тзв. *zellballen* формације.

**Закључак** Уколико је инсулином мале величине, те се не може уочити током операције, ресекција панкреаса је метода избора у хируршком лечењу. Лапароскопски приступ је пожељан због мањег броја постоперационих компликација и бржег опоравка болесника.

**Кључне речи:** инсулином; лапароскопска хирургија; хипогликемијска кома