

# Mystery Called Sarcoidosis: Forty-Four Years Follow-Up of Chronic Systemic Disease

Vesna Škodrić-Trifunović<sup>1,2</sup>, Violeta Vučinić<sup>1,2</sup>, Sanja Simić-Ogrizović<sup>1,3</sup>, Ruža Stević<sup>1,4</sup>, Mihailo Stjepanović<sup>2</sup>, Katarina Ilić<sup>5</sup>, Živorad Savić<sup>4</sup>

<sup>1</sup>School of Medicine, University of Belgrade, Belgrade, Serbia;

<sup>2</sup>Clinic for Lung Diseases, Clinical Center of Serbia, Belgrade, Serbia;

<sup>3</sup>Clinic for Nephrology, Clinical Center of Serbia, Belgrade, Serbia;

<sup>4</sup>Center for Radiology and MRI, Clinical Center of Serbia, Belgrade, Serbia;

<sup>5</sup>Department of Pharmacology, School of Pharmacy, University of Belgrade, Belgrade, Serbia

## SUMMARY

**Introduction** This is a presentation of a 61-year-old female patient. Since 44 years have passed from the onset of her first symptoms until the final diagnosis of sarcoidosis, this was the reason of our decision to publish the case.

**Case Outline** During the follow-up period of 44 years the patient had occasional polymorphic complaints, such as adynamia, nausea, abdominal pains, myalgia, arthralgia, body weight loss (8-10 kg) etc. The clinical course was predominated by splenomegaly, hepatitis and arthralgia, and later chronic renal failure also developed. Laboratory findings showed elevated markers of acute inflammation and autoantibodies. The patient was hospitalized in different university internal hospitals (gastroenterology, allergology, rheumatology, nephrology and pulmonology). Liver biopsy was performed three times, rectum and kidney biopsy once each and finally bronchoscopy and pulmonary biopsy was done. At last, about 40 years from the onset of the first symptoms, in 2006 the diagnosis of lung sarcoidosis was established.

**Conclusion** The final diagnosis of spleen sarcoidosis was confirmed by pathologically verified sarcoidosis of the lungs. This case is particularly interesting because of the presence of familial sarcoidosis (the patient's son also had recurrent pulmonary sarcoidosis).

**Keywords:** sarcoidosis; liver; spleen; lung; kidney

## INTRODUCTION

Sarcoidosis is a chronic granulomatous disease of unknown origin, with pulmonary involvement in more than 90% of patients. Sometimes sarcoidosis can be an enigmatic disease with extremely variable manifestations in pattern, severity and course [1, 2, 3]. Abdominal sarcoidosis is a rare manifestation with the involvement of the liver, spleen or kidney. It can be also commonly underestimated thus causing unnecessary diagnostic dilemma. The diagnosis of spleen sarcoidosis may become a complex clinical problem, because differential diagnosis varies between hematological disorders or disseminated infectious or tropical diseases and other multisystemic diseases with spleen involvement [4, 5, 6]. The final diagnosis of abdominal sarcoidosis can be passed when there is a pathological diagnosis of other organ involvement and clinical or radiological symptoms or signs consistent with liver or spleen involvement [7].

time showed liver and spleen enlargement, with signs of hepatitis of unknown etiology; detailed immunological data from that time are missing. During the first three years the patient was treated at a regional hospital. Symptomatic therapy included lower doses of corticosteroids (10 mg per day) and did not lead to significant improvement. In 1973, she delivered a healthy boy, with a complete illness remission during pregnancy. Liver biopsies were performed twice (1975, 1976) due to pain in the right upper abdomen (pathology: hepatic fibrosis and chronic fibrous pericholangiolitis). There was no suspicion of liver sarcoidosis or elements of granulomatous inflammation. There was a suspicion of liver fibrosis. After that, rectal biopsy was done (pathology: chronic interstitial colitis). In 1976, during abdominal laparoscopy due to polypectomy, splenomegaly was seen although the patient was asymptomatic. In 1987, ultrasonography of liver detected a diffuse nonhomogenic and modestly enlarged spleen with lymph nodes in the splenic hilum of about 25 mm in size. For the first time laboratory findings of high gamma globulin values, positive antimitochondrial antibodies (AMA) and smooth-muscle antibodies (SMA) were established along with non-specific markers of inflammation. At this period, corticosteroids (15 mg/day) were administered several times during 1-2 years due to a suspected systemic

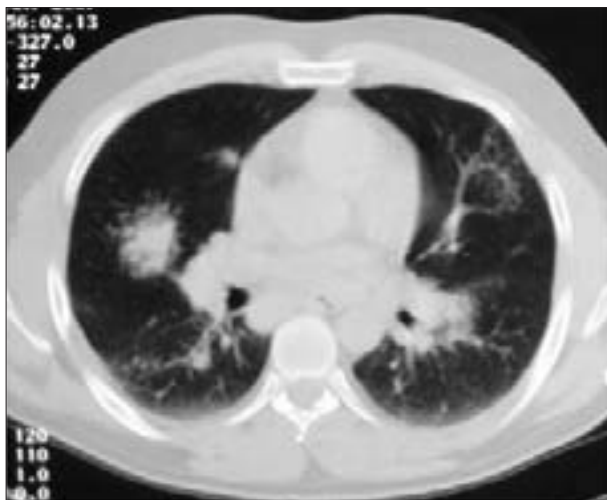
## CASE REPORT

In 1967, when aged 17 years, our patient experienced sudden abdominal pains, followed by general feeling of weakness and malaise. Clinical and abdominal examination at that

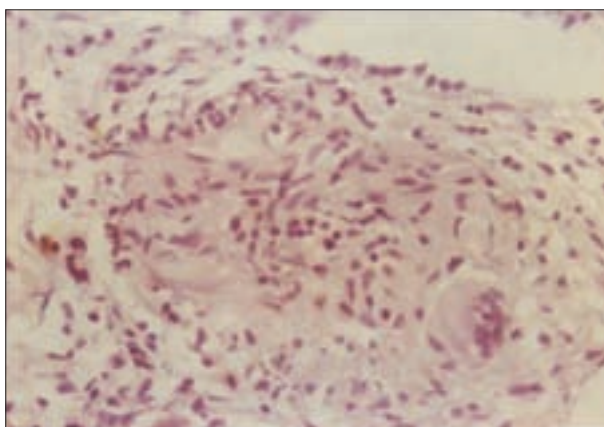
### Correspondence to:

Vesna ŠKODRIĆ-TRIFUNOVIĆ  
Clinic for Lung Diseases  
Clinical Center of Serbia  
Višegradska 26, 11000 Belgrade  
Serbia  
vesna.skodric@kcs.ac.rs;  
vesnaskodric@eunet.rs

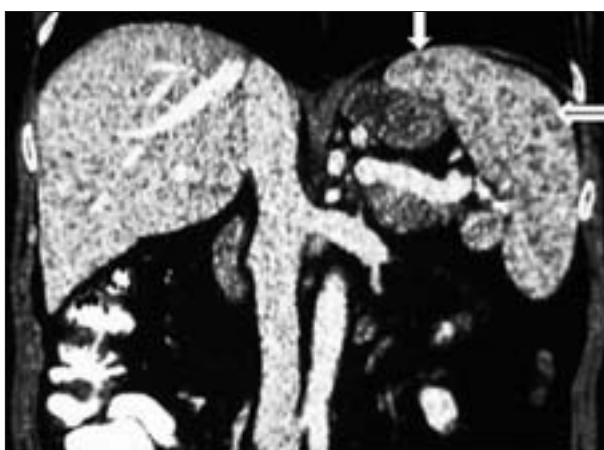disease of the connective tissue. Therefore the patient was referred to the Department of Rheumatology for further investigation. In 1991 splenomegaly and chronic hepatitis were detected again. During 1993 the patient developed arterial hypertension and kidney failure (glomerular filtration rate – GFR 50-60 ml/min) and proteinuria (0.5-1 g/24 h). In 1997 clinical and laboratory signs of different systemic disease persisted. The criteria for systemic lupus erythematosus were not met, however non-specific markers of inflammation and autoantibodies were detected (FITC ANA 0, anti-DNK antibodies 0). Kidney biopsy was performed (pathologic analysis showed a few glomeruli only, with a thickened basal membrane, but with predominant tubulointerstitial fibrosis and sclerosis with vascular sclerosis). During the next two years, the patient was treated with azathioprine (75 mg) and corticoids (5-20 mg/day). In 2000, she was on corticosteroid therapy due to renal failure. First detected changes of the chest were interpreted as interstitial fibrosis, but it was not further investigated. The spleen and hepatogram were normal and only gamma globins were slightly elevated. In 2006, worsening of kidney function was detected (rising serum creatinine level up to 170  $\mu$ mol/L and declining GFR of less than 40 ml/min). Kidney ultrasound revealed small sized kidneys with thin and bright renal parenchyma (features of chronic kidney disease). Since she had fever, chest CT was done revealing bilateral lymph node enlargement with interstitial changes (Figure 1). This time a pulmonologist was consulted and bronchoscopy was indicated. Bronchoscopy revealed hyperemic mucosa covered with white nodules. Pathological analysis discovered epithelioid noncaseating granuloma verisimilar sarcoidosis (Figure 2). Also, the value of angiotensin-converting enzyme (60.2 U/L) and calcium serum level (2.85 mmol/l) were elevated. Meanwhile, hepatogram and ultrasound liver and spleen findings were normal. The diagnosis of pulmonary sarcoidosis grade I/II was established. In the meantime, the patient's son aged 28 years was prior to our patient diagnosed pulmonary sarcoidosis. Since 2006 corticoid therapy (at initial dose of 30 mg/day) was decreased and excluded during 2008.



**Figure 1.** Chest CT scan shows thickened interstitium of both lungs and enlarged hilar lymph nodes

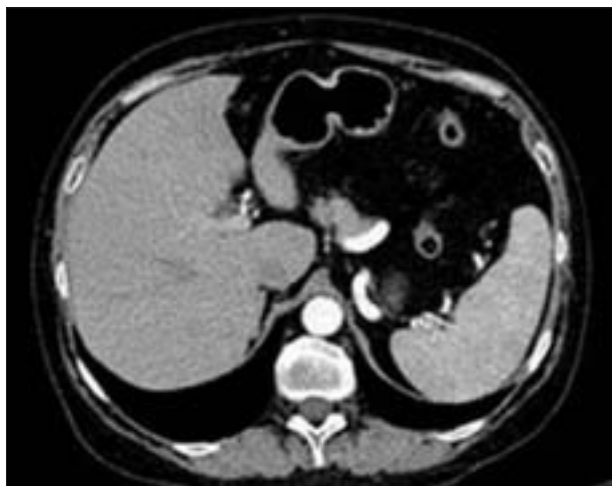


**Figure 2.** Microphotograph of lymph node shows epithelioid noncaseating granuloma



**Figure 3.** Coronal reformat abdominal CT revealed enlarged spleen with numerous hypodense nodular lesions (arrows)

Throughout the first 6 months in 2009, the patient was feeling well. Corticosteroids were withdrawn because chest and abdominal computerized tomography (CT) findings and ACE level were normal. However, in the second part of 2009 she started to lose weight (over 10 kg) and had nausea, and abdominal pains. Due to these complaints and renal failure progression the patient was admitted to Nephrology Clinic in January 2010. Abdominal CT revealed enlarged spleen with diffuse hypodense nodules (Figure 3) and chest CT showed a bilateral pulmonary reticulonodular pattern with mediastinal lymphadenopathy. For the first time ACE level was increased (up to 99 U/L) and polyclonal hypergammaglobulinemia was revealed (particularly IgG and IgA). Bone marrow biopsy was performed and findings were negative for neoplasia/lymphoma. Tumor markers were also negative and infections were excluded. During this time dermatology examination of the skin revealed changes typical of skin sarcoidosis (papular erythema with minimal whitish squamosis of the hands and legs). Thus, according to chest and abdominal CT, high ACE level, skin changes and other examinations, the diagnosis of pulmonary and extrapulmonary sarcoidosis recurrence was established. Prednisolone (30 mg/day) therapy was started again in March 2010. Follow-up of the patient in June and September 2010 revealed improvement of subjective feeling, without prior symptoms during



**Figure 4.** Contrast enhanced abdominal CT after treatment demonstrates spleen of normal size and structure

prednisolone in dose of 10-20 mg/day and renal insufficiency which stabilized (creatinine clearance 40 ml/min). Chest and abdominal CT showed absence of lymphadenopathy and hepatosplenomegaly (Figure 4). Laboratory analysis showed that ACE level was within normal limits. On the last follow-up the patient was without pulmonary and spleen sarcoidosis.

## DISCUSSION

In patients with splenic sarcoidosis the disease is usually severe, persistent and chronic, and tends to affect extra-thoracic organs [8, 9, 10]. At the time when our patient experienced first signs and symptoms of splenic sarcoidosis almost 40 years ago, diagnostic procedures for sarcoidosis were developing. This case report confirms the rule that the diagnosis of sarcoidosis is more accurate when it is suspected by the doctor. Extrapulmonary presentation as the initial manifestation of the disease is often unrecognized and may mimic other etiologies. Therefore, in this patient the diagnosis of sarcoidosis remained an unsolved puzzle for over 40 years. The acute onset of the disease, with clinical manifestations of splenomegaly and hepatitis, were significant prognostic parameters of the chronic nature of the disease in our case, as well as the indicated results by other investigators [5, 11]. At that time, during the 70-ies similar examples were found in the literature when splenectomy was performed because of suspected lymphoma but later pathological finding revealed sarcoidosis [12, 13, 14]. It is well known that corticosteroids are indicated as a very effective therapeutic agent at the clinical course of “disease with no name”. Possibly, temporary doses of prednisolone in the dose of 5-20 mg were not sufficient to stop this chronic inflammatory disease and besides, there were permanently appearing new problems. Thus, in our case splenomegaly was established for the first time in 1976 during laparoscopy, but also in 1987, 1991 and 2010 by ultrasound or CT examination and at that time, according to the medical data, corticosteroid therapy was started many times with different durations

(1-2 years). Spontaneous remissions of sarcoidosis occur in nearly two thirds of patients, but chronic, progressive disease may result in severe sequelae [4, 5, 10]. This could probably be the explanation for the undefined liver findings. Three times repeated liver biopsies pointed to fibrosis in a systemic disease or suspected liver TBC because of granuloma detection. Laboratory findings suggested spreading of the disease to the kidneys, furthermore biopsy of kidneys confirmed interstitial nephritis without granulomas, which was also found by Mahévas M. et al. [15] in 10 of 43 examined patients. Therapy with azathioprine and corticosteroids during the next two years did not stop the progression of chronic renal failure but the progression was relatively slow during the next 10 years, with proteinuria as can be expected in chronic mainly tubulointerstitial processes. During 2006, when corticosteroid therapy was stopped, radiological, bronchoscopic and pulmonary changes appeared which was typical of sarcoidosis. For the first time, after a lymph node biopsy epithelioid non-caseating granuloma verisimilar sarcoidosis was established. On corticoid therapy a complete remission was achieved. After long time (1991-2009) the patient was without splenomegaly but in 2010, the disease reactivated with enlarged spleen and diffuse hypodense nodules; a rare form of spleen sarcoidosis seen on abdominal CT that was previously reported in the literature [16]. Chest CT and high level of ACE confirmed reactivation of sarcoidosis.

At the end it is very important to note that during a long-term follow-up period there was no development of hypersplenism, anemia or elevated transaminases. Only once, hypercalcemia was detected, but calciuria was not measured because GFR was less than 60 ml/min. All the time the high sedimentation rate as well as hypergammaglobulinemia was presented as signs of nonspecific inflammation. Finally, after 5 months of corticosteroid therapy the patient was again in a complete remission. Also, this case is interesting because of the presence of sarcoidosis in the patient's family (patient's son also had recurrent pulmonary sarcoidosis). It is possible that genetic factors and environmental agents of infection may result in autoimmune response that is manifested as sarcoidosis [17]. But it is also likely that genetic factors may be important in defining the pattern of disease presentation and progression as well as its overall prognosis. In conclusion, clinical manifestations of sarcoidosis, especially abdominal localization are extremely heterogeneous and overlap with a wide spectrum of diseases, and due to this fact biopsy and pathologic confirmation of sarcoidosis is a necessity whenever possible. Final diagnosis of spleen sarcoidosis can be confirmed in the presence of pathologically verified sarcoidosis of the lungs as in our case.

## ACKNOWLEDGEMENTS

This work was supported by the Ministry of Science and Technological Development of Serbia, contract No. 175046, 2011–2014.

## REFERENCES

- James DG, Zumla A. The Granulomatous Disorders. Cambridge: Cambridge University Press; 1999.
- Milovanović A, Milovanović J, Torbica N. Ocena radne sposobnosti kod neurosarkoidoze. Srp Arh Celok Lek. 2006; 134(5-6):238-40.
- Morgenthau SA, Iannuzzi MC. Recent advances in sarcoidosis. Chest. 2011; 139(1):174-82.
- Sestini P, Marchi B, Marri D. Liver disorders in pulmonary sarcoidosis. Sarcoidosis. 1993; 10:177-9.
- James DG, Sherlock S. Sarcoidosis of the liver. Sarcoidosis. 1994; 11:2-6.
- Čolović N, Čemerikić V, Čolović R, Zogović S, Stojković M. Hamartom slezine. Srp Arh Celok Lek. 2000; 128(3-4):331-4.
- Hunninghake GW, Costabel U, Ando M, Baughman RP, Cordier JF, du Bois R, et al. ATS/ERS/WASOG statement on sarcoidosis. Sarcoidosis Vasc Diff Lung Dis. 1999; 16:149-73.
- Salazar A, Mañá J, Corbella X, Albareda JM, Pujol R. Splenomegaly in sarcoidosis: a report of 16 cases. Sarcoidosis. 1995; 12:131-4.
- Fordice J, Katras T, Jackson RE, Cagle PT, Jackson D, Zaleski H, et al. Massive splenomegaly in sarcoidosis. Sou Med J. 1992; 85:774-8.
- Judson M. Hepatic and splenic sarcoidosis in Baughmans sarcoidosis. Lung Biology in Health and Diseases. 2006; 26:571-92.
- Sharma OP, Vucinic V, James DG. Splenectomy in sarcoidosis: indications, complications, and long-term follow-up. Sarcoidosis Vasc Diff Lung Dis. 2002; 19(1):66-70.
- Longcope WT, Freiman DG. A study of sarcoidosis based on a combined investigation of 160 cases including 30 autopsies from The Johns Hopkins Hospital and Massachusetts General Hospital. Medicine (Baltimore). 1952; 31:1-132.
- Sharma OP. Splenic rupture in sarcoidosis: Report of unusual case. Am Rev Respir Dis. 1967; 96:101-2.
- Di Sabatino A, Carsetti R, Corazza GR. Posplenectomy and hyposplenic states. Lancet. 2011; 378(9785):86-97.
- Mahévas M, Lescure FX, Boffa JJ, Delastour V, Belenfant X, Chapelon C, et al. Renal sarcoidosis: clinical, laboratory, and histological presentation and outcome in 47 patients. Medicine (Baltimore). 2009; 88(2):98-106.
- Warshauer DM, Dumbleton SA, Molina PL, Yankaskas BC, Parker LA, Woosley JT. Abdominal CT findings in sarcoidosis: radiologic and clinical correlation. Radiology. 1994; 192:93-8.
- Schurmann M, Lympany PA, Philipp R, Muller-Myhsok B, Wurm K, Schlaak M, et al. Familial sarcoidosis is linked to the major histocompatibility complex region. Am J Respir Crit Care Med. 2000; 162(3):861-4.

## Мистерија звана саркоидоза: четрдесет и четири године клиничког праћења хроничне системске болести

Весна Шкодрић-Трифунковић<sup>1,2</sup>, Виолета Вучинић<sup>1,2</sup>, Сања Симић-Огризовић<sup>1,3</sup>, Ружа Стевић<sup>1,4</sup>, Михаило Стјепановић<sup>2</sup>, Катарина Илић<sup>5</sup>, Живорад Савић<sup>4</sup>

<sup>1</sup>Медицински факултет, Универзитет у Београду, Београд, Србија;

<sup>2</sup>Клиника за пулмологију, Клинички центар Србије, Београд, Србија;

<sup>3</sup>Клиника за нефрологију, Клинички центар Србије, Београд, Србија;

<sup>4</sup>Центар за радиологију и магнетну резонанцу, Клинички центар Србије, Београд, Србија;

<sup>5</sup>Катедра за фармакологију, Фармацеутски факултет, Универзитет у Београду, Београд, Србија

### КРАТАК САДРЖАЈ

**Увод** Ово је приказ болеснице старе 61 годину. С обзиром на то да су од првих симптома болести до коначне дијагнозе саркоидозе прошле 44 године, то је био разлог да овај случај објавимо.

**Приказ болесника** Током наведеног периода с времена на време су се јављале полиморфне тегобе, као што су адинамија, мучнина, бол у трбуху, артралгија, миалгија, губитак телесне тежине (8–10 kg) итд. У клиничкој слици доминирали су спленомегалија, хепатитис и артралгија, а касније се развила и хронична инсуфицијенција бубрега. У лабораторијским анализама маркери инфламације и аутоантитела били су повишени. Болесница је била хоспитализована у

различитим интернистичким клиникама (гастроентерологија, алергологија, реуматологија, нефрологија, пулмологија). Биопсија јетре је урађена три пута, биопсија бубрега и ректума једном и на крају су урађене бронхоскопија и биопсија плућа. Коначно, четрдесет година након почетка првих симптома болести, 2006. године је потврђена дијагноза саркоидозе плућа.

**Закључак** Коначна дијагноза саркоидозе слезине постављена је после патохистолошке потврде саркоидозе плућа. Овај случај је посебно занимљив због постојања фамилијарне саркоидозе (син болеснице је такође боловао од рецидивирајуће саркоидозе плућа).

**Кључне речи:** саркоидоза; јетра; слезина; плућа; бубрег

Примљен • Received: 11/08/2011

Прихваћен • Accepted: 04/07/2012