

Morphological Characteristics of the Developing Proximal Femur: A Biomechanical Perspective

Marija Djurić¹, Petar Milovanović¹, Danijela Djonić¹, Arsa Minić², Michael Hahn³

¹Laboratory for Anthropology, Institute of Anatomy, School of Medicine, University of Belgrade, Belgrade, Serbia;

²European University, American School of Medicine, Belgrade, Serbia;

³Department of Osteology and Biomechanics, University Medical Center Hamburg-Eppendorf, Hamburg, Germany

SUMMARY

Introduction In contrast to a plethora of studies on the proximal femur in adults, its external and internal morphology in growing children has not been sufficiently analyzed.

Objective We analyzed changes in external and internal morphology of the proximal femur during growth and development to interpret the links between them and concepts of the human femoral biomechanics.

Methods We assessed external geometry, internal trabecular and cortical arrangement, and bone mineral density (BMD) of the proximal femur in 29 children (age at death from 1 month to 14 years) from archaeological context by using microscopic and radiographic methods.

Results The results showed that both the femoral neck width and length increased with age, with the femoral neck becoming more elongated, while the collo-diaphyseal angle decreased. A strong relationship between age and adjusted areal BMD was found, showing continuous increase during childhood. Parallel trabecular pattern at birth changed to mature three distinct trabecular groups (longitudinal – principal compressive, transversal – tensile and randomly scattered) starting from the age of 8 months. In older children the superior and inferior aspects of the femoral neck differently changed with growth, with medial neck having thicker cortex and trabeculae.

Conclusion In the light of bone adaptation principle, the observed changes in external and internal morphology are governed by mechanical forces acting on the developing femur. Our findings on the development of trabecular pattern and cortical distribution are compatible with recent views on the femoral biomechanics which point out the predominance of compressive stresses in the femoral neck, adaptation to shear stresses, multiaxial loading perspective, prevalence of muscle effects over body weight, and existence of adaptational eccentricity.

Keywords: proximal femur; growth; bone adaptation; mechanical loading

INTRODUCTION

The key concepts related to bone functional adaptation to mechanical stress were developed even in the 19th century [1, 2]. Since then a number of anatomical and anthropological studies have focused on the investigation of bone morphology as the reflection of bone mechanical loading history [3]. Due to a rising problem of senile hip fracture in modern populations, research attention was particularly paid to hip bone mineral density, external geometry, and internal architecture as possible determinants of fracture susceptibility [4, 5, 6]. In contrast, the developing femur was less investigated [7-11]. In particular, there are insufficient studies investigating these morphological features comparing it with the children's femur.

The central concept of skeletal biology is the idea that bone form reflects mechanical loading history [1, 2, 3]. Namely, the proximal femur adapts its structure to loads to which it is exposed in the sense that bone trabeculae tend to orientate along the directions of principal stresses [2, 12]. In this way maximum stiffness and bone

strength are achieved [13, 14]. In the “traditional concept” of femoral mechanics, both compressive and tensile stresses occur in the proximal femur [2]. Load which is represented by body weight applied to the femoral head tends to bend the femoral neck which causes tension in the superior and compression in the inferior aspect of the neck. However, in contrast to traditional interpretations, recent studies on stress distribution in the proximal femur have revealed that, when capsular, muscle and ligament forces are also considered, stresses occurring in the proximal femur are predominantly compressive [9, 15, 16]. In that sense, both “principal compressive” and “principal tensile” groups of trabeculae actually correspond to compression stresses, transmitting forces from the femoral head into the shaft. It is now considered that loads originating from muscle contractions are greater than the effect of gravity, due to the disadvantageous positioning of muscle attachments on bony lever [17]. Recent literature suggests the significance of shear stresses (which are not included in Wolff's concept), as shear may be a dominant failure mode for the proximal femur [18] with

Correspondence to:

Marija DJURIĆ
Institute of Anatomy
School of Medicine
4/2 Dr Subotića, 11000 Belgrade
Serbia
marijadjuric5@gmail.com

shear stress being the main stimulus for trabecular bone developmental adaptation [19]. Nowadays, it is believed that observation of single loading condition (even if it is represented by resultant force) is too simplified and cannot completely explain the femoral structure, so multidirectional loading history has to be considered [13]. Specifically, extreme loading directions corresponding to extreme positions in range of joint excursions are reported to determine trabecular directions [9].

OBJECTIVE

In this study we used specimens of proximal femora of non-adults derived from archaeological context to investigate bone trabecular pattern, external geometry and bone mineral density with respect to the growth of individuals. Our aim was to find the links between the changes in external and internal morphology of the proximal femur during growth and development and classical vs. more recent understandings of human femoral biomechanics.

METHODS

The material used in this study consisted of 29 right proximal femora derived from archaeological context. The skeletal remains belong to non-adults, age-at-death from 1 month to 14 years, from the late medieval graveyard of Stara Torina (Serbia). The criterion for inclusion of the specimens in the study was complete preservation of the right femur (with no signs of breakage of the cortical bone, cortical erosion or other macroscopic bone damage). Sex-specific analysis of skeletons was not performed because of uncertainty of sex determination in non-adults. Age determination was based on maximum femoral diaphyseal length [20, 21, 22].

External geometry

Each specimen of the proximal femur was halved in the coronal plane, and three linear measurements were obtained directly from the frontal sections: femoral neck axis length (FAL), femoral neck width (FW), and collo-diaphyseal (neck-shaft) angle (Q). FAL represents the length of the femoral neck axis from the base of the lateral part of the greater trochanter to the femoral head. FW is the length of the narrowest cross-section of the femoral neck. Q is an angle between the long axis of the femoral neck and the shaft of the femur. The neck index (NI), representing a ratio between the femoral neck width and femoral neck axis length, was introduced here by the authors in order to describe the general shape of the femoral neck.

Bone mineral density

In vitro DXA scans (dual X-ray photon absorptiometry) were performed using a HOLOGIC 1000 W densitome-

ter (Hologic QDR 1000/W; Hologic, Waltham, MA). The femoral specimens were submerged into a water bath in the standard position. Using the standard hip analysis software, areal bone mineral density (aBMD, g/cm²) was determined for the femoral neck region, intertrochanteric region, Ward's triangle and total hip region.

Trabecular pattern

High-resolution digital X-ray imaging was performed to investigate the internal organization of proximal femora. Antero-posterior radiographs of all specimens were taken by Visaris digital X-ray system (Model Digraf C).

Each frontal section of proximal femora was photographed and qualitative analysis of specimens was undertaken to investigate the trabecular pattern (orientation of trajectories, intersections).

In order to perform microscopic analysis of the thickness and distribution of trabecule in different regions of the femoral neck (medial and lateral neck and Ward triangle), undecalcified bone samples embedded in methylmethacrylate were cut into 100 µm thick slides in frontal plane using a Leica diamond saw (Leica SP 1600). On the cross sections, three regions of interest were defined. Zone A represented the lateral neck region, zone B comprised the central portion of the neck (including Ward's triangle), while zone C was composed of the medial part of the neck.

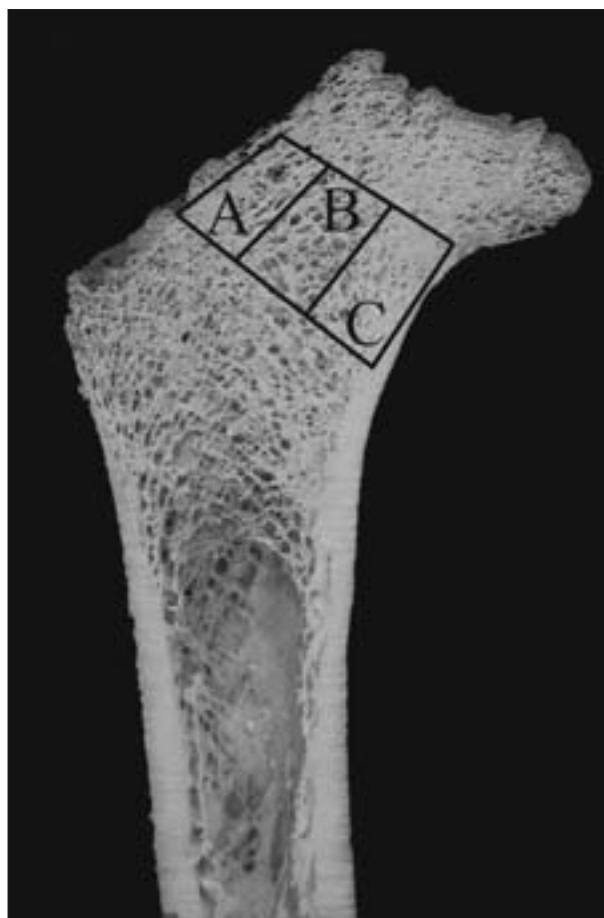


Figure 1. Femoral cross-section displaying three regions of interest: A. lateral neck; B. Ward's triangle; C. medial neck

The regions were situated between two parallel lines drawn perpendicularly to the axis of the femoral neck (Figure 1). Those regions were analyzed on unstained 100 µm thick ground sections of undecalcified bone using a polarized-light microscope.

Statistical analysis

The one-sample Kolmogorov-Smirnov test was used to check for the normality of the distribution in the observed external geometric and densitometric parameters. Since DXA measurements (aBMD) are size dependent, i.e., measurements are from a two-dimensional image projection of a three-dimensional structure, in a growing child this causes inaccuracies when interpreting measurements [23]. Therefore, to control the effects of the third dimension, aBMD was adjusted to the femoral neck diameter. Linear regression analysis was used to assess the age-dependence of adjusted bone mineral density and external geometric parameters, while in case of the neck index geometric curve better fitted the data. The Pearson's correlation was used to determine the level of association among external geometric parameters. SPSS statistical package (version 15) and MedCalc (version 9) were used for the analysis, and the results were considered significant at 0.05 level.

RESULTS

External geometry

During childhood the femoral neck width and femoral neck axis length showed increase. Nevertheless, the observed age-dependent decrease of the neck index indicates that the femoral neck generally elongates with age (Table 1). However, the decrease of the neck index is not gradual; NI decreases dramatically from birth to the end of the first year and then decreases only slightly achieving a plateau at about the age of 3 years (Figure 2). The collo-diaphyseal angle showed a negative age trend, with values ranging between 138 and 112 degrees (Table 2). It did not correlate significantly with the femoral neck axis length, femoral neck width or the neck index (Pearson correlation; $p=0.177$, $p=0.263$, $p=0.242$, respectively).

Table 1. Linear regression analysis for age dependence in densitometric and geometric parameters

Parameter	R	R ²	p
Neck-shaft angle	-0.305	0.093	0.114
Neck index [§]	-0.910	0.828	<0.001
Neck axis length	0.961	0.923	<0.001
Neck width	0.959	0.920	<0.001
aBMD neck	0.474	0.224	0.011
aBMD intertrochanteric	0.559	0.312	0.002
aBMD Ward	0.515	0.265	0.005
aBMD total	0.543	0.295	0.003

[§] non-linear regression

Regression equation: $\text{Log}(\text{neck index}) = 0.0966 - 0.2145 \times \text{Log}(\text{age})$

Bone mineral density

Adjusted areal bone mineral density demonstrated continuous increase during childhood in all regions of interest (Figure 3, Tables 1 and 2).

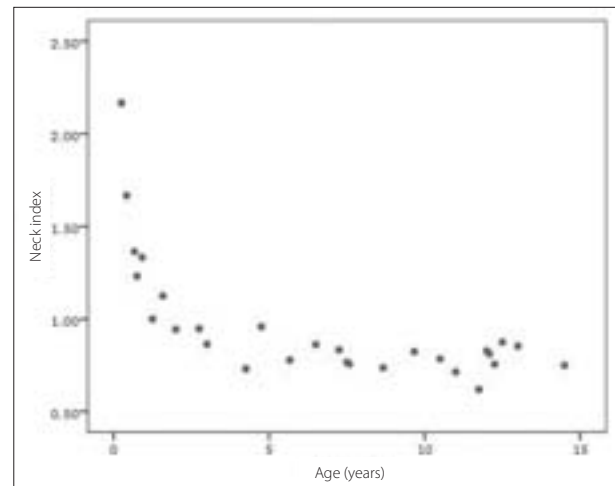


Figure 2. Changes in the neck index as a function of age

Table 2. Descriptive statistics for external geometry and densitometric parameters of growing femora

Parameter	Mean	SD	Min.	Max.
Femoral neck width (cm)	2.3	0.7	1.3	3.5
Femoral neck axis length (cm)	2.7	1.2	0.6	4.4
Neck index (dimensionless)	0.960	0.332	0.619	2.167
Neck-shaft angle (degrees)	129.1	6.4	112	138
Adjusted BMD neck (g/cm ²)	0.315	0.044	0.225	0.389
Adjusted BMD intertrochanteric (g/cm ²)	0.371	0.054	0.285	0.514
Adjusted BMD ward (g/cm ²)	0.317	0.048	0.222	0.448
Adjusted BMD total (g/cm ²)	0.344	0.048	0.263	0.436




Figure 3. Increase of femoral adjusted areal bone mineral density (BMD) with age of individuals

Trabecular pattern

Qualitative analysis of frontal sections of proximal femora showed that trabecular pattern changed from the parallel trabeculae after birth to three distinct trabecular groups in the second year (Table 3, Figures 4–7), while the upper end of the medullary canal came closer to the trochanter region.

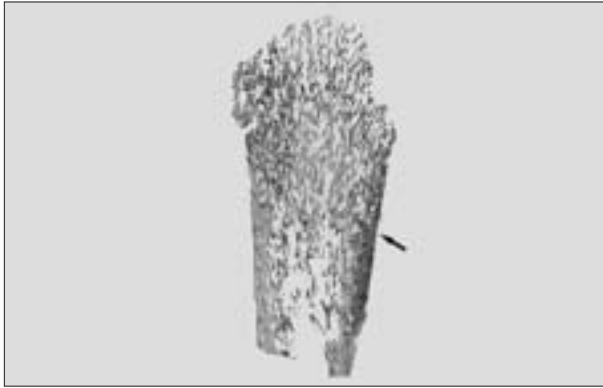


Figure 4. Low power microscopic view of the proximal femur aged one month shows longitudinal bone trabeculae and thin medial cortex (arrow) (100 μ m undecalcified section, unstained)




Figure 5. Low power microscopic view (100 μ m undecalcified section, unstained) of proximal femora aged 3 months (A) and 5 months (B) showing primarily longitudinal bone trabeculae. Observe transversal growth and thicker medial cortex (arrow) in comparison to the previous Figure.

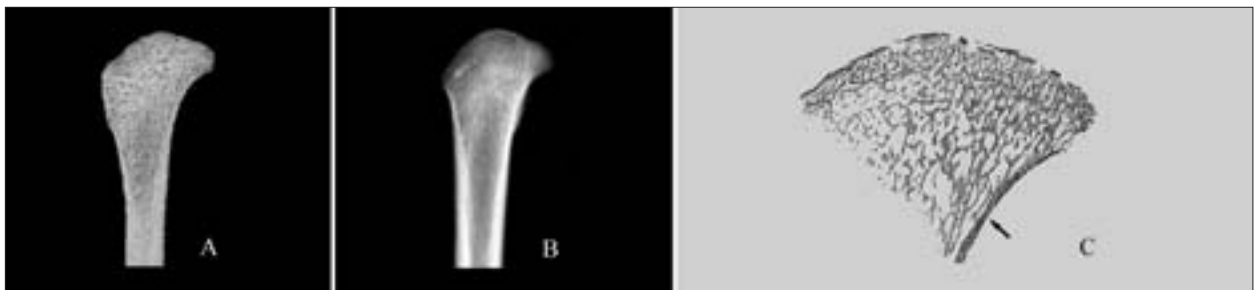


Figure 6. The proximal femur of an 8-month old individual: A. Frontal section; B. Radiography; C. Low power microscopic view showing longitudinal (right), transversal (left up) and random (left below) bone trabeculae. Medial cortex is marked by arrow.

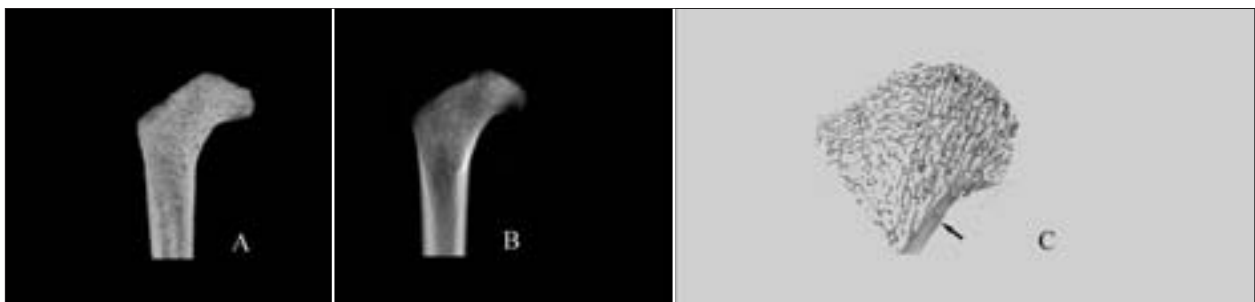


Figure 7. The proximal femur of a 2 year and 8 months old individual: A. Frontal section; B. Radiography; C. Low power microscopic view. See three groups of bone trabeculae: longitudinal (right), transversal (left up) and random (left below). Medial cortex is marked by arrow.

Radiography demonstrated more clearly visible trabecular pattern in younger individuals than frontal sections; starting with the age of 8 months in all individuals principal compressive and tensile trabecular groups of trabeculae were well defined (Figure 6, Table 3).

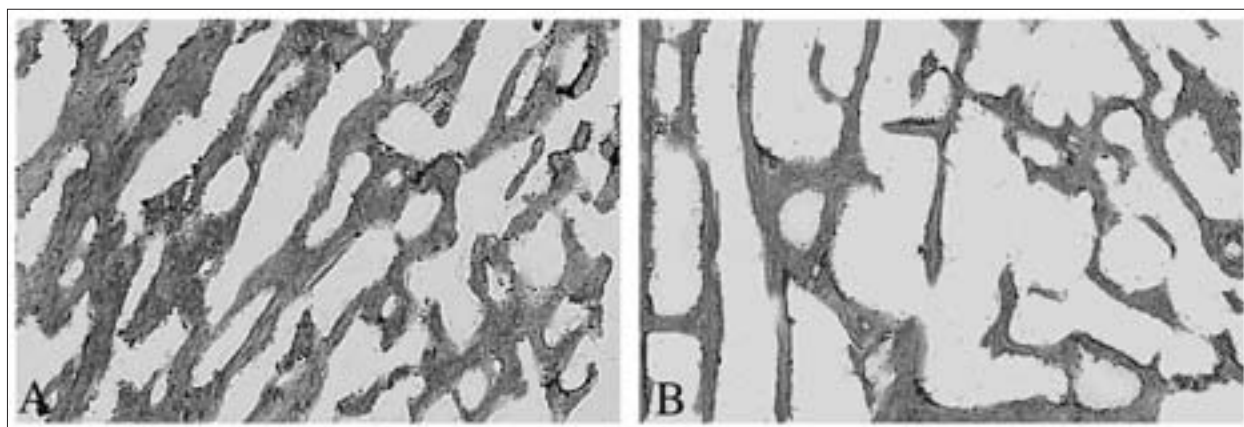
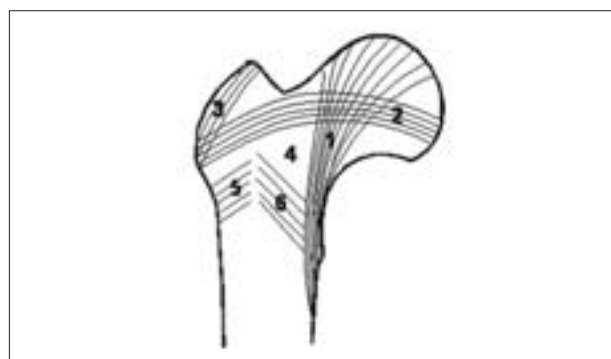
Histological observation revealed that starting from the age of 8 months all specimens demonstrated three groups of bone trabeculae; longitudinal (principal compressive in the medial neck), transversal (principal tensile in the lateral neck) and randomly scattered (Ward's triangle) (Table 3, Figures 4–9). The thickest were longitudinal and the thinnest were randomly scattered trabeculae (Figure 8). Bone marrow spaces were the smallest between the longitudinal trabeculae and the largest in the Ward's triangle (Figure 8).

DISCUSSION

In our sample, observation of specimens of different age revealed outstanding changes in bone size and shape, as well as in internal organization, and BMD.

Table 3. Trabecular pattern of growing femora

Case No	Age	Macroscopic observation	Radiographic appearance	Histological appearance
1	1 month	Straight trabeculae running parallel to the bone long axis	Straight parallel trabeculae	Longitudinal bone trabeculae (Figure 4)
2	3 months	Randomly oriented trabecular network without distinct pattern	No distinct pattern	Longitudinally oriented trabeculae thicker in central and medial areas (Figure 5A)
3	5 months	Randomly oriented trabecular network without distinct pattern	No distinct pattern	Longitudinally oriented trabeculae thicker in central and medial areas (Figure 5B)
4	8 months	Trabeculae at the upper end of medullar canal from the medial and the lateral side run obliquely toward midline – “fish bone” pattern; principal tensile group of trabeculae parallel to the superior surface of the neck is slightly visible (Figure 6A)	Principal compressive and tensile groups are well defined (Figures 6B and 7B)	3 groups of trabeculae: longitudinal (principal compressive), transversal (principal tensile) and randomly scattered (Ward’s triangle) (Figures 6C, 7C and 8); progressive growth of trabeculae and medial cortex
5	9 months	Observable principal tensile group		
6	11 months	Observable principal tensile group		
7	1 year 3 months	Observable principal compressive group of trabeculae		
8	1 year 7 months	All groups of trabeculae are observable on cross sections		
9	2 years	All groups of trabeculae are observable on cross sections		
10	2 years 8 months	Groups of trajectories and Ward’s triangle are visible on cross sections (Figure 7A)		
11-29	Older than 2 years and 8 months			

**Figure 8.** Medium power microscopic view of bone trabeculae and marrow spaces of proximal femur aged twelve years. A. Principal compressive bone trabeculae, medial neck; B. Principal tensile bone trabeculae, lateral neck (left) and Ward’s triangle bone trabeculae (center and right).**Figure 9.** Main groups of trabeculae in adult femur: 1 – Principal compressive; 2 – Principal tensile; 3 – Greater trochanteric; 4 – Ward’s triangle; 5 – Secondary tensile; 6 – Secondary compressive

Growth-related changes in external geometry

Our results demonstrated that the neck-shaft angle decreased with growth, which is in close agreement with other studies [24]. The decrease in the collo-diaphyseal angle during growth could represent the result of changes in body proportions followed by adaptation of the hip joint to vertical posture and gait changed conditions [25, 26]. Namely, it is proposed that modelling of the femoral neck is governed by the balance between vertical compressive forces originating from gravity and the contractions of the iliopsoas muscle, and the tension caused by abductor muscles attached to the greater trochanter [27], with certain morphological differences between different hominid taxa [28]. It is considered that

fitting of the femoral head to the acetabulum is influenced by the neck-shaft angle. This angle represents a beneficial structural adaptation which keeps the lower extremity away from the pelvis and allows more rotation of the hip joint [29]. Inclination of the hip resultant force towards the vertical plane and increase in the magnitude of trochanteric resultant force with maintaining its direction during the growth period cause a decrease in the neck-shaft angle [27].

Although the values of the neck-shaft angle have been reported to correlate positively with the length of the femoral neck in adult population [29], our results indicate that it is not the case during the growth period, i.e., in children there was age-related increase in the neck length while the neck-shaft angle tended to decline.

While in our specimens both the femoral neck width and femoral neck axis length increased with age, the observed age-related increase of the neck index indicates that the growth in length is more rapid causing femoral neck to become elongated as age increases. This adaptation allows a considerable range of movements of the hip joint [30] which is necessary for daily activities and adaptation to biological and social functions of childhood and approaching adolescence.

Trabecular pattern – classical vs. recent view on mechanics of the proximal femur

In fetal and early postnatal period, the whole metaphysis is filled by primary trabecular bone [7] and it is considered that increased mechanical loading in the first year leads to conversion of primary to secondary cancellous bone with two distinct groups of intersecting vault-like trabeculae (compressive and tensile groups) [8, 9, 10]. Townsley [8] has pointed out that the growth-related changes in bone morphology, as an adaptation to habitual loading conditions, are closely related to the beginning of walking which introduces body weight load on the femur; this is consistent with traditional interpretation of stresses within the proximal femur, since weight-bearing stresses are concentrated in the primary compressive system of trabeculae during gait [7, 9, 31]. In our sample, at the age of one month, the proximal femur displayed almost straight longitudinal trabeculae, which is in agreement with data from other studies [7, 8, 10]. With further growth, we noticed more distinctive pattern of trabecular arrangement. However, “principal compressive” and “tensile” groups of trabeculae in our sample appeared at the age of 8 months (visible on radiography Figure 6B and histology Figure 6C), which does not fit in the classical concept since it is before the age at which a child begins to walk. Therefore, our findings speak more in favor of some recent models of the stresses in the femoral neck. Namely, in contrast to traditional interpretation, the stresses in the proximal femur are considered to be predominantly compressive [15, 16]. The hip muscles, joint capsule and ligaments pull the femoral head into the acetabulum contributing to the compression applied to the femoral head [15]. Therefore, the early appearance of the trabecular groups in our sample could reflect increased activity of the muscles inserting into the greater

and lesser trochanter, even before a child starts to walk. This is supported by observations that the largest physiologic loads placed on children’s bones originate from muscle contractions, being even routinely greater than the effect of gravity [17]. Further development and reinforcement of such distinctive trabecular organization in later age could further correspond to stress changes caused by upright sitting at about 6 months, crawling at about 9 months, as well as transitory standing and beginning of walking.

Our findings are also compatible with a further changed picture about the types of stresses in the proximal femur with recent emphasis on the importance of shear stress. The bone is the weakest in shear when compared to tension and compression, and the femur is habitually loaded “off-axis” which augments shear stresses between the layers of the femoral neck [32, 33]. Therefore, in order to maintain its stability, the bone has to adapt itself to accommodate shear coupling. In our study, contrary to the findings of Osborne et al. [7], we consistently found secondary medial and lateral groups of trabeculae in the specimens. This “fish bone” pattern which was observable as early as at the age of 8 months resembled the Hert’s model of trabecular organization in case of multiaxial loading, and those two groups of trabeculae could be considered to originate from extreme angle load cases which cause large bending moments in the femur [13]. Contrary to Wolff’s descriptions, and in line with some other authors [9, 12, 32, 33], trabecular intersections in our sample were notably non-orthogonal. Such non-orthogonality in trabecular arrangement is considered to be the most favorable organization in case of multiaxial joint loading [9, 32, 33], particularly as it could represent an important adaptive response since it has been shown to reduce shear coupling effects [32]. In that way, the bone stability would be encouraged by reducing shear stresses. In our other specimens, all groups of trabeculae were present and their pattern changed slightly with further growth and gait maturation, which is compatible with microCT data by Ryan and Krovitc [10].

Regional differences in bone amount: mechanical perspective

BMD in all regions increases during childhood, which corresponds to enlargement of bone with increase in mineral mass. Increase in bone mass is also reflected in the observation that the trabecular and cortical bone become thicker with increasing age (see the microscopic view, Figs. 4-8), particularly in the medial neck. In our specimens, it was also notable that medial (inferior) neck cortex was considerably thicker than the lateral (superior) cortex. Quite homogenous and dense bone in the youngest individuals changed differently between the medial and lateral aspect of the femoral neck during the growth process. This medial-lateral asymmetry may reflect trabecular eccentricity which has been proposed as one of bone adaptive responses [30]. Furthermore, the differences between the lateral and medial region of the femoral neck correspond to the differences in stresses and strains experienced in

those parts [4, 6, 34]. Namely, in the normal human femoral neck, the major part of the load is concentrated in the medial aspect [31], while the lateral neck is under-loaded.

CONCLUSION

The observed growth-related changes in proximal femoral external and internal morphology are compatible with bone functional adaptation principle. The changes in shape of the proximal femur could reflect the changing complex loading pattern during growth. Quite homogeneous bone in the youngest individuals changed differently between the medial and lateral aspect of the femoral neck

during the growth process. The differential trabecular arrangement and cortical distribution are compatible with recent changes in understanding of proximal femur biomechanics; predominance of compressive stresses in the femoral neck, significance of adaptation to shear stresses, multiaxial loading conditions perspective, the prevalence of the effects of muscle actions over the effect of body weight, and the existence of bone adaptational eccentricity

ACKNOWLEDGEMENTS

The authors acknowledge the support from the Ministry of Science of the Republic of Serbia (project number: 45005).

REFERENCES

- Roux W. Der Kampf der Teile im Organismus. Leipzig: Wilhelm Engelmann; 1881.
- Wolff J. Das Gesetz der Transformation der Knochen. Berlin: Verlag von August Hirschwald; 1892.
- Ruff C, Holt B, Trinkaus E. Who's afraid of the big bad Wolff?: "Wolff's law" and bone functional adaptation. *Am J Phys Anthropol.* 2006; 129(4):484-98.
- Djuric M, Djonic D, Milovanovic P, Nikolic S, Marshall R, Marinkovic J, et al. Region-specific sex-dependent pattern of age-related changes of proximal femoral cancellous bone and its implications on differential bone fragility. *Calcif Tissue Int.* 2010; 86(3): 192-201.
- Milovanovic P, Djonic D, Marshall RP, Hahn M, Nikolic S, Zivkovic V, et al. Micro-structural basis for particular vulnerability of the superolateral neck trabecular bone in the postmenopausal women with hip fractures. *Bone.* 2012; 50(1):63-8.
- Djonic D, Milovanovic P, Nikolic S, Ivovic M, Marinkovic J, Beck T, et al. Inter-sex differences in structural properties of aging femora: implications on differential bone fragility: a cadaver study. *J Bone Miner Metab.* 2011; 29(4):449-57.
- Osborne D, Effmann E, Broda K, Harrelson J. The development of the upper end of the femur, with special reference to its internal architecture. *Radiology.* 1980; 137(11):71-6.
- Townsend W. The influence of mechanical factors on the development and structure of bone. *Am J Phys Anthropol.* 1948; 6(1):25-46.
- Hert J. A new attempt at the interpretation of the functional architecture of the cancellous bone. *J Biomech.* 1994; 27(2): 239-42.
- Ryan TM, Krovitz GE. Trabecular bone ontogeny in the human proximal femur. *J Hum Evol.* 2006; 51(6):591-602.
- Salle BL, Rauch F, Travers R, Bouvier R, Glorieux FH. Human fetal bone development: histomorphometric evaluation of the proximal femoral metaphysis. *Bone.* 2002; 30(6):823-8.
- von Meyer GH. Die Architektur der Spongiosa. *Arch Anat Physiol Wissenschaf Med.* 1867; 34:615-28.
- Miller Z, Fuchs MB, Arcan M. Trabecular bone adaptation with an orthotropic material model. *J Biomech.* 2002; 35(2):247-56.
- Pedersen P. On optimal orientation of orthotropic materials. *Struct Optim.* 1989; 1(2):101-6.
- Rudman K, Aspden R, Meakin J. Compression or tension? The stress distribution in the proximal femur. *Biomed Eng Online.* 2006; 5(1):12.
- Kalmey JK, Lovejoy CO. Collagen fiber orientation in the femoral necks of apes and humans: do their histological structures reflect differences in locomotor loading? *Bone.* 2002; 31(2):327-32.
- Frost HM. Muscle, bone, and the Utah paradigm: a 1999 overview. *Med Sci Sports Exerc.* 2000; 32(5):911-7.
- Ford CM, Keaveny TM. The dependence of shear failure properties of trabecular bone on apparent density and trabecular orientation. *J Biomech.* 1996; 29(10):1309-17.
- Keaveny T, Morgan E, Niebur G, Yeh O. Biomechanics of trabecular bone. *Annu Rev Biomed Eng.* 2001; 3:307-33.
- Mareh MM. Linear growth of the long bones of extremities from infancy through adolescence. *Am J Dis Child.* 1955; 89:725-42.
- Mareh MM. Measurements from roentgenograms, heart size, long bone lengths, bone, muscles and fat widths, skeletal maturation. In: McCammon RW, editor. *Human Growth and Development.* Springfield: Charles C. Thomas; 1970. p.155-200.
- Scheuer JL, Black SM. *Developmental Juvenile Osteology.* London: Academic Press; 2000.
- Rauch F, Schoenau E. Changes in bone density during childhood and adolescence: an approach based on bone's biological organization. *J Bone Miner Res.* 2001; 16(4):597-604.
- Hefti F. Deviations in the axes of the lower extremities. *Orthopade.* 2000; 29(9):814-20.
- Rafferty KL. Structural design of the femoral neck in primates. *J Hum Evol.* 1998; 34(4):361-83.
- Bulandra AM, Gielecki JS, Leciejewska I, Karaszewski P, Sieron D. Digital-image analysis of the femoral shaft/neck angle in human fetuses. *Folia Morphol (Warsz).* 2003; 62(4):415-7.
- Heimkes B, Posel P, Plitz W, Zimmer M. Age-related force distribution at the proximal end of the femur in normally growing children. *Z Orthop Ihre Grenzgeb.* 1997; 135(1):17-23.
- Holliday TW, Hutchinson VT, Morrow MMB, Livesay GA. Geometric morphometric analyses of hominid proximal femora: Taxonomic and phylogenetic considerations. *HOMO J Comp Hum Biol.* 2010; 61(1):3-15.
- Isaac B, Vettivel S, Prasad R, Jeyaseelan L, Chandhi G. Prediction of the femoral neck-shaft angle from the length of the femoral neck. *Clin Anat.* 1997; 10(5):318-23.
- Fox JC, Keaveny TM. Trabecular eccentricity and bone adaptation. *J Theor Biol.* 2001; 212(2):211-21.
- Lotz J, Cheal E, Hayes W. Stress distributions within the proximal femur during gait and falls: implications for osteoporotic fracture. *Osteoporos Int.* 1995; 5:252-61.
- Pidaparti R, Turner C. Cancellous bone architecture: advantages of nonorthogonal trabecular alignment under multidirectional joint loading. *J Biomech.* 1997; 30:979-83.
- Skedros JG, Baucom SL. Mathematical analysis of trabecular 'trajectories' in apparent trajectorial structures: the unfortunate historical emphasis on the human proximal femur. *J Theor Biol.* 2007; 244(1):15-45.
- Milovanovic P, Potocnik J, Stoiljkovic M, Djonic D, Nikolic S, Neskovic O, et al. Nanostructure and mineral composition of trabecular bone in the lateral femoral neck: Implications for bone fragility in elderly women. *Acta Biomater.* 2011; 7(9):3446-51.

Морфолошка обележја проксималног крајка бутне кости током развоја: биомеханички аспекти

Марија Ђурић¹, Петар Миловановић¹, Данијела Ђонић¹, Арса Минић², Михаел Хан³

¹Лабораторија за антропологију, Институт за анатомију, Медицински факултет, Универзитет у Београду, Београд, Србија;

²Амерички медицински факултет у Београду, Европски универзитет, Београд, Србија;

³Институт за остеологију и биомеханику, Универзитетска болница Хамбург-Епендорф, Хамбург, Немачка

КРАТАК САДРЖАЈ

Увод За разлику од обиља студија које су анализирале горњи крајак бутне кости код одраслих особа, његова спољашња и унутрашња морфологија код деце нису довољно истраживане.

Циљ рада Испитивали смо промене спољашње и унутрашње морфологије горњег крајка бутне кости које настају током раста и развоја ради утврђивања њихове повезаности с биомеханичким чиниоцима који делују на бутну кост човека.

Методе рада На горњим крајцима бутне кости 29 особа (узраста од месец дана до 14 година) из археолошког контекста испитивани су спољашња геометрија, унутрашња грађа трабекуларне и кортикалне кости, као и минерална густина кости, применом макроскопских, микроскопских и радиолошких метода.

Резултати С узрастом детета долази до пораста ширине и дужине врата бутне кости, с тим да он постаје у целини издуженији, као и смањења колодијафизарног угла. Постоји јака

позитивна повезаност узраста детета и стандардизоване минералне густине кости. Паралелни распоред трабекула који постоји на рођењу мења се тако да се од осмог месеца могу препознати три посебне групе трабекула (компресивна група, тензиона група и насумичне групе). Горњи и доњи сегмент врата бутне кости код деце старијег узраста се различито мењају, тако да доњи део врата има дебљи слој кортикалне кости и дебље трабекуле.

Закључак Примећене морфолошке промене представљају адаптацију на дејство механичких сила на бутну кост у развоју. Наши резултати о унутрашњој грађи у складу су с новијим биомеханичким схватањима која истичу превагу компресивних напона, доминантну адаптацију на смицање, значај мишићних ефеката и вишеосовинског оптерећења, као и постојање адаптационе ексцентричности унутрашње грађе врата бутне кости.

Кључне речи: горњи крајак бутне кости; раст; адаптација кости; механичко оптерећење