

Influence of Different Methods of Internal Bone Fixation on Characteristics of Bone Callus in Experimental Animals

Djordje Gajdobranski^{1,2}, Milorad Mitkovic^{3,4}, Nada Vučković^{1,5}, Miroslav Milankov^{1,6}, Slobodan Jovanović⁷, Miodrag Manić⁷, Milan Mitković⁴

¹Medical Faculty, University of Novi Sad, Novi Sad, Serbia;

²Institute for Youth and Health Care of Vojvodina, Novi Sad, Serbia;

³Medical Faculty, University of Niš, Niš, Serbia;

⁴Orthopedic and Traumatology Clinic, Clinical Center, Niš, Serbia;

⁵Center for Pathology and Histology, Clinical Center of Vojvodina, Novi Sad, Serbia;

⁶Clinic of Orthopedics and Traumatology, Clinical Center of Vojvodina, Novi Sad, Serbia;

⁷Mechanical Faculty, University of Niš, Niš, Serbia

SUMMARY

Introduction Correct choice of osteosynthesis method is a very important factor in providing the optimal conditions for appropriate healing of the fracture. There are still disagreements about the method of stabilization of some long bone fractures. Critically observed, no method of fracture fixation is ideal. Each osteosynthesis method has both advantages and weaknesses.

Objective The objective of this study was to compare the results of the experimental application of three different internal fixation methods: plate fixation, intramedullary nail fixation and self-dynamisable internal fixator (SIF).

Methods A series of 30 animals were used (*Lepus cuniculus*) as experimental animals, divided into three groups of ten animals each. Femoral diaphysis of each animal was osteotomized and fixed with one of three implants. Ten weeks later all animals were sacrificed and each specimen underwent histological and biomechanical testing.

Results Histology showed that the healing process with SIF was more complete and bone callus was more mature in comparison to other two methods. During biomechanical investigation (computerized bending stress test), it was documented with high statistical significance that using SIF led to stronger healing ten weeks after the operation.

Conclusion According to the results obtained in this study, it can be concluded that SIF is a suitable method for fracture treatment.

Keywords: intramedullary nail fixation; plate fixation; self-dynamisable internal fixator; experimental animals

INTRODUCTION

Compared to other tissues and organs, the skeletal system has a significant regeneration potential. Fracture healing is an extremely complex interaction of cells, biologic pathways, and molecules. Certainly, the inflammatory response is one of the initiating factors of bone healing [1, 2]. Although the regenerative potential of bone tissue is very high, the healing process is disturbed in 5% to 10% of cases which can result in delayed union or nonunion [3-7]. Considering the frequency of fractures, high incidence of healing disorders identifies a significant problem in modern traumatology. Animal models of fracture consolidation are fundamental for understanding of biological process of bone repair in humans [8].

There are several factors that may cause disorders in fracture healing: the severity of the wound, i.e. degree of damage to the surrounding soft tissue, degree of dislocation and fragmentariness, infection, loss of bone tissue, fracture stability, fragment distraction, bone

vascularization after trauma, patient's age, diet, etc. It is important to mention that insufficient vascularization, caused by trauma that led to fracture, can also be seriously damaged by the operative treatment, i.e. the selection of osteosynthesis method as well as the surgical technique, can significantly affect the process of healing. The surgical technique, osteosynthesis method, stability of fracture and infection are factors that can be controlled by an orthopedic surgeon in the process of appropriate fracture healing.

Correct choice of osteosynthesis method is a very important factor in providing the optimal conditions for appropriate healing of the fracture. There are still disagreements about the method of stabilization of some long bone fractures. Critically observed, no method of fracture fixation is ideal.

Considering the importance of the problem of delayed union and nonunion of bone fractures from the medical and socio-economical perspective, a great number of studies, both clinical and experimental, are justified because

Correspondence to:

Djordje GAJDOBRANSKI
Institute for Youth and Health
Care of Vojvodina
Hajduk Veljkova 10
21000 Novi Sad
Serbia
dr@gajdobranski@gmail.com

they help improve the existing and development of new methods of osteosynthesis with the aim of solving this great problem of modern traumatology.

In this work, an experimental model was used for performing an indirect comparison of three methods of the internal fixation by analyzing the histological and biomechanical characteristics of bone callus. The first two methods, intramedullary nail and plate osteosynthesis represent standard procedures for treating long bone fractures. The third method, the application of self-dynamisable internal fixator (SIF), represents a novelty that unites positive characteristics of the external fixation and the internal osteosynthesis.

OBJECTIVE

The aim of this study was to compare the results of the experimental application of three different internal fixation methods: plate fixation, intramedullary nail fixation and SIF.

METHODS

Experimental model

Healthy rabbits (*Lepus cuniculus*, i.e. *Lepus canis*, order: *Lagomorpha*), type Chinchilla, were used as experimental animals, which provided approximately equal genetic characteristics, including the reaction to trauma and infection. Both sexes were used equally, with similar weight and age. All rabbits were sexually mature, with average age of 6 months (5 to 7 months), of approximately similar weight (average weight 1420g), and raised under equal conditions.

The experimental work included operative treatments on thigh-bones of experimental animals (total of 30 rabbits), followed by monitoring the process of healing by histological analysis and biomechanical examination. The femur was selected for two reasons: first, because of the use of new implants which are examined in the healing of femoral fracture in humans, and second, because low bone density and large muscle mass predispose rabbits to femoral fractures [9].

Experimental animals were premedicated by i.m Atropine (0.02-0.04 mg/kg). Introduction and maintenance of general anesthesia was performed by administering 5%




Figure 1a-d. Osteotomy of the rabbit femur using Gigli saw and implantation of intramedullary nail

Ketamine hydrochloride, in a dosage of 80mg/kg. The surgical treatment was completed according to the principles of asepsis and antisepsis. The operative procedures were performed on the rear right limbs, whereas some of the rear left limbs were used as controls. A lengthwise cut through the skin and subcutaneous tissue on the lateral section of the thigh enabled the access to femoral muscles. Thereafter, the fascia was separated between *Caput vertebrale m. bicipitis femoris* and *Caput pelvinum m. bicipitis femoris*, allowing the femur to be reached. All experimental animals were divided into three groups by random sampling.

In the first group – Group 1 (10 rabbits), after having separated the surrounding muscles, a transversal osteotomy was done in the middle part of the femoral diaphysis using a Gigli saw ($\phi=1$ mm), and the fracture was fixed by an intramedullary nail ($\phi=2.6$ mm) (Figure 1a-d).

In the second group of animals – Group 2 (10 rabbits), after having separated the surrounding muscles, a plate was applied which was fixed on the lateral side of the femoral bone by four screws. Then, a transversal osteotomy was performed by Gigli saw in the middle part of femoral diaphysis, between the second and the third screw (Figure 2a-c).

With the third group – Group 3 (10 rabbits), the surrounding muscles were separated and SIF was fixed on the lateral part of the femoral bone using four clamps, and then a transversal osteotomy, 1 mm in diameter, was done, in the middle part of diaphysis of the femoral bone, as described in previous two groups of animals (Figure 3a-d).

Intramedullary nails, plates, clamps, screws and the bar of the internal fixator were made of stainless steel for



Figure 2a-c. Implantation of plate and screws in rabbit femur and osteotomy by Gigli saw


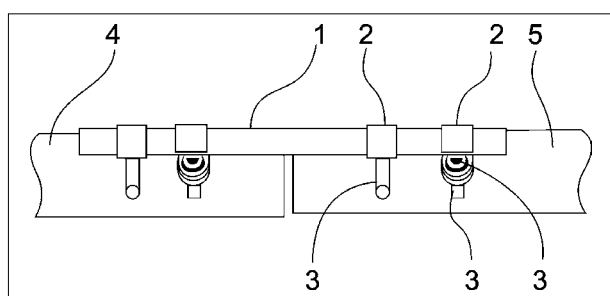


Figure 3a-d. Implantation of SIF in rabbit femur and osteotomy by Gigli saw



Drawing 1. Self-dynamisable internal fixator (SIF)

implants, type 316L (ASTM F 138-2), manufactured by Traffix DOO (Serbia). Intramedullary nail was 2.6 mm in diameter and 58 mm long. Plates were 35 mm long, 6 mm wide and 1.5 mm thick with 4 holes. All screws for plates and internal fixators were cortical screws 2.5 mm in diameter and 17 mm long. Self-dynamisable internal fixator consisted of 2 mm diameter and 42 mm long bar and four clamps (Drawing 1). Each clamp (2) has a hole for the bar (1) and perpendicular hole for the screw (3). The construction of the clamps and screws provides two functions. The first is the possibility of three-dimensional fixation of each main bone fragment (4) and (5), as each clamp (2) can rotate around the bar (1), and screws (3) can be applied in convergent configuration. The second function is that the construction of each clamp and screw complex provides spontaneous axial telescoping and consequent biocompression on the fracture area. If there is no axial contact between fragments (4) and (5) on the fracture area, then muscle activity and bone fragment micromotion may lead to loosening of screws and clamps and cause spontaneous telescoping. Because of this feature - spontaneous dynamization - only in case when there is no stability of the fracture site, the implant can be regarded as an "Intelligent implant". This implant known as self-dynamisable internal fixator (SIF) has been developed by senior author Mitkovic BM [10].

The wound was cleaned with sterile physiological solution, along with the appropriate hemostasis, and stitched along anatomic layers. Postoperatively, the rabbits were kept in separate cages, and given standard food and water. Throughout the postoperative period, daily clinical

control of the animals was performed and combined with the antibiotic therapy (Penicillin 200.000 IU/24 h i.m. and Gentamicin 4 mg/kg/24 h i.m.) during the first three postoperative days. At the beginning, the animals were moving in the cage using the operated leg without support. The clinical control included monitoring the behavior of the animals, possible food rejection, mood changes, and general veterinary examination with the inspection of the wound and recording of possible systemic and local infections.

Ten weeks after the procedure all animals were sacrificed in order to monitor the healing of the fracture according to the types of internal fixation. A disarticulation of the hip joint was done and the obtained preparations were used for further investigations.

Histological evaluation

The bone callus was taken for a histological analysis, fixed in formalin, decalcinated, and processed with standard histologic procedure. Bone cuts were made in longitudinal and transversal plane relative to the osteotomy site whereby a complete union area was obtained for analysis. Microscopic analysis was done by the light microscope.

Biomechanical evaluation

The remaining preparations, 9 from each group, were prepared for biomechanical testing by removing the surrounding tissue and osteosynthetic material (Figures 4a,b and 5). After sacrificing the experimental animals, the surrounding musculature was carefully removed from the operated bones. The femoral bones were wrapped in gauzes saturated in physiological solution, and stored in freezer at -8°C . Immediately before testing, the femoral

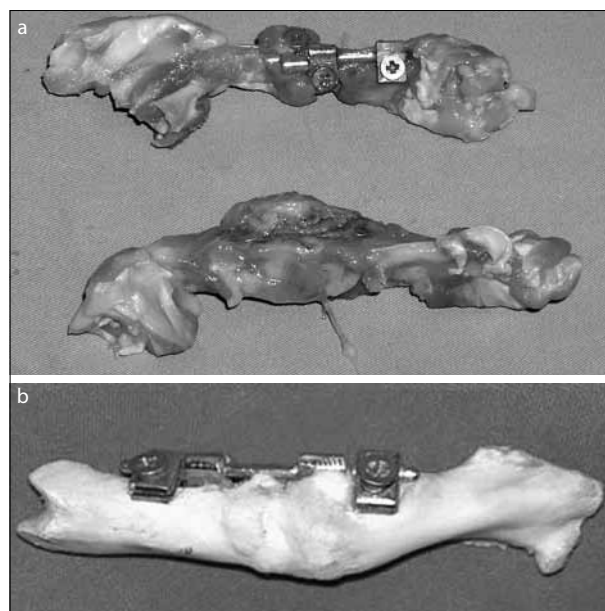


Figure 4a,b. Preparations for biomechanical testing before complete removal of muscles and osteosynthetic material




Figure 5. Mechanical testing of rabbit femur after removal of soft tissues and implants

bones were defrosted at room temperature for 24 hours, after which the osteosynthetic material was removed. At the moment of testing, the temperature of the bones after conservation was 23–25°C.

After sacrificing the animals, two femoral bones from each group were taken from the extremities that have not undergone experimental work. After removing the musculature, one femoral bone from each group underwent biomechanical testing a few hours later, in order to obtain the parameters of healthy, fresh bones. Other healthy femoral bones, one from each of three groups, were prepared in the same manner as the operated bones and stored in the freezer along with the operated bones with the aim of obtaining the parameters of healthy, conserved bones.

The biomechanical characteristics of the bones were tested at the Measurement Laboratory of the Faculty of Mechanical Engineering in Nis.

The measurement techniques used in the experiment

Electrical methods of measuring of mechanical quantities were used to test the strength of the bones. Equipment included: measurement transducer, amplifier and registration device. The following devices were used in the experiment: force measurement cell (sensor) U1/50 kg, manufactured by Hottinger Baldwin Messtechnik GmbH, Germany, path measurement cell (sensor) W20 TK, manufactured by Hottinger Baldwin Messtechnik GmbH, Germany, measurement amplifier DMC 9012A with 6 channels manufactured by Hottinger Baldwin Messtechnik GmbH, Germany, and measurement computer Notebook 520 C manufactured by Apple-McIntosh with BEAM software ver. 3.1 manufactured by Hottinger Baldwin Messtechnik GmbH, Germany.

RESULTS

After the removal of osteosynthetic material, histological analysis of the callus was performed, along with biomechanical testing.

Histology

Histological analysis of bone callus in Group 1

There were areas of necrosis at osteotomy site but with no signs of fresh bleeding and with necrosis of the bone marrow fat tissue (Figure 6a). Proliferated bone trabeculae with equal width and irregular distribution were found around necrosis foci (Figure 6b). An incomplete layer of osteoblasts was located around the bone trabeculae. The periosteum was focally thickened, with unequal width and with newly formed hyaline cartilage of irregular width (Figure 6c). The endosteal reaction included an incomplete scope of proliferated, hyperplastic osteoblasts.

Histological analysis of bone callus in Group 2

At osteotomy site, there were tiny bone fragments of various sizes and shapes with an incomplete layer of osteoblasts (Figure 7a). Bone marrow was edematous with foci of fat tissue necrosis and slightly fibrosed. Periosteal reaction was composed of proliferated hyaline cartilage with the signs of endochondral ossification (Figure 7b). The zone of endochondral ossification was wide and distinctive but with less regular distribution of chondrocytes (Figure 7c). Endosteal reaction was composed of an incomplete order of osteoblasts distributed around bone trabeculae.

Histological analysis of bone callus in Group 3

Bone trabeculae at osteotomy site were of various size and shape, surrounded by the line of osteoblasts (Figure 8a). In the bone marrow, one part of fat tissue was replaced by proliferated connective tissue. Towards the cortical bone, the bone trabeculae were more regularly positioned and they were distributed parallel to the cortex (Figure 8b). Outside of osteotomy site the bone had normal morphological appearance with preserved bone marrow which was fatty and hematopoietically active. The periosteum within osteotomy area was thickened and elevated above the cortical part of the bone (Figure 8c). Between the connective tissue of the periosteum and the cortical part of the bone, there was a layer of hyaline cartilage with the signs of proper endochondral ossification. Endosteal reaction was composed of multiplied and hyperplastic osteoblasts around the newly formed bone trabeculae.

Biomechanical testing

Following the sacrificing of the animals, two femoral bones were taken from each group that had not undergone experimental work. After removing the surrounding tissue, one femoral bone from each group was subjected to few hours of biomechanical testing. The remaining bones were tested biomechanically after defrosting, along with the operated femoral bones. After the application of load,

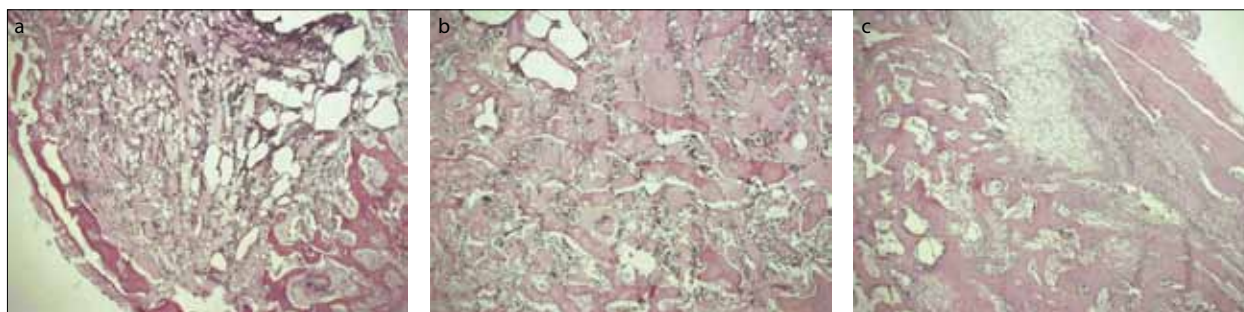


Figure 6a-c. Histological characteristics of callus – Group 1

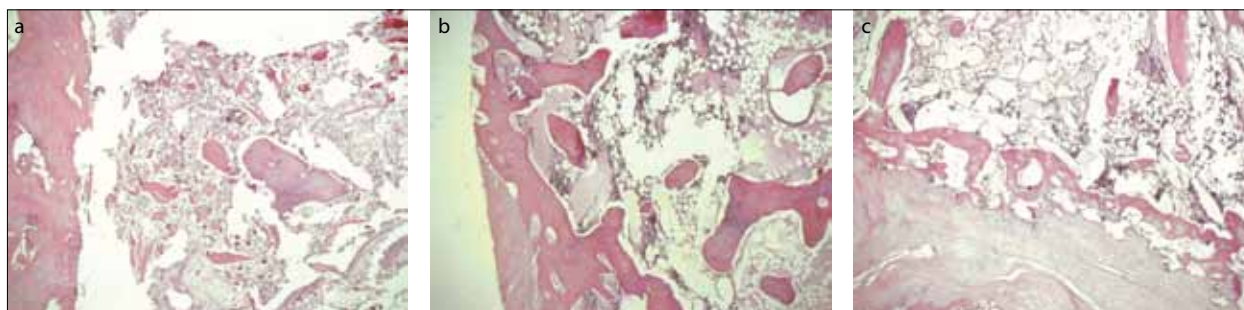


Figure 7a-c. Histological characteristics of callus – Group 2

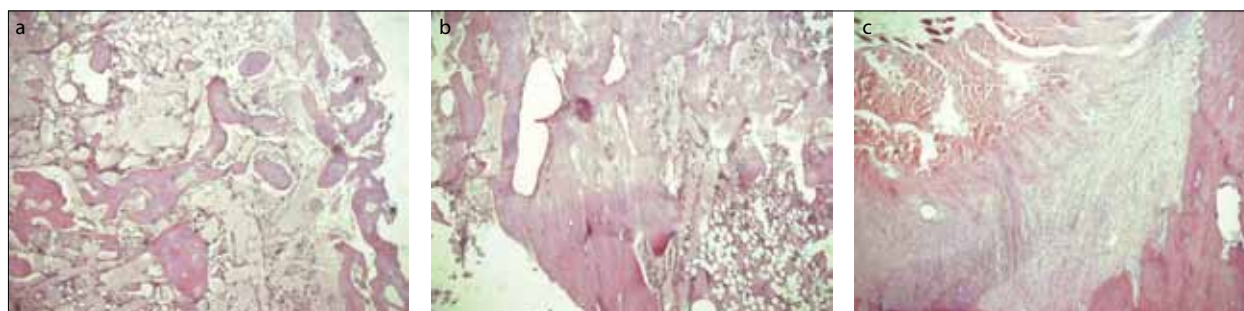


Figure 8a-c. Histological characteristics of callus – Group 3

fracture occurred at a certain moment, depending on the acquired firmness of the callus, i.e. the newly formed bone.

The average quantity of force necessary to cause fracture of a healthy fresh rabbit femoral bone was 350 N, whereas the average quantity of force necessary to cause fracture of a healthy conserved bone was 325 N.

The average value of deflection before the moment of fracture of healthy fresh rabbit femoral bone due to force was 1.5 mm, whereas the average value of deflection of healthy conserved bone due to force was 1.45 mm.

The average value of time necessary for the effect of force to lead to the fracture of a healthy fresh rabbit femoral bone was 4.8s, whereas the average value of time needed for the fracture of a healthy conserved bone due to the effect of force is 2.7 seconds.

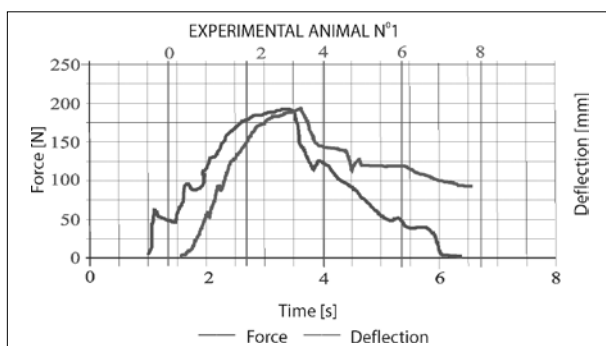
The results of biomechanical testing of union in Group 1

Out of nine preparations, biomechanical testing was performed in eight. The remaining preparation was not tested because complete disintegration was verified. Biomechanical testing of eight preparations provided the following

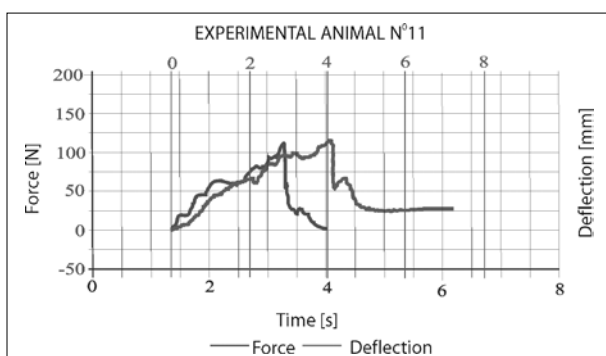
values: average value of force necessary for the fracture of femoral bone was 173.75 N; average value of deflection of the femoral bone due to force was 3.64 mm; average value of time the effect of force needed to cause the fracture of the femoral bone was 3.26 s. Graph 1 shows the results of biomechanical testing of experimental animal number 1.

The results of biomechanical testing of union in Group 2

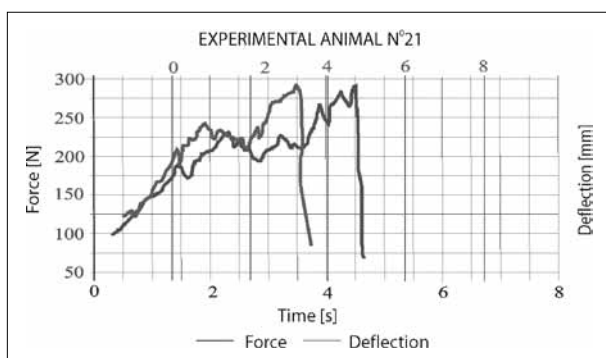
Out of nine preparations, the biomechanical testing was performed in seven. Two preparations were not tested because one was found to be completely disintegrated while femoral bone nonunion was evident in another, i.e. pseudarthrosis was found after the removal of plate. The biomechanical testing of seven preparations provided the following values: average value of force necessary for the fracture of femoral bone was 92.86 N; average value of deflection of the femoral bone due to force was 4.03 mm; average value of time the effect of force needed to cause the fracture of the femoral bone was 4.63 s. Graph 2 shows the results of biomechanical testing of experimental animal number 11.



Graph 1. The result of biomechanical testing of experimental animal number 1



Graph 2. The result of biomechanical testing of experimental animal number 11



Graph 3. The result of biomechanical testing of experimental animal number 21

The results of biomechanical testing of union in Group 3

Biomechanical testing was done with eight preparations. The preparation with a complete disintegration was not tested. The biomechanical testing provided the following values: average value of force necessary for the fracture of femoral bone was 273.75 N; average value of deflection of the femoral bone due to force was 5.06 mm; average value of time the effect of force needed to cause the fracture of the femoral bone was 4.46 s. Graph 3 shows the results of biomechanical testing of experimental animal number 21.

DISCUSSION

This work uses experimental models in order to perform an indirect comparison of three methods of the internal

fixation by analyzing the histological and biomechanical characteristics of bone callus. The first two methods, the intramedullary nail osteosynthesis and plate osteosynthesis are part of standard procedures of long bone fracture treatment. The third method, the application of SIF, represents a novelty that combines positive characteristics of the external fixation and plate osteosynthesis [10].

Choosing an experimental animal model is suitable for further development of trauma implant. Isaksson and associates have shown recently [11] that during the remodeling phase of fracture healing in mice, the callus gradually transforms into a double cortex, which thereafter merges into one cortex. In large animals, a double cortex normally does not form. The effects of biological differences between species or other reasons cannot be excluded, but this study demonstrates how the difference in loading mode can explain the differences between the remodeling phase in small rodents and larger mammals.

The use of locked bridge plating relies on secondary bone healing, which requires interfragmentary motion for callus formation. Recent study by Bottlang et al. [12] evaluated healing of fractures stabilized with the locked plating construct and far cortical locking construct, which is a modified locked plating approach that promotes interfragmentary motion. The study tested whether far cortical locking constructs can improve fracture-healing compared with standard locked plating constructs. They used ovine tibial osteotomy model stabilized with locked plating or far cortical locking constructs applied medially where the far cortical locking constructs were designed to provide 84% lower stiffness than the locked plating constructs and permitted nearly parallel gap motion. Fracture healing was monitored on weekly radiographs. After the animals were sacrificed at week 9, healed tibiae were analyzed by computed tomography, mechanical testing in torsion, and histological examination.

The results showed that callus on weekly radiographs was greater in the far cortical locking constructs than in the locked plating constructs. Callus in the locked plating specimens was asymmetric, having 49% less bone mineral content in the medial callus than in the lateral callus. In far cortical locking specimens, medial and lateral callus had similar bone mineral content. The far cortical locking specimens healed to be 54% stronger in torsion. They concluded that inconsistent and asymmetric callus formation with locked plating constructs was likely due to their high stiffness and asymmetric gap closure. By providing flexible fixation and nearly parallel interfragmentary motion, far cortical locking constructs formed more callus and healed to be stronger in torsion than locked plating constructs. However, the influence of the mechanical stability of individual stabilization techniques on the molecular mechanisms of fracture healing has not been completely elucidated yet [13]. Another recent experimental study investigated the effect of an intramedullary suction system on the pressure and fat extravasation in isolated bovine bone and sheep model [14]. The suction system appears to control the surge in intramedullary pressure and therefore prevent fat embolism.

In our study, intramedullary nail without a locking system was used as it is difficult to provide such a small interlocking system. Thus, the contact between fragments in osteotomized bone is not prevented, thereby providing possibility for better healing. On the other hand, the IM nail is rotation-unstable. Schoen and associates have recently developed a new intramedullary, rotation-stable locking device, usable in standardized osteotomized rat femurs, and evaluated it biomechanically and *in vivo* for maintenance of a critical-size osteotomy gap in a model of conscious pseudarthrosis [15]. Previously, stabilization of osteotomies in small animal models has mainly been accomplished by Kirschner wires, but the rat's tremendous ability to heal an osteotomy stabilized by this method has masked the effects of osteoinductive agents. Russell and associates in their study propose a modified 20-hole, 1.5-mm stainless-steel plate to stabilize 5-mm segmental defect [16]. Instability of fixed osteotomized bone prolongs the chondral phase during the bone healing [17]. In this study, sixty-four sheep underwent mid-shaft tibial osteotomy that was treated either with rigid or semi-rigid external fixator. Animals were sacrificed at 2, 3, 6 and 9 weeks postoperatively and the fracture calluses were analyzed using radiological, biomechanical and histological techniques. The mechanical competence of the healing callus at 6 weeks was inferior compared to tibiae treated with rigid fixation. Semi-rigid fixation resulted in a larger cartilage component of the callus, which persisted longer. Remodeling processes were initiated earlier in the rigid group, while new bone formation continued throughout the entire investigation period in the semi-rigid group. This study provided evidence that less rigid fixation increased the time required for healing. The process of intramembranous ossification that appeared during the initial stages of healing proved to be independent of mechanical stability. However, the delay in healing was related to prolonged chondral phase.

Using intramedullary nail in studies on experimental animals can often lead to implant failure due to small nail diameter. In order to prevent this experimental complication, Durall and associates conducted a study [18] in which they determined bone healing at 20 weeks, after either static fixation (SG) or dynamization (DG) at 4 weeks in osteotomized canine femurs repaired with the interlocking nail (ILN) secured with a type I external skeletal fixator (ESF). They found that ILN locked with a type I ESF can be used for fixation of mid-shaft femoral fractures. Dynamization at 4 weeks did not affect bone healing but prevented stifle ankylosis and promoted earlier limb function. These experimental results can influence further development in diaphyseal femoral fractures even in human traumatology.

Regarding biomechanical testing and evaluation of healing of the experimentally osteotomized animal long bones, the torsion test [12] or bending stiffness measurement [19] are most commonly used. In our study, we used the bending stiffness test.

During the healing process, experimental osteotomy model shows changes in biomechanical characteristics. Our results are similar to the results obtained in canine

model [20] but vary in terms of the fixation methods being used.

Recently, new internal fixing materials made from shape-memory alloys (SMAs) have been used for long bone fracture [21]. The implant was designed in a shape to circumferentially fix the fractured bone using resilient SMA claws. Fifteen female Wister rats were treated surgically as an experimental model. All rats were sacrificed at 16 weeks postoperatively, and radiological and histological evaluations were performed. In biomechanical test, good fixation ability of the implant was demonstrated. In animal model, there were no cases of postoperative infection or death and postoperative gait was stable in all cases. Radiological examination at 16 weeks postoperatively demonstrated the implant firmly fixed to the fractured part, endosteal healing, and no callus formation in all cases. In the histological evaluation, bone union in all cases was characterized by endochondral ossification from within the medullary cavity. Union was achieved in all 15 rats. However, such large plate-like implants are even more suitable from the biomechanical point of view. It separates muscles from pretty big bone surface and also needs more testing on bigger animals to prove that healing is comparable with methods which preserves periost.

Histomorphometric (quantitative) evaluation of the present study was shown to be compatible with bone healing achieved in qualitative experimental models that have been found in literature. The analysis of histological preparations with tested methods of the internal fixation in our study has demonstrated that, contrary to other methods of internal fixation, the preparation in which, after osteotomy the bone fragments have been stabilized by SIF for ten weeks, has the callus possessing the histological characteristics which show that the process of bone healing is partly finished and that in these cases the callus has acquired morphological characteristics of healthy mature bone.

During the defined periods of application, the method of SIF osteosynthesis has demonstrated the best results in biomechanical testing. In other words, there is a statistically significant difference between SIF and other methods of internal fixation. Within biomechanical testing, it was necessary to apply the greatest amount of force in order to cause fracture of the rabbit femoral bone in which SIF was applied after osteotomy for a period of ten weeks. The obtained values are very close to the values provided by the mechanical testing of healthy conserved rabbit femoral bone. We have explained it by the feature of SIF because over time screws and clamps become a little bit loose, thus contributing to more implant elasticity and possibility of telescoping (compression by muscles force) which is desirable in later stages of bone healing.

CONCLUSION

According to the results obtained in this study, it can be concluded that SIF is a suitable method for the treatment of fractures as it has more advantages over plate and intramedullary nail fixation.

REFERENCES

- Pape HC, Marcucio R, Humphrey C, Colnot C, Knobe M, Harvey EJ. Trauma-induced inflammation and fracture healing. *J Orthop Trauma*. 2010; 24(9):522-5.
- Gajdobranski Dj, Živković D. Disorders in fracture healing. *Med Pregl*. 2003; 56(1-2):39-42.
- Boer FC, Patka P, Bakker FC, Haarman HJThM. Current concepts of fracture healing, delayed unions, and nonunions. *Osteosynthesis and Trauma Care*. 2002; 10:1-8.
- Runkel M, Rommens PM. Pseudoarthrosen. *Unfallchirurg*. 2000; 103:51-63.
- Rüter A, Mayer E. Pseudoarthrosen. *Chirurg*. 1999; 70:1239-45.
- Hulth A. Current concepts of fracture healing. *Clin Orthop*. 1989; 249:265-84.
- Gajdobranski Dj, Micić I, Mitković M, Mladenović D, Milankov M. Management of impaired fracture healing: historical aspects. *Med Pregl*. 2005; 58(9-10):507-12.
- Matos MA, Araújo FP, Paixão FB. Histomorphometric evaluation of bone healing in rabbit fibular osteotomy model without fixation. *J Orthop Surg Res*. 2008; 3:4.
- Reuter JD, Ovadia S, Howell P, Jaskwich DH. Femoral fracture repair and postoperative management in new zealand white rabbits. *Contemp Top Lab Anim Sci*. 2002; 41(4):49-52.
- Mitković M, Bumbaširević M, Golubović Z, Mladenović D, Milenković S, Micić I, et al. New biological method of internal fixation of the femur. *Acta Chir Iugosl*. 2005; 52:113-6.
- Isaksson H, Gröngroft I, Wilson W, van Donkelaar CC, van Rietbergen B, Tami A, et al. Remodeling of fracture callus in mice is consistent with mechanical loading and bone remodeling theory. *J Orthop Res*. 2009; 27(5):664-72.
- Bottlang M, Lesser M, Koerber J, Doornink J, von Rechenberg B, Augat P, et al. Far cortical locking can improve healing of fractures stabilized with locking plates. *J Bone Joint Surg Am*. 2010; 92(7):1652-60.
- Histing T, Holstein JH, Garcia P, Matthys R, Kristen A, Claes L, et al. Ex vivo analysis of rotational stiffness of different osteosynthesis techniques in mouse femur fracture. *J Orthop Res*. 2009; 27(9):1152-6.
- Smith PN, Leditschke A, McMahon D, Sample RR, Perriman D, Prins A, et al. Monitoring and controlling intramedullary pressure increase in long bone instrumentation: a study on sheep. *J Orthop Res*. 2008; 26(10):1327-33.
- Schoen M, Rotter R, Schattner S, Mittlmeier T, Claes L, Vollmar B, et al. Introduction of a new interlocked intramedullary nailing device for stabilization of critically sized femoral defects in the rat: A combined biomechanical and animal experimental study. *J Orthop Res*. 2008; 26(2):184-9.
- Russell G, Tucci M, Conflitti J, Graves M, Wingerter S, Woodall J Jr, et al. Characterization of a femoral segmental nonunion model in laboratory rats: report of a novel surgical technique. *J Invest Surg*. 2007; 20(4):249-55.
- Epari DR, Schell H, Bail HJ, Duda GN. Instability prolongs the chondral phase during bone healing in sheep. *Bone*. 2006; 38(6):864-70.
- Durall I, Falcón C, Díaz-Bertrana MC, Franch J. Effects of static fixation and dynamization after interlocking femoral nailing locked with an external fixator: an experimental study in dogs. *Vet Surg*. 2004; 33:323-32.
- Hente R, Führtmeier B, Schlegel U, Ernstberger A, Perren SM. The influence of cyclic compression and distraction on the healing of experimental tibial fractures. *J Orthop Res*. 2004; 22(4):709-15.
- Hara Y, Nakamura T, Fukuda H, Harada Y, Nezu Y, Tagawa M. Changes of biomechanical characteristics of the bone in experimental tibial osteotomy model in the dog. *J Vet Med Sci*. 2003; 65(1):103-7.
- Kawakita E, Wang Z, Kato T, Inaba T, Kasai Y. Basic research on a cylindrical implant made of shape-memory alloy for the treatment of long bone fracture. *Open Orthop J*. 2012; 6:239-44.

Утицај различитих метода унутрашње фиксације костију на особености коштанога калуса експерименталних животиња

Ђорђе Гајдобрански^{1,2}, Милорад Митковић^{3,4}, Нада Вучковић^{1,5}, Мирослав Миланков^{1,6}, Слободан Јовановић⁷, Миодраг Манић⁷, Милан Митковић⁴

¹Медицински факултет, Универзитет у Новом Саду, Нови Сад, Србија;

²Институт за здравствену заштиту деце и омладине Војводине, Нови Сад, Србија;

³Медицински факултет, Универзитет у Нишу, Ниш, Србија;

⁴Клиника за ортопедију и трауматологију, Клинички центар, Ниш, Србија;

⁵Центар за патологију и хистологију, Клинички центар Војводине, Нови Сад, Србија;

⁶Клиника за ортопедију и трауматологију, Клинички центар Војводине, Нови Сад, Србија;

⁷Машински факултет, Универзитет у Нишу, Ниш, Србија

КРАТАК САДРЖАЈ

Увод Избор методе остеосинтезе је веома важан фактор у обезбеђивању оптималних услова за одговарајуће зарастање прелома кости. И даље постоје неслагања око методе стабилизације прелома дугих костију. Критички посматрано, ниједна метода фиксације коштаних уломака није идеална; свака метода остеосинтезе има и предности и недостатке.

Циљ рада Циљ овог рада је био да се упореде резултати експерименталне примене три различите методе унутрашње фиксације: интрамедуларне фиксације клином, фиксације плочицом и фиксације самодинамизирајућим унутрашњим фиксатором (СИФ).

Методе рада Као експериментална животиња коришћен је кунџ (*Lepus cuniculus*). Укупно је 30 животиња сврстано у три групе од по десет животиња. Код сваке животиње начињене су остеотомија дијафизе бутне кост и фиксација једним од

три имплантата. Десет недеља након остеотомије и фиксације све животиње су жртвоване, а препарати су подвргнути хистолошкој анализи и биомеханичком испитивању.

Резултати Хистолошке анализе су показале да је процес зарастања био потпунији а коштани калус зрелији код животиња код којих је примењена фиксација СИФ у односу на друге две методе фиксације. Биомеханичко испитивање, компјутеризованим стрес-тестом савијања, показало је да употреба СИФ доводи до високо статистички значајно јачег коштанога зарастања у односу на друге две методе фиксације.

Закључак На основу добијених резултата може се закључити да је фиксација применом СИФ погодна метода у лечењу прелома кости.

Кључне речи: интрамедуларна фиксација клином; фиксација плочицом; самодинамизирајући унутрашњи фиксатор; експерименталне животиње