

Morning Glory Syndrome Associated with Primary Open Angle Glaucoma – Case Report

Marija Božić^{1,2}, Paraskeva Hentova-Senčanić^{1,2}, Vujica Marković^{1,2}, Ivan Marjanović²

¹Faculty of Medicine, University of Belgrade, Belgrade, Serbia;

²Clinic for Eye Diseases, Clinical Center of Serbia, Belgrade, Serbia

SUMMARY

Introduction Morning glory syndrome (MGS) is a rare congenital optic disc anomaly, first reported in 1970. MGS is a nonprogressive and untreatable condition, which usually occurs as an isolated ocular anomaly, and can be associated with the increased incidence of nonrhegmatogenous retinal detachment, and also with strabismus, afferent pupillary defect, visual field defects, presence of hyaloids artery remnants, ciliary body cyst, congenital cataract, lid hemangioma and preretinal gliosis.

Case Outline We report a clinical case of MGS associated with primary open angle glaucoma. The use of sophisticated diagnostic tools, such as retinal tomography and visual field testing is limited if multiple eye conditions are present, since optic disc does not have "usual" appearance that can be analyzed according to standard statistical databases.

Conclusion In treating and follow up of glaucoma cases associated with other diseases and conditions that affect the appearance and function of the optic nerve head, sometimes the use of modern technological methods is limited due to difficult interpretation of the obtained results.

Keywords: glaucoma; morning glory; syndrome

INTRODUCTION

Morning glory syndrome (MGS) is a rare congenital optic disc anomaly, first reported in 1970 by Kindler [1], and possibly even ten years earlier by Pendlar [2]. This anomaly usually affects one eye and is characterized by an enlarged, funnel-shaped optic disc with the central mass of glial tissue and retinal vessels that emerge from the central core in radial pattern, and run straight towards the peripheral retina [3]. MGS is a nonprogressive and untreatable condition, which usually occurs as an isolated ocular anomaly, but its accurate diagnosis is especially important because of its possible association with the systemic anomalies (kidney, skull, central nervous system) and the increased incidence of nonrhegmatogenous retinal detachment. MGS can also be associated with strabismus, afferent pupillary defect, visual field defects (blind spot enlargement and central scotomata), presence of hyaloids artery remnants, ciliary body cyst, congenital cataract, lid hemangioma and preretinal gliosis [4, 5, 6]. This condition is more common in females.

We report a clinical case of the unilateral MGS associated with bilateral primary open angle glaucoma. One single case of MGS associated with glaucoma has been described in literature by Rinaldi et al. [7] in 1986. Back in those years, there was a lack of sophisticated diagnostic and follow up tools in ophthalmology such as Heidelberg retinal tomography II (HRT II) and visual field testing. Nevertheless, sometimes in our busy everyday practice, we come across cases in which the use of all

modern technological achievements is of little help. The aim of this report was to present a possible approach to complex ophthalmological problem such as the coexistence of multiple optic disc findings and glaucoma, which can be challenging in making the right diagnose and opting for the best therapeutical modality.

CASE REPORT

A 45-year old woman was referred with stinging sensation in both of her eyes. At the first examination, her best-corrected visual acuity was 20/20 in her right eye (native), and 2/60 in her left eye, which could not be improved by lenses. Slit lamp findings showed normal appearance of anterior segment structures in both eyes. The pupillary reflexes were normal, and strabismus and nystagmus were absent. Intraocular pressure (IOP) measured by Goldmann applanation tonometry was 40 mmHg and 42 mmHg in her right and left eye, respectively. Pachymetry (Palm Scan AP 2000, Ophthalmic ultrasound, 2007, Micro Medical Devices Inc. Calabasas, CA, 91302 USA) showed the central corneal thickness of 545 μ m and 547 μ m for the right and the left eye, respectively. Gonioscopy showed wide opened angles on both of her eyes, moderately pigmented (Scheie II), with no goniosynechia. Optic nerve assessment (78D lens) revealed normally looking disc in her right eye, with c/d ratio of 0.6 and morning glory disc anomaly in her left eye (Figure 1).

Peripheral retina was intact in both eyes. Standardized echographic examination re-

Correspondence to:

Marija BOŽIĆ
Maršala Biruzova 29
11000 Belgrade
Serbia
ammilovic@gmail.com

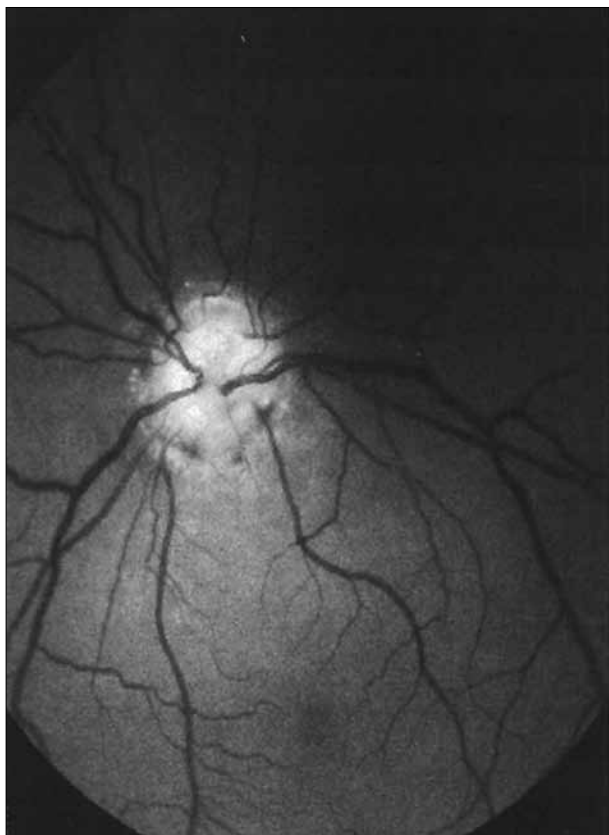

Figure 1. The fundus in the left eye




Figure 2. B scan ultrasound of the left eye

vealed axial length within normal limits (anteroposterior = 23.77 mm right, and 23.92 mm left), but B scan revealed posterior ectasia on her left eye (Figure 2). IOP phasing, laser-scanning ophthalmoscopy of the optic disc on HRT II (Heidelberg Retinal Tomography II, Heidelberg Engineering, Heidelberg, Germany) unit and visual field test (Humphrey field analyzer, Carl Zeiss Meditec, Dublin, California, USA) were performed on both eyes. IOP phasing was 24-34 mmHg and 26-32 mmHg in her right and her left eye, respectively. Visual field test showed sensitivity loss and nasal scotomata in her right eye and drastic sensitivity loss in the left eye, with the preservation of 10° of the lower half of the central visual field. MD was -19.1 (dB) and -27.7 (dB) in the right and the left eye visual field, respectively.

Since IOP could not be controlled with maximum tolerated medical therapy (timolol+ dorzolamide twice daily,

latanoprost once in the evening), the penetrating surgery to her right eye (trabeculectomy) was performed, reaching the target pressure (14 mmHg) on repeated measurements. IOP in her left eye decreased upon topical medicine (timolol+dorzolamide twice daily, latanoprost once in the evening).

HRT II printout could be interpreted for the right eye only, due to the strange appearance of her left optic disc. However, HRT examination was repeated in 41-month followup period, and no signs of significant changes in disc appearance in either eye were noticed.

Knowing that MGS can be associated with various systemic anomalies, our suggestion was to carry out the battery of tests (brain and skull CT scan, blood tests for kidney function and abdominal ultrasound), and fortunately, all findings were within normal limits.

DISCUSSION

Real pathogenesis of MGS is uncertain, but this is probably a form of optic disc dysplasia of embryological origin. This rare optic disc anomaly is thought not to be a true coloboma, but rather posterior ectasia, which is the consequence of developmental disturbance of sclera [8,9]. However, it is debatable whether MGS represents a single entity or is one of the many expressions of the same pathogenic stimulus. MGS is believed to result when incomplete neuroectodermal development leads to abnormal closure of the embryonic fissure [10]. We present a case of MGS associated with primary open angle glaucoma. Such association has been reported just once till today [7], and the authors have concluded that their reported case is a kind of congenital glaucoma associated with MGS, since they have found proof of a congenital malformation of the anterior chamber angle. In the case we present, no anomaly of the anterior chamber angle was found, so we do not propose that embryological event that led to MGS had anything to do with coincidence of glaucoma in the same patient.

Diagnosis of MGS is primarily made by stereoscopic evaluation of the optic nerve head. Overall enlargement of the affected disc, excavation and radial pattern in which vessels enter and exit the disc are three typical things to look for in such cases. However, in cases of associated chronic optic disc disease, such as glaucoma, and other conditions that also might affect disc appearance and/or its function, making the right diagnose is not an easy task. The use of sophisticated diagnostic tools, such as retinal tomography, optical coherence tomography and visual field testing, is limited in such cases, since optic disc does not have a “usual” appearance that can be analyzed according to standard statistical databases. More than often we have patients with glaucoma associated with high myopia, hypermetropia or tilted disc, all of which affects and challenges our ability to assess optic disc appearance and function. In the case we report, it is uncertain to what extent glaucomatous process played the role in reduced visual acuity in the left eye since the patient was not aware of her visual ability before. In treating glaucoma in this case, we

had to be guided simply by repeated IOP measurements, as to decide which therapeutical option is the best choice for the patient. In spite of the fact that HRT findings on the left eye were difficult or almost impossible to assess, our

patient was followed up for 41 months, but no progression on either eye was shown, so we believe that we have made the right choice – to treat the right and perform surgery on the left eye.

REFERENCES

- Kindler P. Morning glory syndrome: Unusual congenital optic disc anomaly. *Am J Ophthalmol.* 1970; 69:376-84.
- Pendler C. Unusual coloboma of the optic nerve entrance. *Br J Ophthalmol.* 1961; 45:803-807.
- Steinkuller PG. The morning glory disk anomaly: case report and literature review. *J Pediatr Ophthalmol Strab.* 1980; 17:81-7.
- Jackson W, Freed S. Ocular and systemic abnormalities associated with morning glory syndrome. *Ophthalmic Paediatr Genet.* 1985; 5:111-5.
- Jacobs M, Taylor D. The systemic and genetic significance of congenital optic disc anomalies. *Eye.* 1991; 5:470-5.
- Manschot W. Morning glory syndrome: a histopathological study. *Br J Ophthalmol.* 1990; 74:56-8.
- Rinaldi E, De Rosa G, Severino R, Cennamo G. Morning glory syndrome with chronic simple glaucoma. *Ophthalmic Paediatr Genet.* 1986; 7(1):69-72.
- Brodsky MC. Congenital optic disc anomalies. *Surv Ophthalmol.* 1994; 39:89-112.
- Ribeiro-da-Silva J. Congenital optic disc deformities. A clinical approach. *Ophthalmic Paediatr Genet.* 1985; 5(1-2):67-70.
- Cennamo C, Liguori G, Pezone A, Iaccarino G. Morning glory associated with marked persistent hyperplastic primary vitreous and lens colobomas. *Br J Ophthalmol.* 1989; 73:684-6.

Синдром „морнинг глори“ удружен с примарним глаукомом отвореног угла

Марија Божић^{1,2}, Параскева Хентова-Сенђанић^{1,2}, Вујица Марковић^{1,2}, Иван Марјановић²

¹Медицински факултет, Универзитет у Београду, Београд, Србија;

²Клиника за очне болести, Клинички центар Србије, Београд, Србија

КРАТАК САДРЖАЈ

Увод Синдром „морнинг глори“ (енгл. *morning glory*) је ретка конгенитална аномалија папиле видног живца, која је први пут описана у литератури 1970. године. Реч је о не-прогресивном и неизлечивом стању које се обично јавља као изолована очна аномалија, мада може бити повезана с повећаном учесталашћу нерегматогене аблације ретине, са страбизмом, аферентним оштећењем реакције пупиле, цистом цилијарног тела, конгениталном катарактом, оштећењима у видном пољу, хемангиомом капака и преретиналном глиозом, као и системским аномалијама бубрега, лобање и централног нервног система.

Приказ болесника Код 45-годишње жене дијагностиковани су синдром „морнинг глори“ на левом оку и примарни глауком отвореног угла на оба ока. Резултати детаљних офталмолошких прегледа ове болеснице нису се могли протумачити на уобичајен начин због специфичног изгледа папиле видног живца, па смо се у даљем лечењу руководили висином интраокуларног притиска, како бисмо одабрали најповољнији терапијски приступ.

Закључак У лечењу глаукома удруженог са другим обољењима и стањима која утичу на изглед и функцију папиле видног живца некада је употреба савремених технолошких метода ограничена због отежаног тумачења добијених налаза.

Кључне речи: глауком; морнинг глори; синдром

Примљен • Received: 15/01/2013

Прихваћен • Accepted: 16/04/2013